

M17698

The Library of the
Wellcome Institute for
the History of Medicine

MEDICAL SOCIETY
OF
LONDON
DEPOSIT

Accession Number

Press Mark

HAMILTON, John



22101771739

Joseph Lester Esq
with the Comptrol of the
Author -

LECTURES,

&c., &c.

L. A. 4.

LECTURES

ON

SYPHILITIC OSTEITIS

AND

PERIOSTITIS.

BY

JOHN HAMILTON,

SURGEON TO THE RICHMOND HOSPITAL,
AND TO SWIFT'S HOSPITAL FOR LUNATICS;
LATE PRESIDENT OF THE PATHOLOGICAL SOCIETY OF DUBLIN.

LONDON:

J. & J. CHURCHILL, NEW BURLINGTON-STREET.

DUBLIN: FANNIN & CO., GRAFTON-STREET.

1874.

- 11017412

DUBLIN:
PRINTED AT THE UNIVERSITY PRESS,
BY M. H. GILL.

M17698

WELLCOME INSTITUTE LIBRARY	
Coll.	weIMOmec
Call	
No.	WC 160
	1874
	H 212

H5

THESE Lectures, delivered at the Richmond Hospital, do not pretend to the completeness of a Systematic Treatise ; but I hope their practical nature may be found of use to the young surgeon, when studying the characters and Treatment of Syphilitic Osteitis and Periostitis.

J. H.

14, MERRION-SQUARE, NORTH,
Dublin, January 1, 1874



Digitized by the Internet Archive
in 2014

<https://archive.org/details/b20391845>

CONTENTS.



LECTURE	PAGE
I.—SYPHILITIC OSTEITIS AND PERIOSTITIS,	1
II.—IN THE CERVICAL VERTEBRÆ,	10
III.—IN THE ORBIT,	24
IV.—THE SOFT NODE,	39
V.—THE YELLOW TUBERCLE,	55
VI.—IN THE MAXILLARY AND NASAL BONES,	70
VII.—TREATMENT,	87

LECTURES,

&c. &c.

LECTURE I.

Syphilitic Osteitis and Periostitis.

THE syphilitic poison affects the periosteum and bones; either as an early or a late symptom. Disease in these structures is met with in three forms:—First, Periostitis; second, Bony Node; third, Soft Node. Other secondary symptoms, eruptions, ulcers of the throat, or of the tongue, &c., usually accompany these affections, but they are sometimes solitary. When they occur very late, that is, many years after infection, they are frequently the only symptom.

First, Periostitis.—From the intimate connexion between the periosteum and bone, it may be doubted whether the former can ever be diseaséd without the latter partaking of the morbid action. Certainly the patient will complain of pain and tenderness over a bone, as the tibia or clavicle, without there being any apparent swelling; and in the absence of any

pathological investigation it has been thought that the bone was not affected; but I have ascertained by dissection that even in these slight cases, the periosteum will not only be found more vascular and opaque, but more adherent to the bone, which latter is also more vascular. In a more decided form, the periosteum becomes thickened and indurated like fibro-cartilage and quite adherent to the bone, which by swelling and increased redness shows that it had partaken in the inflammation. When this inflammation has been acute, œdema is observed, but rarely redness, and, in early syphilitic periostitis, purulent effusion between the bone and periosteum is scarcely met with. Where there is redness and pus, the disease is primary in the bone, the specific inflammation terminating in caries, or necrosis, as in the soft node.

The diagnosis of periostitis is easy; pain in some part of a bone, worse at night, with shrinking tenderness on pressure. From rheumatism it is readily distinguished by the fixity and seat of the pain, and the tenderness on pressing the bone. In rheumatism the disease usually manifests itself in the joints or synovial apparatus, and the pain is erratic. This erratic character is peculiar to rheumatism, as Chonul ascertained by an observation of 600 cases.

The following is an example of periostitis, as a

late symptom, though I believe the bone in this, as well as every case of periostitis, to be simultaneously affected. There was no indication from swelling that it was so.

Periostitis of Sternum, Femur, and Ossa Ilii.—Case taken by Mr. Frazer.—Roger Quinan, aged 26 years, admitted into No. 5 ward, September 8th, 1846, for syphilitic periostitis. On the centre of the sternum is a very tender spot, the size of a half crown: there is a similar spot, but rather more extensive, on the inner surface of the right femur, just above the condyle: also on the outer surface of the right os ilium, beginning about an inch from the anterior superior spine, and extending for three inches along the crest of the bone, and covering a space two inches wide. The inflammation of the periosteum is acute, the slightest pressure causing him to jump from one side of the bed to the other. The left os ilium is similarly affected, but not so severely. About four years before, he got a chancre on the dorsum of the glans. He had no treatment, and it continued sore for three or four months; it has left a depressed cicatrix. He never took any mercury, that he is aware of. The pains in the bones of the sternum and femur are of a year's duration, in the ilia of four months. He was dismissed cured at the end of three weeks (Sept. 30th), by the use of leeches to the ilia, followed by blisters and the

internal exhibition of the hydriodate of potash, five grains three times in the day, with infusion of sarsaparilla.

2nd. The bony node is a tumour of some portion of the surface or substance of a bone, not usually very prominent, but with its margin diffused. Painful, particularly at night, the pain not generally acute, but of a dull, wearing out character. It is sometimes, however, very severe, when the inflammation is more acute, and the more rapid swelling of the bone puts the inflamed periosteum suddenly on the stretch. The node is very tender, and in some acute cases the tenderness so extreme that the patient will scarcely endure the finger to be pointed at it. The enlargement arises from the effect of inflammation of the substance of the bone, thickening the lamellæ, and expanding the cells, as well as thickening the periosteum over it. Though the surface of a node may appear smooth and uniform, a careful tactile examination will discover small irregularities or depressions (see Plate), and a pathological investigation shows small hollows of different sizes, and a section exhibits the cancellæ at the seat of the disease to be much enlarged, and to contain a reddish serum. The syphilitic node more rarely exhibits the close, ivory-like structure of the idiopathic exostosis, from which it is further distinguished by its broad, diffused base. In the long,



*Enlargement of bone from
Syphilitic Osteitis.*

thin bones of the ulna, radius, or clavicle the whole substance and circumference of the bone at the part affected is engaged, constituting a partial hyperostosis and fusiform tumour of the bone. If a node is seen early, treatment will remove all traces of it. This is a fact important to be known, as when one occurs on the forehead the patient's dread of a permanent deformity may be allayed. In a policeman in No. 5 ward of the Richmond Hospital, a node in the centre of the forehead, the size of a chesnut, disappeared entirely. On the other hand, should a node be large, hard, and of long standing, the enlargement will be permanent. The clavicle, ulna, or front of tibia are not unfrequently found deformed from this cause. The bony node may occur as an early symptom, along with other secondary affections, as rashes or sore throats, but it is most common among the later manifestations of the disease. Periostitis and bony nodes are most frequently met with in the following parts of the Osseous system:—The clavicle, particularly the acromial end: spine of scapula: tibia, more commonly the lower half: the sternum: the ribs: the bones of the cranium: the ulna, sometimes the surface of the ulna, more commonly the whole substance of the bone: the dorsal surface of the metacarpal bones. It will be seen that these, the ordinary situations, are where the bones are most

superficial, and that it is rare to meet with nodes or periostitis in the fleshy part of the thigh, where the bone is well covered by muscle, the back of the tibia when covered by the gastrocnemii and solæi muscles, the humerus when covered by the deltoid; the part of the last bone most commonly affected by syphilis is where it is least covered, as at the insertion of the deltoid at the outer side about the centre. We meet with syphilitic osteitis and periostitis in the following situations also, but much less frequently, some very rarely indeed—viz., the upper or covered end of the radius; the trochanters; the patella, the spines of the dorsal vertebræ; the bridge of the nose or nasal bones; the edge and roof of the orbit; the tarsal bones; the bodies of the cervical vertebræ at the back of pharynx.

When osteitis and periostitis are superficial, as in the ordinary positions already pointed out, the diagnosis, as I have said, is easy—the nature and position of the pain, its being worse at night, the shrinking tenderness on pressure, and the tumefaction, when it exists, render it quite obvious. But when they occur in the less ordinary situations, it sometimes requires careful examination to detect the real nature of the disease. When over the patella or at the side of the articular ends of the condyles of the femur or the head of the tibia, a careless observer might think the knee itself was

engaged, and take a more serious view of the case. I lately saw a case also where the fifth rib in front was affected in a female with osteitis and periostitis, and the disease was so masked by the sympathetic irritation of the adjacent breast, that it required a careful examination before the integrity of the mammary gland and the real nature of the disease was ascertained. A right diagnosis, followed by a blister and the hydriodate of potash and sarsaparilla, effectually relieved the pain. Osteitis and periostitis of the spines of the vertebræ are so like spinal irritation and neuralgia, that it is only by much care in the examination of the local derangement and the concomitant symptoms, with the history, that accurate induction is obtained. A still more important and interesting locality is where the bodies of the vertebræ in the pharynx are the seats of osteitis and periostitis. Another situation which is not unusual, and where it might lead to mistake, is the trochanter major of the femur. It may be distinguished from hip disease by the absence of the fulness of the groin which is observable in hip disease, whether from synovitis, or ulcer of the cartilages—the two forms observable in adults—by the greater freedom of motion and the absence of pain on moving the thigh—and on pressure or percussion of the foot, these leading distinctions will be sufficient. It is more likely to be con-

founded with sciatica, as the pain and irritation are apt to extend from the inflamed trochanter to the nerve in its vicinity, and down the course of the nerve to a certain extent. The following case is an example.

An office-keeper in the Poor Law Office came to me in September, 1862, on account of pain in the left hip, and extending upwards and downwards. It had been mistaken for sciatica, and treated accordingly, without any good result; he had suffered from the pain for several months. It was worse at night, and caused slight lameness. On careful examination, and from the history, I came to the conclusion that it was syphilitic osteitis and periostitis of the great trochanter. Not only was there an absence of the signs of disease in the joint, or of the sciatica nerve being engaged, but there was an obvious tumefaction of the trochanter, and it was exquisitely tender on pressure. By blistering, and the use of the hydriodate of potash, and of the bichloride of mercury in small doses, he got very nearly well; but he had a severe relapse. I therefore cut down to the bone, dividing a thickened and indurated periosteum; this was followed by complete relief. I have seen him during the last year, and he has had no return.

Osteitis and periostitis are very common in the ribs, and might, from the seat of pain and the

impeded full respiration, and catch in the breathing, be mistaken for pleuritis, acute or chronic, according to the severity of the pain. Such an error should be rare, as the shrinking tenderness over the rib, the tumefaction and the absence of respiratory indications should be sufficient for a correct diagnosis. Many years ago, an officer was sent home invalided from India, for a most obstinate pain in the left side, about the 8th rib, with more or less dyspnœa and deranged health. It had been taken for chronic pleurisy, and in the beginning there might perhaps have been some difficulty in the case, but when I saw him the diagnosis was easy—the 7th and 8th ribs laterally were enlarged, so as to touch each other, and form a tumour, which was tender on pressure and painful at night, a case in fact of syphilitic osteitis and periostitis of the two ribs.

LECTURE II.

In the Cervical Vertebrae.

OSTEITIS of the cervical vertebræ is a very serious affection, the tumefaction of the front of the bodies projecting into the throat, causing difficult swallowing, not only by the mechanical obstacle of its bulk, but by its affecting the movements of the pharyngeal constrictors, and impeding the action of deglutition. Any attempt to swallow hastily a morsel of meat, or other compact mass, is frequently attended with symptoms of impending suffocation. In one case the patient was often obliged to have the back struck, to help him to get the morsel up again. In all these cases they are obliged to swallow even smaller morsels cautiously and slowly. The pain is usually severe, and increased on motion, so that the neck is instinctively kept fixed, giving a peculiar appearance. From the articulating surfaces becoming implicated, the motions are at first stiff, and finally locked in many instances, ankylosis having ensued. Movements are sometimes attended with a crackling noise. From the impeded painful

motion, and the nocturnal exacerbation of suffering, with the difficult deglutition, this is a very distressing form of syphilitic disease of the bones, but further complications render it still more to be dreaded: the increase of the vertebræ in bulk encroaches on the cavity of the spine, and compresses the spinal marrow; it also diminishes the openings at the side for the exit of the nerves, and thus in both ways induces various forms of paralysis of motion or sensation, these paralytic affections offering a perplexing variety of symptoms. I have also seen the node in the pharynx attended with suppuration and a train of urgent dangerous throat complications, and great pain and distress. From this sketch it will appear how truly formidable the disease is in this situation; I may further elucidate it by a few cases.

Osteitis and Periostitis of the Cervical Vertebrae, with bony Tumour in the Pharynx.—William M'Cann, ætat. 28, admitted into the Richmond Hospital, November, 1849. The right testicle three times its natural size, egg-shaped, smooth, hard, and elastic; no distinction between the body and the epididymis, no water in the tunica vaginalis (simple syphilitic sarcocele), chord thickened. No pain or tenderness of the testicle, but severe pain up the right iliac fossa to the lumbar region. His chief complaint, however, is of very severe pain in the back of the

neck, so bad at night that he cannot sleep. He keeps the head quite fixed, as motion of the neck gives great pain. He has difficulty in swallowing, with a scalding feel in the throat. On examination, a bony tumour is felt at the back of the pharynx, below the level of the tongue, about the body of the 4th vertebra. Pain radiates from this to all his bones; it comes about 5 or 6 o'clock in the evening, and becomes most intense at 12 o'clock. Four years before, he contracted a chancre which was four months in healing, though he was salivated and got hydriodate of potash and sarsaparilla. He soon after got pains in the bones and nodes on the shins, which were cured by hydriodate of potash; they returned in a few weeks, but yielded to the same treatment. About three or four months since, the bones again became painful, with enlargement of the testicle. It is only a fortnight since that his swallowing became affected with pain and immobility in the neck. He was put under mercurial inunction to full salivation, when all pain left the throat, and all difficulty of swallowing. The testicle softened and became less, the body soft and distinguishable from the epididymis.

At the end of twenty-one days he was discharged; the testicle nearly its natural size, the induration not quite gone from the epididymis. No uneasiness in the throat or difficulty of swallowing: the tumour gone.

Osteitis and Periostitis of the left Transverse Processes, and left Side of the Bodies of the 2nd, 3rd, and 4th Cervical Vertebrae, with Paralytic Symptoms.—John Simmons, aged 24, a tailor, of intemperate habits, admitted for pain and stiffness of the neck, October 28, 1850. Any attempt at motion causes severe pain at the back and left side of the neck, shooting up into the head. The pain becomes so severe at night as to keep him from sleep, and this pain is independent of motion, and is of a different character. He swallows with difficulty, and the attempt to get down the morsel sometimes nearly chokes him. He has dyspnœa, with a catch in his breath, most likely from three ribs on the left side being affected with osteitis and periostitis. Examination of the seat of the pain at the back of the neck shows a tumefaction of bony hardness at the left side, the transverse processes of the second and third cervical vertebrae being considerably hypertrophied. Inside the throat, at the back of the pharynx, a fulness is perceived, and the left side is tender on pressure, but no distinct tumour can be seen or felt in the pharynx. The upper part of the tibia for three or four inches below the tubercle is enlarged; the enlargement is of the whole substance of the bone. It was painful twelve months ago, but is not so now. There is want of appetite, and considerable emaciation. About seven years ago he

contracted a chancre followed by two buboes, eruptions on the skin, sore throat, iritis, and pains in the bones. Two and a half years since, he had three soft nodes on the head, which where opened, became ulcers, and healed, with depressions in the cranium. He has taken little mercury, and been chiefly treated with hydriodate of potash. The stiffness and pain in the neck came on six months ago, but only latterly swallowing has become difficult. Hydriodate of potash has failed to relieve him. The occiput was shaved, and a blister applied over the swelling and along the spine, and he was given four grains of hydrargyrum cum cretâ three times a day. Under this treatment he improved considerably, pain and tenderness over the tumor of the vertebrae nearly gone, the motions of the head freer and without pain, and he could swallow easier. He slept at night, and the sweatings ceased. The mouth was made slightly sore. The improvement was so decided that he left the Hospital after having stayed in it between three and four weeks, being desired to attend at the Hospital twice a week, and to take the twelfth of a grain of the oxymuriate of mercury; for though he had neither pain nor difficult swallowing, the tumour, though less, was still there. He neglected to do what he was bid, and after an interval of about three months he returned to the Hospital. The long swelling of the vertebrae is increased,

particularly in the transverse direction, and the power of lateral motion nearly gone, but some in an antero-posterior direction. He carries his head in a peculiar stiff manner, evidently guarding against the pain caused by motion, and any movement is attended with an audible crackling sound. The swallowing is again very bad, and a bony tumour can be felt at the back of the pharynx, about the level of the base of the tongue. But he has a new group of symptoms, from derangement of the spinal nerves, both the brachial and the cervical plexus, caused no doubt by the narrowing of the openings by which they leave the spine, from enlargement of the vertebrae. They become thus exposed to injurious compression, and paralysis is the result. He now for instance has lost a great deal of the power of the arms, which he keeps in a flexed position, and is unable to straighten them. He cannot raise the arm at right angles with the body; and no matter what position the hand is held in, when let loose it falls prone and helpless, as in painters' paralysis. He has a general feeling of numbness of the skin over the whole body except the face, and a sense of tightness and constriction of the left side of the chest particularly, so that he cannot draw a full breath. He has weakness of the lower limbs, especially the knees, and when walking down the ward, his limbs crossed suddenly and he fell. When he attempts to inspire fully, the

chest is seen to expand, but it is evident that there is no action of the diaphragm, which the hollow state of the abdomen and its immobility show does not descend. As the third and fourth cervical are chiefly engaged by the osteitis, and the phrenic nerve comes out between them, this nerve is compressed and the diaphragm consequently paralyzed. He complains of burning sensations down his spine and along the arms. He is much emaciated; pulse slow and weak.

After having been put under various treatment, mercurial and hydriodate of potash, with repeated blistering, the amendment was very trifling, and he left the Hospital very little better of the paralysis, though he suffered much less pain and could swallow better.

In the next cases the osteitis of the bodies of the vertebræ terminated in pharyngeal abscesses.

W. M., who had suffered for years from soft nodes, with exfoliation of the bones, sore throat, and ulceration of the larynx, evidenced by dyspnœa, loss of voice, cough, and paroxysms of suffocation, which yielded to treatment, came to me saying that he had a lump in the throat, by which he had been twice nearly choked in his office. The attack was so severe that he thought he would die. I saw at the back of the pharynx, and extending below the level of the tongue, a prominent tumour which felt soft

and fluctuating to the finger. I, therefore, with a narrow guarded bistoury punctured the tumour (keeping the tongue well down with a spatula), and thick matter flowed out. I then passed a probe-pointed bistoury into the opening, and enlarged it freely; the end of the bistoury came in contact with hard rough bone. There escaped about half an ounce of thick matter with a little blood. I saw him a few days after, much better, the choking feel had gone, and he could swallow better. I could see at the back of the pharynx an oval hole the size of a shilling, brown at the bottom, which I thought was bone. He looks pale, and complains of his left shoulder, where I found a red soft node over the acromial end of the clavicle. I opened it, and some matter was discharged, with relief. He sweats at night. I put him on hydriodate of potash, and in three weeks he was nearly well.

I saw another gentleman with an abscess at the back of the pharynx. He would not let Mr. Cusack open it, but it burst of itself, with relief to the pain and choking feel. He had soft nodes on the scapula, and many syphilitic ulcers covered with rupia over the body. He would take no medicine.

About six years ago a man of the name of Martin M'Kay, a fruit-seller, came to the hospital, suffering dreadful pain in the back of the neck and shooting down the arms; the least motion increased the pain,

as did exercise over uneven or rough ground, or the motion of a vehicle. There was swelling and tenderness of the cervical vertebræ at the upper part of the spine. He kept his head fixed on the neck. Partly from the difficulty of lying in any easy position, and partly from increased pain, he slept badly at night. He had been ill with this pain for fourteen weeks, and at different periods previously had suffered from various forms of secondary and tertiary symptoms. By blisters and hydriodate of potash in decoction of sarsaparilla, he got so well that he left hospital at the end of three months. After two months he came back suffering somewhat from the pain, but chiefly from a new symptom, difficulty in swallowing, and a sense of choking. I found an abscess at the back of the pharynx, which I opened. This afforded immediate relief, and after a proper course of treatment he completely recovered, and when I saw him a few days ago there was no trace of his former complaint, and the motions of the head and neck perfect.

When the bones of the cranium are the seat of the disease, the brain itself becomes implicated by the swelling of the bone and the inflammation extending to its membranes. Some years ago a gentleman consulted me for syphilitic pains of the head, worse at night, but never absent, with swelling in different parts of the cranium, and great tenderness. But his chief complaint was of drowsiness; if he


was still for any time he would fall asleep. When hunting, which pursuit he followed up to the time I saw him, the excitement kept him awake, but riding quietly to cover he would get so sleepy as almost to fall from his horse. He got well under treatment, and though he occasionally suffers from pain, he has never been so ill since.

A barrister came up from circuit to see me. I had treated him from time to time for syphilitic osteitis and periostitis of the cranium. While in the country he had suffered a good deal from pains in the head, and drowsiness; the last so excessive that the day before I saw him he had fallen asleep in court and had been roused up with difficulty: this so frightened him that he came up to town the next day. I cured him, and he followed his extensive business at the bar very well for a year. At the end of that time he went down to the country to canvass for an approaching election. Though he had been particularly cautioned against drinking, on this occasion he thought it necessary, to forward the purpose of the election, to drink with several of the electors. This brought on severe pains in the head, and he returned to town very ill. He left a note in the evening for me to see him the next morning, but he had a fit in the night, in which he died. The drowsiness, almost amounting to coma, in these cases, is no doubt from the pressure of the tumefied

bone on the brain (see Plate 2). The experiment of Sir Astley Cooper is conclusive. After having removed a portion of the cranium of a large dog with the trephine, he pressed firmly with his finger, when the dog became comatose and fell. On removing the finger he got up, turned round two or three times from giddiness, and walked away. The amount of pressure from a node on the cranium is no doubt different according to the state of the circulation in the inflamed bone and its membrane, and of the brain itself, hence the injurious effects of stimulants and intemperance.

A very serious complication from the effects of the pressure on the brain from osteitis and periostitis of the cranium, and possibly of the irritation ensuing, is epilepsy. I have never met with it as a secondary or early symptom, but always as a late effect of the disease.

A young man, assistant-surgeon in the artillery, consulted me on account of epileptic fits. I traced them to osteitis and periostitis of the cranium, marked by swelling, pain, and tenderness of the bone, the syphilitic origin some years antecedent. He had been treated with the ordinary remedies for epilepsy by another practitioner, who had not recognised its real origin. Under proper treatment he recovered completely, and during the eight years which have since elapsed, he has had no return.



Thickened Parietal Bone.

Very lately I saw, in consultation with Dr. Hawkesley, of London, a case of a gentleman who had had syphilis in a bad form, both secondary and tertiary, who three weeks previously had three epileptic fits during the night. These had been preceded by pain in the forepart of the cranium, near the forehead, on the left side. There was shrinking tenderness and some swelling of the bone over the seat of the pain. In the course of many years I have seen many similar cases, and in every instance by prudence on the part of the patient and proper treatment they have terminated favourably. In a man of the name of Horrigan, in No. 2 ward, with thickened frontal bone on the left side, five attacks of epilepsy have occurred in the last few months. I have already mentioned where the intemperance of the patient led to a fatal result. It should be borne in mind that epilepsy occurs also from the presence of the yellow tertiary tubercle (the gummata of the French) in the dura mater. Such cases are extremely rare (I have only seen one), and I should think would be nearly always fatal. They may be surmised to be the cause of the epilepsy, where these tubercles exist in other parts of the body, and where the signs of disease of the cranium are absent. In the only case I have seen, the tubercle was the size of a small nut, yellow, and imbedded in the substance of the dura mater at

the upper part near the falx. There was turbid serous effusion into the arachnoid cavity. His intellect had been much affected, stupid, dull, and the memory gone, a dull pain in the head. The convulsions only occurred a short time previous to death.

Paralysis is also an occasional result of osteitis of the cranium. A waiter of the name of Thomas Kelly was admitted into the Richmond Hospital many years ago, with total want of power from the shoulder down to the elbow of the left arm; he had the power of moving the forearm on the elbow, but all motion was lost in the thumb. He had also lost the power of the right wrist and hand, and had difficulty in raising the hand to the back of the head, from weakness of the elbow joint. Five years before he had contracted the primary affection; three years before admission he first had nodes on the head, one on the left side of the forehead, and two at the back of the head. They were hard and painful, and he could not bear to wear his hat; and he had headache. He would get cured by hydriodate of potash for a time; but from drinking hard and neglecting to persevere in the treatment, he had frequent relapses. At last, after having had this affection for two years, and after a heavy drinking, the paralysis began in his right thumb; a month after, he lost the power of the other

thumb. Some months after, he found on extending the right hand he could not extend the middle finger, and shortly afterwards he could not lift heavy dishes, or finally raise his hand to his head. He had no paralysis of sensation, but felt darts of pain down the arms, and they became very much wasted.

No treatment had the least effect on the disease.

LECTURE III.

In the Orbit.

In the Orbit.—When osteitis and periostitis occur in the orbit, particularly in the orbital plate of the frontal bone, the relation of the part to the brain above, and the eye below, causes peculiarities in the symptoms which deserve attention. First: the case may come to you when the bone and periosteum are inflamed, but with little swelling. The patient complains of more or less pain in the orbit and eyebrow, which pain is little felt during the day, but at night there is a regular exacerbation, the pain then becoming severe, preventing sleep, and only going off towards morning. It might, under these circumstances, be mistaken for a remittent neuralgia or brow-ague, as it is called. For though the paroxysm of pain in the latter is ordinarily about noon, or in the morning, yet in some rare cases it takes place in the evening. A mistake of this kind would probably lead to the use of quinine, not only with no benefit, but so far injurious by delaying the use of really efficacious remedies. A simple means of avoiding such an error is to put the finger well

under the eyebrow and press firmly on the roof of the orbit; the shrinking tenderness of periostitis would at once declare the nature of the disease.

Secondly: there may be such an amount of swelling of the bone and periosteum, and effusion between them, and into the adjacent parts, as to cause tumefaction of the eyelids, particularly of the upper, and even displacement of the eye, downwards, forwards, and outwards, or inwards, according to the position of the tumour. The diagnosis then might appear to be simple, but the following case will show that it is not always so:—

Mary Falkner,¹ aged 33, florid complexion, married, and has had three children, the first two alive and healthy, the last a miscarriage at seven months, came to me at the South-eastern Dispensary when I was surgeon to that Institution, complaining of great pain in the left eye, and side of the head, with impaired vision. A considerable protrusion of the eyeball was at once observable; the eyelids, especially the upper, were swollen and puffy-looking, filling up the usual depression beneath the eyebrow, of a dull red colour, streaked with veins. The eyeball presented no marks of inflammation, a few tortuous veins being alone seen at its upper and inner part. The iris was of a greenish hue; the pupil

¹ Dublin Medical Journal, 1836.

natural as to size, but not shape, being oval from side to side, and at the upper and back part a bright green spot, of irregular shape and metallic lustre, was very distinct. The pain complained of was most intense, referred to the eyeball, but darting into the head, the whole left side of which was affected: worse at night, and depriving her of sleep. It was aggravated by the least motion of the body or of the eye, and by lying on that side. There is also a distressing feel of sand in the eye, probably produced by the friction of the tense eyelids over the protruded eyeball. Sight is much impaired, objects appearing misty and indistinct, and on looking down double *muscæ volitantes* are constantly before the eye. She is subject to giddiness and lightness of the head: pulse quick and full, tongue furred. Three months ago she miscarried, and supposes she got cold; the eye became painful and the eyelids red and swollen. Since then the pain has gradually increased, and vision equally diminished.

At first sight I was inclined to set it down as an incipient case of fungus hæmatodes, and though usually the first approaches of that disease are not marked by such pain, yet even in this respect it bears a remarkable resemblance to some of the cases related by Mr. Wardrop,¹ and in the appear-

¹ Wardrop on Fungus Hæmatodes, p. 44.

ance of the eye itself, which was precisely what he describes, and what I had myself previously seen. But the woman's florid complexion and healthy appearance, and the vision still continuing, though impaired, led me to doubt the soundness of this opinion. The next most obvious things were, the presence of matter, or some tumour in the orbit, but the most careful examination failed to detect either. As the symptoms were such as would at least warrant the conclusion that some of the tissues of the part were inflamed, I resolved, though in much doubt, to try the effect of antiphlogistic treatment. But no benefit followed. Sir P. Crampton, who saw her, would give no decided opinion as to the nature of the case, but his prognosis was most unfavourable. He recommended the trial of small doses of the oxymuriate of mercury: but the stomach was so irritable that this medicine could not be borne, it was given up: and after a little time I got her admitted into the Meath Hospital. The prominence of the eye was now so much increased, that it had the appearance of being larger than the other, and the eyelids could not be completely closed; the protrusion was in the direction downwards and outwards. The pupil, dilated a few days before by the extract of belladonna, has never since returned to its natural size, but now appears prevented from doing so by the lens being pushed

against it; it had still the same oval form; the lower edge of the iris was turned in; the metallic spot was much more forward, and now seemed to occupy the whole of the pupil, giving it a greenish and rather opal look; a small brown waving line, like a vessel, was seen crossing it. She got no relief from the pain, night or day, and though mitigated for a short time by leeching, it soon returned worse than ever; the stomach, too, became so irritable that nothing would stay on it, and the vision was reduced to distinguishing dark objects between her and the light. Though the irritability of the stomach was allayed by the application of a blister, the other symptoms became worse, in spite of a variety of treatment, and she left the hospital hopeless of getting any relief. Although different views were taken of the case by the experienced surgeons of that institution, yet the general impression was, that it was decidedly malignant—an opinion, after the description I have just given, that was certainly most reasonable; and I am inclined to believe that, had not the extent and severity of the pain in the head referred to the inside, intimated the likelihood of the disease being deepseated, if not to the extent of engaging the brain, the question of excision of the eye would have been seriously considered, which the woman from her suffering would have consented to. It was about a week after she left the hospital

that I first detected what the disease really was. On carefully examining the eye, I pressed hard on the orbit, and so much pain was given, that the existence of periostitis in this situation instantly struck me; and further examination showed the whole upper and inner part of the orbit, as far as the swollen lid allowed me to examine, to be equally tender, leading to the conclusion that the disease extended still further back. An explanation of the phenomena of the case became easy; the inflammation of the periosteum, and the consequent effusion between it and the bone, fully accounted for the pain, swelling, protrusion of the eye, &c. ; and she now, for the first time, confessed that she had been disordered by her husband eight years previously, and had taken mercury; but shortly after, an eruption with (apparently) iritis had showed itself, and subsequently sore throat, and occasionally for the last few years pains in the bones. The disease being understood, the treatment became obvious: she was put under the influence of mercury, and kept so for six weeks, with the use of the decoction of sarsaparilla. She had then lost all pain, and had regained her health and spirits. The eye had nearly returned back into the orbit, the swelling had left the lids, and vision was sensibly improved. Nine months after, there was no difference between the two eyes, the sight tolerably good, though still

misty, and she had experienced no pain during that time. The osteitis of the orbital plate of the frontal bone, besides causing the symptoms enumerated, swelled lid, displacement of the eyeball, &c., may give rise to more serious evidences of the extension of the disease of the bone to the dura mater above it, and finally to the brain itself.

Mary Williams, ætat. 27, a delicate-looking woman, has paralysis of the left upper eyelid, complete ptosis, with some pain over the left side of forehead, extending occasionally over the whole head. Under the edge of the orbit, at the inner side, a small swelling is perceptible to the touch, and the finger pressed on it and deeper along the roof of the orbit gives much pain, the shrinking tenderness of periostitis being very perceptible. There is some weakness of the right arm, scarcely amounting to paralysis, and also more decidedly of the left leg, which prevents her walking properly. A slight pain in the right shoulder. There is a depressed cicatrix over the right side of the forehead where, she says, a swelling formed, and was opened and white matter came out: no other symptom.

Five years after she contracted syphilis, followed by eruptions, pains in the bones, and iritis; the effect of the last is apparent in a permanently oval state of the right pupil, and the sight impaired. She frequently took mercury.

September 11, 1844.—She was ordered three grains of blue pill and a quarter of a grain of iodine three times a day.

September 16.—She is better, being able to raise the eyelid a little, less tenderness under the edge of the orbit, and no pain in the head. She has taken ten of her pills. Rept. pil.

September 23.—The mouth became slightly sore, the pills therefore were discontinued, and ten grains of the hydriodate of potash in compound decoction of sarsaparilla given three times a day.

September 25.—She improved under this treatment, could raise the lid one-half, recovered the use of her limbs, and all pain left the head, and the tenderness was removed from the orbit, firm pressure on the affected spot causing no uneasiness. On close examination when the eye is opened, it appears on a lower plane, and a little more prominent, she sees dark things before her, and has double vision, one object above another.

October 25.—She was let out on pass, but did not return. There was still a little ptosis; in other respects much improved, as already reported: she came to the hospital to-day for re-admission, in consequence of a feeling of deadness and paralysis of the other or left arm and hand, and an inclination to stagger; she had some headache; and the ptosis still existed. She was ordered the one-twelfth of a

grain of the oxymuriate of mercury in a drachm of tincture of bark three times daily.

At the end of ten days, these symptoms were all gone except the ptosis, which was, however, greatly lessened; the lid still hung, but she had the power to nearly quite raise it. The eye less prominent, but still a little anterior to the plane of the other. She went out, being desired to continue her medicine some time longer.

A married woman sent for me to see her eyes. I found her with a shade over the left eye. When this was taken off, considerable tumefaction was seen in both upper and lower lids, but particularly of the upper, which so overhung the eye, that scarcely any of it could be seen. The tumefaction was pale red, and œdematous. She could not move the lid so as to open the eye, and it could only be slightly done by another person, when the eye appeared very little inflamed, but it was obviously pushed down by a swelling, which filled up the space below the orbital ridge: she had scarcely any sight with the eye, objects appearing black. Pressure on the orbital ridge, and for some extent about it on the forehead, gave pain, the œdematous swelling extending slightly so far, and below also a little on the cheek. There is a slight œdematous swelling of the right upper lid, and pressure under the orbital ridge gives pain. She suffered from pain

in the left side of the forehead, coming on at night.

Three years before, she had had phagedenic syphilitic ulcers on the labia, which were near a year in healing. Mercury had disagreed with her, in any form, and the disease had finally yielded to the hydriodate of potash. Since then at different times she has had periostitis over the tibiæ, the fingers, and at the back of the metacarpal bones; these had yielded to the same remedy, with blisters. It was clearly a case of periostitis and osteitis of the orbital ridge and roof of the orbit and neighbouring portion of the frontal bone, and that the effusion between the bone and periosteum and the adjacent cellular tissue of the roof of the orbit had caused the displacement downwards, and protrusion of the eye, and the œdema and redness of the eyelid. Hydriodate of potash failed in relieving her, and the symptoms got worse. A blister was applied to the left temple, and the sixteenth of a grain of the oxymuriate of mercury given three times a day.

Under this treatment gradual improvement took place. She could raise the eyelid sufficiently to distinguish objects, and the œdematous swelling so far disappeared that a well marked tumour could be distinguished under the eyebrow. This tumour was hard, but only tender on decided pressure, vision restored, and the other eye quite well. After a

time fluctuation became evident in the tumour. Under the same treatment, and friction of the swelling with mercurial ointment, it lessened materially, and the fluid was evidently absorbing fast. At this time she got cold and laryngitis; and Sir Philip Crampton, who saw her in my absence, put her on calomel till full salivation. This had a most marked effect on the tumour, which rapidly reduced to the size of a pea, but was soft and fluctuating.

After a short time it burst, and discharged thin matter, which it continued to do; the eye still rather below the level of the other eye. She went to the country, and was better of doing so, but shortly after her return I was asked to see her immediately, the note stating that she was out of her mind. I found her sitting with her head hanging down, and the expression of her face dull and heavy: she answered questions, but imperfectly and sluggishly, and then relapsed into a lethargic state. It appeared that she had been more or less in this condition for some days, occasionally raving. She put out her tongue when asked to do so. Pulse 76. With much difficulty I got her to bed; I then ordered calomel gr. ii., every third hour, and a blister to the forehead. The gums became affected, but with no change except for the worse; she went into complete coma, lying with her eyes open, but distorted downwards by the tumefaction under both orbital ridges, not much in

the right, occasional stertor, complete unconsciousness, and she passed under her. Pulse 68. A slight return to sensibility manifested itself, but the soft parts over the sacrum sloughed, exposing a dead portion of bone, and after a few days she expired, quite unconscious for some time previously.

With some difficulty I got permission to examine the head, but 43 hours after death, and as the weather (August) was intensely hot, the body was far gone in putrefaction. The brain was so far decomposed that little could be learnt from its examination, except that it appeared not to have been congested. The orbital plate of the left frontal bone was found rough and carious, the dura mater and arachnoid membrane corresponding to it both thickened and adherent at the affected portion.

One of the bad effects of caries of the orbital plate of the frontal bone is, that after the soft node bursts, a fistulous opening remains in the upper lid, with contraction, puckering, and adhesion to the carious bone. Ectropium results, the eye cannot be closed, and the constant exposure of the cornea induces opacity and blindness.

Denis M'Dermott, aged 20, a strumous-looking man. In the centre and upper part of the forehead, rather to the right side, is a large depression into which the end of the thumb could be admitted, and in which there is a fistulous opening, discharging

thick, yellow matter. But though large pieces of dead bone have been taken formerly from this place, the probe which passes freely could not detect any dead bone.

There is ectropium of the left upper eyelid, which is drawn up and adherent to the under part of the orbital arch about the centre. At this part is a fistulous opening covered with raised flabby granulations. The cornea, from constant exposure, is dull and hazy, and at its centre a small spot of ulceration. The pupil contracted, to exclude as much as possible the constant light—the sight of the eye is nearly gone. Four years ago he contracted a chancre on the corona glandis, followed by a bubo in the right groin. One year after, he got nodes on the shins, and in the seat of the present fistulous openings. The last suppurated, and were opened, and left fistulous openings. About seven weeks since, he had an attack of erysipelas of the head and face, with the formation of an abscess in the left upper lid; the contraction of the eyelid was much increased after this was opened.

I felt with a probe, and removed a piece of dead bone from under the eyebrow.

He greatly improved by the use of the hydriodate of potash and sarsaparilla, but the ectropium was much in the same state when he left the hospital, six weeks after admission.

Some years after, I saw this man in the poor-house: his health was good, and no disease of bone, but the ectropium was the same, and the cornea quite white and opaque.

In a very similar case the termination was fatal. A man had a soft node of the forehead on the left side, and also of the roof of the orbit. From the frontal bone, about two and a half inches above the eyebrow, a large loose exfoliated piece of bone had been removed. Previous to this he had suffered from epilepsy, but not afterwards. A fistulous opening existed beneath the eyebrow, communicating with carious bone at the roof of the orbit; ectropium was formed by the contraction of the upper lid. An operation was performed by the late Mr. Hutton to relieve this, by dividing the adhesions between the soft parts and bone, but a fortnight after the operation he had an epileptic fit in which he died.

On examination, the frontal bone round the opening through the cranium, formed by the removal of the loose piece of bone, shelved down to the dura mater, which was adherent at the edge. In the centre of the opening the brain was only covered by the dura mater and arachnoid—some concrete matter was found on these membranes at this situation, but no pus; they were a little more vascular than natural. A perforation led out through

the roof of the orbit and the opening of the frontal bone at the lower part. Round this opening of the orbital plate under the skull, the brain and its membranes were firmly adherent, and could not be separated. A few days before the fatal fit, he was low spirited and inclined to wander in his talk. I could multiply examples, but enough have been given, to show the serious effects on the organ of vision and on the brain by syphilitic disease of the orbital plate of the frontal bone.

LECTURE IV.

The Soft Node.

ANOTHER, and usually a late, form of syphilitic disease of the bone and periosteum is the Soft Node. A large hospital like this is rarely without a case of this affection, and at present I have in my wards three examples of soft node. A woman with one on the right parietal, and another in the centre of the frontal bone: a young man with one in the centre of the forehead: in the third case the soft node is situated at the lower end of the tibia, close to the ankle.

The soft node presents itself as a tumour on a bone, soft and fluctuating, of the colour of the integuments at first, but after a time becoming red. It appears in fact like an abscess over a bone. The contents in the early stage are thin, transparent serum, yellow, or reddish from being tinged with blood, or partly serous and partly of a cheesy consistence, rarely pure pus. Soft nodes may occur in any of the superficial bones, but above all, the

cranium, and next to that the sternum are the most frequent sites.

They vary in size from that of a chesnut to an ordinary apple, or even larger. There may be only one, or several: besides many on the cranium, there may at the same time be others on the sternum, clavicle, or ulna, &c. In some broken-down constitutions they are large, flat, and diffused over a wide space, as in the following case:—

Large Soft Nodes on the Sternum and Occiput.—Richard Quin, aged 32, admitted into the Richmond Hospital, January 28th, 1851. There is a soft node on the sternum, which occupies the whole surface of the bone, and extends beyond it on the left side. It is not prominent at any one particular part, but rather flat on the surface, the integuments slightly reddened, and fluctuation very distinct. Firm pressure causes him to start with pain, but when untouched the tumour causes him no uneasiness. If he coughs, however, draws a full breath, or makes any exertion, pain shoots from the node down the arms. His ribs are tender on pressure, in several places, but no swelling apparent. On the occipital bone, about the situation of the tuberosity, there is a prominent swelling, the size of a crofton apple, fluctuation distinct; and firm pressure at the circumference causes pain. He has patches of

scaly eruption in different parts of the body, and in the right groin below Poupart's ligament is a suppurating lymphatic gland the size of a small egg.

The soft node is the product of the syphilitic inflammation of the bone and periosteum, in strumous and broken-down constitutions. The effusion, such as I have described, which takes place between the periosteum and bone, causes the latter to die to the extent of the surface deprived of its periosteum, the necrosis being either superficial or deep. When the node opens, the necrosed bone which is exposed separates after a long time. When the node is cured without having opened, the effusion is absorbed, the granulating surface of the periosteum absorbs the layer of dead bone, and after having done so becomes adherent to the living bone, with which it had become approximated. This is well shown in Plate No. 4, taken from a preparation for which I am indebted to my friend Dr. Joseph Burne, surgeon to the South Dublin Union.

The part chiefly examined was the parietal bone. After the scalp was removed, there appeared a diffused tumour, only slightly elevated above the surrounding level; the general surface redder than natural, in patches, and uneven. This swollen part was softer to the feel. When an incision was made

down to the bone, and the periosteum turned back, a layer of soft white substance appeared, of a consistence between that of curdy strumous matter and lymph, which was between the bone and periosteum, and adhered to the latter. The periosteum was thickened, red, and pulpy, and when the matter was wiped off, and in places where this curdy matter did not exist, the red granular periosteum lay on the bone, the surface of which was absorbed, presenting a worm-eaten appearance. Where the periosteum was covered with the curdy effusion, the bone was quite white, as if dead. A section of the bone shewed it to be thicker, harder, and more condensed than ordinary bone, with scarcely an appearance of vascularity, the cancellated structure of the bone or diploe having disappeared, and been replaced by the condensed material already described.

In this case, the disease had been materially benefited by treatment, the woman having died of Bright's kidney before the cure of the cranium was completed. But the effusion between the periosteum and bone had been nearly absorbed, and the dead bone in process of removal by the granular surface of the periosteum, where the effusion had been entirely absorbed. In cases such as this, where the superficial dead bone has been absorbed, there will be a depression on the surface of the bone. This has given rise to Verchow's opinion, that there is a



syphilitic disease of the bone in which it is absorbed, and a depression results. I believe there is no need of such a division, but that it is simply a termination of the cured soft node. When the soft node opens, the discharge is not proportional to the size of the tumour, nor does the swelling subside usually to the same extent as an ordinary abscess that has opened. Where it is large and flat, with extensive necrosed bone beneath it, there may be many openings, forming a group of small ulcers leading down to dead bone.

John Paiden, aged 31, a labourer, has an extensive patch of ulceration on the centre of the forehead, consisting of many small ulcers, like lupoid ulcers, that lead down to carious and necrosed bone, which can be felt hard and rough by a probe passed into any of the openings. The whole frontal region is swollen and uneven, and in many places sore to the touch, and slightly redder than natural. At present he suffers little pain, but before the swelling broke he suffered severely. He has noise in his ears like a sea shell, rather deaf of left ear, some weakness of the limbs, and some numbness of the finger ends, particularly of the fore and middle fingers—he does not sleep well, and has frightful dreams. He has large patches of pustulo-crustaceous eruption on the right arm, back, left shoulder, left side of chest, and thighs. A dull,

red centre, rather scurfy, and a circumference of small ulcers covered with greenish scabs. Both testicles affected with syphilitic tubercles.

He got a phagedenic sore three years ago, which destroyed a portion of the glans. He took mercury to salivation, and the chancre healed after many weeks. He never took mercury since. He had secondary eruption and sore throat. The secondary pimples after a time took on their present form, slowly spreading from the centre, as they healed, to the circumference. He is uncertain when the testicles first got affected, but it is near two years since he first felt pain in the forehead. It broke, five weeks ago. With the exception of the tubercles in the testicles which were not quite absorbed, this man got entirely well of his other symptoms at the end of eleven weeks. There was no exfoliation of dead bone, but it appeared to me that it was absorbed by the granulations which sprung up from the carious surface of the inner table of the frontal bone, as it assumed healthy action under the treatment.

Where the termination is favourable the dead bone exfoliates, and leaves a granulating surface which cicatrizes with a depressed white fibrous cicatrix. The dead plate of the external table of the skull is often, after separation, still kept in its place by atmospheric pressure, or by the adhesion

and dovetailing of the granulations from the surface of the inner table. I have seen also, as in the case of Paiden, just quoted, and many others, granulations piercing the outer table through at different points by absorption, and increasing, so that at length the intermediate bone is removed by them.

In the next case the greater part of the necrosed bone was removed by the absorbing action of large granulations.

John Ryan, aged 28, a painter; has been a hard drinker. About nine years ago, he contracted a sore on the penis, which he describes as having been soft, and a bubo formed and broke.

Two years after, he had a "brown" rash, followed by pains in the bones; the right shoulder and the left knee were slightly swollen. Fourteen months since a small red spot came in the centre of the forehead: there was no pain. It broke, and left an ulcer down to the bone.

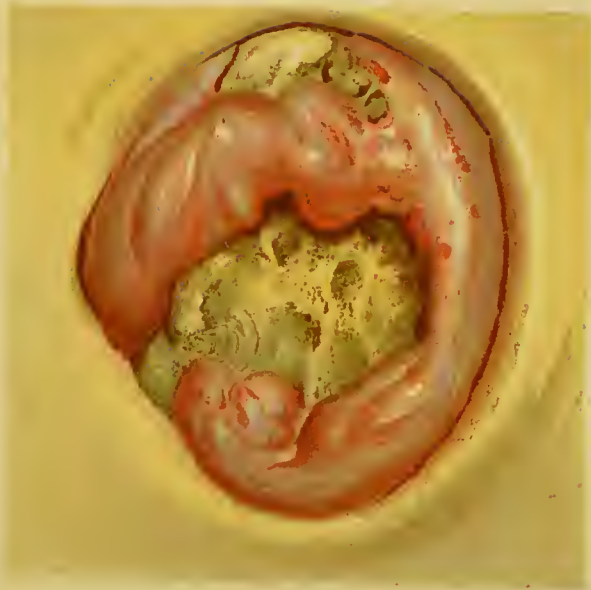At present there is an ulcer the size of a crown piece, of an irregular oval shape; at the bottom dead bone is exposed, of a pale brown colour, irregular, and worm-eaten on the surface. The bone is evidently thickened, as some of the prominent irregularities are on a level with the surface of the skin. Inside the margin of the ulcer are large prominent masses of granulation, of a red colour. Wherever these are situated the bone is absorbed,

according to the size of the granulation. Round the ulcer the forehead is swollen and shining, and has a soft, boggy feel, and on pressure matter is expressed from beneath the edge of the ulcer, and it is tender.

He sweats a little, but his general health is good, though he looks rather pale and waxy. He has been six months in hospital, and the improvement is remarkable in his health. Some portions of the bone have exfoliated. Pulse 88.

He never since the commencement of the illness till his admission took mercury. His treatment has consisted, while in hospital, in good diet, fresh air, and the hydriodate of potash in tincture of quassia, or decoction of sarsaparilla, or small doses of oxymuriate of mercury in tincture of bark. After having been away from the hospital for the two or three months following, he returned, January 1, 1872, the dead bone still *in situ*, but evidently only connected to the adjacent parts by granulations, dovetailing into the irregular edges and depressions of the necrosed bone. I seized it with a forceps, and by a steady, strong pull removed the whole piece, with the exception of a small portion which broke off. The subjacent part, after its removal, was red and fleshy, and as if granulations had been pressed down. The rapidity of the cicatrization was remarkable, his general health good. Plate 3 exhibits

PLATE III



FORSTER & CO LITH, DUBLIN

the mass of bone, much thickened and irregular, in some places thin, in others thick and perforated, and worm-eaten by the granulations.

When a dead piece of the external table is only kept in its place by atmospheric pressure, or by the granulations, and is removeable from side to side, there is on the part of the surgeon a great temptation to prise it up and remove it. And yet this should be only done with great caution, as the inner table is in all probability eaten away, thin and weak, as we see in the skulls in museums, that have suffered from syphilitic disease. Ill-regulated force, therefore, might cause a fracture of the inner table, with injury to the brain.

In one case, where the dead piece of bone was about the size of a shilling, dry and exposed by the destruction of the softer parts, by the daily cautious application of strong nitric acid I softened and finally removed it entirely. In other cases I have not been so fortunate, the compact thickened bone apparently little influenced by the acid. I have used the strong sulphuric acid as recommended by Mr. Pollock of St. George's Hospital, with similar results. In a case of syphilitic necrosis of the sternum I had to resort to the following means of getting rid of the dead bone. The patient was a butcher, a strong young man, who had had a soft node on the middle of the sternum, ending in

necrosis. When I first saw him there was a hole in the sternum, through which the forefinger could be passed. This hole communicated with a cavity containing a mass of dead bone about the size of a chesnut, loose, and receiving an impulse from the action of the heart, one side of the cavity in which it was being formed by the right side of the pericardium. It had been in this condition many months, and was a source of distress to the young man, not from pain, but the uncleanness of the profuse discharge. He was, moreover, anxious to get married. Two methods might be adopted for his relief, either to enlarge the opening or to diminish the size of the piece of dead bone, till small enough to pass out of the opening in the sternum. I preferred the latter. I got a scissors forceps, made with the ends turned in, and sharp, meeting at a right angle, constituting a small pair of nippers. With this I cut away bit by bit till I got the piece out. In a few weeks the round hole had closed.

In the following case the dead bone was in a cavity at the lower end of the tibia, communicating with the ankle joint.

A young man of the name of John Reilly, who had been a cavalry soldier in India, and had drunk hard, now a groom, was admitted in October, 1870, into the Richmond Hospital, with tertiary syphilis. His appearance was unhealthy in the extreme, and


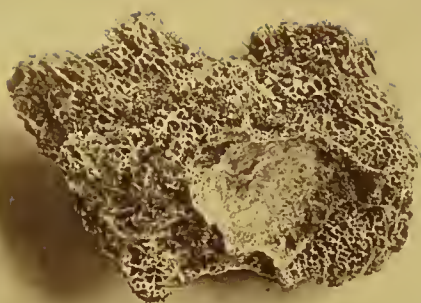
his voice was guttural. On the back of the pharynx was a large, irregular, excavated ulcer, of a foul greyish surface, and extending right across the pharynx and implicating the soft palate. His breath in consequence is very foul. There is a fetid discharge from the nose, the septum of which is perforated by an ulcer.

Both knees are painful and swollen, particularly the left, presenting all the signs of considerable effusion into the joint. He complained a good deal of pain and swelling of the right ankle joint, the pain most severe during the night. The lower end of the tibia next the joint was also swollen, painful, and very tender, with some effusion between the bone and periosteum, fluctuation very distinct. He has also tubercular syphilitic sarcocele of the right side, the testicle swollen, hard and nodulated. This group of symptoms showed as bad a form of syphilitic constitutional poisoning as possible. His history was, that in 1868 he had a hard chancre and suppurating buboes. For these he took mercury internally and used mercurial baths, till salivation. Some months after, he had pains in the bones, and sore throat, but no rash; the pains were cured in this hospital by me with hydriodate of potash. He continued well, with occasional pain only in the right ankle, till January, 1870, when the pains returned badly, with sore throat and sore nose. After

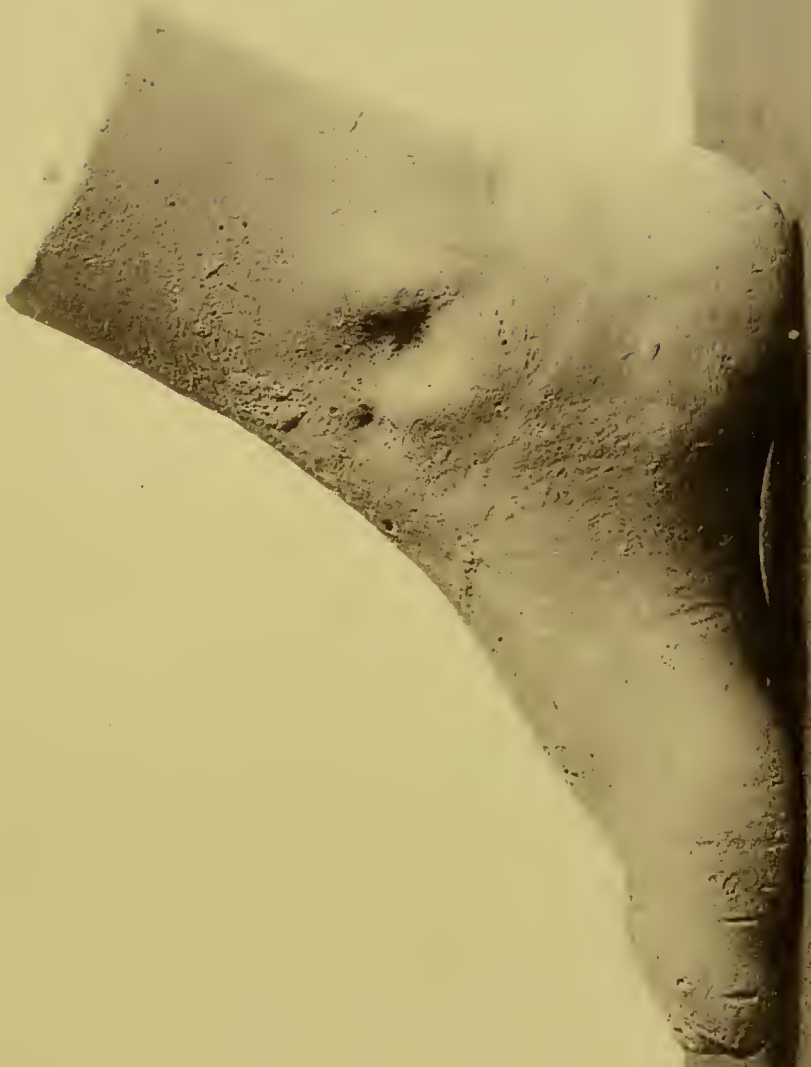
suffering many months, with temporary relief, he was admitted into the hospital eleven months ago.

Under treatment all his symptoms improved, except the pain and swelling of the lower end of the right tibia; this, rather better for a time, suddenly became much worse, the surface red, and fluctuation more obvious. The swelling of the ankle increased, with pain on motion. I therefore made an incision down to the bone and gave exit to some matter. Temporary relief followed, but only temporary, for the pain recommenced worse than ever, the ankle more swollen, the lower end of the tibia also, which broke by many openings, leading down to diseased bone. The distress was so great, and the constitutional symptoms ran so high, that had the origin of the disease not been syphilitic, I should have performed amputation of the lower part of the leg. As it was, I waited till the first violence of the sympathetic fever was subsiding, and as I felt loose bone, I made a free incision down to it, and removed the large mass of necrosed bone shown in the Plate 5. It will be seen that the lower end of it extended to the ankle joint.

The amendment was most striking, and though the ankle became ankylosed, he had a very good use of the foot. Some months after, I found a small hole where the bone had been removed, discharging a thin matter, but he could walk very well, and



*John Reidly. bits of dead bone
removed from lower end of Tibia.*



John Peilley, cast of ankle, some months after removal of dead bone.

there was considerable motion of the ankle joint. He was otherwise well, though he had led a dissipated life. See Plates 5 and 6.


Rose Dowling, ætat. 30, pale and sickly-looking, labouring under late syphilitic disease, from four years previous infection. In the centre of the forehead is a soft, red node, fluctuating in the middle, hard at the circumference, also an open node in the right parietal bone, occupying a large space, in which the integument had been ulcerated away, with dead bone at the bottom, crossed at the centre by a band of integument, which disappeared soon after by ulceration. This space is about the extent of a crown piece, with well-defined, round granular edge, the dead bone evidently extending for some distance under the margin. The bone itself of a light brown colour, dry, and ringing on percussion, rather worm-eaten in appearance on the surface. Some ulceration at the back of the pharynx, and a small perforating ulcer in the centre of the hard palate.

Under hydriodate of potash, with tincture of quassia, she regained in a remarkable manner her general health. The node of the forehead, though red, and the integuments thinned, disappeared, the ulcer of the palate closed, but there was little change in the open node—if anything rather larger; subsequently she had an abscess of the lachrymal

sac, which was, I think, consequent on obstruction of the lachrymal duct from thickening of the schneiderian membrane, of which she had symptoms. This was opened, and a small lachrymal fistula remained. The edges of the dead parietal bone subsequently became separated from the adjacent sound bone, and a rim of large granulations was evidently busy in the work of absorption. A hole also came through the lower part of the dead bone, and a large granulation filled the opening. The pulsation of an artery moved this granulation, but it disappeared after a time. Though nitric and sulphuric acids were alternately diligently applied, no essential impression was made on the bone. It was not till June 21st, 1872, a year and three months after I first saw her, that I succeeded in removing the bone. It was so hard that, though I had previously tried to gouge it away, the chisel made no impression on it, and the possible thinned condition of the inner table made me cautious of undue violence. The piece of dead bone now felt loose, and could be moved from side to side. I got an assistant to hold one edge of the bone steady with a forceps, while I lifted up and removed it with another. By this means I prevented the edge of the bone opposite to that I was raising being pressed against the subjacent parts. It came away without much force, and



Rose Dowling



*Rose Dowlings, Portions of
the dead bones removed.*

nearly entire, and the rapidity of healing after was most remarkable.

May 24, 1873.—She came to the hospital on account of some irritation in both eyelids. She was otherwise quite healthy, and had in her arms a healthy baby of two or three months old. Where the bone had been removed, there was a large depression, the bottom quite firm, formed by the inner table covered by a white, shining, fibrous membrane. See Plates 7 and 8.

When, as in some of these cases, a considerable ulcerative destruction of the soft parts leaves the dead portion of bone fully exposed, it is rarely black, usually of a light brown colour, dry, and resounding when struck with a hard or metallic substance. The necrosis may be confined to the external table, or both tables may be affected; and in this latter case, when the bone has separated and come away, the dura mater is exposed, and the pulsation of the brain perceptible. A man was admitted into the Richmond Hospital, not long ago, with syphilitic disease of the bones of the cranium. The original infection dated four years back, subsequent to which he had had rashes, sore throat, and pains in the bones. For these symptoms he was only once salivated. He had had soft nodes on the forehead, and at the back part of the parietal bone, about six months before. The nodes broke,

leaving an ulcer on the parietal bone, at the bottom of which dead bone could be felt, and in the centre of the forehead there was a deep red ulcer, from which the bone had exfoliated, and had left the dura mater quite exposed, and the pulsation of the brain strongly rising and falling. In aggravated cases, where extensive portions of the cranium are affected, particularly when both tables are necrosed, the termination may be fatal, either from the constitution sinking under the local complaint, or from the direct effects on the brain, inducing epilepsy and coma.

Such, then, are the principal forms and conditions under which you meet with the soft node, and such their usual terminations. In most museums may be seen specimens of syphilitic crania; but fearful as is their appearance, corroded, and perforated by ragged irregular holes, they yet convey but a faint idea of the state of the living sufferer who once bore them. Emaciated, feeble, worn out by sleepless nights, by sweats and diarrhœa, by hectic in its worst form, and with profuse fetid discharge rendering him loathsome to himself and to others. Too often racked by pains in the other bones of the body, or with the additional miseries of pharyngeal ulcerated throat, or of ulcer of the larynx, or many ulcers over the body—no state of human misery can be much greater.

LECTURE V.

The Yellow Tubercle.

ANOTHER form in which the periosteum and bone become affected by the syphilitic poison is that of the yellow tubercle, which the old authors called gumma. This yellow tubercle is one of the late or tertiary symptoms of syphilis, and has been found in various structures of the body, the subcutaneous cellular tissue, the fibrous membranes forming the fibrous fasciæ of the extremities, the periosteum itself, the dura mater, or in the substances of organs, of the muscles, of the glands, as the testicles, the liver and heart, in both which M. Ricord has found them; *it is supposed* to be present in the lungs, in the brain, and my friend and colleague Dr. M'Dowel found, in a hemiplegic patient who had other symptoms of syphilis, a yellow tubercle the size of a small bean in the centre of the spinal marrow. When the bones are affected by them, I believe the tubercle begins primarily in the periosteum, and secondarily affects the surface of the bones. The tumour, after gaining the size of an olive, or larger,

with unchanged integument, begins soon to redden, the skin to thin and ulcerate, disclosing a yellow shreddy or broken-down substance, which is the softened tubercle; the discharge is thin and scanty, mixed with shreddy portions of the tubercle; as the disease goes on unchecked, more of the integuments ulcerates, and some of the yellow mass of the tubercle comes away, leaving a foul-looking ulcer, with the surface of the bone engaged, dead and deprived of periosteum, or presenting a cavity more or less deep—the first most common in the cranium, the last in the bones of the extremities—the circumference of the ulcer dull red, the edges thin, undermined, and irregular. Sometimes these tumours are very large. A tailor came to me to-day (May 20, 1863), with a large node on the right parietal bone, fully the size of an apple, with a diffused base; the middle ulcerated to the size of a shilling, the ulcer circular, with thin, undermined, purple edges and margin, the centre of it occupied by the yellow substance of the tubercle. He had evidently had one on the inside and back of the alveolar process of the upper jaw, where there was a deep, granulating ulcer, encroaching on the neighbouring palate, and with a tooth in the centre of it, bared of alveolar process and rather loose—a good deal of dull, red tumefaction about it, speckled with small pustules. From the ulcer, he

says, a yellow substance like a core came away. He has considerable discharge from the nostrils, and it appears to me that the antrum is opened by this disease. There is an ulcer on the pubes at the root of the penis, from which also a yellow core came. This began with a round swelling, of small size, increasing, reddening, and finally ulcerating. It now looks as if healing. He is pale, has lost flesh, sweats at night, and suffers from periosteal pains of the tips of shoulders, and upper and lower extremities. The ulcerated tumour on the head is painful, particularly at night.

Eighteen months ago he got a running from the urethra, thin. After it got well, he had an abscess at the under side of the penis next the scrotum. Nothing was observed till four months ago, when the tubercles commenced on the side of the head and the pubes, and the inside of mouth became affected. In Glasgow he was ordered some powders which salivated him, but did him no good.

June 13, Saturday.—He was admitted into the Richmond Hospital three weeks ago: a wonderful improvement has taken place. His strength has returned, he has pulled up flesh, and his complexion has lost the pale yellow look. During this time he has been taking the decoction of sarsaparilla, with five grains of the hydriodate of potash three times

a day. Has had full diet, and been allowed to take walking exercise out of the hospital daily. I removed with the forceps and scissors the broken up yellow tubercle, and there is now a healthy red granular sore, in the centre a yellow piece of dead bone, which the granulations at its circumference are lessening daily by absorption.

The tooth was drawn, and the next day a piece of dead alveolar process (the centre of which contained the socket of the tooth) about the size of a marble. This was followed by great relief to the mouth.

Though the whole aspect of this disease is very threatening, and promises to be tedious, it is generally much less serious than it looks. Under proper treatment and the removal of the softened tubercle, the sore throws up healthy granulations, and cicatrization ensues, with a permanent, shining, white depressed cicatrix. It is very rare that there is not some other tertiary syphilitic symptom, pustulo-crustaceous eruption, bad form of ulcer at the back of the pharynx, glazed, indurated, fissured tongue, other affections of the bone and periosteum, and much derangement of the general health. If the case is seen early, when the tubercle of the periosteum is still pale or only slightly discoloured, it may almost certainly be cured by the iodide of potassium in decoction of sarsaparilla, infusion or

tincture of bark, or other appropriate vehicle, and by the local application of the strong tincture of iodine. When the tubercle has ulcerated, and the yellow substance of it is exposed, the sooner that is removed the better; it is an inorganic substance, which as a foreign body keeps up irritation. Sometimes it is so soft and loose that gentle traction with a forceps is sufficient; at other times it is best to hasten matters by an incision across the tumour, which may then be more readily removed: when there is much pain, or a neighbouring joint is in danger, this may be imperatively called for. The following case will be found a remarkable instance of the disease, and exhibits the good effect of the treatment recommended.

Alice Cooney, ætat. 28, a delicate-looking woman, admitted for a tumour of the left temple. It is large and prominent, but diffused at the base, extending from the upper part of the temporal region down to the zygomatic process of the malar bone. It is generally firm to the touch, but in some places there is an obscure feel of fluctuation. There are three fistulous-looking openings filled with a yellow strumous-looking exudation, and discharging in small quantity healthy-looking pus. The upper part of the tumour is of a dusky red colour. The globe of the eye is slightly pushed up and protruded, and a little out of the axis of vision. She

is only partially able to open her mouth, and the left cheek is thickened and pressed against the teeth. She complains of no pain or constitutional disturbance.

At first she attributed the tumour of the temple to a blow received twelve months before from her husband, three weeks after which the part began to swell. But she afterwards confessed that she had been diseased, and she showed another tumour on the tibia, about an inch below the tubercle, about the size of a marble, of a purplish colour, with a small opening on the top, of a yellow colour, and a little lower down in front of the tibia pain and shrinking tenderness, from periostitis.

She was put on the iodide of potassium, five grains three times a day in decoction of sarsaparilla, and the tumour covered with a dressing of diluted iodine ointment. After she had been in the hospital about seven weeks, though she was greatly improved, still the amendment appeared to me slow; and finding that a probe went tolerably freely in most directions through the tumour, I made a free incision through it, and when the bleeding had subsided found the interior of the swelling composed of a yellow substance, scarcely fibrous, with no sign of vascularity. Examined in the microscope by Dr. Frazer, it was found to be an unorganized material. I removed as much as I could at

the time, and subsequently as it became sufficiently loose I took away the entire, till there remained a deep hole down to the temporal bone, which however was covered with a soft substance, so that the bone itself was not felt. The yellow mass was evidently of tubercular character—most likely of the periosteum, and resting on the temporal bone, not unlike the tubercles in tubercular syphilitic sarcocele.

Two months after admission she miscarried of a dead child, three or four months old. After this her general health improved remarkably, and the tubercle on the leg and periostitis got well. The wound in the temple, two months afterwards, was reported to be free from all yellow tubercle, and to be granulating healthily: just at the anterior edge of the temporal muscle there was a round hole leading into the orbit, showing the perforation of the bone by the absorbing pressure of the yellow tubercle, and the consequent effusion into the orbit, and pushing the eye forwards, upwards, and a little out of the axis of vision. This opening was about the size of a bean, and a probe could be readily passed through it into the orbit: at the back of this hole the edge of the temporal muscle can be seen moving with the actions of the jaw. There is some œdema of the upper and lower eyelids.

April 25.—The opening gradually diminished

to the size of a pin-hole, and then altogether closed, the tumefaction of the temple disappeared, the eye returned to its natural position, and five months after admission she was dismissed cured. See Plates 9 and 10.

The next case shows the good effect of early treatment.

A Yellow Tubercle in the Periosteum of the Temporal Bone.—A gentleman was brought to me for consultation by Mr. Newland of Camden-street. He was a stout, florid man, his face very red and pimply, the effects of drinking too much punch. On the right temple was a flattish tumour, of the natural colour of the integuments, nodulated, deepseated under the temporal muscle, and as if fixed to the bone. It was of firm consistence, and interfered somewhat with the masticatory functions of the jaw. I looked upon it as a yellow tubercle of the periosteum, most likely of syphilitic origin. What confirms this is, that he says he had a very disagreeable *boil* on the chest, which kept discharging for many months. It had just healed, with a depressed irregular cicatrix into the sternum, the tubercle having most likely originated in the periosteum of that bone.

It was twenty years since he had had syphilis; from that time to this he had no symptoms of that disease.



Alice Cooney.



Alice Cooney.

I recommended five grains of the hydriodate of potash in decoction of bark three times a day, and the tumour to be painted with the strong tincture of iodine two or three times a week. Regular living.

Mr. Newland informed me that under this treatment the tumour entirely disappeared.

Tumour connected with the Metacarpal Bones of the Left Hand.—Catherine Flood, aged thirty-eight, a healthy looking woman—a widow who had had four dead children—she thinks in consequence of a hurt while carrying the first child, by lifting a heavy weight.

Eleven months ago, while washing and wringing heavy cloths, she perceived the left hand to swell, but without pain, and when she returned to lighter work the swelling decreased. Six weeks since, the swelling became larger and accompanied with pain, and she had to give up work. Has a tumour on the dorsum of the left hand from the wrist to the knuckles. It is prominent, nodulated, with a slightly livid, pink colour on the top. It seems to spring from the dorsum of the metacarpal bones of the fore, middle, and ring fingers—those of the thumb and little finger are not engaged. There is no tumefaction in the palm. A separate nodule can be felt between the metacarpal bones of the thumb and forefinger, soft, and obscurely fluctu-

ating. The nodule which is the highest part of the tumour has also a fluctuating feel. After being in hospital a few days the pink colour went off. The greater part of the tumour has a firm, elastic feel, like that of soft cartilage, with a firmly fixed base. She appears to be otherwise healthy. Pulse 84.

The arm was put on a splint: tincture of iodine was applied over the tumour, and she got five grains of the hydriodate of potash in decoction of sarsaparilla three times daily. This treatment was given in the belief that the disease was the yellow tubercle of the p̄riosteum of the metacarpal bones. It succeeded admirably, as a fortnight afterwards (July 1) the swelling was two-thirds less, smaller and harder. She had a dispute with the ward-maid and left the hospital. About the same time my late friend and colleague, Professor Smith, had a case of the same disease at the lower end of the inside of the humerus. A deepseated tumour fixed to the bone, elastic and with a pseudo-fluctuating feel; little pain. It increased slowly, became nodulated and more extensive, so as to assume an aspect of malignant disease. It became red on the summit, and a small hole formed and increased, the diameter of an inch; this disclosed the real nature of the tumour, a large yellow tubercle being seen, the tumour being composed of them.

Catherine Flood was re-admitted September 23rd; the hand rather worse than when she left, though not as bad as when first seen; livid in one part where the nodule was soft and most prominent. Under a similar treatment, continued for four or five weeks, she was nearly cured, when the same quarrelsome temper made her leave the hospital.

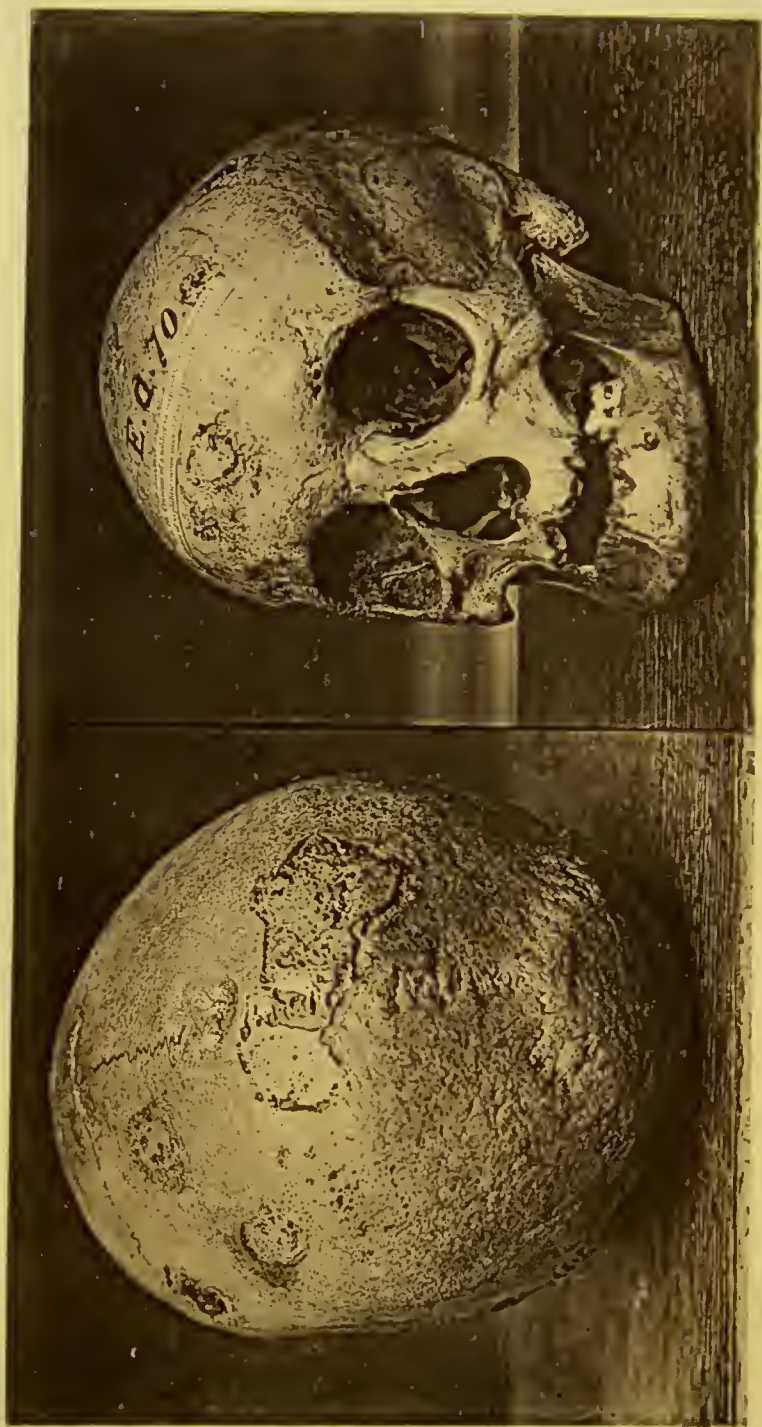October, 1859.—Came to the hospital with the hand much worse than it had yet appeared, ulcerated in one prominent place in the centre, where a yellow tubercular substance was apparent. A few days after admission a second tubercle over the metacarpal bone of the thumb ulcerated, exposing as in the other case the tough, yellow substance of the tubercle. The yellow substance was allowed to loose a little, and then seized with a forceps and extracted—the tubercle nearly entire in one case, and constituting a small oval yellow tumour cutting firm, the other more shreddy and in pieces. The ulcer in the back of the hand healed rapidly and is now just well—the other granulating from the bottom and will soon close. There is a third tubercle at the digital end of the metacarpal bone of the forefinger, red, tumid, and soft on the summit, apparently about to run the same ulcerated course as the others. At first I used no medicine, but for the last few days (October 31) she has been put

on the hydriodate of potash and decoction of sarsaparilla.

May, 1866.—She was admitted for a small, lupoid ulcer in the right calf, also with several subcutaneous tubercles on the thigh of the same side, and a few in other parts of the body—sallow and out of health, but not thin. The cicatrix of the former disease of the metacarpal bone was apparent, with a superficial depression on the surface of the bone. After a few weeks' treatment with the hydriodate of potash and sarsaparilla she got quite well and has continued so.

December 3, 1850.—A man came to the Dispensary of the Richmond Hospital with extensive necrosis of the frontal bone, which lay black at the bottom of a large irregular ulcer with overhanging edges. The dead bone was loose for about one-half, which I removed by gentle but firm traction with a forceps: beyond the ulceration extended a portion of the integuments of the cranium up towards the vertex, of a white, cicatrized appearance. On the parietal protuberance on the right side was an ulcer the size of a shilling, with a portion of the external plate of the skull dead and black.

Now the origin of this caries and necrosis is curious. It began with a small lump quite moveable, under the skin, from side to side, that is, a syphilitic subcutaneous tubercle. It broke, an ulcer



*Skulls showing superficial caries from
ulceration of the soft parts.*

formed, which spread and laid bare the frontal bone, which then became carious and necrosed. The syphilis was of old standing.

Dec. 4.—There is still another way in which the periosteum and bones are affected by the syphilitic poison. In bad constitutions, the secondary cutaneous tubercular or other eruptions are apt to run into ulceration; these ulcers are often deep, and when situated on the head especially they eat their way through the soft parts, including the pericranium or periosteum, down to the bone itself. If they are not attended to early, the destruction of the periosteum over the bone may lead to the death of the latter, according to the size and shape of the ulcer—or the ulcer may only very partially destroy the periosteum at the base of the ulcer, and the bone be only superficially and to a small extent destroyed—a kind of nibbling away, from caries of the surface. Where the ulcer has been deeper round the circumference, the destruction is in a circular or ringlike form, and hence the peculiar appearance of some of the skulls in our museums. There was a very good and characteristic specimen in Park-street Museum, now belonging to the Belfast College; and through the kindness of Dr. Cuming, who got photographs taken for me, I am enabled to exhibit them. See Plate 111.

When the case is seen sufficiently early, proper

treatment will lead to the healing of the ulcers without any exfoliation from necrosis, granulations springing from the base, and soon filling up the excavation. The following instance from my hospital case book will exhibit the nature of the disease before the bone is reached, and the effect of the treatment.

Thomas Kelly, ætat. 34, admitted 12th May, 1851, with the following symptoms: on the vertex are three deep ulcers, one the size of a shilling, well marked granular edge, the base formed by the pericranium of a yellowish grey colour, and soft, the other two ulcers smaller, but going also down to the pericranium. Sore throat, a small deep yellow ulcer in the anterior arch of the palate, not painful, but his speech is guttural. The ulcers on the head are dreadfully painful, particularly at night, from 6 o'clock in the evening to 2 o'clock in the morning.

Pain at night in the lower third of the tibia, where the bone and periosteum are thickened. There are a few tubercular spots scattered over his back and forehead, the size of split peas, elevated, and of a reddish brown colour. A small painful abscess over the right trochanter. The posterior cervical glands are enlarged to the size of a walnut.

He is a pawnbroker's clerk, and is a miserable looking little man, very depressed in mind, and rather deaf. Pulse 90, weak.

About five months since he contracted a sore at the junction of the penis with the pubes. The sore became large, and at the end of a week two buboes came, one in each groin. They were painted with tincture of iodine and they disappeared. The sore was much more troublesome, and did not heal until after the administration of mercury, and the application of sulphate of copper. At the end of two months he got sore throat, and the ulcers came on the head, covered with an elevated scab: also the pains in the bones: the abscess of trochanter about ten days ago.

He was brought under the influence of mercury by inunction, and directly the mouth became sore, a manifest improvement took place in all his symptoms, the ulcers on the head became cleaner, and granulations sprung up from their base. At the end of the month one of the ulcers on the head was well, the others cicatrizing. A week after, they were all healed up, and he was dismissed cured, and his general health excellent. He had taken hydriodate of potash for the last week, which he was desired to continue.

LECTURE VI.

Disease of Maxillary and Nasal Bones.

A VERY distressing form of syphilitic affection of the bone is the necrosis which attacks the upper and lower jaws. The upper maxilla I have found to be the most frequently engaged; more or less of the alveolus becomes dead, the teeth in the affected portion get loose, the gums swollen, red and spongy, and ulcerated next the teeth, and finally removed, leaving the dead bone bare. A horribly fetid discharge is constantly flowing; the breath is foul; mastication, deglutition, and speech are all interfered with, and the state of the patient, when the disease is extensive, most wretched and not without danger. The best treatment in such a case is to remove the loose teeth, and directly separation has taken place between the dead and living bone, to seize the portion of dead alveolus with a strong forceps, and remove it. After this, the swelling of the gums, the pain and irritation, and foul discharge stop, and should there be a large gap in the jaw, and the teeth wanting, after the part has healed, it

can be filled up by the work of the dentist. An actor of considerable merit consulted me for late symptoms of syphilis. Patches of pustulo-crustaceous eruption in various parts of the body, particularly on the temple and forehead; a syphilitic lupoid ulcer on the right nostril, which had partially destroyed the ala nasi; osteitis and periostitis of the sternum, scapulæ, &c., and necrosis of the right side of the middle of the upper jaw, including two teeth which were quite loose. He was pale, emaciated, and sweated in the night, which was restless. His mind was miserable on account of the destructive ulceration of the right side of the nose, and the dread of the teeth falling out, and thus being prevented from following his profession, his only means of support. By the exhibition of small doses of blue pill and extract of hyosciamus at bed time, and five grains of hydriodate of potash with tincture of bark, morning and midday, I stopped the spread of the ulcer on the nose and healed it, cured the pains in the bones and the pustulo-crustaceous eruption. His general health became excellent, and the necrosis of the upper jaw loose enough for removal.

On Saturday I took away the two teeth and a large portion of the upper jaw, leaving a gap which extended into the right maxillary sinus. On Monday the swelling of the gums had so far fallen that a

dentist took a cast of the gap, and thirty hours after he had a well-fitting vulcanized India-rubber plate with two teeth in his mouth. He soon after acted as well as ever. I have had many cases of a similar kind.

Sometimes large portions of the jaws, including many teeth, are thus destroyed. In the case of a woman of the name of Biddy Nolan, I took away nearly the whole of the upper part of the horizontal ramus of the lower jaw. This necrosis is generally quite independent of any local effect of mercury, as it does not occur particularly after salivation in the earlier stages, but is a later symptom, and an evidence of syphilis in a scrofulous constitution; the tertiary syphilitic osteitis terminating in necrosis, as the soft node does.

When the dead bone can be got at, a good deal of it may be removed with the cutting forceps, without waiting for the process of separation, as it is a great matter to free the mouth of dead bone as soon as possible.

But of all the forms of syphilitic disease of the osseous system, the caries and necrosis of the complicated bony structure of the nose is the worst, the most disfiguring, and the most loathsome. It begins with dull pain in the nose, an obstructed feel in the nostrils, a desire to frequently blow the nose, when scabs and a drop or two of blood come away. The

nose then becomes red and swollen, a constant fetid discharge flows from the nostrils, or back into the pharynx. In consequence of the caries destroying the bony, and finally the cartilaginous septum, the nose becomes flattened or falls in—pieces of dead bone come away, or after having caused by their presence terrible distress and irritation, separate and pass out through the anterior or posterior nostrils. Nature often tries to assist the expulsion of these dead bones by forming a hole, or sometimes two, in the hard palate, ulceration beginning on the floor of the nose above, laying bare the bone, which becomes carious to the extent of the ulceration, and finally is removed with a portion of the soft parts, constituting a hole through which the end of the forefinger can often be readily passed, and the dead bones of the nose find a more easy exit than by the flattened nostrils. The fœtor of the breath is most sickening and overcoming, rendering the existence of the patient almost unbearable—loathsome to himself and to others. I have seen the nasal bones, the septum, the box of the ethmoid bone—all come away in these cases: in one instance ulceration opened the centre of the nose externally, through which air came for a time. Sometimes a detached portion of dead bone gets back into the pharynx, and gives rise to symptoms of choking. As the bony structures are thickened and enlarged by the

inflammation, they fill up the cavities of the nostrils, and are of such a bulk as to be beyond getting through the natural openings, or those formed in the manner I have described, and the surgeon is obliged, by breaking up the diseased mass of bone, to render its exit possible, as was done in the case of James Carroll. The deformity from all this destructive disease is hideous and persistent: the nose flat and spread out, with a transverse depression across it, and the alæ nasi contorted, the nostrils contracted like two irregular slits. The bones of the nose suffer in another way, ulceration beginning in the soft parts, the alæ, the tip of the nose, or cartilaginous septum. Sometimes the bony septum and vomer alone are destroyed; very rarely the ethmoid bones. The mutilated nose is more or less destroyed, and the interior laid open. Nature, by curling in the remains of the soft parts at the side, tries to lessen the gaping hole, but the resulting deformity is very repulsive.

Destruction of the Bones of the Nose, the disease beginning in the soft parts. March 12, 1869, Ward 5.—James Carroll, house carpenter, ætat. 33, admitted with syphilis. His face presented a frightful spectacle of the ravages of the disease. The nose quite flat, the nasal bones and septum gone. The soft parts of the nose partially destroyed; the nostrils thrown into one gaping hole, another

ulcerated opening at the upper part leading into the cavity of the organ, and communicating on the right side with an irregular greenish ulcer, at the bottom of which was the dead nasal process of the upper maxillary bone. The cheeks on each side were indented with irregular cicatrices of former superficial ulceration, which scarred appearance extended up over the left side of the forehead. The whole of the affected portion of the face deep red. The left lower eyelid was drawn down by a cicatrix, and the right upper eyelid in the same way at its inner edge was drawn to the upper part of the nose. On looking into the throat, a portion of the right side of the uvula and soft palate have been destroyed, and present a white cicatrized appearance. In the hard palate are two openings, one which would admit the forefinger, the other smaller; through those the dark brown dead bone which fills the cavity of the nose can be seen. The left testicle rather less than the natural size, with a hard feel, as of a tubercle, at the lower and front part of the body, which otherwise is less pulpy than usual.

Seven years ago he got a small chancre, yellow and soft, on the foreskin, which had always been in a state of phymosis, no bubo. Three years after, some scaly spots, which disappeared after a time. Fourteen months after, the testicle became swollen, with a dull pain and dragging sensation up the

loins. It gradually lessened and got well. Five and a half years from the chancre, a small yellow ulcer, he says, like chancre, came on the right ala nasi, and the ulceration spread over the nose and face and forehead, and back into the nose and throat, with destruction of the nasal bones. There is a good deal of discharge from the nose, brownish yellow and very fetid. At no time did he take mercury to salivation, a few pills only at intervals.

I seized the dead bone at the upper part of the nose, and got away some of it, but it was not loose enough to get away the whole. Another dead piece, apparently the bony septum, is also quite firm and unfit for any attempt at removal. He was put on the hydriodate of potash with decoction of sarsaparilla.

April 25. —He left hospital for some weeks on some matter of business, and returned a few days ago. His general health and the appearance of the face were much improved, but the dead bone was as firm as ever. I had not hitherto made any strong effort to dislodge it, as I feared in doing so I might crack across the cribriform plate of the ethmoid bone, and the process of separation had been very slow, and the enlarged mass of dead bone was so hard that I made little impression with small cutting forceps, the only ones I could use, on it. I now, however, found a line of separation from the healthy



*James Carroll, bits of dead bone
from Nose & Jaw.*

nasal bone at the upper part at right side ; through this I got a narrow cutting blade of a strong forceps, and cut off portions, altogether amounting in size to a chesnut. There was some bleeding. I finally removed all the dead bone from the nose and the alveolus of the upper maxilla with the teeth. Plate 13 conveys an idea of the amount of dead bone taken away.

He afterwards got quite well, and it was my intention to have restored the lost nose ; but he left the hospital to do a job that he was wanted to do, and I have never seen him since. I was told that he had died of some acute attack.

Pat Harpin, ætat. 34, admitted January, 1852, with necrosis of the bones of the nose.

The nose is deformed and flattened, with diminished nostrils. There is a yellow incrustation filling them, with occasional foul and fetid discharge ; at the extremity of the nose is an ulcer the size of a shilling. No other syphilitic symptom. The septum of the nose is ulcerated away, except at the lowest division of the nostrils, and dead bone can be felt within the nose. Seven years ago he had chancres, cured by mercury to salivation, no after consequences. Two years since, he contracted other chancres, for which he was slightly salivated, and they healed. Shortly after this he was awoke at night by a piece of dead bone in his throat, pre-

ceded by very little uneasiness in the nose, but followed by inflammation of the nose, redness and obstruction. At the end of six months a large piece of dead bone came from the left nostril. This piece looks like an enlarged portion of the nasal process of the maxillary bone. Since then the nose has fallen. The ulcer on the surface of the nose began as a small pimple six months ago. Mr. Hamilton divided the remaining portion of the septum below, running both nostrils into one, and extracted all the portions of dead bone. The man was put on nitric acid and decoction of sarsaparilla, and was discharged well, February 16th, about three weeks after admission. The ulcer healed, and no discharge or fœtor from the nose.

When there has been formed a round hole in the hard palate, of sufficient size, the dead portions of the nasal bones may be extracted through it. I have often done this, and I recollect Sir Philip Crampton having removed a large piece in this way.

Pat. Gordon, ætat. 36, a small farmer. Ten years before he came to the hospital contracted a chancre near the frenum, followed by two buboes, and afterwards by sore throat. For both primary and secondary symptoms he took mercury to salivation. He continued four years without complaint, when he got sore throat which lasted a year. For this

he also took mercury. Between two and three years since, the nose first became affected, a dull pain across the bridge, worse at night, very tender to the touch, and with external redness and swelling, after which there began to be a thin, fetid discharge from the nostrils, with now and then a little blood and hard scabs, and after a time small pieces of rotten bone. After this had continued a year, the bridge of the nose fell in, and an opening formed in it, through which the "breath came." This, under treatment, closed. When brought under observation, the disfigurement was great, the nose quite sunk, and a deep depressed ridge in its place. The nostrils flattened and pinched in—a piece of decayed bone can be seen in the right. A large hole, through which the finger can be readily passed, exists in the hard palate, and more pieces of dead bone can be seen and felt there. At the back of the pharynx the cicatrix of a former ulcer is apparent, and there is a slight streak of ulceration down the tonsils.

The breath is overcomingly fetid, and speech much affected, the voice nasal and raucous. Through the right nostril was drawn out, by a forceps, nearly the whole of the right nasal process of the maxillary bone, quite soft and rotten; and through the opening in the palate, besides a quantity of bone so soft as to be smashed by the pressure

of the forceps, a large piece the size of the first joint of the midfinger, and which appeared to be a part of the ethmoid bone. The operation completely relieved him.

After the bone has been all removed, the hole in the palate can of course be closed by the dentist, a metal plate crossing the palate over the opening, and secured to the teeth. A patient of mine in poor circumstances contrived an ingenious way of accomplishing this object. He chewed a piece of India rubber till it was very soft, and put it in the hole, pressing it with his fingers in the nostril and mouth, so as to make a soft stud which effectually closed the hole for a time, and restored to the voice its natural tone, and prevented liquids getting into the nose.

May 7, 1856.—A man, ætat. 30, formerly a soldier and some years in India, contracted syphilis seven years since, but never to his knowledge took mercury; came to the Dispensary with a disfigured nose, flat and depressed, but not to an extreme degree, red, very tender, and discharging matter with the horrid fœtor of dead bone. This last could be seen in the nostrils of a dull bistre brown, irregular and moveable, the septum perforated, leaving about an inch of the lower end of the cartilaginous septum entire. The disease of the nose was of six months' duration, having begun with stuffing of the

nose, and then pain, soreness and discharge with horrid fœtor, rendering his state wretched in the extreme. As the dead bones could not be extracted through the nostrils, I first with a strong scissors slit up the remains of the septum, throwing both nostrils into one. This enabled me to take out the nasal processes of the malar bones, the bony septum, and the box of the ethmoid, all of a blackish brown colour, rotten, desperately fetid, and enlarged.

The next day he was greatly better, the cuts feeling rather sore, but the red blush had left the nose, where it was so observable before. There was no further trouble in this case.

These cases sufficiently display the symptoms of the disease and its treatment; the latter consisting in the speedy extraction of the necrosed bones when loose, or when not loose cutting as much of them away as can be done. The injection of a very weak lotion of carbolic acid materially lessens the fœtor. The constitutional treatment is that of other late forms of syphilis in bad constitutions, the hydriodate of potash, the nitric acid with decoction of sarsaparilla, good diet, and if possible sea air.

In the following case, where the soft and bony structures of the nose had been destroyed, I relieved the deformity by the Tabricotian operation.

CASE VIII.—Patrick Whelan, aged 35, lately in

the Constabulary, admitted March, 1862, with great deformity from loss of the nose. The anterior part of the nose is nearly gone, the cartilaginous septum, the alæ, and the lower part of the nasal bones. The remains of the nose are nearly quite flat to the face, except at the root of the nasal bones. The opening is represented by a narrow vertical slit that would admit the edge of a shilling; this narrowing is caused by the falling in and contraction of the remains of the alæ. Of the cartilaginous septum only a small portion exists, discernible when the edges of the opening are held asunder. Besides the great deformity of the mutilation, he is annoyed when speaking, by the necessity of holding the edges of the slit open, as otherwise he does not breathe freely, nor is his voice sufficiently strong; his respiration at other times is not impeded, the lateral flaps moving to and fro in inspiration and expiration. A slight superficial ulceration exists on the remains of the septum, but this is all the disease at present apparent. When he was admitted, six or seven weeks since, there was redness and swelling at the edge of the bridge of the nose, and a deep fissure-like ulcer, transversely, where the nose and upper lip join.

So long ago as 1852, he contracted a chancre, for which he got mercury to salivation, and the sore healed in two months. Since then he has suffered

occasionally from pains in the knees and periosteal pains at the tips of the shoulders. A year ago the nose first became ulcerated on the inside, the ulcer gradually destroying the soft parts and a portion of



the bones. He was in consequence discharged from the constabulary.

He was under treatment for a long time before I could operate. First for osteitis and periostitis; one small node formed exactly in the centre of the forehead, whence the flap would have to be taken, besides others on the ribs and sternum. Then, when this disease of the bones and periosteum was cured, he became affected with pleuritis, with effu-

sion in the lower part of the right pleura. When he had recovered from this I sent him to the seaside for a while, from whence he returned so well, that June 3rd, 1863, I performed the operation. I was careful to make the raw bed for the new nose flap as narrow as possible, while the flap from the forehead was of a good size. The nose was carefully approximated, and the edges kept together by four sutures on the left, and three on the right side, beginning from the bottom. I used fine thread for the sutures.



Wednesday, 10th.—On Monday, the sixth day, I removed the needles and four of the upper sutures. Yesterday the left lowest ligature, to-day the right.

The whole of the edges had united by the first intention, and on each side presented two clean even lines. The new nose looks very well, altering for the better, most remarkably, the whole expression of the face. The forehead wound granulating healthily, the lower part between the eyebrows scarcely showed the line of union. I had found the introduction of silver wire ligatures troublesome, and consequently painful; for this reason, in this case I used fine thread, which exceeded my expectation in the nearly total absence of all irritation.



Indeed, on the sixth day, so little inflammation surrounded them, that it was not easy to say where they were.

July 11th.—Thirty-eighth day.—I divided the

root of the new nose, and treated it as usual. Union by the first intention followed. After this the nose looked remarkably well, firm, and fleshy, and a good shape, being sufficiently prominent in spite of the absence of bony support. The only



drawback was, that, as I had not removed the lateral flaps of the old nose, he could not sniff up well. I removed these, and he could sniff up quite well after.¹

¹ The Restoration of a Lost Nose, by John Hamilton, 1864.

LECTURE VII.

Treatment.

HAVING described the different forms of syphilitic osteitis and periostitis, we now naturally turn to their treatment. It has already, to a certain extent, been exemplified in the many cases related in the previous lectures, but may now be discussed in a more systematic manner. When the disease occurs in the form of nodes among the early or secondary symptoms, such as eruptions, ulcers of the throat, or of the tongue, condylomata, iritis, &c., the best treatment is the administration of mercury to full salivation. This may be accomplished either by the external or internal use of the remedy. Whether we select one or the other, the important matter is, that the action of the medicine be decided, and that it be kept up in a milder degree for some time; for at least three months, when the evidence of the poisoning is well marked. Mercurial frictions are certainly among the most effectual means of ridding the system of the syphilitic poison. A drachm of the strong mercurial ointment rubbed in every day

generally affects the system in about a week: after salivation it may be rubbed in every second or third day for the full period. But it is not always easy to get a patient to submit to the dirt and unpleasantness of mercurial frictions; there are, besides, people with such irritable skins that the inunction at once brings out an attack of exema. This local irritation may be, in some instances, allayed by changing the place of friction, but this does not always answer, and we are then obliged to give them mercury in another way. When the concomitant secondary symptoms are severe, the syphilitic rash well marked, and every indication of profound poisoning of the system, two grains of calomel and a quarter of a grain of opium may be given three times a day till the gums are affected; the same object may be attained by five grains of grey powder, or five grains of blue pill three times a day.

Thomas Donovan, aged 33.—Thickly scattered over the entire body, face, and extremities, are the marks of a fading papular eruption, distinct spots, copper coloured, shining, with small silvery adherent scales not unlike psoriasis guttata, varying in size from a small spangle to a shot. He complains of pains in the joints, particularly the shoulders and elbows, so severe that he can scarcely raise his hand to his head. He has a swelling of the bone and periosteum at the junction of the middle and lower

third of the right tibia: and also of two ribs below the right mamma, over a space the size of a crown piece. No sore throat. He was infected about three months ago, the chancre on the skin at the root of the penis, next scrotum. It has left a decided scar, sunk, white, and rather hard. He did nothing for the chancre for a month—then took 16 pills and used a lotion, when it healed. A month since, the pains began and a week after the papular eruption, preceded by lassitude and sickness.

He had taken hydriodate of potash without the least advantage. He was ordered five grains of grey powder three times a day, with one-eighth of a grain of opium. His mouth became fully sore, without any griping, when the mercury was stopped. The eruption rapidly faded, all pain ceased in the node, which, however, still continued prominent, and the other pains left him. In a few days after, the swelling of the node went away, a few coppery stains alone remained of the eruption. He was kept gently under the influence of the mercury, and, with the exception of a little diarrhœa, went on very well, and was discharged cured thirty-two days after admission.

It will be found in such cases, where the node forms only one of a group of secondary symptoms, that as they get better by the mercurialization, so it will improve, ceasing to be tender, or painful, and

finally disappear. There are some members of the profession, I am aware, who believe that not only is mercury objectionable when the bones are affected, but that their diseased condition is the result of the previous use of mercury. I have sufficiently shown, by my recommendation, that I do not agree with this opinion. A style of reasoning has been adopted (unsupported by facts) that, when mercury has been previously given, the diseases of the bones which may afterwards appear are caused by it. On the same principle, the deaths in phthisis might be attributed to cod liver oil—for how few die of that fatal disease, who have not previously taken cod liver oil? I have notes of cases where well marked nodes, with other secondary symptoms, occurred where no mercury at all had been given for the primary chancre. I have met with many cases of tertiary osteitis and periostitis, particularly of the cranium, where no mercury had been used for primaries or secondaries. A proper mercurial course in the vast majority of cases improves the general health. After salivation is induced, the patient loses his sallow look, and after a little puts up flesh. In some cases of bad secondary infection, tubercular eruption, ulcers in many parts of the body, nodes and bad sore throat, with emaciation and night sweats, I have, after salivation and consequent relief of these symptoms, got the patient weighed, and found the increase of

weight remarkable; whereas for weeks previously he had been continuing daily to reduce in condition. I recollect a woman of the town saying to me that she had no objection to mercury, as she always found that it renewed her constitution, and a gentleman observed that the only objection he had to mercury was that it made him too fat.

There are, of course, certain constitutions in which mercury acts as a poison, and cannot be borne. They are very rarely met with, and a careful observant surgeon will soon ascertain the constitutional peculiarity and stop the medicine. I lately saw a gentleman who had anasarca, with weak heart and large liver. He told me that mercury always disagreed with him, producing an irritable rash. I thought I would obviate this by giving the smallest dose, and ordered two grains of blue pill three times a day. On the second day (eight grains having been taken) irritation of the skin began, followed by mercurial exema. It seemed, however, otherwise to have acted beneficially, in a degree disproportionate to the quantity taken; as the liver reduced in size, the anasarca disappeared, and dyspnoea was removed. In another case, where I knew two grains of grey powder to have induced salivation, I was consulted for pediculi pubis, and thought I might safely destroy these vermin by rubbing about the size of a pea of mercurial ointment among the hair.

I was wrong, for minute as the quantity was, salivation to a slight degree ensued.

But in ordinary constitutions mercury agrees very well, without producing any bad effects. Indeed, in some cases it is invaluable, where tertiary osteitis refuses to yield to iodide of potassium even in large doses, the pain and local inflammation continuing severe—or when, occurring in the bones of the cranium, epilepsy results, either from the pressure of the thickened bone, or, the inflammation and irritation extending to the membranes of the brain. In these cases I have found the iodide of potassium, though of some use, not of itself sufficient to cure the disease, and mercury succeed in doing so. A man of the name of Horrigan had frequently been admitted for osteitis and periostitis of the left side of the forehead, a good deal of diffused swelling of the frontal bone, exquisite tenderness, and the most severe pain, keeping him awake all night, in spite of the use of narcotics. He always got well by large doses of iodide of potassium, and blistering, except on one occasion when mercury had to be given, with complete relief. The iodide of potassium at first used to relieve him, in five grain doses three times a day, but finally fifteen grains had to be given thrice daily. Directly he got relief he left the hospital, so that he never could use the remedies long enough to thoroughly cure the disease. Hence

his frequent relapses. He returned, after some months' absence, with very grave symptoms in addition to the pain of the forehead. Besides this being unusually severe, he had a stupid, confused feel in the head, and just prior to admission had had two epileptic fits. There was a difference in the two pupils, the left dilated: his face flushed and head hot. In consequence of these last symptoms I applied a few leeches behind the left ear, blistered the forehead, and ordered fifteen grains of the iodide of potassium three times a day; but there was no improvement at the end of a week. I brought him, therefore, gently under the influence of mercury, when the most marked relief ensued. For a fortnight after, I gave him four grains of blue pill and one of extract of hyosciamus at bed-time, and fifteen grains of the iodide morning and midday. The result for the time was complete removal of all the symptoms. In this case there was enlargement of the liver, which I have often observed to be attendant on bad forms of osteitis. If you see, therefore, that mercury cures the nodes which sometimes accompany other secondary symptoms, and the patients improve in health, do not let reasoning, or that imaginary possibility of bad effects which haunts the minds of some, deter you from its use. When you can, as in the above case, be guided by facts, do not mind theoretical arguments. I believe

the opposition to the proper use of mercury in syphilis has done infinite mischief, putting aside our best and surest remedy, and letting the poison run havoc in the system, while ineffective remedies are resorted to as substitutes. I once succeeded to the care of a large number of cases of secondary syphilis after a gentleman who was a non-mercurialist. They had been treated with sarsaparilla, bark, nitric acid, iodide of potassium, &c. They were generally labouring under the same unmitigated forms of disease, eruptions, nodes, sore throat with syphilitic cachexia well marked, sallow faces and wasted forms. It was interesting to observe how rapidly all the symptoms diminished and finally disappeared, with full restoration to health, under a well-regulated mercurial course. If in ignorant hands this remedy has done, as any other remedies would, some mischief, it is no reason why the scientific surgeon should therefore reject it. The effects of mercury, when introduced by Carpensis in 1514, were so remarkably efficacious in curing the then deadly forms of the disease, that the greatest sensation was produced. The estimation in which mercury was then held is well shown by Fracastorius¹ in his poem. In a beautiful fable he represents an unfor-

¹ Fracastorius, Veronensis— Syphilis. In Boerhaave's Collection—Aphrodisiacus sive de Lue Venerea.—1728.

tunate shepherd who had offended Apollo by having killed a sacred stag, and been punished by the furious god with syphilis. Afflicted night and day with dreadful pains and other symptoms of the disease, he prayed for relief to the goddess of a neighbouring fountain. She directed him to a certain gloomy cave, into which he enters, and meets the nymph to whose care were entrusted the subterranean metals. She guides him through many winding passages glittering with gold and silver; at last he stood on the borders of a vast lake of liquid shining metal: this was quicksilver. He was told to plunge thrice in and rub himself well with the lustrous metal, the nymph lending a helping hand. As the process proceeded he wondered to see the foul marks of the disease leave him; his limbs become painless and free, and every trace of the past washed away.

“*Simul argenti ter fonte salubri
Perfundit, ter virgineis dat flumina palmis
Membra super, juvenem toto ter corpore lustrat
Mirantem exuvias turpes, et labe maligna
Exutos artus, pestemque sub amne relictam.*”

Such is the ingenious metaphor of the man of genius, but he was also a practical physician of great repute. He speaks highly of mercurial inunction, and that it should be pushed till the gums are eroded and water flows from the mouth. From

that time to this, upwards of 300 years, no essential improvement in the treatment of secondary symptoms has been made. Mercurial inunction is still the best way of ridding the system of the poison.

But where the inflammation of the bone and periosteum occurs late, either a solitary symptom or accompanied by any of the other late evidences of constitutional infection which we are accustomed to call tertiary, the subcutaneous tubercles called gummata, cutaneous ulcers, pustulo-crustaceous patches of eruption, or pharyngeal ulceration, the iodide of potassium is our most valuable remedy, removing the pain in slight cases in a week or fortnight. Even in some severe cases the effect of the remedy is more rapid.

Rebecca S., admitted 4th Nov., 1873—a delicate-looking young woman—suffering from severe pain in the knee, left shoulder and right side of head—arising from syphilitic osteitis and periostitis of the affected parts. There being an exquisitely tender node on the external orbital process of the right frontal bone, another at the head of right tibia, with some swelling of the knee, and a third occupying the whole thickness of the left humerus about the insertion of the deltoid. The pain unusually severe, particularly at night, totally preventing sleep. She was thin, and subject to night sweats. The attack was of some weeks' standing,

the result of a primary affection about three years before. She had suffered from the pains at different periods before, but never so severely. She had for a short time previous to admission taken 5-grain doses of iodide of potassium three times a day, with opiates at night, but with no relief.

On the 5th she was put on 10-grain doses in decoction of sarsaparilla, and ten grains of Dover's powder at bedtime. On the 10th she was well, no pain, and the swelling of the forehead and knee quite gone. The humerus, though neither painful or tender, still larger than natural. She suffered from slight iodism. She left the hospital, being directed to continue the iodide of potassium for a fortnight.

But to insure against relapse it should be taken for a much longer period. This makes private practice so much more successful. In hospital practice they will leave immediately after the pains cease, and discontinue to take the medicine. A convenient way to give the iodide of potassium is, dissolved in any of the bitter tinctures colombo, gentian, or orange peel: I frequently prescribe it in tincture of quassia, four ounces of the tincture, and from eight to sixteen scruples of the iodide, so that each teaspoonful or drachm contains from five to ten grains, and may be taken in a large wine-glass of water three times a day. I think the medicine better borne and more efficacious when well

diluted. Fluid extract of sarsaparilla may also be made the vehicle for the iodide. As the medicine is to be continued for a long time, an occasional change in the vehicle is desirable. We are sometimes obliged to resort to larger doses, fifteen or twenty grains three times a day. When these fail we must have recourse to mercury, as in Horrigan's case. In some cases the combination of the iodide of potassium and mercury answers best. This I recommended long ago in my Essay on Syphilitic Sarcocoele; the potash morning and midday, and eight grains of blue pill and two of extract of hyosciamus at bed-time. Those persons who cannot bear iodide of potassium without suffering from the well known bad effects of coryza, sore watery eyes, pains in the stomach, or exema, are a difficulty to the surgeon. In a few instances I have met with patients who have had the courage to persevere, though suffering from those effects, till tolerance of the remedy followed, and the best results were obtained. I have also observed that where the violent effects mentioned have ensued, the amelioration in the disease has been rapid. I have tried the bromide of potash with some, but not marked, benefit, and I think in such cases we had best fall back on a persevering use of small doses of bichloride of mercury. Where it is thought advisable to give it in decoction of sarsaparilla, I would offer a caution:

viz. : to have the bichloride dissolved in equal parts of spirits of wine and distilled water, so that a drachm or tea-spoonful by measure contains the requisite dose. This may be taken in a wine-glass of the decoction three times a day, a little after a meal ; whereas, if the oxymuriate, though previously dissolved in spirits of wine, is added *en masse* to the decoction of sarsaparilla, after a time a portion of it ceases to be held in solution, and falls to the bottom, so that the last dose is so unequally loaded with the bichloride that it becomes poisonous. I met with a gentleman who had suffered in this way. On taking the last dose which remained in the bottle, he was seized with excruciating pain in the belly, with violent dysentery, straining and bloody and mucous stools. He recovered with difficulty ; and for several years after, on taking any thing that disagreed with him, he had attacks of pain in the cœcal region, with dysentery. In one of these attacks I attended him.

But when iodide of potassium fails, the symptoms in late affections of the bones are so acute, we are compelled to use more decided mercurial treatment. A man contracted syphilis eight years before admission. There were two nodes on the left side of the forehead, above the eyebrow, another on the posterior inferior angle of the parietal bone, both large, but not distinctly fluctuating, very tender, and

painful at night; some slight periostitis of the ribs and of the spine of the scapula, small soft tubercles, not discoloured, and moveable under the skin, in different parts of the body, particularly the chest. But the most striking symptom of which he complains is dreadful headache, across the forehead, the temples, and going up to the vertex—constant for the last fortnight, but always worse at night; keeping him awake, and if he slumbers he awakes with a start in alarm, and is obliged to sit up. With the pain both within and without his head, there is a throbbing feel, and the eyeballs are painful. He has no other head sensation, but he has double lateral vision and converging strabismus. Iodide of potassium gave no relief; but all these symptoms ceased directly the mouth became affected by mercury.

Besides the constitutional treatment, much benefit will be experienced from the application of blisters. Leeches are rarely useful, except in some cases where there is great heat, throbbing, and tension, from the acute course of the disease, and where in the head there are symptoms of congestion, intense headache, confusion, and giddiness. Opiates are of great use, and well borne. In some rare instances, where the pain continued severe after a fair perseverance in these remedies, I have found relief follow the division of the thickened periosteum down to

the bone. A piece of lint should be put in the incision, which should be allowed to heal slowly. I have already alluded to the case of an office-keeper under the Poor Law Board, where the osteitis and periostitis were in the trochanter major, and where a severe relapse had occurred after he had been relieved by constitutional treatment. Permanent relief followed a free incision down to the bone through the thickened and indurated periosteum.

A healthy-looking young woman was admitted into the Richmond Hospital, suffering dreadfully from pain in the right side of the head, over the parietal bone—worse at night, and with exquisite tenderness on pressure. Two years ago she contracted syphilis from her husband, followed by spots on the skin, and sore throat. She had suffered from the pain for seven months, and it had resisted different kinds of mercurial treatment, iodide of potash, and a blister, which last gave most relief. Three days previous to admission she had endured more pain than ever. There was a diffused swelling of the part, and at the most painful spot a small elevation which fluctuated, but not decidedly. The examination could scarcely be made, from the excessive tenderness. A free incision through the centre down to the bone was made; there was no matter, but free bleeding; the surface of the bone rough and irregular. A piece of lint was put into

the wound ; Dover's powder at bed-time. After this all pain ceased.

It is best to prevent the cut healing too soon, as the following case shows :—

A woman was admitted with a painful node on the lower third of the tibia, which continued painful in spite of varied treatment. I divided the periosteum down to the bone ; it was thickened, and cut like gristle. The incision was followed by relief, but it healed quickly, when the pain returned as bad as ever. A second incision was made, and kept from uniting by dressing from the bottom with lint. It healed by granulation, and permanent ease followed.

Now with regard to a soft node, we have to deal with a late form of the disease in a bad constitution. Good air, good diet, the iodide of potassium, with the external application of the strong tincture of iodine, generally succeed in removing the swelling, by curing that state of the bone on which it depends, and causing absorption of the effusion between it and the periosteum. One caution let me give you—be very slow in opening a soft node. Sometimes they are so red, and the integuments so thin, the fluctuation of matter so strongly apparent, that one would expect it to burst immediately, or that it ought to be opened—but in apparently the most hopeless cases I have brought about absorption—

and it is very important to do so, for necrosis nearly inevitably takes place when the surface of the bone is exposed to the air. A gentleman consulted me for a large, red, fluctuating swelling at the back of the cranium. My first impression was that it was an abscess, and should be opened. On inquiring into the history of the case, I came to the conclusion that it was a soft node. Under the influence of the iodide of potassium it entirely went away, and has never since returned—now some four years ago. Five or six months since, a gentleman came to me with a large soft node on the outside of the right os calcis. As there was some pain, and the integuments were quite thin and red, and appeared on the eve of bursting, I felt disposed to let out the fluid. The gentleman himself, however, requested me to wait for a few days, as on a former occasion when it was nearly as bad I had put it back. He was right; for in a fortnight the swelling had nearly disappeared. I saw him a few days ago, and the node had quite gone, some thickening of the bone remaining where it had been. You have seen in the large ward a soft node of great size on the clavicle, red and fluctuating from one end to the other, with the skin little thicker than paper, and yet quite absorbed by the same treatment. When the disease is somewhat abating, its departure may be hastened by the local application of

the tincture of iodine. I have already given the pathology of a soft node in the process of cure, Plate No. 4. I am more particular in impressing this forbearance in opening a soft node, for when it is done, as I have said, necrosis is almost inevitable, the separation of the dead bone most slow—during the whole of which time the patient undergoes the misery of an open fetid sore, and if in the centre of the forehead most disfiguring, and driving him out of society. You will, however, meet cases in which you are obliged to make an opening to relieve excessive pain. In such cases, or where the node has opened of itself, and the dead bone is exposed, we must in the greater number of cases wait till it has become separated and fit for removal. I have been rather disappointed in the effects of nitric or sulphuric acids applied with a view of eating away the dead fragment, nor is operative interference usually in our power. In the lecture on soft nodes I have sufficiently dwelt on the caution necessary when the bone is (as it often is in the head) over a corroded and fragile inner table, and the brain so nigh. Besides, the disease affects the bone not only in increasing it in size, but in hardness also; attempts to gouge with a chisel I have found to have no effect on it, and all force here is unjustifiable. If nature opens the soft node with a small opening with undermined edges, it is best, as a general rule, to enlarge the

opening from one end to the other. The thin and purple integuments are otherwise apt to be destroyed. A soft bread and water poultice at first, and greasy applications, as zinc ointment, over the exposed surface of bone certainly do good. My experience goes in favour of this recommendation of Tenon that greasy applications to the bone, stripped of periosteum by accident, promote the growth of granulations from the surface. Good country air, the seaside if possible, and a regulated nutritious diet, help us materially in the action of separating the bone, and in a permanent cure: and a continuance of the iodide of potash, long after the disease is apparently well, prevents relapse.

I need not insist on the advantage of taking away the piece of dead bone directly it is loose, nor on the necessity of removing by an incision the softened yellow gummatous matter over a bone. The case of Alice Cooney offers a striking example of the benefit arising from the last. In those distressing cases of necrosis of the bones of the nose, we should diligently watch the moment they are detached, and can be seized with a forceps and extracted—the presence of the rotten bits of bone cause such irritation and misery, and their removal is attended by such immediate relief. Nor should we hesitate to divide the lower part of the perforated septum of the nose, when such a proceeding

facilitates the extraction. The divided portion of the septum soon re-unites. The same rule should be followed in the necrosis of the jaw: the sooner it is taken away the better, the bone forceps assisting materially in anticipating the slower process of separation.

There are still other cases in which operative interference is imperative. Sometimes in syphilitic osteitis matter forms in the centre of the bone: and though after a time it makes its way to the surface, it does so after much suffering, and often violent local inflammation. If we can shorten this process by giving exit to the matter, we shall give great relief.

James Keown, ætat. 36, a sallow-faced man, was admitted with considerable swelling of the elbow and forearm, for about two-thirds of the upper part. This swelling is found to depend on an enlargement of the upper part of the ulna; the bone four or five times its natural circumference, very tender and hard: osteitis and periostitis—the inflammation of the articular end causing effusion into the elbow joint, and mechanically preventing the arm being quite extended or flexed. He suffered constant deepseated pain, worse at night, when he got no sleep.

The original syphilitic taint is remote, but his present symptoms date six months back. At one

time an incision had been made; blood alone flowed out, and there was no relief. In the hospital he was blistered, took iodide of potassium and the oxymuriate, with Dover's powder at bed-time. But though there was some reduction in the size of the swelling, it still remained much enlarged, with slight œdema, and he still suffered pain, and the arm was useless. Under these circumstances, I conceived that the symptoms were caused by an abscess in the bone.

I made an incision an inch long down to the bone where it was widest, and then applied the drill, which worked at first with some difficulty, the substance of the bone being hard and condensed, but then the drill met with less resistance, and after it had penetrated three-quarters of an inch I withdrew it. A little less than a drachm of very thick matter flowed out. A probe moved freely about in a cavity apparently capable of containing a hazel nut. After this he scarcely suffered pain till he left the hospital well.

The matter will work its way through the bone, and form a superficial abscess, and letting out the matter will give relief. We are sometimes obliged to do something more. A young woman took a child to nurse. The child had syphilis, spots, sore throat and mouth. Her nipple became ulcerated, followed by an eruption, sores on the inside of labia, and dreadful pain in the right tibia, and right upper

jaw. On admission there was a dull red tumour in the middle of the front of the tibia, and the whole circumference of the tibia at the affected part was enlarged. It fluctuated freely. To relieve the great pain an incision was made freely through the tumour down to the bone, its surface rough but soft—the matter was between the bone and periosteum. The point of the knife sunk into a soft depression, and an opening was discovered leading into the cavity of an abscess in the substance of the bone. Great relief of the pain followed, but after a short time it returned. It struck me that this was owing to the opening being too small. With a crucial incision I bared the bone round the opening, so as to expose it fully, and enlarged it with a gouge. Complete and permanent relief followed.

In conclusion, I may say that I know no diseases so amenable to treatment as syphilitic osteitis and periostitis, and in which, in the most severe cases, the surgeon can do so much to alleviate where he cannot cure.

THE END.



CORRIGENDA.

- Page 14, last line, *for long read bony.*
— 30, line 5 from bottom, *for after read ago.*
— 67, line 4, *omit Dec. before 4.*



