

SURGICAL
ANATOMY

J. A. C. MACEWEN



57-

Glasgow
University Library



Book No **0433961**



30 114 0043396 13





SURGICAL ANATOMY

Digitized by the Internet Archive
in 2015

<https://archive.org/details/b2146506x>

SURGICAL ANATOMY

BY

JOHN A. C. MACEWEN

B.SC. IN ANATOMY AND PHYSIOLOGY WITH HONOURS

M.B., C.M. WITH HONOURS

FELLOW OF THE FACULTY OF PHYSICIANS AND SURGEONS, GLASGOW

SENIOR ASSISTANT TO THE REGIUS PROFESSOR OF SURGERY, GLASGOW UNIVERSITY;
SURGEON TO THE ELDER HOSPITAL, GOVAN; ASSISTANT SURGEON TO THE
ROYAL INFIRMARY, GLASGOW, AND TO H.R.H. PRINCESS LOUISE HOSPITAL,
ROSENEATH; LATE CIVIL SURGEON, SOUTH AFRICAN FIELD FORCE



LONDON
BAILLIÈRE, TINDALL AND COX
8, HENRIETTA STREET, COVENT GARDEN

1910

[All rights reserved]



PREFACE

THE author's aim has been to present a concise yet connected account of the anatomical facts of importance to the surgeon, indicating the relative importance of these facts by brief references to their surgical bearing. The physiology of the parts under discussion has also been touched upon when of surgical import.

It is hoped that the aim will commend itself to medical men, and to students of surgery and of anatomy, and that they will find the detail given sufficient to obviate frequent reference to systematic text-books of anatomy.

Generally, the author has followed the teaching of the standard British and Continental works, and to these he gladly acknowledges his indebtedness. On a number of points, however—as, for example, regarding the function of the periosteum—he has followed that of his teacher, Sir William Macewen, whose opinions are based not merely upon clinical experience, but also in many cases upon long series of experiments.

In the mode of presenting certain facts, likewise—as in surveying the anatomy of hernia from the abdominal instead of from the external surface—the author has followed methods which long experience in teaching has convinced him are most readily grasped by the student.

J. A. C. M.

GLASGOW,
November 1, 1909.

CONTENTS

SECTION I

HEAD AND NECK, VERTEBRAL COLUMN, BRAIN AND SPINAL CORD

	PAGE
THE HEAD - - - - -	I
THE CRANIUM - - - - -	5
THE BRAIN - - - - -	19
THE CRANIAL NERVES - - - - -	35
THE EAR - - - - -	42
THE EYE AND OCULAR APPARATUS - - - - -	54
THE NOSE - - - - -	74
THE ACCESSORY SINUSES - - - - -	80
THE FACE - - - - -	85
THE UPPER JAW - - - - -	88
THE PAROTID REGION - - - - -	89
THE LOWER JAW - - - - -	92
THE TEETH - - - - -	94
THE PTERYGO-MAXILLARY OR ZYGOMATIC FOSSA - - - - -	96
THE SPHENO-MAXILLARY FOSSA - - - - -	99
THE CAVITY OF THE MOUTH - - - - -	100
THE PHARYNX - - - - -	109
THE NECK - - - - -	112
THE VERTEBRAL COLUMN - - - - -	139
THE CORD - - - - -	143

SECTION II

THORAX

THE THORAX - - - - -	150
THE MAMMARY GLAND - - - - -	156
THE THORACIC CAVITY - - - - -	160
THE HEART - - - - -	164
THE THORACIC AORTA - - - - -	166
THE THORACIC TRACHEA - - - - -	168
THE LUNGS - - - - -	172
THE OESOPHAGUS - - - - -	174

SECTION III

ABDOMEN AND PELVIS

	PAGE
THE ABDOMEN	177
THE ABDOMINAL PARIETES	177
THE INGUINAL REGION	187
THE ABDOMINAL CAVITY	200
THE STOMACH	203
THE DUODENUM	210
THE SMALL INTESTINE	214
THE LARGE INTESTINE—CÆCUM	217
THE VERMIFORM APPENDIX	218
THE COLON	222
THE LIVER	227
THE PANCREAS	235
THE SPLEEN	237
THE LUMBAR REGION	239
THE KIDNEYS	242
THE SUPRARENAL CAPSULES	246
THE SOLAR PLEXUS	248
THE AORTA	248
THE INFERIOR VENA CAVA	248
THE THORACIC DUCT	249
THE PELVIS	249
THE BLADDER	257
THE URETHRA	262
MALE ORGANS OF GENERATION	265
THE PENIS	265
THE PROSTATE	267
THE TESTICLE	271
FEMALE ORGANS OF GENERATION	275
THE UTERUS	275
THE VAGINA	277
THE OVARY	281
THE VULVA	284
THE PERINEUM	284
THE RECTUM	290

SECTION IV

LOWER EXTREMITY

THE HIP	299
THE HIP-JOINT	312
THE THIGH	322
THE FEMUR	325

	PAGE
THE KNEE - - - - -	328
THE KNEE-JOINT - - - - -	334
THE LEG - - - - -	345
BONES OF THE LEG - - - - -	351
THE ANKLE AND FOOT - - - - -	353
THE ANKLE-JOINT - - - - -	361
THE NERVES OF THE LOWER EXTREMITY - - - - -	371

SECTION V

UPPER EXTREMITY

REGION OF THE SHOULDER - - - - -	375
THE SHOULDER-JOINT - - - - -	383
THE AXILLA - - - - -	388
THE ARM - - - - -	394
THE HUMERUS - - - - -	399
THE ELBOW - - - - -	404
THE ELBOW-JOINT - - - - -	408
THE FOREARM - - - - -	413
THE WRIST AND HAND - - - - -	421
THE WRIST-JOINT - - - - -	432
THE THUMB AND FINGERS - - - - -	436
THE NERVES OF THE UPPER EXTREMITY - - - - -	438
INDEX - - - - -	443

LIST OF ILLUSTRATIONS

FIG.	PAGE
1. CRANIAL POINTS - - - - -	2
2. SCALP SECTION - - - - -	6
3. CORONAL HEAD SECTION PASSING THROUGH PORTION OF THE SPINAL CANAL - - - - -	15
4. CORONAL HEAD SECTION PASSING THROUGH MIDDLE EAR -	40
5. TEMPORAL BONE - - - - -	44
6. SAGITTAL HEAD SECTION PASSING THROUGH THE TYMPANIC MEMBRANE AND DISPLAYING THE MIDDLE EAR, ATTIC, ITER, AND MASTOID ANTRUM - - - - -	46
7. HORIZONTAL HEAD SECTION, PASSING THROUGH THE MIDDLE EAR. VIEWED FROM BELOW - - - - -	49
7A. HORIZONTAL HEAD SECTION, ABOUT $\frac{1}{4}$ INCH BELOW FIG. 7	50
8. DIAGRAM OF EYE - - - - -	63
9. DIAGRAM OF NASAL CAVITY, ETC. - - - - -	79
10. THE ZYGOMATIC AND SPHENO-MAXILLARY FOSSÆ - - - - -	96
11. DEEP DISSECTION OF THE LEFT SIDE OF THE NECK - - - - -	115
12. DIAGRAM OF A TRANSVERSE SECTION OF THE NECK AT THE LEVEL OF THE SEVENTH CERVICAL VERTEBRA, SHOWING THE ARRANGEMENT OF THE DEEP CERVICAL FASCIA, AND THE POSITIONS OF OTHER STRUCTURES - - - - -	118
13. DEEP DISSECTION OF THE LEFT SUBMAXILLARY REGION -	121
14. DISSECTION OF THE FRONT OF THE NECK - - - - -	129
15. THE TERMINAL PART OF THE SPINAL CORD, AND THE CAUDA EQUINA - - - - -	144
16. THE APPROXIMATE RELATION TO THE SPINAL NERVES OF THE VARIOUS MOTOR, SENSORY, AND REFLEX FUNCTIONS OF THE SPINAL CORD - - - - -	147
17. DIAGRAM OF BREAST LYMPHATICS - - - - -	158
18. TRANSVERSE SECTION OF THE THORAX THROUGH THE SECOND STERNUM IN FRONT AND THE BODY OF THE NINTH THORACIC VERTEBRA BEHIND, SHOWING THE REFLECTIONS OF THE PLEURÆ AND THE POSITION OF THE VISCERA -	162
19. SCHEME OF ABDOMINAL MUSCLES (IN SECTION) - - - - -	181
20. CUTANEOUS NERVES OF THE TRUNK. ANTERO-LATERAL VIEW -	184
21. STEREOGRAM OF ABDOMINAL WALL, GIVING AN EXAGGERATED VIEW OF THE INGUINAL, FEMORAL, AND OBTURATOR CANALS-	188

FIG.	PAGE
22. DIAGRAM OF ABDOMINAL WALL FROM BEHIND - -	192
23. DIAGRAM ILLUSTRATING THE DEVELOPMENTAL OBLITERATION OF THE FUNICULAR PROCESS (SERIES A), AND THE FORMS OF INGUINAL HERNIA (SERIES B), AND HYDROCELE (SERIES C) WHICH MAY ARISE THEREFROM - - -	196
24. DIAGRAM OF PERITONEUM, ITS SACS AND FOLDS - -	202
25. THE SUPRAMESOCOLIC COMPARTMENT OF THE ABDOMEN. PORTIONS OF STOMACH AND LIVER HAVE BEEN REMOVED TO DISPLAY THE DIAPHRAGM FORMED BY THE TRANSVERSE COLON AND MESOCOLON WITH KIDNEY, SPLEEN, AND PANCREAS - - -	204
26. TRANSVERSE SECTION OF THE ABDOMEN AT THE LEVEL OF THE FIRST LUMBAR VERTEBRA - - -	210
27. THE INFRAMESOCOLIC COMPARTMENT OF THE ABDOMEN. ON THE RIGHT A PORTION OF STOMACH, AND TRANSVERSE COLON CARRYING WITH IT TRANSVERSE MESOCOLON, ARE SHOWN TURNED UP AS FOR THE OPERATION FOR POSTERIOR GASTRO-JEJUNOSTOMY - - -	212
28. THE INFERIOR SURFACE OF THE LIVER - - -	229
29. ANTERIOR VERTICAL SECTION OF PELVIS FROM FRONT - -	252
30. POSTERIOR VERTICAL SECTION OF PELVIS FROM BEHIND - -	254
31. VIEW OF PELVIC BASIN FROM ABOVE - - -	255
32. DIAGRAM OF MALE PELVIS. VIEWED FROM ABOVE. ON THE RIGHT SIDE THE PERITONEUM HAS BEEN FOLDED OVER, DISPLAYING THE RIDGES AND FOSSÆ, WHILE ON THE LEFT THE PELVIS IS SHOWN CUT IN SECTION - - -	258
33. THE VISCERA OF THE MALE PELVIS (LATERAL VIEW) - -	270
34. VIEW OF FEMALE PELVIC BASIN FROM ABOVE - -	278
35. THE GLUTEAL REGION AND BACK OF THE THIGH. DEEP DISSECTION - - -	303
36. THE FRONT OF THE THIGH (SCARPA'S TRIANGLE) - -	307
37. OUTLINE DIAGRAM OF LONGITUDINAL SECTION OF HIP - -	313
38. OUTLINE DIAGRAM OF TRANSVERSE SECTION OF THIGH AT THE JUNCTION OF UPPER AND MIDDLE THIRDS - - -	324
39. SAGITTAL SECTION OF THE RIGHT KNEE-JOINT, VIEWED FROM THE OUTER SIDE - - -	336
40. DIAGRAM OF KNEE-JOINT OF ADOLESCENT - - -	340
41. OUTLINE DIAGRAM OF TRANSVERSE SECTION OF LEG IN THE UPPER THIRD - - -	348
42. OUTLINE DIAGRAM OF LONGITUDINAL SECTION OF FOOT - -	356
43. THE SYNOVIAL SHEATHS AT THE ANKLE. ANTERIOR VIEW - -	359
44. THE SYNOVIAL SHEATHS AT THE ANKLE. INTERNAL VIEW - -	360
45. DIAGRAM OF THE SIX SYNOVIAL MEMBRANES OF THE FOOT - -	365
46. NERVE-SUPPLY OF LOWER EXTREMITY - - -	373
47. THE RIGHT GLENOID CAVITY, AND THE ADJACENT LIGAMENTS - -	384
48. COSTO-CORACOID MEMBRANE - - -	389

LIST OF ILLUSTRATIONS

xiii

FIG.	PAGE
49. OUTLINE DIAGRAM OF TRANSVERSE SECTION OF UPPER ARM IN THE MIDDLE THIRD - - - - -	403
50. THE AXILLARY SPACE, AFTER REFLECTION OF THE PECTORALIS MAJOR ; AND THE SUBCLAVIAN TRIANGLE - - - - -	404
51. SUPERFICIAL DISSECTION OF THE FRONT OF THE LEFT ELBOW -	406
52. OUTLINE DIAGRAM OF TRANSVERSE SECTION OF ELBOW -	408
53. LONGITUDINAL SECTION OF ELBOW - - - - -	411
54. LONGITUDINAL SECTION OF FOREARM AND HAND - - - - -	417
55. OUTLINE DIAGRAM OF TRANSVERSE SECTION OF FOREARM IN LOWER THIRD - - - - -	418
56. DEEP DISSECTION OF FRONT OF RIGHT FOREARM, AND SUPER- FICIAL DISSECTION OF PALM - - - - -	424
57. THE GREAT PALMAR BURSA, AND THE SYNOVIAL SHEATHS OF THE FLEXOR TENDONS - - - - -	429
58. THE SYNOVIAL SHEATHS OF THE EXTENSOR TENDONS -	432
59. DIAGRAM OF THE FIVE SYNOVIAL MEMBRANES OF THE HAND -	433
60. TRANSVERSE SECTION OF WRIST - - - - -	435
61. CUTANEOUS NERVES OF ARM - - - - -	440

SURGICAL ANATOMY

SECTION I

HEAD AND NECK, VERTEBRAL COLUMN, BRAIN AND SPINAL CORD

THE HEAD

Surface Anatomy.

THE head is generally not symmetrical, the left half being the larger. In some cases this asymmetry is due to pressure at birth, rickets, or syphilis, and is very marked, the head presenting a lop-sided appearance. The relation of length to breadth of the skull varies considerably in different races, the term *dolichocephalic* denoting an elongated type, and *brachycephalic* one which is more rounded. The cranial capacity likewise varies, being small (*microcephalic*) in African Bushmen, and large (*megacephalic*) in more civilized races. A microcephalic condition is met with pathologically associated with cretinoid idiocy, while in hydrocephalus the head is often very large.

It must not be concluded that the shape of the head is always an index of the cranial development, and this is particularly the case in the frontal region, where the 'development' depends largely upon the presence and size of the frontal sinuses. A high and prominent forehead is frequently associated with rickets, in which the frontal and parietal eminences may also be enlarged owing to new bone formation. Inherited syphilis also produces overgrowths of bone round

the anterior fontanelle, constituting what are known as Parrot's nodes.

The *sagittal suture* is that formed by the union of the superior margins of the parietal bones. It can generally be detected by palpation running antero-posteriorly. By a *SAGITTAL SECTION* is meant one running antero-posteriorly.

The junction of the parietals anteriorly with the frontal bones forms the *coronal suture*, which can also generally be palpated, running across the vertex from side to side. By a

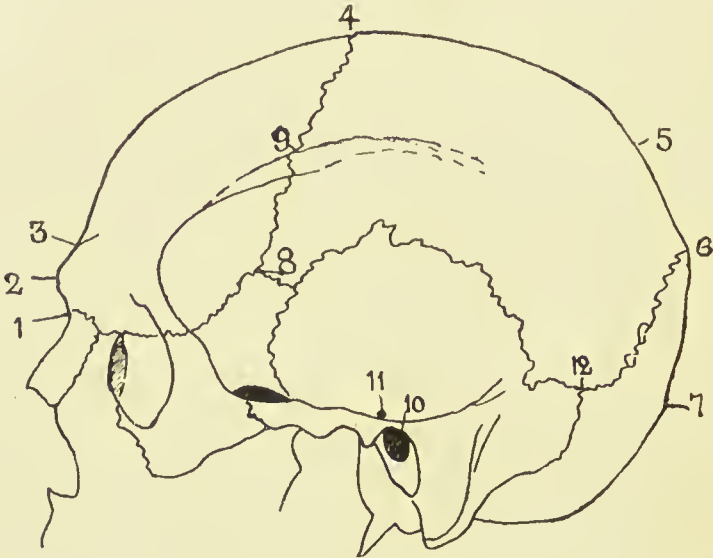


FIG. I.—CRANIAL POINTS.

- | | | |
|--------------|-------------|--------------------------|
| 1. Nasion. | 5. Obelion. | 9. Stephanion. |
| 2. Glabella. | 6. Lambda. | 10. Meatal Point. |
| 3. Ophryon. | 7. Inion. | 11. Pre-auricular point. |
| 4. Bregma. | 8. Pterion. | 12. Asterion. |

CORONAL SECTION is meant one running at right angles to the sagittal.

The point at which coronal and sagittal sutures meet is called the *BREGMA*, and can be made out on careful palpation. It can be indicated approximately by taking the mid point of a line drawn across the vertex from the centre of one external auditory meatus to the other.

Posteriorly the parietals form with the occipital bone the *lambdoidal suture*, the apex of which is called the *LAMBDA*. It is generally palpable, but its exact position may be difficult to define, owing to the frequent presence of a large Wormian

bone at this point, called the *os epactal* or *preinterparietal bone*. The lambda lies about $2\frac{1}{2}$ inches above the external occipital protuberance, and indicates the position of the posterior fontanelle. When the os epactal is present, its lower border indicates fairly exactly the most prominent part of the skull posteriorly.

The external occipital protuberance is called the INION, and it should be noted that it does not form the most prominent point of the skull posteriorly, but lies distinctly below that point.

The middle of the fronto-nasal suture is called the NASION, and is easily located at the root of the nose. The point of articulation of the antero-inferior angle of the parietal with the sphenoid is called the PTERION, and is indicated by taking a point $1\frac{1}{4}$ inches behind and $\frac{1}{4}$ inch above the most prominent point of the external angular process of the frontal. The frontal and temporal bones also articulate here, the sutures forming together a rough capital H. The MEATAL OF AURICULAR POINT is the centre of the external auditory meatus. The PREAURICULAR POINT is situated immediately above the zygoma and in front of the tragus.

The point of junction of parietal, mastoid, and occipital bones is called the ASTERION, and lies $1\frac{1}{2}$ inches behind and 1 inch above the auricular point.

The GLABELLA is a point midway between the two superciliary ridges, and the VERTEX is the summit of the cranial vault—a variable point.

In addition to the normal cranial sutures, a *fœtal suture* may persist, and cause error in diagnosis. The most common of these is one extending up from the foramen magnum toward the external occipital protuberance, which normally is closed by the fifth month of intra-uterine life. This is the most common site of *cranial meningocele*, or protrusion of the cerebral membranes, the next most common position being through the fronto-nasal suture. In addition to the *occipital suture* mentioned, which may extend through the whole length of the occiput, the expanded portion of the occiput is divided into four pieces at birth by two lateral fissures running into the protuberance. These may persist and be mistaken for fractures, and it is well to remember that the portion of occiput above these fissures is developed from

membrane, and the portion below from cartilage. Fissures may also persist in the posterior portions of the *parietals* (the small portion of the parietal bone so separated being called an interparietal bone), and if bilateral and joined may present a *sagittal fontanelle*.

Of much importance to the surgeon is the power of locating the principal cerebral centres and bloodvessels by means of external measurements. A simple method of locating the *Rolandic fissure*, around which the chief motor areas are grouped, is to take a point $\frac{1}{2}$ inch behind the mid-point between nasion andinion, and from it draw a line down and forwards at an angle of $67\frac{1}{2}$ degrees (three-quarters of a right angle) till it meets the Sylvian fissure. The position of the *Sylvian fissure* is indicated by drawing a line upwards and backwards from the pterion to a point $\frac{3}{4}$ inch below the parietal eminence, and the *parietal eminence* lies at the junction of the upper and middle thirds of a line drawn from a point $\frac{1}{2}$ inch behind the mid-point between nasion andinion to the auricular point. The *short ascending limb of the Sylvian fissure* is indicated by a line $\frac{3}{4}$ inch long, running upwards and slightly forwards from the pterion. A line drawn from the nasion to the inion gives the position of the *longitudinal fissure* of the brain. The *longitudinal sinus* runs along this line, slightly to the right side. The *lateral sinus* is represented by a line drawn from a point $\frac{1}{2}$ inch above the inion to the asterion. At this point the lateral sinus turns rather sharply down and forwards, forming the commencement of the sigmoid sinus, which is very variable in its exact position. In some cases the knee of the sinus comes to within $\frac{1}{4}$ inch of the external osseous meatus, while in others it may be $\frac{3}{4}$ inch behind it.

The trunk of the *middle meningeal artery* may be reached at a point $1\frac{1}{2}$ inches behind the external angular process of the frontal, and $\frac{3}{4}$ inch above the zygoma, while its anterior branch is reached at a point $\frac{3}{4}$ inch higher up.

The *supra-orbital notch* lies at the junction of the middle and inner thirds of the supra-orbital ridge, and is generally easily palpable. A line drawn down and outwards from it to the interval between the two bicuspid teeth of both jaws passes through the *infra-orbital foramen*, which is situated $\frac{1}{4}$ inch below the lower margin of the orbit, and, if prolonged,

indicates the position of the *mental foramen*, situated midway between the upper and lower borders of the ramus of the lower jaw. The position of the point of entrance of the *inferior dental nerve* into its canal on the inner side of the ramus of the lower jaw is got by taking the mid-point between zygoma and inferior border of lower jaw, and the mid-point between anterior and posterior borders of the ascending ramus.

The *facial artery* crosses the lower jaw about $\frac{1}{2}$ inch in front of the angle, at which point there is generally a slight depression in the bone, which forms the best guide to the vessel.

THE CRANIUM.

The **scalp** consists of the skin of the head, subcutaneous tissues, and occipito-frontalis muscle, these structures being intimately attached to one another by large numbers of small fibrous bands. The boundaries of the true scalp are, therefore, those of the occipito-frontalis muscle, which may be indicated on the surface by a line running from the middle point in front along the supra-orbital margin to the angular process of the frontal, thence slightly above the zygoma to the external auditory meatus, and so to the superior curved line of the occipital bone.

The succeeding layers consist of—(a) the so-called ‘dangerous area,’ consisting of a layer of loose areolar tissue; (b) the pericranium, or external periosteum of the skull; (c) the skull itself. The *skin* of the scalp is very thick, particularly over the occipital region, and is well supplied with sudoriparous and sebaceous glands, the latter giving rise to *sebaceous or atheromatous cysts* or wens through blockage of their ducts. These cysts are generally confined to the skin, not involving the subcutaneous structures, and in removing them it is important not to open the sac, nor to open into the dangerous area, as the contents are generally septic.

Owing to the very lax attachment of the occipito-frontalis to the underlying pericranium, or periosteum of the skull, by loose areolar tissue, it possesses a great degree of mobility, as is evidenced by the movement of the scalp as a whole when the brow is wrinkled. This freedom of movement has an effect in protecting the scalp from injury, and the looseness

of the attachment is also illustrated in avulsion of the scalp from the hair becoming caught in revolving machinery, and in scalping.

The scalp has a rich vascular and lymphatic supply. The ARTERIES run in an upward direction in the subcutaneous tissues, are tortuous, and anastomose freely. They arise

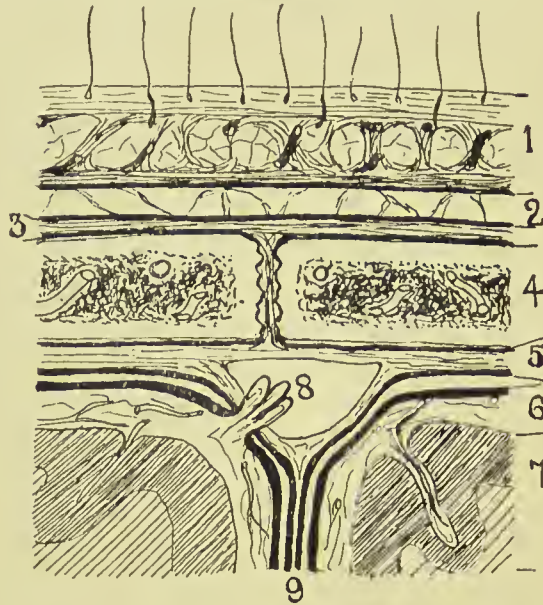


FIG. 2.—SCALP SECTION.

1. Scalp, composed of skin, dense cellular tissue, and occipito-frontalis aponeurosis. Fluid accumulations small and circumscribed.
2. Loose areolar layer. Fluid accumulations widely spread.
3. Pericranium, loosely attached to bone save at sutures. Fluid accumulations limited to one bone.
4. Bone of skull with vascular diploic tissue.
5. Dura mater, comparatively loosely attached save at sutures. Fluid accumulations may be considerable.
6. Pia-arachnoid, loose but very vascular. Fluid accumulations widely spread.
7. Brain matter with small end arteries. Fluid accumulations generally circumscribed.
8. Superior longitudinal sinus, formed by splitting of dura, and presenting a projecting Pacchionian body which communicates between the sinus and the subarachnoid space, and probably assists in regulating the amount of cerebro-spinal fluid.
9. Falx cerebri formed by a process of dura.

from frontal and supra-orbital branches of the ophthalmic of the internal carotid, and the superficial temporal, posterior auricular and occipital branches of the external carotid.

The *superficial temporal* artery may be reached through a vertical incision $\frac{1}{2}$ inch in front of the ear, and the *occipital*, which is generally the largest vessel of the scalp, through an incision passing obliquely backwards and upwards from behind the tip of the mastoid process.

Ligature of these vessels, and particularly of the temporal, may be required (apart from injuries) in the treatment of *circoid aneurysm*, which sometimes affects them. Owing, however, to the free anastomosis, this treatment is seldom successful. Where, from any reason, it is desirable to check the whole blood-supply of the scalp (as in operation on large *nævi*), a piece of rubber tubing may be tied tightly round the head at the level of the eyebrows in front and under the external occipital protuberance behind. Owing to the upward direction of the cranial vessels, one should, in cutting scalp flaps, make them with the convexity toward the vertex. While the arteries are comparatively free in the subcutaneous tissues, running in tunnelled spaces, the *veins* are rather adherent, and hence, when divided, tend to gape and give rise to free hæmorrhage. In operations on the scalp hæmorrhage, as just explained, is generally troublesome, and, owing to the very dense nature of the scalp itself, the vessels are frequently difficult to pick up with pressure forceps. Artery forceps may be employed for the more troublesome ones, and the others arrested by firm pressure applied for a few minutes.

The extreme vascularity of the scalp explains why wounds heal so rapidly, and why sloughing rarely occurs, even when portions are almost detached. In one rhinoplastic operation for the formation of a new nose a flap is taken down from the brow, the portion so detached being fed through its narrow pedicle by the small frontal artery.

The LYMPHATICS of a small central anterior portion of the brow and upper part of the nose drain to the submaxillary glands; the frontal and parietal regions in front of the ear drain to the preauricular; the parietal region over and for a short distance behind the ear drains to the postauricular; and the remainder to the occipital glands.

The NERVES supplying the scalp are the supratrochlear, supra-orbital (which may be cut for relief of neuralgia of scalp), auriculo-temporal, posterior auricular, and great occipital.

WOUNDS of the scalp do not gape, as a rule, unless the occipito-frontalis be divided in a transverse direction. They frequently present a sharply-cut appearance, even when produced by blows from blunt instruments, the scalp splitting over the cranium as the outer coating of a cricket-ball sometimes does when struck by a flat bat. A close inspection of

such wounds produced by blunt instruments shows that the hair bulbs are not cut, but project from one edge of the wound ; and, further, nerve fibrils, and even vessels, may be seen stretching uncut across the deeper parts.

Owing to the dense structure of the scalp, large *effusions of fluid*, such as pus or blood, cannot occur in it. In many severe contusions, however, the scalp tissues are actually displaced and heaped up peripherally; while a considerable amount of blood is also effused. This effused blood clots more rapidly at the periphery than in the centre, and the peripheral portion is frequently so firm and sharply defined that, on running the fingers over it, and then dipping into the central soft portion, one is apt to think that a depressed fracture of the skull has occurred. When in doubt, firm pressure should be applied by the finger for a short time over the raised area. If due to blood-clot, it will be dispersed by the pressure, whereas fracture is rendered more prominent.

Effusions of fluid in the loose AREOLAR TISSUE lying under the occipito-frontalis, on the other hand, are only limited by the insertions of the occipito-frontalis muscle anteriorly and posteriorly, while laterally they may extend downwards over the temporal fascia to near the zygoma. This region, then, is known as the *dangerous area of the scalp*, and particularly where there is reason to fear that it has been opened into by a septic scalp wound should the wound be treated by packing, allowing it to granulate from the bottom. It should be noted that the occipito-frontalis is practically continuous in front with the pyramidalis nasi, corrugator supercilii, and orbicularis palpebrarum, and hence effusions readily extend into the tissues of the eyelid and nose from under the occipito-frontalis.

The PERICRANIUM forms a rather loose covering for the bones of the skull, save at the sutures, where it dips in between them and is firmly adherent. Effusions of fluid under the pericranium are therefore generally confined to a single bone.

Cephalhæmatoma, an effusion of blood under the pericranium of the parietals, is generally due to pressure or injury during labour (see also Extra- and Subdural Hæmorrhage).

Stripping of the pericranium is not generally a matter of much moment, as the bones of the skull derive their chief blood-supply from the diploic vessels.

Temporal Region.—Over the temporal region the aponeurosis of the occipito-frontalis becomes very attenuated, losing itself gradually as it approaches the zygoma by numerous small insertions into the temporal fascia. It also sends some prolongations into the subcutaneous tissues, but in this region the aponeurosis is not nearly so intimately associated with the subcutaneous tissues as in the scalp proper.

The *temporal muscle* takes origin from, and is covered in by, the *temporal fascia*, which arises from the temporal ridge and runs down to be inserted into the zygoma, splitting as it does so to enclose branches of the temporal and orbital arteries, embedded in fat. The fascia is remarkably strong and dense, so as to be practically indistinguishable from bone on palpation. Were an abscess occurring in the temporal region, this fascia would tend to prevent its pointing locally, and would direct it under the zygoma, whence it may extend even to the neck.

The pericranium in this region is much more adherent than it is over the vault, and hence subpericranial hæmatomas are very unlikely to occur.

The *bones* composing the **cranial vault** are developed in membrane, possess few osteoblasts, and have but little healing power. Thus, after destruction of a portion of the vault, it is unusual to find repair by osseous tissue, the bone generally being replaced by fibrous tissue.

Necrosis most often affects the frontal and parietal bones, and not infrequently the external table alone is affected. Extensive destruction of the anterior portion of the vault is sometimes due to syphilitic ulceration, the dura presenting at the bottom of the ulcer. Craniotabes is a condition met with in early life, affecting generally the parieto-occipital region, due to rickets or inherited syphilis, in which the bone becomes thin and parchment-like.

The *inner table* of the skull is thinner and more brittle than the outer, and in fractures or gun-shot wounds involving both tables is generally much more extensively shattered than the outer. In some cases where a rifle-bullet strikes the skull tangentially, cutting a groove in the external table, the inner, although apparently not directly implicated, has been shattered over a considerable area and driven into the brain substance. Sometimes also, as the result of injury, the inner

table may be fractured without evidence of fracture affecting the outer table. The inner table is grooved by the sinuses and the Pacchionian bodies, and also by the middle meningeal artery. In some cases the artery is actually embedded in the bone, and is then particularly liable to injury from fracture.

The *diploic tissue* between the two tables is very vascular, most of the blood being derived from the meningeal vessels. The return flow of venous blood is chiefly directed through the *diploic veins* toward the great sinuses, but a portion is carried by emissary veins to the superficial blood channels, which thus bring superficial and deep systems into direct communication. Other emissary veins run directly from the sinuses to the superficial veins.

These **emissary veins** are of great importance surgically, as they afford access for pyogenic organisms to the sinuses and meninges from superficial affections at these parts. The most important are: (a) Mastoid, which runs from the sigmoid sinus to the posterior auricular or occipital veins through the *mastoid foramen*; (b) parietal, from the superior longitudinal sinus to the scalp veins through the *parietal foramen*; (c) superior orbital, communicating with the ophthalmic and facial frontal diploic veins; (d) vein of foramen cæcum, connecting those of the nasal mucous membrane with superior longitudinal sinus; (e) veins from cavernous sinus through the foramen ovale; (f) veins from the lateral sinus through the postcondylar foramen, etc., to deep occipital veins; (g) numerous small vessels running from inside to outside of the skull through the sutures; (h) frontal, nasal, and angular veins, with the cavernous sinus, through the ophthalmic veins.

The skull varies greatly in thickness—not only in different individuals, but also at different parts—a point which must be kept in mind when trephining. Speaking generally, it is thickest over the frontal and occipital regions, attaining a maximum at the posterior occipital protuberance, and is thinnest over the squamous portion of the temporal.

The *frontal sinuses* are formed at the expense of the diploic tissue, which is absent at these places, while the tables are wide apart. They vary much in size in different individuals, and are generally larger in males. The septum between them is frequently displaced to one side or other, and sometimes only one sinus may exist, or they may be altogether absent.

They can generally be examined in a darkened room by transillumination from a lamp in the mouth. When normal, they are fairly translucent, as a rule, whereas they become opaque when filled with pus.

The *cranial sutures* are of importance surgically, as their arrangement, interdigitation, and complicated structure, while producing practically a single bone, yet do much in conjunction with the elasticity of the bones themselves to modify fracturing forces. At birth the persistence of the *anterior fontanelle* (which normally closes by the second year) increases the adaptability of the head. The *posterior fontanelle* normally closes before birth. Separation at the sutures rarely occurs apart from fracture save in early youth, but a few cases of separation at the squamous suture have occurred. The coronal and sagittal sutures have been most frequently affected by fracture. The skull also possesses a series of buttresses, by which the force of blows is transmitted and diffused, thereby minimizing the chances of fracture. Sometimes, however, a blow struck upon a strong, unyielding bone, such as the occipital, may be transmitted to a weak bone—*e.g.*, the orbital plate of the frontal—with such force as to fracture it, the bone struck remaining intact (fracture by contre-coup). In old persons the sutures tend to disappear, synostosis occurring, while the bones themselves lose their elasticity to a great extent, fracture of the skull being then more easily produced.

The *Wormian bones*, or *ossa triquetra*, occur chiefly about the lambdoidal suture. Generally few in number and symmetrical, they may form a regular chain, and in cases of hydrocephalus are present in large numbers, and attain a large size. The os epactal at the apex of the occipital has already been referred to. They are occasionally met with about the lachrymal bones and outer extremity of the sphenomaxillary fissure, and one frequently occurs about the antero-inferior angle of the parietal, in the region of the pterion, which is called the *epipteric* bone, is scale-like, and may suggest a separation of the tip of the great wing of the sphenoid.

FRACTURES OF THE VAULT of the skull are generally due to direct violence. Where the blow is struck on the frontal region, the force is transmitted to the parietals upon which the posterior part of the frontal rests, and these deal with it as follows. When the parietal region is injured, the force

tends to drive the upper borders of the bone inwards, and therefore the lower borders outwards. This latter movement is resisted by the overlapping of the great wing of the sphenoid and squamous bone. From the latter it is transmitted by the zygoma to the superior maxilla and frontal bone, and patients frequently complain of pain in the face after receiving such injuries. The occiput is not similarly provided with means of dissipating the force of blows applied to it, and is generally more readily fractured.

The **base of the skull**, developed from cartilage, is of much more varying thickness than the vault. The bones do not interdigitate as those of the vault do, and they are pierced by numerous foramina.

The **ANTERIOR FOSSA** lies at a considerably higher level than the other fossæ. The bone constituting its base is extremely thin, and, forming as it does the roof of the orbital and nasal cavities, is easily fractured by instruments thrust into them. Such fractures are dangerous—not so much from probable damage to the anterior lobes of the brain, as from the great liability to entrance of organisms to the meninges and brain. Sometimes in nasal injuries affecting the ethmoid the anterior end of the longitudinal sinus may be torn, torrents of blood escaping with a hissing noise through the dilated nostrils. Where the nasal mucous membrane is torn in fracture of the anterior fossa, bleeding from the nose occurs, and if mucous membrane, bone, and dura are all ruptured, cerebro-spinal fluid may escape. Where the orbital plate of the frontal is broken, subconjunctival ecchymosis generally appears a few days after the accident, travelling from behind forwards, and in severe cases proptosis may occur. The anterior fossa lodges the frontal lobes of the cerebrum.

The **MIDDLE FOSSA** is situated at a considerably lower level than the anterior, and, viewed from above, is like a triangular box, the base of which, directed toward the surface, is covered by the squamous of the temporal and a small portion of the sphenoid, while the apex is formed by the sella turcica, the anterior wall by the great wing of the sphenoid, and the posterior wall by the petrous of the temporal.

The middle fossa contains the temporo-sphenoidal lobe of the brain, and its enclosing form is of importance as thereby the pressure caused by temporo-sphenoidal abscess is directed

upwards to the motor cortex, and especially the face centre. Lodged at the apex of the triangle, in a depression on the anterior surface of the petrous and enclosed in a fold of dura mater, lies the GASSERIAN GANGLION.

Almost immediately under the ganglion lies the internal carotid artery, passing down to the foramen lacerum medium, while under it again lies the cartilaginous extremity of the Eustachian tube. This relationship may be a cause of the inflammatory conditions sometimes found affecting the dural sheath of the Gasserian ganglion, and giving rise to a terrible form of trigeminal neuralgia, which can only be relieved by removal of the ganglion. The ganglion sends off the three branches of the fifth nerve; the first, or ophthalmic, passing along with the third, fourth, and sixth nerves, and the ophthalmic vein through the sphenoidal fissure; the second, or superior maxillary, through the foramen rotundum; and the third, or inferior maxillary, along with the small meningeal artery, through the foramen ovale. The ganglion is most easily and safely reached by making an osteoplastic flap of cheek and anterior wall of antrum of Highmore, following the inferior orbital nerve back through the sphenomaxillary fossa to the foramen rotundum, laying the foramen rotundum and the foramen ovale into one by means of a bur, and then incising the bulging dural pouch in which the ganglion lies, and twisting out the ganglion by means of the two great trunks. Thus the subdural space is not opened into, nor the brain exposed (Macewen). In the posterior or petrous wall of the middle fossa lie the middle ear, mastoid antrum, etc., and, as the wall of bone separating these structures from the middle fossa is very thin, disease spreads readily from them to the meninges and the temporo-sphenoidal lobe.

Entering the fossa at the *foramen spinosum*, a little external to the foramen ovale is the MIDDLE MENINGEAL artery, which runs first outwards and then, divided into anterior and posterior branches, upwards over the external wall of the fossa, which is grooved, and sometimes tunnelled, to receive it. Owing to its intimate relations with the bone, this artery is not infrequently torn in cases of fracture of these parts, causing extensive extradural hæmorrhage, and compression of the brain.

The crests of the ridges forming the triangular fossa are

occupied by sinuses. These *intracranial sinuses* are formed by a splitting of the dura mater, and have a triangular section, with rounded base. Anteriorly, running along the sphenoidal crest is the small and unimportant *sphenoparietal sinus*; internally the apex is occupied by the large and very important *cavernous sinus* which, with the internal carotid artery, lies in a groove on the body of the sphenoid. The two cavernous sinuses are intimately connected by means of the *circular sinus*. Posteriorly, connecting the cavernous with the knee of the lateral sinus is the *superior petrosal sinus*, running along the petrous crest. It is not a large sinus, and is not so important as the inferior petrosal.

The POSTERIOR FOSSA, viewed bilaterally, is roughly triangular in shape, with a rounded base. It is covered in by the arched *tentorium*, save at the apex, where there is an oval opening in the tentorium for the passage of the mesencephalon. The occipital lobes rest upon the upper surface of the tentorium, while within the fossa the cerebellum, medulla, and portions of all the cranial nerves, except the first three, are contained. The posterior fossa may thus be compared to a shut box, the tentorium forming the lid, and it can be readily understood why pressure, as from abscess, occurring in this fossa has a rapid and general effect upon the cerebellum.

The *cerebellum* is not, as is generally stated, entirely confined to the posterior fossa. On the contrary, its lower extremity enfolding the medulla frequently passes down through the foramen magnum, to terminate opposite the atlas, or even the axis (see plate). The tentorium splits at its bony insertions to form posteriorly the large *lateral sinuses*, and anteriorly the superior petrosal sinuses. Emerging antero-laterally from the posterior surface of the petrous are the seventh and eighth nerves, and it is by the sheaths of these nerves that pyogenic mischief is frequently carried from the middle and internal ear to the meninges, causing generalized meningitis. Running from the posterior end of the cavernous sinus down to the jugular bulb is the *inferior petrosal sinus*.

While FRACTURE OF THE BASE of the skull may be due to either direct or indirect violence, it most frequently occurs by extension from the vault. The fracture may involve the anterior, middle, or posterior fossa, and the symptoms differ according to the fossa involved.

In FRACTURE OF THE ANTERIOR FOSSA there is generally bleeding from the nose, as already described ; proptosis of the eyeball from accumulation of blood behind it, with the subjective sensation of flashes of light from irritation of the optic nerve ; effusion of blood into the conjunctiva, and later

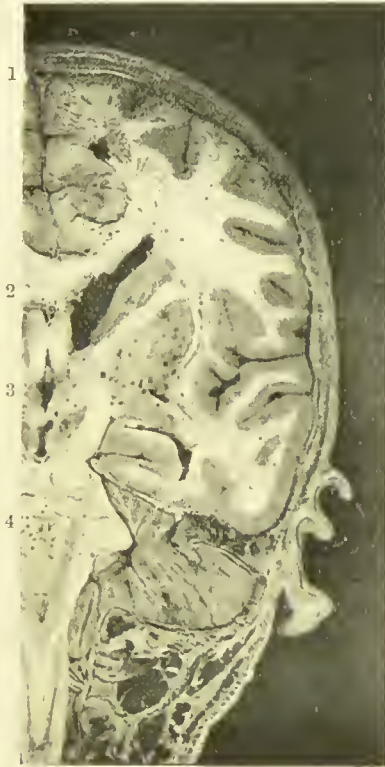


FIG. 3.—CORONAL HEAD SECTION PASSING THROUGH PORTION OF THE SPINAL CANAL.

Note opposite 1 the superior longitudinal sinus and the falx cerebri extending vertically downwards from it. At 2, the corpus callosum, and beyond it the lateral ventricle (dilated) with the optic thalamus projecting into its outer side. Opposite 3, the third ventricle, and beyond it the internal capsule (white), lenticular nucleus, external capsule (white), claustrum, and then the surface of the island of Reil enveloped by the parietal and temporo-sphenoidal lobes. Opposite 4, the pons and portion of the middle cerebellar peduncle, and below it the medulla, cord, and upper spinal nerves. Beyond the pons, the cerebellum roofed in by tentorium. Note how the cerebellum projects down through the foramen magnum, enveloping the medulla.

into the eyelids, coming on some time after the injury. The speech centre may be affected in left-sided lesions, and occasionally the face centre is involved.

In FRACTURE OF THE MIDDLE FOSSA there is generally bleeding from the ear, the membrana having been ruptured ;

but occasionally the blood may pass down the Eustachian tube and be swallowed, and, if subsequently vomited, may lead one to suspect internal injuries. Where the dura is ruptured, escape of cerebro-spinal fluid by the ear is frequently met with, the fluid in some cases finding its way into the middle ear through a fracture of the tympanic attic, and in others coming along the sheaths of the seventh and eighth nerves where the internal ear is involved. While a hernia cerebri might possibly protrude through the ear, it certainly is of very rare occurrence. Facial paralysis from involvement of the facial nerve is common, and deafness from involvement of the eighth nerve is less so. Pharyngeal ecchymosis frequently appears within a few days of the accident.

In FRACTURE OF THE POSTERIOR FOSSA the movements of the tongue and of swallowing are generally impaired, owing to involvement of the ninth nerve about the jugular foramen, or the twelfth about the anterior condyloid foramen, while ecchymosis over the mastoid and posterior triangle of the neck appears some days after the injury, the same region being tender to pressure.

The Cerebral Membranes.—The brain is generally described as having three coverings—the dura, arachnoid, and pia mater. Surgically speaking, the pia and arachnoid are one over the greater part of their extent, and may be treated together.

The DURA MATER lines the entire cavity of the cranium, and is continuous with the dura of the spine through the foramen magnum. It sends prolongations along the nerves—*e.g.*, the optic, to fuse with the sclerotic; the seventh and eighth nerves, to the internal ear. It is a tough fibrous membrane, which acts both as *internal periosteum* of the skull and as a covering for the brain. It is said to be the chief source of blood-supply to the skull, but in operations on the brain large osteoplastic flaps may be raised from the dura without untoward effect. Like all periosteum, of course, the dura mater has no bone-forming function, the function of a periosteum being to supply blood to the bone, and to act as a limiting membrane to the osteoblasts.

In cases where the skull has been damaged, the dura, from its tough, unyielding character, forms, along with the scalp, an excellent protection for the underlying brain. The dura is rather loosely adherent over the vault, a fact well seen in

raising osteoplastic flaps from it, but is more firmly attached over the base, and particularly over the petrous, sella turcica, and cribriform plate, fractures of these parts being generally associated with tearing of the dura. It is more adherent to the vault during infancy and old age, and frequently becomes firmly attached in pathological conditions. By means of its processes, the *falx cerebri* and *tentorium cerebelli*, it supports the brain, and limits the transmission of impulses received by injury from one part to another. It forms the great blood sinuses of the skull by splitting. The dura does not possess a true lymphatic system, and while it contains numerous lymphatic spaces, it does not readily yield a passage to purulent processes. EXTRADURAL ABSCESS, even when large, and causing considerable tension, frequently remains external to the dura, and does not give rise to leptomeningitis. Extradural abscess is sometimes caused by extension through the bone of septic mischief from scalp wounds. The pus may not involve either pia or brain, but partial destruction of the overlying bone may occur, toxins escape, and œdema of the overlying soft parts be caused, probably some considerable time after the primary wound has healed. This condition is known as 'Pott's puffy tumour.'

While EXTRADURAL HÆMORRHAGE is generally localized, it is often caused by rupture, from fracture, of the middle meningeal artery, and may then be of sufficient extent to cause death. The vessel lies in a groove, or even a tunnel, in the bone, and the anterior branch is the one most often affected. The effused blood separates the dura from the cranium, and causes pressure on the brain, while the vessel remains within its osseous canal. The artery has been torn by blows without fracture of the skull. In all such cases it is important to remember that unconsciousness often comes on gradually, the patient being able to speak intelligently and walk about for perhaps an hour or so after the accident. The dura is separated from the pia arachnoid by a slight space—the *subdural space*—which contains cerebro-spinal fluid.

The **pia arachnoid** may be considered surgically as a single flocculent membrane. The arachnoid portion does not dip down into the sulci and is smooth on its dural aspect, while it is intimately connected with the pia underneath by a fine filamentous structure whose interstices are filled with cerebro-

spinal fluid, forming the SUBARACHNOID SPACE. In most places this space is insignificant, but particularly at the base of the brain it expands greatly, forming the WATER-BED of the brain. This bed is of great importance surgically, as it prevents the brain, in severe injuries, from being impacted against the base of the skull. It extends forwards as far as the optic nerves, the largest spaces being the *cisterna pontis*, under the pons and medulla, and *cisterna magna*, between the roof of the fourth ventricle and under surface of the cerebellum. The frontal lobes, resting on the anterior fossa, do not possess this support, and thus are not infrequently lacerated by injury.

The PIA MATER is a delicate membrane which supports a rich vascular network for the supply of the brain, the whole being floated by the cerebro-spinal fluid. The pia may thus be regarded as the blood-supplying covering of the brain, just as the dura supplies the skull. The pia not only dips down into the sulci, and turns in at the transverse fissure to form the *velum interpositum* and *choroid plexuses*, but also sends prolongations along the cerebral vessels into the brain (perivascular sheaths), so that it is easy to understand how a degree of encephalitis must almost certainly accompany leptomeningitis.

The pia, like the dura, is continuous with that of the cord, and similarly sends prolongations along the cranial and spinal nerves.

The continuity of cerebro-spinal fluid between the outside and inside of the brain and the cord is of importance. When the brain expands, as it does at each cardiac impulse, fluid is forced from the cranial cavity to the spinal portion, and returns on diastole, the pressure being thus kept constant. In congested conditions of the ganglia also fluid would be displaced through the foramen of Magendie and other communications, and equilibrium thus restored.

SUBDURAL HÆMORRHAGE, unlike the extradural variety, is often very extensive, extending both above and below the arachnoid, and sometimes even to the cord. It may arise from rupture of the vessels of the pia arachnoid, or, if the dura be torn, may extend from either the middle meningeal artery or from one of the sinuses, such as the superior longitudinal, cavernous or, lateral. Even after blood has clotted

in the subdural space, it may slip from its position, which perhaps was over the vertex, and cause death by pressure on the medulla.

MENINGITIS, or inflammation of the cerebral membranes, may affect the dura mater (pachymeningitis) or the pia arachnoid (leptomeningitis). Pachymeningitis is generally due to pyogenic organisms, and, if not accompanied by leptomeningitis, is generally localized. Leptomeningitis, when due to pyogenic organisms, is generally diffuse, often extending along the membranes of the cord, and accompanied by a degree of encephalitis. Pyogenic infection of the cerebral membranes may arise from many causes, notably middle-ear disease. Tubercle is generally conveyed by the blood-stream, and involves the pia mater, particularly at the base of the brain and along the Sylvian fissure.

A congenital protrusion of the membranes, or *meningocele*, occurs most frequently posteriorly, through the occiput, and less frequently at the root of the nose. When accompanied by brain matter it is called a *meningo-encephalocele* or *encephalocele*, and when the protruded portion is distended by ventricular fluid it is called *hydrencephalocele*.

THE BRAIN.

Of importance to the surgeon is a knowledge of the location of the principal brain centres and their relation to the surface of the head. If two parallel lines be drawn from the nasion in front to a position $\frac{1}{2}$ inch above the superior curved line of the occiput behind, one $\frac{1}{2}$ inch to the right and the other $\frac{1}{4}$ inch to the left of the middle line, they will represent the *inner margins* of the right and left cerebral hemispheres, while the space between them is occupied by the *superior longitudinal sinus*, which enlarges as it passes back and lies rather to the right of the middle line, owing to the greater size of the left hemisphere. A line drawn from the nasion in front to the external angular process of the frontal with an upward convexity fully $\frac{1}{4}$ inch above the orbital margin, thence carried backwards along the upper border of the zygoma to the pre-auricular point, and from that to the external occipital protuberance, will roughly indicate the *inferior margin of the cerebrum*. A line drawn from the nasion to the inion (naso-

iniac line), and divided into four equal parts, will represent the position of the PARIETO-OCCIPITAL SUTURE at the junction of its third and fourth quarters. The POSTERIOR HORIZONTAL LIMB OF THE SYLVIAN FISSURE will be represented by the anterior half of a line drawn from the pterion to the parieto-occipital suture, while the SHORT ANTERIOR HORIZONTAL ($\frac{1}{2}$ inch long) and VERTICAL ($\frac{3}{4}$ inch long) processes of the Sylvian fissure run from the pterion in the directions indicated by their names. The position of the FISSURE OF ROLANDO is indicated by a line commencing $\frac{1}{2}$ inch behind the mid-point of the naso-iniac line, and running down and forwards at an angle of $67\frac{1}{2}$ degrees (three-quarters of a right angle) to meet the Sylvian line.

The **frontal portion** of the cerebrum is bounded centrally and inferiorly by the lines already given, while posteriorly it is bounded by the Rolandic fissure.

It consists of superior, middle, and inferior convolutions, and also of a precentral convolution, which is about $\frac{3}{4}$ inch broad, and is bounded in front by the precentral sulci, which run parallel to the Rolandic fissure. The third or inferior left frontal convolution—Broca's lobe—contains the MOTOR SPEECH AREA, and would be indicated on the surface by a point nearly an inch in front of the Rolandic area, and slightly below the temporal ridge. It lies between the anterior and the ascending limbs of the Sylvian fissure. The PRECENTRAL CONVOLUTION is the most important motor area of the brain, and, according to Sherrington, contains all the centres previously attributed to the posterior central convolution. This motor area occupies practically the whole length and breadth of the precentral convolution, and extends into the depth of the Rolandic fissure. Whether the posterior central convolution (belonging to the parietal region) is also involved is at present uncertain. The area for the *lower limb* occupies the region of the upper third of the Rolandic fissure, and also dips superiorly into the longitudinal fissure. The area for the *upper limb* occupies the region of the middle third of the Rolandic fissure, while the area for the *face* occupies the lower third.

The fissure of Sylvius separates the lower end of the Rolandic area from the temporal lobe, and as the latter is frequently affected by cerebral abscess, the pressure from which

is directed chiefly upwards, it follows that the face centre is frequently affected in such cases (causing an incomplete paralysis of the face on the opposite side), whereas the arm is rarely, and the leg is practically never, affected. Further, it should be noted that the face is first affected, and the leg, if affected at all, last, the affection coming on gradually (compare with internal capsule).

The **parietal lobe** extends from the longitudinal fissure above to the Sylvian fissure below, and is bounded in front by the Rolandic fissure and behind by a line drawn from the position of the parieto-occipital fissure to the asteric point (parieto-mastoid line). It presents the posterior central convolution, bounded posteriorly by the posterior central sulci, which are parallel to and $\frac{3}{4}$ inch behind the Rolandic fissure. It also presents a superior parietal lobule and superior marginal and angular convolutions. The latter is supposed to contain the *word-seeing centre*, and lies just behind and above the posterior extremity of the Sylvian line.

The **temporal lobe** is limited above by the Sylvian fissure, below by the line indicating the lower level of the brain. It extends anteriorly to about $\frac{3}{4}$ inch from the outer margin of the orbit, while posteriorly it is bounded by the lower portion of the parieto-mastoid line. It presents superior, middle, and inferior convolutions, the two former separated by the parallel fissure, and the latter lying over the thin tegmina of the middle ear and mastoid, and being frequently infected by pyogenic invasion through these thin plates of bone. As the temporal lobe is limited anteriorly, posteriorly, and externally by bone, the pressure of an abscess must be directed upwards and inwards. The upward pressure affects the motor area of the face, while the inward pressure affects the third nerve, causing first irritation (contraction of pupil on same side), and later paralysis (dilatation of pupil on same side) of the nerve. The central portion of the superior temporal convolution is supposed to contain the *word-hearing centre*.

The **occipital lobe** lies posterior to the *parieto-occipital fissure*, but is not sharply demarcated from the parietal and temporal lobes, which merge with it. It presents superior, middle, and inferior convolutions. The line from the pre-auricular point to the external occipital protuberance indi-

cates posteriorly the position of separation between cerebrum and cerebellum by the tentorium, and of the lateral sinus, which is formed by a splitting of the dural processes which form the tentorium.

The **cerebellum** occupies a strictly limited space between the tentorium and the containing bone, and hence, when affected by abscess, and even by tumour, is unable to accommodate the increased mass, the pain in such conditions being generally very intense, owing to pressure. Further, as there is no septum between the two halves of the cerebellum, it is generally difficult to determine the side occupied by a lesion by the symptoms alone, the pressure being diffused over both sides. Where the cerebellum is affected by *abscess*, this most often has arisen from the mastoid region, and the treatment necessitates a thorough opening up of the mastoid, exposing, and, if necessary, ablating the sigmoid sinus to prevent dissemination of the septic matter within it, and then, by cutting the bone still further backwards, exposing and opening the cerebellar fossa and evacuating the abscess. Tumour of the cerebellum may be reached by an incision under the external occipital protuberance, shelling the muscles (the parts generally bleeding freely), and then either trephining or cutting a bone flap, and finally opening the cerebellar dura.

The **island of Reil** lies at the bottom of the posterior horizontal limb of the Sylvian fissure, and is thus closely related to the frontal, parietal, and temporal lobes by which it is enveloped. A short distance under its surface, and conforming to it, is a thin plane of grey matter, the *claustrum*; then follows a thin plane of white matter, called the *external capsule*; and then comes the lenticular nucleus. The *lenticular nucleus* corresponds in extent with the island of Reil, and lies nearly $\frac{1}{2}$ inch from its surface. Its internal surface is more convex than its external (the convexity being directed inwards), and forms the outer boundary of the internal capsule. The **INTERNAL CAPSULE** in horizontal sections is bent at the junction of its anterior and middle thirds, the bend or genu conforming to the most prominent part of the lenticular nucleus, while on the inner side the anterior limb is bounded by the caudate nucleus and the posterior limb by the optic thalamus. Surgically the anterior half of the posterior limb (middle third of whole and not 1 inch long in horizontal

section), which lies about 1 inch from the surface of the island of Reil, is of most importance, as it contains the fibres descending from the motor area of the cortex. Lying close to the genu are the fibres going to the facial nucleus, then come some going to the hypoglossal nucleus, and further back are the fibres going to the pyramidal tracts, which influence the motor cells in the anterior cornua of the cord for the supply of the limbs. Those fibres which supply the arm lie in front of those supplying the leg. The remainder of the capsule is occupied by sensory and communicating fibres. (According to Dr. Foster, fibres for the eye and head lie even anterior to the genu.)

Owing to the crowding of the fibres in the internal capsule, a lesion about the genu, even a small hæmorrhage, produces an extensive result, *hemiplegia* or paralysis of the whole of the opposite side resulting, while a sensory disturbance generally accompanies it. The internal capsule is very rarely affected by pressure from temporo-sphenoidal abscess, but when it is, the paralysis generally affects first the leg and then, in rapid succession, the arm and face (compare with affection of motor cortex.)

The **basal ganglia** consist of (*a*) CORPORA STRIATA, composed of the caudate and lenticular nuclei, of which the former projects into the lateral ventricle, while the latter is extraventricular, lying to the outer side of the caudate nucleus and of the optic thalamus; (*b*) OPTIC THALAMI, the upper surfaces of which assist in the formation of the floor of the lateral ventricles, while parts are covered by the velum interpositum of the pia mater; (*c*) CLAUSTRA lying outside the lenticular nuclei; (*d*) CORPORA QUADRIGEMINA, CORPORA GENICULATA (internal), and PINEAL BODY, which are situated below the posterior extremity of the optic thalami, and rather internal to them, forming practically the posterior boundary of the third ventricle and the roof of the commencement of the aqueduct of Sylvius, which connects the third and fourth ventricles; (*e*) AMYGDALOID NUCLEI, which lie in the temporal lobes, in front and above the extremity of the descending horns of the lateral ventricles. Not only do these ganglia generally appear to be connected with the reception and transmission of impulses from and to the brain, but they also seem to exercise a semi-independent control of the more com-

plex reflexes and co-ordination of movement. The function of the corpora striata cannot be further defined. They are intimately associated with the optic thalami and with the cerebral cortex. The optic thalamus, especially its hinder portion, together with the external geniculate body situated at its posterior extremity, and the superior corpus of the quadrigemina, is intimately associated with sight. In addition, many afferent fibres pass through the thalamus from the tegmentum of the crus to the cortex, while others, also going to the cortex through the internal capsule, originate in the thalamus (thalamic radiation). The inferior corpora of the quadrigemina and also the internal corpora geniculata are connected with hearing.

The functions of the other nuclei are indefinite or unknown.

The body of the **lateral ventricle** is situated internal to the caudate nucleus, which forms part of its outer boundary and floor. The *corpus callosum* forms its roof, while it is separated from its neighbour of the opposite side by the posterior part of the septum lucidum and junction of corpus callosum with the fornix. From the body of the ventricle an *anterior horn* projects a short distance forwards and outwards, while posteriorly, at the splenium or posterior curled end of the corpus callosum, the *posterior* and *descending horns* diverge. The position of the divergence is represented on the surface by a point $\frac{1}{2}$ inch vertically above the external auditory meatus. The descending horn curves round the posterior extremity of the optic thalamus, and projects forwards and inwards along the temporal lobe toward the temporal pole. The *posterior horn* curves backwards and inwards into the occipital lobe. The bodies of the two lateral ventricles communicate anteriorly with the third ventricle, which lies beneath them, by the *foramina of Monro*, and hence with one another. The THIRD VENTRICLE communicates with the FOURTH VENTRICLE by the *aqueduct of Sylvius*, whence it becomes continuous with the central canal of the cord.

The lateral ventricles communicate directly with the sub-arachnoid space by means of the slit-like openings at the extremity of each descending horn, and indirectly by the foramen of Magendie and lateral recesses of the fourth ventricle.

The subarachnoid space is best developed on the under

surface of the medulla and the cerebellum, forming the water-bed, or cisterna magna; but the various spaces freely communicate with one another, with the spinal subarachnoid, and, by means of the Pacchionian bodies, with the longitudinal and other sinuses. Thus the ventricular system normally communicates freely with the subarachnoid system, and an equality of pressure is preserved. In HYDROCEPHALUS the ventricles of the brain become distended, sometimes to such an extent as to leave only a narrow rim of brain matter between them and the dura. The condition is supposed to be due to blocking of the foramina of Magendie and the other communications mentioned.

TAPPING OF THE VENTRICLES of the brain has been occasionally advocated in the treatment of hydrocephalus. Two horizontal lines, one 2 inches above and the other $\frac{1}{2}$ inch above, and both parallel to, the zygoma represent roughly the upper and lower limits of the cornua of the ventricles, while two vertical lines, the anterior through the junction of the anterior and middle third of the zygoma, and the other 2 inches behind the tip of the mastoid process, define the anterior and posterior limits. A permanent communication may be established between the ventricle and either the subarachnoid space or the subcutaneous tissues, and the distension thereby relieved.

In health the brain pulsates markedly when the dura is opened, and it is supposed that the subarachnoid system equalizes and distributes the pressure so caused. Not merely the cardiac, but also respiratory effects, can be traced, the latter being due to the arrest of the venous return from the brain during inspiration by the mechanism explained in connection with the sigmoid sinus. An abscess or tumour of the brain increases the *intracranial pressure*, even a small abscess, in its rapid growth, causing considerable disturbance, whereas a tumour, growing much more slowly, may attain considerable dimensions without producing marked effects, unless it be situated at a focal point. On opening the dura in such cases absence of pulsation is frequently marked at first, then the cerebral matter is gradually extruded through the opening, the pulsation becoming apparent as the extrusion proceeds with each cardiac impulse. Superficially placed tumours and encapsulated abscesses may occasionally be extruded

in this manner on opening the dura, and in most cases the pulsation assists the removal or evacuation of the pathological process. Tumours of the brain occasionally erode the cranial cavity and present externally as subcutaneous pulsating swellings.

Cerebral Circulation.—The MENINGEAL VESSELS are classified, according to the fossa they supply, into anterior, middle, and posterior meningeal sets. The anterior are derived from the ophthalmic artery, the posterior from the occipital and ascending pharyngeal of the external carotid, and from the vertebral, while the middle fossa is supplied by the only large vessel of the series, the middle meningeal. The *middle meningeal artery* is derived from the internal maxillary, and enters the skull through the foramen spinosum, whence it runs up and forwards, often lodged in a groove or even a canal in the bone, and divides into anterior and posterior branches. Rupture of this vessel, from fracture of the skull or possibly severe concussion, is the main source of extensive extradural hæmorrhage, the blood stripping the dura from the bone, and forming a large hæmatoma, which often causes compression, ending fatally. To arrest the hæmorrhage it is necessary to trephine the skull, taking care not to cut the vessel embedded in the bone in doing so. The trunk is reached at a point $\frac{3}{4}$ inch above the zygoma, the anterior branch $1\frac{1}{2}$ inches behind the external angular process of the frontal and $1\frac{1}{2}$ inches above the zygoma, and the posterior branch $1\frac{1}{2}$ inches above the external auditory meatus. Where the dura is torn, the hæmorrhage may become subdural, and is then generally extensive, sometimes causing pressure on the medulla.

As already mentioned, the **cerebral sinuses** are formed by a splitting of the dura mater, and present a triangular section, with rounded base. The SUPERIOR LONGITUDINAL SINUS is connected, at least in early life, with the veins of the nose, through the foramen cæcum, in front. As it runs backwards it lies slightly to the right of the middle line, and, gradually enlarging, receives tributaries which communicate with the scalp veins. It ends posteriorly by joining the lateral sinuses at the torcular Herophili. While septic infection does occasionally extend to this sinus through its communications, causing *septic thrombosis*,

it is more frequently the seat of *marasmic thrombosis*, such as occurs in weakly emaciated children. The frequency of the marasmic type is accounted for by the slow circulation in this sinus, due to (a) tributaries entering at an angle opposed to the direction of the current; (b) Pacchionian projections; (c) rapid enlargement of the sinus; (d) junction with the lateral sinus at right angles. While marasmic thrombosis occurs more frequently in *azygos sinuses*, such as this, septic thrombosis occurs most frequently in *dual sinuses*, such as the sigmoid. Nævi occurring along the middle line of the scalp not infrequently communicate with the sinus, and hence must be treated with caution.

The CAVERNOUS SINUS is so called from the fibrous strands which divide its interior, and commences by receiving the ophthalmic vein (whence sepsis may spread from the orbit), and ends by dividing into the superior and inferior petrosal sinuses, while it communicates with its neighbour through the CIRCULAR SINUS, so that thrombosis generally extends from one side to the other. In its outer wall are embedded the internal carotid artery, and the third, fourth, first division of the fifth, and sixth nerves.

The INFERIOR PETROSAL SINUS receives large quantities of blood from the cavernous sinus, the blood being pumped into it from the communicated pulsations of the internal carotid artery, which practically lies in the cavernous sinus. The vessel pursues an almost vertical downward course to join the jugular bulb. When wounded, bleeding from this sinus is very difficult to arrest.

The LATERAL SINUS runs first horizontally outwards from the torcular, and then, at its junction with the superior petrosal sinus, forms the sigmoid sinus. The right lateral sinus conveys most of the blood (brought by the longitudinal sinus) from the cortex, while the left lateral sinus conveys that brought by the straight sinus from the central ganglionic regions.

The SIGMOID SINUS pursues a tortuous course along the posterior wall of the petrous, and ends, after making an almost complete circle and forming the jugular bulb, in the internal jugular vein. The tortuous course, formation of the bulb which rests on a prominence of bone, and the comparatively narrow mouth of the jugular vein, are all factors in preventing

the aspiration of this and the other communicating sinuses on inspiration. As the sinuses are rigid channels, they would otherwise be easily aspirated by the suction action of inspiration, anæmia of the brain, with consequent unconsciousness, resulting. This does occur in some individuals in whom the bony prominence under the jugular bulb is wanting, when a long breath is taken suddenly. Normally, however, the flow is arrested during inspiration by the flattening of the bulb upon the bony projection, while the inferior petrosal sinus, acting as an injector, rapidly restarts the flow, once inspiration is at an end.

As the sigmoid sinus is in close relationship to the mastoid antrum, it frequently suffers from pyogenic thrombosis by extension of the septic process. Where the mastoid antrum is large, it sometimes extends under the sigmoid sinus, and comes directly into relationship with the cerebellum, cerebellar abscess thus occasionally arising from mastoid disease, without previous sigmoid sinus thrombosis.

The emissary mastoid vein leaves the sigmoid sinus just beyond its commencement, and not infrequently conveys septic mischief to it from the outside. The dome of the jugular bulb is situated directly under the middle ear.

The STRAIGHT SINUS runs along the junction of the falx with the tentorium, from the inferior longitudinal sinus to the left lateral sinus, near the torcular. It conveys blood from the inferior longitudinal sinus and also from the interior of the brain, brought to it by the veins of Galen, which emerge from under the corpus callosum. These veins are believed to take part in removing cerebro-spinal fluid from the ventricles of the brain, and hence obstruction of the veins may be a cause of hydrocephalus.

The brain derives its blood-supply from the vertebral and internal carotid arteries, after these have anastomosed at the CIRCLE OF WILLIS. This circle is formed posteriorly by the basilar (from junction of the two vertebrals), which gives off the two posterior cerebral arteries, which in turn supply the two posterior communicating branches of the circle, which join the internal carotids.

The internal carotids are continued up as the middle cerebral arteries, but give off anteriorly the anterior cerebral arteries, which communicate with each other through

the anterior communicating artery, thus completing the circle.

The anterior, middle, and posterior CEREBRAL VESSELS form a rich vascular network in the pia mater, which is a thick flocculent membrane enveloping the brain and dipping into the sulci. From it the cortical vessels run vertically into the brain, through the grey matter, to terminate in the white matter. These vessels do not anastomose, and are thus end arteries. The *middle cerebral* is of most importance, and runs in the fissure of Sylvius, giving off inner and outer striate branches to the lenticular and caudate nuclei and optic thalamus, all of which pass through the internal capsule. These vessels, in common with other small vessels supplying the internal nuclei, are frequently affected by arterio-sclerosis and *aneurysms*, which may be multiple (miliary aneurysms of Charcot), and one of the outer striate branches going to the caudate nucleus, which is larger than its neighbours, is a frequent source of cerebral hæmorrhage. The middle cerebral also supplies branches to the motor area (all but a small portion of the leg area supplied by the anterior cerebral) and the centres for hearing, motor speech, and part of that for vision. This vessel is the usual source of CEREBRAL HÆMORRHAGE, or apoplexy, generally from rupture of a small aneurysm. If small, the hæmorrhage forms a localized clot in the brain substance, while if large, it may extend over a large area of the surface, giving rise to compression, or may burst into the lateral ventricle.

Rupture of one of the striate branches generally affects the internal capsule, and in these cases, although the lesion may be small, the effect is generally a hemiplegia owing to the crowding of the motor fibres. *Cerebral embolism* is followed by softening of the brain substance, where the smaller central arteries are affected, but is less often complete when the vessels supplying the cortical area are affected owing to the pial anastomosis. Embolism has followed the manipulation and treatment of carotid aneurysm from detachment of clots, and where one of the large vessels is blocked paralysis or death may result. Owing to the free anastomosis of the cerebral vessels, it is possible to ligature both common carotids, with an interval of a few weeks between them, the circulation being carried on by the vertebrals.

The anastomosis, together with the markedly tortuous course of the large vessels and small size of the vessels entering the brain, diminishes the pulsation affecting the brain substance. The larger cerebral vessels have no companion veins, the blood being returned by the sinuses. The small superficial veins discharge their blood into the superior longitudinal, lateral, and cavernous sinuses, while the small, deep veins from the interior of the brain empty into the straight sinus.

The **mesencephalon** is about $\frac{3}{4}$ inch long, and occupies the aperture in the tentorium cerebelli connecting the cerebrum above with the pons, etc., below. It presents the corpora quadrigemina dorsally and the large CRURA CEREBRI ventrally, which gradually converge to enter the pons. Each crus is encircled by the optic tract at its point of emergence from the cerebrum. Each crus consists of a *tegmentum*, or dorsal portion, which contains sensory fibres running to the region of the optic thalamus, and a *crusta*, or ventral portion, which contains the motor fibres which have descended from the cortex through the corona radiata and internal capsule to reach it. Hæmorrhage into the crusta causes hemiplegia of the opposite side of the body, and, when on the inner margin, paralysis of the third nerve on the side of the lesion.

The **cerebellum** lies under the tentorium, which separates it from the under surface of the cerebrum, and behind the pons and medulla. It consists of two lateral hemispheres and a median portion, the vermis, and is also divided into upper and lower portions by the great horizontal fissure. It is composed of grey matter externally, and white matter internally, with several grey nuclei embedded in it. It is connected with the brain, pons, and medulla by three peduncles. The SUPERIOR PEDUNCLES contain efferent fibres, which extend upwards on the dorsum of the pons to the inferior quadrigeminal bodies. They converge as they ascend, forming first the lateral boundaries and later the roof of the fourth ventricle, and they are concealed from view by the overlapping cerebellum. The MIDDLE PEDUNCLES are the largest, and contain both afferent and efferent fibres, which connect the cerebellum with the pons. The INFERIOR PEDUNCLES also contain both afferent and efferent fibres, and consist of the restiform body of the medulla continued upwards over the pons and then turned backwards to the cerebellum. The direct cerebellar

tract forms the greater portion of the *afferent fibres* in the inferior peduncle, which cross chiefly to the opposite side of the cerebellar cortex. The *efferent fibres* of the inferior peduncle form the cerebello-olivary-tract, connecting the cerebellum with the medulla. The cerebellum is not always confined to the cranial cavity, but often extends through the foramen magnum, wrapping round the medulla and even the upper extremity of the cord.

The **pons** is situated between the crura cerebri and the medulla, its ventral surface being composed of the transverse fibres of the middle cerebellar peduncles, which sweep across it from side to side. This ventral surface lies in contact with the dorsum sellæ of the sphenoid and basilar process of the occipital bone, and presents a median groove, which lodges the basilar artery and two lateral eminences, due to the underlying masses of the pyramidal tract passing from the crura cerebri above to the medulla below. The fifth nerve emerges near its upper margin, while the sixth, seventh, and eight nerves emerge at its lower border. The dorsal aspect of the pons, together with that of the medulla, presents the lozenge-shaped **FOURTH VENTRICLE**, which is roofed in by the thin superior and inferior medullary vela, which proceed outwards from the white centre of the cerebellum, and run respectively up and down, covering the ventricle with a peaked roof. The inferior velum is deficient at its lower border, and presents an opening, the **FORAMEN OF MAGENDIE**, which permits of communication between the fourth ventricle and the subarachnoid space, similar openings occurring at the apices of the lateral recesses, which project laterally from the widest part of the space, and curve round the upper parts of the restiform bodies (*foramina of Key and Retzius*). The fourth nerves issue from the substance of the superior velum close to the inferior quadrigeminal bodies. The striæ acousticae cross the floor of the ventricle transversely, and make the distinction between the pontine and medullary portions, and possibly connect the cochlear nucleus with the cerebellum.

The **medulla** is about 1 inch long, conical in shape, being broader above, and connects the pons with the cord. In direction it is vertical, and it ends about the foramen magnum, the ventral surface lying on the basilar portion of the occipital bone, while the dorsal and lateral surfaces are largely covered

by the cerebellum. The median furrow on the ventral surface commences as a blind depression, the foramen cæcum, at the lower border of the pons, and ends at the decussation of the pyramids. The posterior median furrow commences about half-way down by the approximation of the boundaries of the fourth ventricle. From the antero-lateral furrow the root branches of the twelfth nerve emerge, while from the postero-lateral furrow emerge those of the ninth, tenth, and eleventh nerves. Between the anterior median and lateral furrows lies the *pyramid* containing the motor strands, which break up lower down into *direct* and *crossed pyramidal tracts*, the former going directly down the *anterior column* of the cord, while the latter crosses at the decussation of the pyramids, to enter the *crossed pyramidal tract* in the postero-lateral portion of the cord. The lateral surface of the medulla presents the *olive* lying outside the pyramid, which is formed by the underlying inferior olivary nucleus. The posterior surface presents the *funiculi gracilis* and *cuneatus*, in which the *columns of Goll and Burdach* respectively terminate in the *gracile* and *cuneate nuclei*. External to these lies the *tubercle of Rolando*, formed by the *substantia gelatinosa Rolandi*, which caps the posterior horn coming to the surface, while at the upper extremity of this posterior surface is the *restiform body*, which forms the inferior cerebellar peduncle, and in which the direct cerebellar tract runs to the cerebellum. The medulla contains the nuclei of all the cranial nerves after the fourth; the cardiac, respiratory, and vasomotor centres; those for vomiting, deglutition, etc.; those governing the sweat, lachrymal, and salivary secretions, and centres for winking and dilatation of the pupil.

The **cord** is partially divided by anterior and posterior median clefts, the former being generally much shallower and broader than the latter, and containing a fold of pia mater not presented by the latter. There is no antero-lateral sulcus along the line of emergence of the anterior nerve roots, but the postero-lateral sulcus from which the posterior roots emerge is marked. The columns of *Goll and Burdach* occupy the posterior surface between the median fissure and postero-lateral sulcus, the former placed internally to the latter, from which it is separated in the cervical region by the posterior paramedian groove containing a process of pia mater. The

grey matter in each half forms a crescentic mass with a blunt anterior and long posterior horns, the two halves being connected by a grey commissure containing the central canal, an anterior white commissure lying in front of the grey one. The anterior cornua contain the large multipolar nerve cells from which the motor nerves originate, and which form their trophic centres, just as the cells in the cortex govern the motor tracts in the cord. The posterior cornua receive the sensory fibres, which have already passed through a ganglion before entering the cord. *Clarke's column* consists of a cell group situated in the posterior horn of grey matter in the dorsal region. The *substantia gelatinosa Rolandi* is a V-shaped mass capping the posterior horn in the cervical and dorsal regions. The course of SENSORY FIBRES is doubtful. Probably many first enter Burdach's column and divide into a short descending and long ascending fibre. The latter is gradually displaced inwards by fibres from other nerves, until it enters Goll's column and ends ultimately in the medulla. Other fibres probably enter Clarke's column, possibly first crossing to the opposite side, whence fibres pass to the direct cerebellar tract and Gower's comma tract (two superficial tracts lying, the former postero-laterally, and the latter antero-laterally). The direct cerebellar tract runs to the cerebellum, while Gower's tract probably does likewise, after passing through the *formatio reticularis*. The sensory tracts, after passing through the medulla and pons, occupy the tegmentum of the crus, and the posterior third of the posterior limb of the internal capsule, and then pass to the cortex, particularly of the occipital region, through the corona radiata. The direct pyramidal tracts descend on either side of the median anterior fissure, while the crossed pyramidal tract lies in front of the posterior horn. The MOTOR TRACTS run from the cortex of the Rolandic area through the corona radiata, anterior two-thirds of the posterior limb of the internal capsule, crista of the crus, pons, and medulla, where most of the fibres cross to enter the crossed pyramidal tract, while a few go direct into the direct pyramidal tract.

Concussion of the brain consists of a molecular vibration of the brain substance, with or without laceration, but with multiple punctiform ecchymoses. The condition may be accompanied by grave symptoms at the time, or they may

only appear at a later period. Concussion is a frequent result of railway accidents.

Compression may be caused by depressed fracture, hæmorrhage, abscess, tumour, etc., and its effects will depend on the extent and location of the lesion.

Abscesses of the brain occur most frequently in the temporo-sphenoidal lobe or in the cerebellum, the infection being conveyed from the middle ear in many instances. It is noteworthy that cerebral abscesses are generally accompanied by low temperature and slow, full pulse, owing to the compression of the brain.

Of the *tumours* of the brain, tubercle, if it may be called a tumour, is the most common, the lesions occurring most frequently about the base, although they may occur at any part. Syphilomas occur not infrequently, while of true tumours *glioma* is the most common. Some gliomas present sarcomatous elements, and may ultimately erode and perforate the skull, and present on the surface as pulsating tumours. As tumours grow comparatively slowly, as a rule, the brain accommodates itself to the increasing pressure for a considerable period, pressure symptoms only becoming marked when the tumour is getting large. In such cases, even when, from size or location, removal of the tumour is out of the question, the raising of an osteoplastic skull flap, so as to relieve the pressure, is frequently followed by marked benefit. Where, on the other hand, the tumour has invaded some focal area, such as the motor cortex, the patient may be subject to fits of *Jacksonian epilepsy*, which differs from ordinary epilepsy in many important particulars, and which frequently affords valuable information as to the seat of the lesion, from the fit beginning in, and sometimes even being confined to, the part (*e.g.*, a thumb) supplied by the affected portion of cortex. In operating on intracranial tumours, it is usual, instead of trephining, to raise an osteoplastic flap of superficial soft tissues and bone in one piece, so as to expose a considerable surface. After the operation is finished, the osteoplastic flap is replaced.

THE CRANIAL NERVES.

The **olfactory** springs externally from the fissure of Sylvius, near the anterior perforated space. As it is close to the third frontal convolution, it follows that aphasia from affection of Broca's lobe on the left side may be associated with defective sensation of smell in the left nostril. The nerve may be completely destroyed by fracture of the anterior fossa or by malignant disease of the ethmoid, through the cribriform plate of which it passes to be distributed to the nasal mucous membrane.

The **optic nerve** arises from the geniculate bodies under the optic thalamus and corpora quadrigemina, the TRACTS winding over the crura cerebri and converging in front of the interpeduncular space to form the OPTIC COMMISSURE. Here the fibres of the tracts divide, the outer half of each continuing to the outer side of the corresponding retina, while the inner half crosses to supply the inner half of the opposite retina. Behind these fibres are others, which run from one tract to the other, and are known as *Gudden's commissure*. If, therefore, the entire thickness of one tract be affected by the pressure of a tumour, the temporal side of the eye on the same side and the nasal side of the opposite eye will be rendered blind (hemianopsia). If the OPTIC NERVE be pressed on, however, as by a tumour of the orbit, there will result complete blindness of both sides of the affected eye, probably associated with affections of the third, fourth, and sixth nerves, which lie close to it.

The **third nerve**, or motor oculi, arises in front of the pons, near the posterior perforated spot, lies on the outer wall of the cavernous sinus, and, dividing into two branches, enters the orbit through the sphenoidal fissure between the heads of the external rectus. The action of the third nerve is considered in connection with the eye. It affords from its action on the pupil, which becomes contracted when the nerve is irritated, and dilated when it is paralyzed, a very delicate test for *intracranial pressure* arising from tumour, hamorrhage, or abscess in the region of the middle fossa. A lesion near the Sylvian aqueduct might produce a bilateral paralysis of the nerves.

The **fourth nerve** emerges just behind the corpora quadri-

gemina. Its course is similar to that of the third, and its action is discussed with the eye.

The **fifth**, or **trigeminal**, arises from the surface of the pons by a small motor and large sensory portions. These proceed forward in the posterior fossa of the base, pierce the dura at the attachment of the tentorium cerebelli to the superior border of the petrous, the sensory root then forming the large GASSERIAN GANGLION, which is lodged in a small cavity of the dura, formed by a splitting of its layers, and called the *cavum Meckelii*. The ganglion lies in a depression on the apex of the petrous, and divides into its three branches—ophthalmic, superior, and inferior maxillary, the motor root joining the latter. The OPHTHALMIC DIVISION pursues a course similar to the third nerve, and breaks up into frontal, nasal, and lachrymal branches, the nasal branch supplying the sensory root to the LENTICULAR GANGLION, which ganglion supplies the short ciliary nerves to the ciliary muscle and iris. Destruction of this division not merely destroys reflex blinking, but removes the trophic influence of the nerve on the parts supplied, ulceration being apt to occur in consequence.

The SUPERIOR MAXILLARY DIVISION passes through the foramen rotundum, crosses the spheno-maxillary fossa, and runs under the floor of the orbit, to emerge at the infra-orbital foramen. It supplies the skin in the temporal and malar regions, and the teeth and gums, lining of the antrum, and sensory branch to Meckel's ganglion. MECKEL'S GANGLION supplies the nasal fossæ, roof of mouth, upper part of pharynx, tonsil, gums, soft palate, and uvula, etc. ; while by its motor branch, derived from the vidian, it enervates the levator palati, azygos uvulæ, palato-glossus, and pharyngeus.

The INFERIOR MAXILLARY DIVISION emerges through the foramen ovale, and divides into anterior and posterior trunks, of which the *anterior* is chiefly motor and supplies all the muscles of mastication except the buccinator (supplied by the seventh). The *posterior* trunk gives off the *auriculo-temporal*, which supplies that region with sensation, as well as the temporo-maxillary joint and parotid gland, and gives a sensory root to the *otic ganglion*, which supplies the tensors tympani and palati. The trunk also gives off the *gustatory nerve*, which supplies sensation to the anterior two-thirds of the tongue. It is joined in the pterygoid region by the

chorda tympani, through which probably taste fibres are derived, and later by branches of the hypoglossal. The *inferior dental* branch supplies the mylo-hyoid and anterior belly of the digastric, supplies sensation to the lower teeth, and gives off the mental branch, which emerges through the mental foramen to supply the skin of the lip and chin. Irritation of this nerve from dental caries may cause earache, while, conversely, placing cotton-wool with a little laudanum in the ear may ease toothache. The cold of an ether spray applied to the external auditory meatus may numb the nerve and enable a tooth to be extracted painlessly.

The Gasserian ganglion has frequently been removed successfully for intense trigeminal neuralgia. The neuralgia is believed to be due to contraction of the dural pocket, containing the ganglion, which is therefore crushed. The ganglion is best reached through the face, antrum of Highmore, sphenomaxillary fossa, and foramina rotundum and ovale (see under Middle Fossa of Skull), but may also be reached through the skull from above, or through the pterygoid region. Tic douloureux is a term frequently applied to trigeminal neuralgia, not necessarily involving all the divisions. Where only one division is affected, it may be due to peripheral irritation, such as dental caries, or inflammation at the point of exit from one of the osseous canals. In such cases a small peripheral operation may be sufficient.

The supra-orbital foramen is situated at the junction of the inner and middle thirds of the supra-orbital margin, and a line drawn from that point to the interval between the bicuspid teeth of both jaws (*Holden's line*) passes through the infra-orbital foramen, and, if prolonged, through the mental foramen.

The *supra-orbital nerve* is reached by a small horizontal incision just above the orbital margin, with its centre on the line. The *infra-orbital nerve* is reached by a similar incision fully $\frac{1}{4}$ inch below the lower margin of the orbit, with its centre on the line, the orbicularis and levator labii superioris being cut through. The *mental nerve* is reached likewise by a similar incision, with its centre on the line midway between the upper and lower margins of the lower jaw. The depressor anguli oris and labii inferioris are cut, and the nerve exposed and treated either by stretching or by cutting. The *lingual*

nerve may be reached by an incision through the mucous membrane a little below and behind the last molar tooth. The *inferior dental nerve* is reached through a vertical incision in the mucous membrane of the mouth, above and in front of the internal pterygoid, the muco-periosteum being shelled, and the nerve caught as it enters the dental foramen. It may also be treated through an external incision, the ascending ramus being trephined.

The **sixth nerve** arises from the floor of the fourth ventricle, and emerges between the anterior pyramid and pons. It lies to the inner side of the cavernous sinus, but otherwise has a course similar to the third. Its action is discussed under the Eye.

The **seventh, or facial, nerve** arises with the sixth from the floor of the fourth ventricle, and emerges between the olive and restiform body. It enters the internal auditory meatus with, but above, the auditory nerve, traverses the Fallopian aqueduct, and emerges at the stylo-mastoid foramen, whence it passes through the parotid gland and forms the *pes anserinus*.

A partial decussation of the facial nerve occurs in the pons at the level of the apparent origin of the fifth nerve. If a unilateral lesion occur in the pons anterior to this position, the face will be paralyzed on the same side as the rest of the body, a complete hemiplegia resulting on the side opposite to that of the lesion. If, on the other hand, the lesion be below the level of this crossing, the face will be paralyzed on the same side as the lesion, whereas the paralysis of the rest of the body will still be on the opposite side (the decussation of the pyramids occurring lower down, in the medulla).

In the petrous portion it gives off the *great petrosal*, which runs to Meckel's ganglion through the vidian, and also the *chorda tympani*, which leaves the tympanic cavity through the Glaserian fissure to supply the transverse lingual muscle, and ultimately joins the gustatory, to which it probably conveys taste fibres. Owing to the chorda supplying the transverse lingualis, which protrudes the tongue on its own side, a patient with facial paralysis protrudes the tongue toward the affected side.

The facial nerve supplies the muscles of the face, and also the buccinator. When the *trunk* is paralyzed, the paralysis

of one side of the face is absolute: the patient cannot close the eye, the cornea accordingly becoming affected; the tears drop on to the cheek; the mouth is drawn to the affected side; and saliva dribbles from the affected corner. Food lodges in the cheek from paralysis of the buccinator, and the patient cannot whistle.

A peripheral lesion of the nerve may also arise from cold (Bell's paralysis).

Where the *centre* is affected the paralysis is generally not absolute, the mimetic play of the features being maintained.

The nerve may be reached through an incision $1\frac{1}{2}$ inches long, from the anterior margin of the mastoid process, at the level of the external auditory meatus, to a point just behind the angle of the lower jaw. The sterno-mastoid is drawn backwards, and the parotid gland pulled forwards, the posterior belly of the digastric pulled downwards, and the nerve exposed at the upper part of the wound and stretched. The operation may be done for facial spasm. In some cases of facial paralysis, due to destruction of part of the nerve, the peripheral portion has been united to the spinal accessory, the result, however, not being altogether fortunate, even when successful so far as restoration of motor function is concerned, as the face muscles must then work in conjunction with those supplied by the spinal accessory.

The **eighth, or auditory, nerve** arises in the floor of the fourth ventricle, and emerges between the olive and restiform body, to pass to the internal auditory meatus below the facial. It supplies the auditory apparatus.

The **ninth, or glosso-pharyngeal, nerve** arises in the fourth ventricle, emerges between olive and restiform body, and leaves the skull by the *jugular foramen* to supply sensation to the pharynx, and the posterior part of the tongue with taste. It gives branches to the stylo-pharyngeus and tonsil.

The **tenth, vagus, or pneumogastric**, arises and emerges like the ninth, and also leaves the skull through the jugular foramen, giving off the auricular or *Arnold's nerve* as it does so, which passes through the petrous and supplies the skin behind the pinna and the lining of the auditory meatus. Moistening the skin of this region with water is supposed to convey stimulus to the pneumogastric, which would urge it to renewed exertion after a heavy dinner. Foreign bodies

in the ear frequently cause uncontrollable cough from irritation conveyed along Arnold's nerve to the superior laryngeal branch of the vagus. This *laryngeal branch* leaves the trunk after it has been joined by the accessory portion of the spinal accessory, runs down and forwards beneath the internal

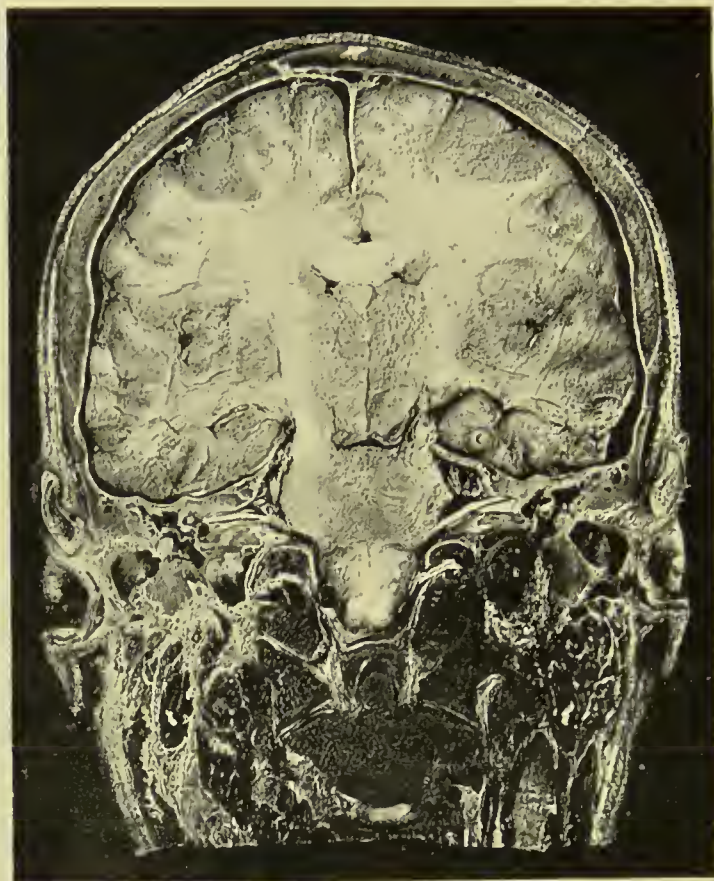

FIG. 4.—CORONAL HEAD SECTION PASSING THROUGH MIDDLE EAR.

Above, the superior longitudinal sinus and falx cerebri are seen.

Note in the brain the corpus callosum, the anterior horns of the lateral ventricles, and optic thalami.

The temporo-sphenoidal lobes are shown resting on the thin tegmen tympani. The attic of the tympanum is well shown, as likewise the tympanum occupied by part of the ossicles and a portion of the external auditory meatus.

Note in particular the entrance of the seventh and eighth nerves into the internal ear.

carotid, to supply the crico-thyroid muscle and laryngeal mucous membrane. Irritation of the nerve causes spasm of the glottis.

The *recurrent laryngeal* branch passes round the first part of the subclavian on the right and the transverse aorta on

the left, and runs up to enter the lower and back part of the larynx, and supply all the muscles except the crico-thyroid.

Pressure on the nerve causes cough. Pressure on both nerves causes complete loss of voice, but no shortness of breath.

The vagus nerves supply the lungs, heart, and the stomach, and communicate with the great sympathetic plexuses. Irritation of the terminal filaments supplying the stomach frequently cause "stomach cough."

The **spinal accessory**, or eleventh nerve, consists of an accessory part, which arises like the vagus and ultimately blends with it, and a spinal part, which arises from the anterior cornu of the cord, and ascends to enter the skull by the foramen magnum, and leave it again with the vagus. It passes down and backwards through the sterno-mastoid, which it supplies in part, and ends in the trapezius.

The nerve is associated with phonation, the accessory portion supplying the motor filaments in the vagus, while the spinal part controls the muscles mentioned. Stretching or cutting of the nerve may be necessitated in spasmodic torticollis. An incision $2\frac{1}{2}$ inches long is made from the apex of the mastoid process, along the anterior border of the sterno-mastoid. The anterior border of the muscle is defined and turned up, and the nerve treated as it reaches the muscle on its under surface. The transverse process of the atlas forms a useful guide to the nerve.

The **twelfth**, or **hypoglossal, nerve** arises from the floor of the fourth ventricle, and emerges between the anterior pyramid and olive. Leaving the skull through the anterior condylar foramen, it descends with the vagus to the level of the angle of the jaw, and then passes forwards, over the carotid vessels and hyo-glossus muscle, to pass beneath the posterior tendon of the digastric and the mylo-hyoid, and end in the genio-hyo-glossus. It supplies the extrinsic muscles of the tongue, and gives off a descending branch to supply the depressors of the hyoid bone.

In paralysis of the nerve the tongue, on protrusion, turns to the affected side.

BULBAR PARALYSIS, also known as Duchenne's paralysis, or labio-glosso-pharyngeal paralysis, consists of disease of the medulla affecting the origins of the seventh, ninth, tenth,

eleventh, and twelfth nerves, and is a very serious affection. Speech is affected, the lips and tongue are paretic, mastication and swallowing are difficult or impossible, and the face is also paretic.

THE EAR.

The **pinna** may be congenitally absent, malformed, or abnormally small (microtia) or large (macrotia). Small fistulæ may be found, due to failure in fusion of the various tubercles from which the embryonic ear is formed, and of greater consequence is imperfect closure of the first branchial cleft, from which the external auditory meatus, middle ear, and Eustachian tube are formed. Where the cleft is not closed it may present as a fissure, commencing either at the tragus or helix, and extending perhaps into the middle ear, the *membrana tympani* being defective or even absent. Sometimes a small tubercle is found near the upper extremity of the helix presenting a tuft of hair. It is known as Darwin's tubercle, and is supposed to represent the tip of the tapering ear of lower animals. Supernumerary auricles, small and ill-formed, are rarely found on the cheek or side of the neck. The *subcutaneous tissue* on the outer aspect of the pinna is dense and closely adherent to the perichondrium, and hence inflammatory processes in this position are generally small, but very painful. Tophi, or gouty deposits of urate of soda, are sometimes found along the margin of the helix.

Extravasations of blood (othæmatoma) occur not infrequently on the outer aspect of the pinna, sometimes from injury and at others spontaneously, the latter being found particularly in the insane, and due probably to disease of the vessels. The extravasated blood is generally absorbed, but its absorption is frequently accompanied by deformity of the pinna, and hence it is sometimes desirable to evacuate such collections soon after their formation. Notwithstanding its generous blood-supply from the temporal and posterior auricular arteries, the pinna is a frequent seat of frost-bite, owing to its exposed position and the absence of fatty tissue over its vessels.

The pinna and cartilaginous meatus are very firmly adherent to the skull, sufficiently in some cases to bear the weight of the body. Even where, however, the pinna has been almost

detached, it will, as a rule, rapidly heal if stitched in position. The skin under the lobule of the ear is a frequent site of sebaceous cysts. The glands in this region are not infrequently enlarged from irritation of the scalp due to phtheiriasis, and eczematous conditions of the external ear.

The **external auditory meatus**, rather over an inch in length, has a wall lined with skin, which is composed of cartilage over rather more than the outer half, and of bone over the remainder. It is directed forwards and inwards, and is curved, with the convexity pointing upwards and backwards, so that both osseous and cartilaginous portions are directed downwards. When introducing a speculum, therefore, the pinna should be held upwards and backwards, so as to bring the cartilaginous canal into line with the osseous. The narrowest point is at the junction of cartilaginous and osseous parts. In the infant the meatus is shorter, straighter, and almost entirely cartilaginous. The wall of the meatus presents certain gaps on its anterior and lower aspect, filled with fibrous tissue (*fissures of Santorini*). Through these a parotid abscess may burst into the external ear. The osseous wall, owing to its close relationship anteriorly to the condyle of the jaw, is sometimes fractured by falls or blows on the chin. The skin of the meatus is very adherent to the underlying structures, particularly over the osseous portion, and is furnished over the cartilaginous part with hairs and *ceruminous glands*. Accumulations of *wax* secreted by these glands is a frequent cause of deafness. The osseous portion of the canal, in common with the back of the pinna, is supplied by the auricular branch of the vagus, and hence irritation of this part from wax or foreign bodies frequently causes coughing, and may cause vomiting, yawning, sneezing, or even epileptiform attacks. *Abscesses* in this region are generally very localized and extremely painful, being affected by every movement of the jaw in chewing or even in speaking. *Polypi* not infrequently are found in the external auditory meatus, and may be removed by snaring. Care should, however, be taken not to mistake masses of granulation tissue springing from the cerebral dura, and protruding through the thin layer of bone separating dura and meatus, for polypi. If such be avulsed, the way is laid open for dural or even cerebral pyogenic implication, and death has sometimes resulted from such

mistakes. *Exostoses* occasionally occur in the osseous portion. They are generally of the ivory type and of slow growth.

The **tympanic membrane** in the infant lies almost horizontally, and is attached peripherally to a separate ring of bone, which is complete save in its upper segment. In the adult the membrane is nearly vertical, but is inclined from above and behind downwards, forwards and inwards, so that its anterior and inferior edges form acute angles with the meatal wall.

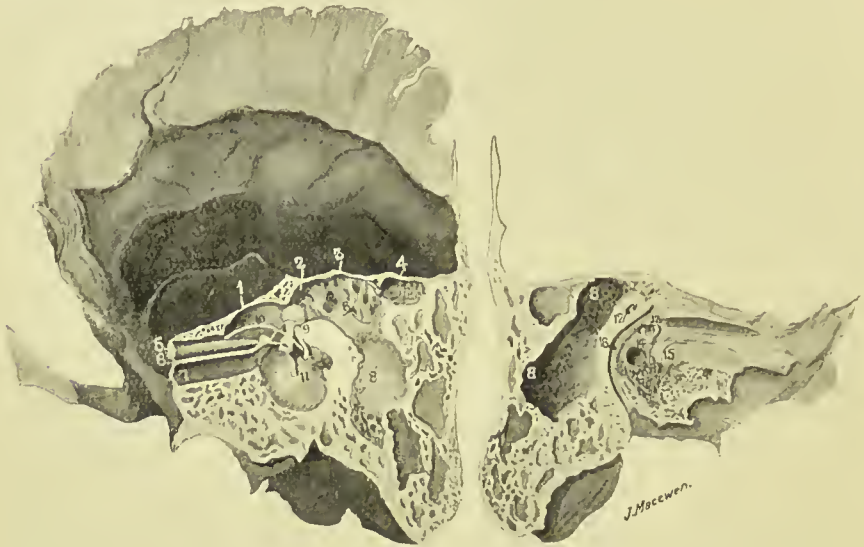

FIG. 5.—TEMPORAL BONE.

- | | |
|--|---|
| 1. Tegmen tympani. | 10. Chorda tympani. |
| 2. Iter. | 11. Tympanic membrane and handle of malleus. |
| 3. Tegmen antri | 12. Superior semicircular canal. |
| 4. Accessory antrum. | 13. Fenestra ovalis and stapes. |
| 5. Tensor tympani. | 14. Fenestra rotunda. |
| 6. Processus cochleariformis. | 15. Promontory with Jacobson's nerve ramifying over it. |
| 7. Eustachian tube. | 16. Facial canal. |
| 8. Mastoid antrum. | |
| 9. Is placed on bone of the facial canal, which conceals the pyramid containing the stapedius muscle. To the left of the figure are the head of the malleus and long process of the incus. | |

It is composed of fibrous tissue, and is lined externally with a very thin layer of skin, continuous with that of the meatus, while internally it is lined with mucous membrane, which is continuous with that lining the middle ear, and which is derived from that of the pharynx through the Eustachian tube. A little below its centre it presents a depression, or *umbo*, corresponding to the attachment of the handle of the malleus. As the CHORDA TYMPANI NERVE, with the vessels

and nerves supplying the membrane, runs across above the level of the umbo, it is well when incising the membrane to do so below the umbo. The *chorda tympani* is a branch of the facial in the lower part of the aqueduct of Fallopius. It enters the middle ear through the iter chordæ posterior, leaves it through the iter chordæ anterior, and then joins the lingual of the fifth beneath the external pterygoid muscle, whence it supplies the anterior two-thirds of the tongue with taste. It communicates in its course with the submaxillary and otic ganglia (see plate). The gap in the ring of bone to which the membrane is attached is situated above and anteriorly, and is called the NOTCH OF RIVINI. From either extremity of this notch a fold of fibrous tissue extends to the short process of the malleus, and the angle so formed is filled in with loose connective tissue, known as SHRAPNELL'S MEMBRANE, or the *membrana flaccida*. Pus may occasionally force its way through this membrane without rupturing the *membrana tympani*. The *membrana tympani* may be ruptured by blows on the ear, and even by loud noises, while it is frequently destroyed by middle-ear disease.

The **middle ear**, or **tympanum**, is a small cavity which contains the ossicles and communicates anteriorly with the pharynx through the Eustachian tube, and posteriorly with the mastoid antrum and cells through the iter. The *lining membrane* of all these parts, including the mastoid antrum and cells, is continuous with the pharyngeal mucous membrane. This membrane is very thin, and in the middle ear is thrown into folds which invest the ossicles, forming practically ligaments for them, and also numerous pouches, that between the *membrana flaccida* and neck of malleus being called the *pouch of Prussak*. The outer wall of the tympanum is formed by the tympanic membrane, and, above the membrane, by the squamous bone. The portion of the tympanum above the level of the *membrana* is called the ATTIC, or epi-tympanic recess. It lodges the head of the malleus, and body and short process of the incus, the latter projecting into the iter (or aditus to the antrum), through which the attic of the tympanum communicates with the mastoid antrum. Thus the greater portion of the ossicles lies above the level of the tympanic membrane. The inner wall is formed by the external surface of the internal ear. At its upper and posterior

part, close to the roof, is seen the projecting FACIAL CANAL. Below this is the FENESTRA OVALIS, occupied by the stapes. Still further down, but more anteriorly, is seen the PROMONTORY or projection of the cochlea, while yet further down and nearly under the fenestra ovalis is the FENESTRA ROTUNDA,

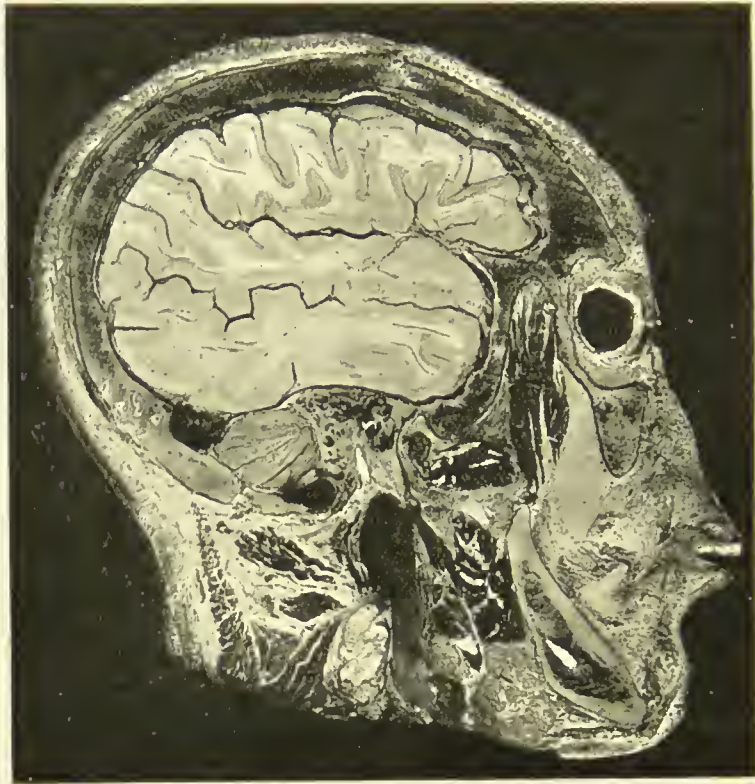

FIG. 6.—SAGITTAL HEAD SECTION PASSING THROUGH THE TYMPANIC MEMBRANE AND DISPLAYING THE MIDDLE EAR, ATTIC, ITER, AND MASTOID ANTRUM.

The membrane is shown cut obliquely and exposing the middle ear, in which are seen the ossicles and the chorda tympani nerve (white). Below and behind these the facial nerve (white) is seen in section.

Note how the middle ear and mastoid cells are surrounded by the condyle of the jaw in front, temporo-sphenoidal lobe above, cerebellum behind, and sigmoid sinus below and behind. The jugular bulb and vein are shown in longitudinal sections (black), and the inferior dental nerve (white) in oblique section within the lower jaw.

closed by a thin membrane and leading to the scala tympani. The roof, or TEGMEN TYMPANI, situated above the upper limit of the tympanic membrane, is a very thin plate of bone, which separates the middle ear from the dura of the middle fossa. In the infant a gap exists in this roof externally, due to the PETRO-SQUAMOSAL SUTURE, which gives passage to some veins,

and traces of it may be found in the adult. Thus extension upwards of pyogenic mischief to the brain from the middle ear may very readily occur. The floor below the lower limit of the tympanic membrane and of the Eustachian tube is narrower than the roof and much thicker. It separates the middle ear from the dome of the internal jugular vein. The anterior extremity of the middle ear is tapered and is occupied above by the canal of the tensor tympani muscle and below by the Eustachian tube, separated from one another by the *processus cochleariformis*. This processus is prolonged backwards almost to the fenestra ovalis, where it forms a pulley for the tendon of the tensor tympani, which curves round it to be inserted into the neck of the malleus. Below the Eustachian tube is a thin plate of bone separating the middle ear from the carotid artery. The posterior wall presents superiorly the iter or communication with the mastoid antrum, which is generally of sufficient size to admit a director. Below the entrance to the iter is the PYRAMID, with a small aperture at its summit for the tendon of the stapedius muscle, while external to the pyramid and close to the tympanic membrane is the small aperture for the chorda tympani nerve. The tympanum is supplied by the tympanic branch of the internal maxillary artery, which enters through the Glaserian fissure, the stylo-mastoid branch of the posterior auricular, the petrosal branch of the middle meningeal, and small branches from the internal carotid. The veins run upwards to join the superior petrosal sinus, downwards to join the temporo-maxillary vein and jugular bulb, and backwards to the lateral sinus. The tympanic nerve plexus is formed by the small superficial petrosal (from otic ganglion to facial nerve), small deep petrosal (from sympathetic surrounding internal carotid artery), and tympanic branch of glosso-pharyngeal (Jacobson's).

The **Eustachian tube**, about $1\frac{1}{2}$ inches long, and lined with ciliated epithelium directing secretion toward the pharynx, commences at the anterior extremity of the middle ear, below and to the inside of the canal of the tensor tympani, and is directed forwards, inwards, and slightly downwards. For the first $\frac{1}{2}$ inch of its course it is surrounded by an osseous wall, the internal carotid artery lying to its inside. It is narrowest at the junction of osseous and cartilaginous portions (isthmus),

and then expands, presenting a *trumpet-shaped mouth* in the pharynx, situated above the soft palate behind the inferior turbinate bone. This mouth is generally closed, but is opened during swallowing by the action chiefly of the tensor palati. This fact is taken advantage of in *Politzer's method of inflation*, in which air is forced up the nostril through a nozzle, while the patient swallows a mouthful of water previously taken, the mouth and nostrils being kept firmly closed meanwhile. Probably, however, the Eustachian tubes are never firmly closed, as air can also be forced into them by attempting to blow through the nose while holding the nostrils; this is known as *Valsalva's method of inflation*. These inflations are performed with a view to clearing the Eustachian tube, as when the tube is blocked partial deafness occurs. They are not entirely devoid of danger, as, if septic material be lodged in the tube, it may be forced up by inflation to the middle ear, and possibly even to the mastoid cells, as the Eustachian tube and the iter are in line with one another, the junction of the incus and stapes, however, intervening.

The **iter**, or aditus, about $\frac{1}{4}$ inch long, leads from the posterior extremity of the attic of the middle ear to the mastoid antrum. Its roof, like that of the middle ear, is composed of a thin plate of bone, separating it from the dura of the temporo-sphenoidal lobe. Its floor and part of its inner wall are formed of hard compact bone encasing the FACIAL NERVE, while the bone encasing the EXTERNAL SEMICIRCULAR CANAL causes a slight prominence on the inner wall posterior to the facial canal.

The **mastoid antrum**, situated at the upper anterior angle of the mastoid bone and present from birth, is very constant in its position, but varies greatly in size (sometimes occupying nearly the whole mastoid process), and also in its depth from the surface. Like the middle ear and iter, it is lined with a thin layer of mucous membrane, continued through the Eustachian tube from the pharynx, and it is separated from the temporo-sphenoidal dura by only a very thin layer of bone, the TEGMEN ANTRI. Anterior to the mastoid antrum lies the descending portion of the FACIAL NERVE, enclosed, as it is in other parts, by dense bone. The mastoid antrum is in direct communication, by numerous small canals, with the MASTOID CELLS, with which the mastoid process is honey-

combed. These mastoid cells freely intercommunicate by similar canals, and they also are lined by mucous membrane continuous with that of the pharynx. It will thus be seen that if ORGANISMS gain access to the Eustachian tube, they may

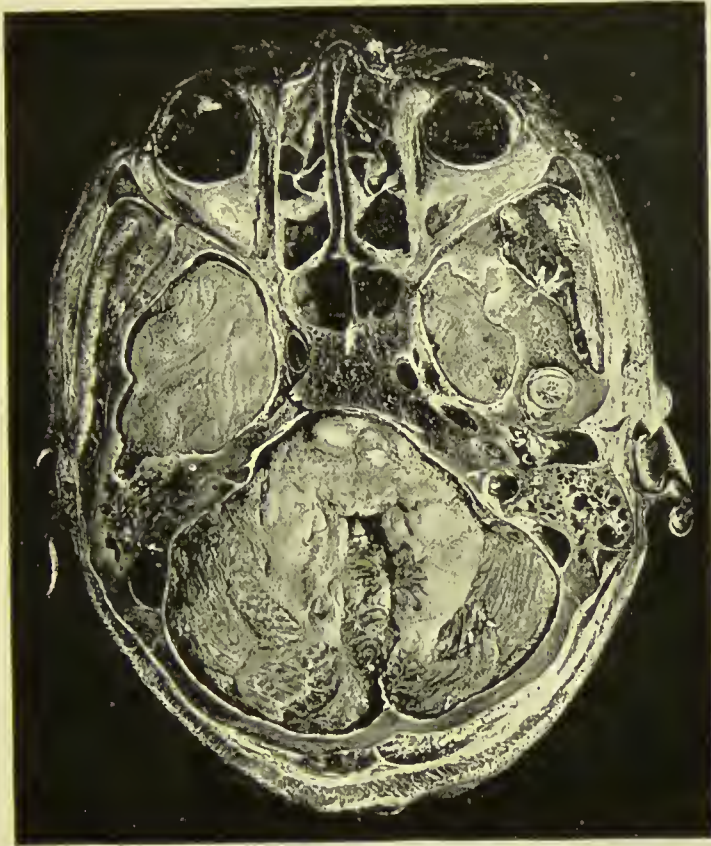

FIG. 7.—HORIZONTAL HEAD SECTION, PASSING THROUGH THE MIDDLE EAR. (VIEWED FROM BELOW.)

Anteriorly are the orbital cavities occupied by the eyes, ocular muscles, nerves, fat, etc., and the ethmoidal and sphenoidal cells. The lower and anterior extremities of the temporo-sphenoidal lobes of the brain are seen, related anteriorly to the posterior ethmoidal and sphenoidal sinuses and orbits, and posteriorly (on the left) to the mastoid cells. On the right the tip of the condyle of the jaw is seen in section, just external to the temporo-sphenoidal lobe, and in front of the tympanic membrane, which is also cut across and separates the external from the middle ear. In the middle ear are portions of the ossicles, and still more internally is a turn of the cochlea cut across, while behind the middle ear the facial nerve (white) is cut transversely. The mastoid cells and their relationship to the sigmoid sinus are well shown, as is likewise the cerebellum, presenting a portion of the fourth ventricle.

travel up to the middle ear, iter, mastoid antrum, and mastoid cells, and as these structures, and particularly the latter, are in close proximity to numerous important parts, and pus cannot readily find an exit from them, life may readily be

threatened. The mastoid antrum, when large, or in other cases the mastoid cells, generally projects backwards, beneath the KNEE OF THE SIGMOID SINUS. The position of the knee of the sinus is unfortunately very variable, being sometimes within $\frac{3}{8}$ inch of the posterior osseous wall of the external auditory meatus, and at others fully 1 inch behind it, while it also varies much as to depth from the surface. When the

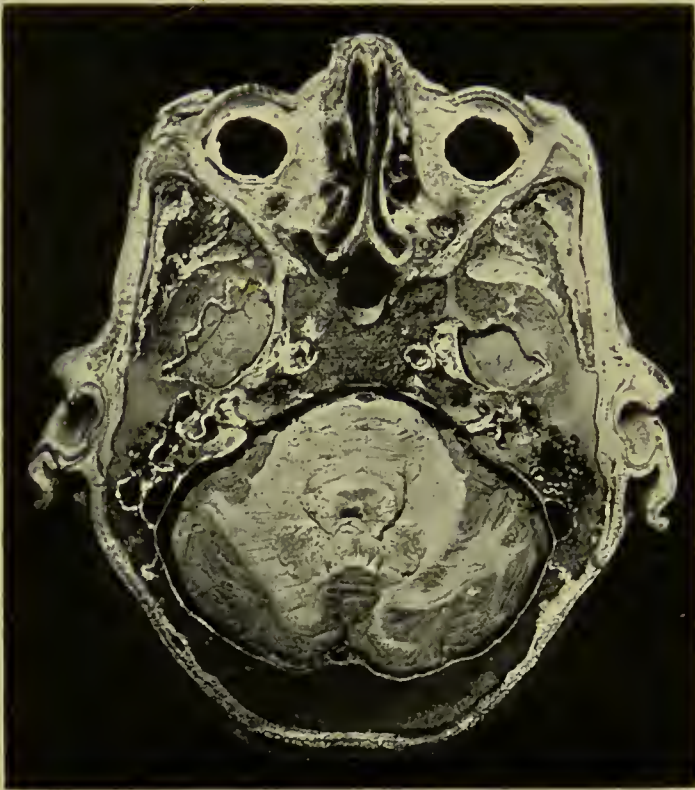

FIG. 7A.—HORIZONTAL HEAD SECTION, ABOUT $\frac{1}{4}$ INCH BELOW 7.

Note the seventh and eighth nerves entering the internal ear together and then diverging. On the left the cochlea, the vestibule, the middle ear, iter, and mastoid antrum are shown, as likewise the external semicircular canal (black, to the inside of the antrum), and the sigmoid sinus.

mastoid antrum projects far back behind the sigmoid sinus, it comes into relationship with the dura of the CEREBELLUM, from which it may be separated by only a thin layer of bone.

EXTENSION OF SEPTIC MATTER UPWARDS from the middle ear, iter, and mastoid antrum, will involve the cerebral dura covering the temporo-sphenoidal lobe, and give rise most probably to EXTRADURAL, or, if the dura be penetrated, to

INTRACEREBRAL ABSCESS. The reason why such extension does not cause generalized meningitis is to be found in the resisting qualities of the dura mater. At first toxins alone penetrate the dura, and these set up an inflammation which is local and leads to soldering of dura, pia-arachnoid, and even brain surface. Thus, when organisms do ultimately perforate the dura, they are in a space confined by adhesions, and are not in the free subdural space. Small veins may also carry the infection to the superior petrosal sinus, causing thrombosis. It will be remembered that, owing to the shape of the middle fossa, the pressure of **temporo-sphenoidal abscesses** is directed *inwards*, as evidenced by PRESSURE ON THE THIRD NERVE, causing first (during the period of irritation) a contraction, and later (from paralysis) a dilatation of the pupil on the same side, and *upwards* to the FACE CENTRE, giving rise to a paralysis of the face on the opposite side, the mimetic play of the features being retained.

EXTENSION BACKWARDS from the mastoid antrum and cells will involve, first, the SIGMOID SINUS, giving rise to sinus thrombosis, and second, possibly the CEREBELLUM, giving rise to **cerebellar abscess**. **Sigmoid sinus thrombosis** will extend down into the internal jugular in the neck, and as the clot becomes purulent and broken down by the action of the organisms, septic emboli may be swept to the lungs (pneumonic type), abdomen (typhoid type), or back to the meninges (meningeal type). As the sigmoid sinus is formed by a splitting of the dura mater, the explanation given above as to the resisting qualities of the dura again holds as the reason why organisms do not immediately penetrate the sinus and enter the circulation. Only toxins penetrate at first. These cause the formation of a thrombus in which there are no organisms, and when, ultimately, organisms do enter the sinus, they encounter a solid mass of clot and not circulating blood. Hence it is not until purulent disintegration of the clot has occurred that systemic infection takes place. EXTENSION INWARDS from the middle ear to the internal ear: Here the organisms may invade, and then travel along the sheaths of the SEVENTH AND EIGHTH NERVES, and so reach the surface of the brain and give rise to generalized **meningitis**. The FACIAL NERVE may be destroyed without invasion of the cerebral membranes,

causing complete paralysis of the face on the same side (contrast with effect of pressure on face centre given above).

It is thus a matter of great importance to be able to go down upon the mastoid antrum, and give exit to the pus contained within it, without damaging the very important structures lying upon all sides of it. This, fortunately, is a comparatively easy matter owing to the constant relationship between the mastoid antrum and the surface markings to be described. The posterior root of the zygoma passes nearly horizontally across the superior border of the external auditory osseous meatus, and extends backwards beyond it, forming an angle with the posterior wall of the osseous meatus. This angle can always be made out on the surface of the bone, and is frequently occupied by a very well-marked depression in the bone. The angle may be converted into a triangle by supplying an imaginary third or posterior side, formed by drawing a tangent upwards from the posterior part of the osseous auditory meatus, and is called the **suprameatal triangle** (Macewen).

An aperture made straight in through this triangle, keeping at right angles with the surface of the bone, will strike the antrum, without damaging the sigmoid sinus, provided that the aperture made be not large. The spine of Henle, sometimes given as a guide to the antrum, is generally only present in well-marked skulls, in which the suprameatal triangle is indicated by a distinct depression in the bone. When present, the spine is situated on the margin of the posterior wall of the osseous meatus. Such an aperture would enable pus to escape, but would not, as a rule, cure the condition, a **RADICAL MASTOIDECTOMY** performed with proper instruments being necessary for this purpose. In performing the radical operation much care is required. When working backwards the sigmoid sinus may be exposed at any moment, and as its position cannot be determined by landmarks, the operation can only be safely performed by an instrument which will cut away the diseased bone gradually without damaging the soft parts (such an instrument is the surgical bur, when properly made). In the radical operation also it is usual to lay the middle ear and mastoid antrum into one, by cutting away the bridge of bone which, forming the external wall of the iter, separates the two. Here again care must be exercised,

as if the bone on the inner side of the iter be cut, both the facial nerve and the external semicircular canal may be damaged. When operating with a surgical bur, the FACIAL CANAL, even in very extensive dissections, can be recognized and avoided, owing to its being encased in dense bone, which contrasts with the softer bone surrounding it. The FACIAL NERVE enters the internal auditory meatus along with the eighth nerve, and at the bottom of the internal meatus enters the AQUEDUCT OF FALLOPIUS, the canal of dense bone already mentioned. In this it first runs outwards and forwards until it reaches the inner wall of the tympanum, when it suddenly bends backwards and downwards, first to the inner side and then to the floor of the iter. Finally, it descends almost vertically just in front of and on the deep surface of the antrum, to the stylo-mastoid foramen. The OSSICLES are frequently involved in disease, and are generally removed in a radical operation, with the exception of the stapes, which is fixed in the foramen ovale. It is worthy of note that hearing is often much improved after the radical operation, partly due, no doubt, to the removal of the granulation masses, which previously blocked up the parts, and also possibly to the freeing of the stapes.

The **mastoid process** varies much in structure. Sometimes, and especially after long-standing disease, it is hard and dense, and contains few cells. At others it is honeycombed with intercommunicating cells, one of which may open at the tip, forming a 'Bezold's aperture.' Where mastoiditis occurs in such cases, the pus may escape by this aperture and present in the neck, generally behind the sterno-mastoid. In most cases the pus, when it escapes, does so by the Eustachian tube, or, once perforation of the drum has occurred, by the external ear. It is important to remember, however, that active mischief may be going on, although the drum is intact. Sometimes the pus finds its way to the surface of the mastoid bone, under the periosteum, by a process of caries, or through remains of the *masto-squamosal suture*, and in such cases the periosteum, carrying with it the pinna, is raised from the bone, so that the patient presents the appearance of having a very prominent ear, which also is projected forwards. A simple incision into this superficial abscess is known to aurists as Wilde's incision. It cannot, of course, cure the

condition. In some cases, where such an aperture exists on the surface of the mastoid, the patient may possess the power of inflating the superficial tissues by forcing air through the Eustachian tube. Such tumours are known as *pneumatocelles*. Apart from disease due to pathogenic organisms, the mastoid antrum is sometimes occupied by an epithelial tumour, composed of pearly masses of epithelium (CHOLESTEATOMA).

In such cases the antrum is generally very large, extending deeply beneath the sigmoid sinus, and profuse suppuration appears to occur readily on the invasion of organisms, and is, of course, extensive. Sometimes pathogenic processes extend inwards and affect the **internal ear**. In some of these the semi-circular canals may be slowly affected (MÉNIÈRE'S DISEASE), and even the whole osseous labyrinth, consisting of cochlea, vestibule, and canals, has been found lying detached in the ear as the result of such processes.

THE EYE AND OCULAR APPARATUS.

The Ocular Apparatus.—The eyeball, lying in the orbital cavity, is largely protected from injury by the prominent eyebrow and the bones forming the cavity. The EYEBROW possesses a considerable range of movement, and when struck is frequently divided by the underlying bone from within outwards, a clean-cut wound being thus produced. The well-defined supra-orbital margin is easily made out by palpation, as well as the *supra-orbital notch* at the junction of its inner and middle thirds, which transmits the supra-orbital vessels and nerve. Penetrating wounds in the orbital region are frequently serious, as the bones in this region being very thin, the brain, cavernous sinus, or even the internal carotid artery, may be damaged. *Arterio-venous aneurysm* may follow the wounding of the two latter structures. The UPPER EYELID covers about three-quarters of the anterior surface of the eyeball, and opening and closing of the eye is chiefly due to its movements. The *tarsal cartilage* of the upper eyelid is the larger of the two, and, commencing close to the palpebral fissure, extends upwards for rather more than $\frac{1}{4}$ inch. Beyond its stiff upper margin the eyelid is soft, and this fact is illustrated in the usual method of everting the eyelid. On eversion of the lids the large *Meibomian glands*, whose ducts

open along their margins, may be seen showing through the conjunctiva. *Tarsal cysts* are produced by blocking of these ducts, while a *stye*, or hordeolum, is a small boil originating in a hair follicle or sebaceous gland. *Marginal blepharitis* is an extensive inflammation of the palpebral margin, which frequently results in an inturning of hair follicles, the lashes thus growing toward and touching the conjunctiva, causing what is known as *trichiasis*. The skin of the eyelids is very lax, and advantage is taken of this in performing numerous plastic operations on the lids. This laxity, however, also favours the occurrence of marked deformity by traction of tubercular and other cicatrices, giving rise frequently to an eversion of the lower lid, known as *ectropion*. *Entropion*, or incurling of the lid, is generally the result of prolonged conjunctivitis, and most frequently affects the upper lid. *Rodent ulcer* frequently affects the eyelid, where the fact that it does not cause contraction is well illustrated, no contraction deformity resulting from its presence. The laxness of the tissues of the eyelids is also illustrated by the frequent occurrence of *œdema* from inflammatory conditions and Bright's disease; by occasional emphysema in fracture of the nasal bone, with tearing of the nasal mucous membrane; and by the readiness with which effusions of blood occur into them from a blow, producing a 'BLACK EYE.' This condition requires to be distinguished from effusion of blood resulting from fracture of the orbital plate of the frontal bone. In black eye the effusion into the eyelids and under the conjunctiva occurs within a few hours of the injury, is general and diffuse, is generally of a chocolate colour, and the subconjunctival portion is limited to the anterior segment of the eyeball. The effusion due to fracture seldom appears before some forty-eight hours have elapsed, is patchy, of a blue colour over the eyelids, of which the lower is generally first affected (owing to gravity), and bright red over the conjunctival portion, the effusion here not being limited to the anterior segment, but extending backwards beyond the visible portion of the eyeball. As the occipito-frontalis muscle sends an expansion into the upper eyelids, effusions of pus or blood may extend from the scalp into the upper lid.

The *eyelids are closed* by the facial nerve acting on the orbicularis palpebrarum. Thus, in a complete facial paralysis

due to destruction of the nerve trunk the patient cannot close the eye on the affected side (*lagophthalmos*) ; the eyeball appears slightly prominent (*proptosis*), owing to want of the restraining action of the orbicularis, and the conjunctiva tends sooner or later to become inflamed from undue exposure. The lower eyelid tends to droop outwards, allowing the tears, the secretion of which is increased by the irritation, to flow on to the cheek (*epiphora*). *Blepharospasm*, or persistent contraction of the muscle, is seen in photophobia from inflammation of the cornea and uveal tract, and sometimes in cases of otitis, trigeminal neuralgia, carious teeth, etc. The *eyelids are opened* by the third nerve acting on the levator palpebræ superioris. In paralysis of the third nerve there is therefore a marked drooping of the upper eyelid (*ptosis*), which can only be slightly raised voluntarily by an exaggerated action of the frontalis muscle, which at the same time wrinkles the forehead. A slight *ptosis* of the upper eyelid may also be produced by paralysis of the cervical sympathetic, which then cannot act on the unstriped fibres, and a pseudo-ptosis may be caused by great swelling of the eyelid, or lipoma of the skin fold overhanging the upper eyelid (*blepharo-chalasis*), or to some congenital defect in the muscles. The fifth nerve supplies *sensation* to the eyelid, the first division supplying four twigs to the upper, and the infra-orbital of the second division supplying the lower. The *blood-supply* is derived from the ophthalmic of the internal carotid, which sends a small twig to the inner side of each eyelid, while by its lachrymal branch it sends a small twig to the outer side of each. Some of the lymphatics drain to the preauricular glands.

While the eyelids meet externally at an acute angle to form the *outer canthus*, internally they first diverge from one another (lacus lachrymalis) before forming the *inner canthus*. At the point of divergence on each lid there is a slight conical elevation, with a small aperture at its summit, the *punctum lachrymale*, which communicates with the lachrymal canaliculus, and conveys the tears to the lachrymal sac. The small space left by the divergence of the lids or lacus lachrymalis is occupied by the *lachrymal caruncle*. The tarsal cartilages of the upper and lower eyelids are connected internally and externally by the *tarsal ligaments*, which are Y-shaped, the stem of the Y being attached to the malar bone externally,

and to the superior maxilla in the case of the internal ligament, while the limbs are attached to the upper and lower tarsal plates. The internal tarsal ligament, or *tendo oculi*, is the stronger, and passes to its insertion in front of the lachrymal sac, while it may send a posterior limb round the lachrymal sac to be inserted into the lachrymal bone. The SEPTUM ORBITALE, which forms a diaphragm separating the superficial from the deep structures of the orbit, is a membranous expansion from the periosteum of the margin of the orbit into the eyelids. In the upper eyelid it blends with the tendon of the levator palpebræ superioris, and in the lower with the tarsal cartilage. Externally it forms the external tarsal ligament, while internally it diverges from the internal tarsal ligament, and passes behind the lachrymal sac to be inserted into the lachrymal bone.

Congenital defects of the eyelids are uncommon. *Epicanthus* is the term applied to a semilunar fold of skin extending over the inner canthus from the upper to the lower eyelid; *ankylo-blepharon* is a fusion of the two eyelids; *coloboma*, a vertical fissure, sometimes associated with a corneal dermoid. *Chalazion* is a granulomatous tumour which occurs in the substance of the eyelid, generally the upper.

The CONJUNCTIVA is a delicate mucous membrane, covered with epithelium, which lines the inner surfaces of the eyelids and the front of the globe. The reflections from the eyelids to the globe are called the superior and inferior *fornices*. Only the epithelial layer covers the front of the cornea, the connective tissue layers ceasing at the corneal margin. The *caruncle* at the inner canthus is formed from conjunctiva, and just external to the caruncle is the *plica semilunaris*, a fold of the membrane which disappears on full external rotation of the eyeball, to permit of which movement it exists. It corresponds to the nictitating membrane of birds. The conjunctiva is but loosely attached to the eyeball, and use is made of this fact in plastic operations for the relief of *symblepharon*, in which, owing to injury, the eyelids become adherent to the eyeball. This laxness readily permits of œdematous swelling of the conjunctiva (*chemosis*) occurring, as well as of *subconjunctival hæmorrhage* from rupture of the unsupported vessels.

The lachrymal and two palpebral branches of the ophthal-

mic branch of the internal carotid supply the conjunctiva with blood, while it is supplied by four nerves: above, the supratrochlear; outside, the lachrymal; inside, the infra-trochlear (all derived from the ophthalmic division of the fifth); and below, by the palpebral branches of the superior maxillary of the fifth.

The conjunctiva is subject to both acute and chronic *inflammation*. In the acute form the conjunctiva becomes deeply congested, the congestion generally being arrested at the corneal margin, where the normal conjunctival vessels terminate. In iritis a zone of circumcorneal inflammation is also seen, but the individual vessels cannot be distinguished; whereas in conjunctivitis they are not only readily distinguishable, but can be moved with the conjunctiva on the cornea by manipulation of the lower eyelid.

Trachoma, or chronic granular conjunctivitis, is most often met with among the poor, and frequently gives rise to entropion. *Pterygium* is a triangular vascularized thickening of conjunctiva, occurring most frequently to the inner side of the cornea, upon which its apex abuts and over which it may grow.

The LACHRYMAL GLAND, which, occupying the fovea lachrymalis of the frontal bone, lies at the upper and outer part of the orbit behind the conjunctiva, secretes the tears which serve to keep the conjunctiva moist, and to remove small particles which may have settled on the surface. The gland consists of two lobes, separated by a process of Tenon's capsule. The orbital lobe is the larger and more important; the smaller is known as the palpebral portion. Excision of the gland may be performed for tumour or intractable epiphora (overflow of tears on to the cheek), sufficient moisture being subsequently secreted by small detached lobules. The gland is supplied by the lachrymal of the fifth, stimulation of which, either directly or reflexly through particularly the nasal branches, causes profuse lachrymation.

The tears are conveyed from the gland to the surface of the conjunctiva by numerous small ducts which pierce the conjunctiva at its reflection on to the upper eyelid. From thence they are carried across the front of the eyeball by gravity, capillarity, and the frequent blinking action of the eyelids, to the inner angle, where, save when the secretion

is excessive, they enter the lachrymal canaliculi through the lachrymal puncta on the eyelids. The *canaliculi*, about $\frac{1}{3}$ inch long, run first vertically, the upper upwards and the lower downwards, then horizontally inwards and finally open close together or by a single opening into the lachrymal sac. The *lachrymal sac* occupies the lachrymal groove, lying upon the orbital septum (which is attached to the crest of the lachrymal bone), the lachrymal bone, and a portion of the nasal process of the superior maxilla, while in front it is crossed above by the tendo oculi, but below is comparatively superficial, lying under the skin and orbicularis muscle. Its junction with the lachrymal canal is the narrowest portion of the common apparatus. The *nasal duct* continues from the sac through an osseous canal, the *lachrymal canal*, formed by the lachrymal and ascending process of the superior maxilla above and the inferior turbinate and superior maxilla below, to open by a small aperture in the mucous membrane of the inferior meatus of the nose. Its direction downwards and backwards is indicated by a line from the commencement of the lachrymal canal to the first upper molar. The lachrymal passages are liable to inflammatory infection from the conjunctiva and the nose, which parts may infect one another through this channel. Inflammation and injury of the duct tend to cause blocking and consequent overflow of tears (epiphora). Sometimes also the lachrymal sac becomes inflamed and distended (*dacryocystitis*), which may even go on to suppuration, the abscess pointing below the tendo oculi. D.B.O

The **ocular muscles**, with the exception of the inferior oblique, take origin from a common tendon, which nearly surrounds the optic foramen. The inferior oblique arises from the antero-nasal aspect of the orbital floor, and then, passing backwards and outwards under the rectus inferior, turns up between the rectus externus and the eyeball, to be inserted into the posterior temporal aspect of the eyeball. The superior oblique passes forwards between the recti superior and internus to the inner side of the anterior margin of the orbit, where it passes through a pulley, and is then directed down and outwards beneath the tendon of the rectus superior, to be inserted a little above and anterior to the inferior oblique into the temporal aspect of the eyeball

between the superior and external recti, and midway between the cornea and entrance of the optic nerve.

The *internal and external recti*, having median insertions, rotate the eye upon its true vertical axis inwards and outwards respectively. The *superior and inferior recti*, being inserted external to the median position, rotate the eyeball upon a horizontal axis, which, instead of being strictly coronal, is directed backwards and outwards. When acting alone, therefore, in addition to turning the eyeball up and down, they also turn it to the nasal side.

The *superior and inferior oblique muscles* rotate the eyeball round a horizontal axis which is likewise not coronal, but is inclined forwards and outwards nearly at right angles (75 degrees) to the axis of the recti muscles. The oblique muscles accordingly turn the eyeball down and up, and at the same time turn it toward the temporal side. Hence, to obtain a movement of the eyeball directly upwards, the superior rectus and inferior oblique act together, the inward tendency of the oblique being corrected by the outward tendency of the rectus, and similarly, in moving the eyeball directly downwards, the inferior rectus and superior oblique act together.

NERVE-SUPPLY.—All these muscles are supplied by the third nerve, except the superior oblique, which is supplied by the fourth, and the external rectus, which is supplied by the sixth. The third nerve also supplies the levator palpebræ superioris, and indirectly the iris and ciliary muscle of the eyeball, through the ciliary ganglion.

A complete *paralysis of the third nerve* accordingly causes ptosis, or drooping of the eyelid; external rotation of the eyeball, and consequent diplopia; fixation of the eyeball, save for down and outward movements; loss of power of accommodation (ciliary paralysis); and dilatation of pupil. An irritation of the third nerve causes contraction of the pupil.

The *fourth nerve* is rarely affected alone, and when it is, causes slight upward movement, with limitation of downward movement of the eyeball, and possibly diplopia.

When the *sixth nerve* is paralyzed there is convergent strabismus, with consequent diplopia, while external rotation is very slight, the obliques only being capable of rotating the eye so as to look directly forwards.

The first or *ophthalmic division of the fifth nerve* supplies

sensation by its three branches to the skin of the brow, upper eyelid, both canthi, and nose ; eyeball and conjunctiva, except that of the lower lid ; and also the nasal mucous membrane. Lesions of this branch are followed by loss of reflex blinking, and hence irritation and ulceration of the cornea frequently follow.

The third, fourth, sixth, and first divisions, of the five nerves may be pressed on and paralyzed by tumours of the orbit or sphenoidal fissure. The third nerve is frequently affected by, and gives valuable indications of, pressure in the middle fossa, arising from bleeding from the middle meningeal artery, or abscess or tumour of the temporo-sphenoidal region. Slight pressure upon it causes irritation, and hence contraction of the pupil, whereas great pressure causes paralysis with dilatation of the pupil. The sixth nerve and the optic nerve itself may be divided by orbital fractures.

The *sympathetic* supplies some unstriped fibres in the upper eyelid, the unstriped *orbitalis muscle of Müller* which bridges the sphenomaxillary fissure, and the radial or dilator fibres of the iris. In paralysis of the cervical sympathetic, therefore, there is narrowing of the palpebral fissure, recession of the globe, and contraction of the pupil.

The BLOOD-SUPPLY of the orbit is by the ophthalmic artery from the internal carotid, which pursues a tortuous course through the fat of the upper segment of the orbital cavity, gives off several branches, including the central artery of the retina, and terminates by inosculating with the angular branch of the facial. The blood returns through the superior and inferior ophthalmic veins to the cavernous sinus. As these veins communicate with those of the face and nose they form a channel for the ready extension of organisms to the cavernous sinus, resulting in *cavernous sinus thrombosis*. An *arterio-venous aneurysm* may result from communication between the ophthalmic artery and veins, or indirectly between the artery and the sinus, causing dilatation and pulsation of the veins of the eyeball and forehead. Aneurysm of the artery itself is sometimes met with, as are also *pulsating sarcomas*.

Suppurative processes occurring in the orbital cavity tend to spread rapidly, causing proptosis, with redness and swelling of the conjunctiva and eyelids, and possibly destruction of the eyeball, and by extension backwards cavernous sinus throm-

bosis. Abscesses frequently discharge at the outer side of the lower eyelid, and this is generally the best point for evacuating them.

The eyeball is situated within the orbit, rather to the nasal side of the centre, and hence, when excising, it is generally most convenient to introduce the scissors for division of the nerve from the outer side. It is invested by the **capsule of Tenon**, which may be regarded as its socket. Commencing in front at the margin of the cornea, and lying under the conjunctiva, with which it is fused at this part, the capsule passes back over the eyeball, to which it is loosely attached by areolar tissue, to the point of entrance of the optic nerve, with the sheath of which it fuses. The capsule is thus in contact on its inner surface with the globe of the eyeball, and on its outer with the orbital fat.

The tendons of the ocular muscles pierce this capsule opposite the equator of the globe, a reflection of the capsule to form a sheath being received by each of the recti muscles as they do so. At each of these reflections the capsule is strengthened by loops of fibrous tissue—the *intracapsular ligaments*—the extremities being attached to the orbital wall, while the loops pass under the muscular tendons, forming pulleys, upon which the recti muscles work, and which thus protect the globe from pressure. The ligaments supplying the internal and external recti, specially well developed and attached at their extremities to the lachrymal and malar bones respectively, are known as *check ligaments*, and limit excessive rotation of the globe inwards or outwards. The most important attachment of the capsule to the orbital wall is afforded by the **SUSPENSORY LIGAMENT OF LOCKWOOD**, which, attached at its extremities to the malar and lachrymal bones, runs across under the anterior part of the eyeball, and so supports it. This ligament is practically part of the capsule, becoming intimately fused with it as it passes under the eyeball. In excising the upper jaw it is important to preserve this suspensory ligament, otherwise the eyeball tends to sink downwards. It also forms a check ligament for the inferior rectus, while the superior rectus is checked by connection with the levator palpebræ.

The **Eyeball**, which, but for the corneal portion, is spherical, is composed of three coats. The outer consists of sclerotic

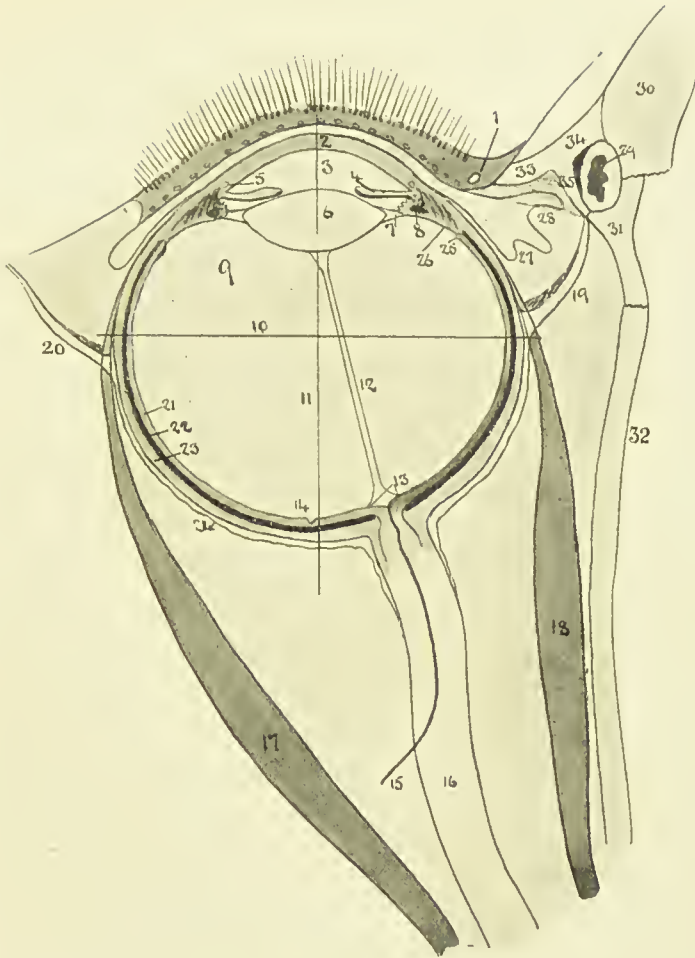


FIG. 8.—DIAGRAM OF EYE.
(After Fuchs.)

- | | |
|--|---|
| 1. Eyelid with lashes, openings of Meibonian glands and lachrymal punctum. | 17. Rectus externus. |
| 2. Cornea. | 18. Rectus internus. |
| 3. Anterior chamber. | 19. Internal check ligament. |
| 4. Iris, with posterior chamber behind it. | 20. External check ligament. |
| 5. Canal of Schlemm. | 21. Retina. |
| 6. Lens. | 22. Chorioid. |
| 7. Suspensory ligament, containing the canal of Petit. | 23. Sclerotic. |
| 8. Ciliary process, containing longitudinal and circular fibres of ciliary muscle and spaces of Fontana. | 24. Tenon's capsule. |
| 9. Vitreous surrounded by the hyaloid membrane. | 25. Ora serrata. |
| 10. Axis. | 26. Orbicularis ciliaris. |
| 11. Equator. | 27. Plica semilunaris of conjunctiva. |
| 12. Hyaloid canal of Stilling. | 28. Caruncle. |
| 13. Optic disc. | 29. Lachrymal sac. |
| 14. Fovea centralis. | 30. Nasal process of upper jaw. |
| 15. Central artery of retina. | 31. Lachrymal bone. |
| 16. Optic nerve. | 32. Orbital plate of ethmoid. |
| | 33. Inner palpebral ligament. |
| | 34. Anterior limb of palpebral ligament. |
| | 35. Posterior limb of ligament with Horner's muscle (tensor tarsi) springing from it. |

and cornea ; the middle of chorioid, ciliary body, and iris ; and the inner of the retina. Where the antero-posterior diameter of the eyeball is normal, the eye is said to be emmetropic ; where too short, a condition of hypermetropia is produced ; and where it is too long, myopia exists. *Hypermetropia* is corrected by the use of a convex lens, which brings the rays more quickly to a focus ; and *myopia* by a concave lens, which delays the convergence.

Outer Coat.—The SCLEROTIC is a dense, unyielding, non-vascular structure, which does not readily become inflamed nor yield to pressure. This latter characteristic accounts for the pain from pressure on the nerves experienced in increased intra-ocular tension, as in *glaucoma*. The weakest part of the sclerotic is at the optic disc, which yields to increased tension, producing the glaucomatous cup, while, with a further increase of pressure, the eyeball expands laterally rather than vertically. When *rupture* of the globe occurs from violence, it is generally the sclerotic which gives way, the rent occurring through the thinnest part, near the corneal junction.

The CORNEA, which is transparent, and convex in shape, converges parallel rays of light upon the lens. Not infrequently it is irregularly curved, the curvature being generally greatest in the vertical meridian, thus giving rise to *astigmatism*. Occasionally it has a conical shape (*keratoconus*). The posterior elastic lamina of the cornea, or *membrane of Descemet*, is of importance, as it shuts off the cornea from the aqueous humour, and so preserves its translucency. It also prevents the invasion of leucocytes from the anterior chamber in inflammatory processes, which therefore collect in the chamber, causing *hypopyon*. It must, therefore, not be broken through in operating for opacity by transplanting rabbit's cornea.

This posterior elastic lamina sends peripherally radiating fibres into the iris—*ligamentum pectinatum iridis*—and in this ligament are a number of *spaces of Fontana*, which afford communication between the anterior chamber and the canal of Schlemm. The *canal of Schlemm* is a circular venous sinus situated at the junction of cornea and sclerotic, and embedded in the tissue of the junction. The cornea after birth has no bloodvessels, except near the margin, where they form loops, but is nourished by abundant lymph streams derived from

these marginal vessels, and returned to the circular venous channel or canal of Schlemm.

Despite the absence of bloodvessels, the cornea has a marked vitality, and *wounds* heal readily, sometimes leaving no subsequent opacity. *Ulcers*, on the other hand, frequently cause opacity, owing to their causing considerable destruction of tissue, which is replaced by connective tissue. Corneal ulcers may lead to perforation, with escape of the aqueous humour and prolapse of the iris, which may become adherent (*anterior synechiæ*). Vascularization of the cornea, however, does occur, a superficial form called *pannus* being frequently associated with conjunctivitis, while a deep vascularization, generally associated with keratitis, may also occur, and is called a *salmon patch* when the vessels form close leases.

The cornea is richly supplied with *nerves*, derived from a plexus round its periphery, supplied by the ciliary nerves. The branches from the plexus ramifying in the cornea have no medullary sheath. In consequence of the rich sensory nervous supply, inflammation of the cornea, *keratitis*, is painful, and accompanied by photophobia or intolerance of light. The painfulness gives rise to excessive lachrymation, and the photophobia to *blepharospasm*, or spasm of the orbicularis muscle, both conditions being reflex. In glaucoma, on the other hand, the pressure on the nerves produces anæsthesia of the cornea. Herpes, or *zona ophthalmica*, also occurs occasionally on the cornea.

Arcus senilis is a degeneration of the corneal tissues, confined to the periphery, generally appearing as a crescent, first in the upper segment, and followed by a second in the lower segment, the two fusing later. It is frequently associated with general atheroma of the vessels, but does not interfere with the healing of corneal wounds.

The **middle coat** of the eyeball, or **uveal tract**, consists of iris, ciliary body, and choroid, and possesses a rich vascular supply.

The IRIS, or diaphragm, attached peripherally to the ciliary processes, and to the cornea by the ligamentum pectinatum iridis, and perforated a little to the nasal side by the *pupil*, hangs in front of the lens, the pupillary margin resting upon, but not attached to, the anterior surface of the lens capsule. It is covered by epithelium on both surfaces, is furnished with

sphincter and dilator muscular fibres, and is pigmented. In *albinos* there is no pigment, and the red colour of the iris is due to the rich vascular supply. In blue eyes the pigment is confined to the posterior layers, while in brown eyes it is scattered throughout. In some cases the pupil may be displaced peripherally and present an oval outline (*corectopia*), or more than one pupil may be present (*polycoria*). The peripheral attachment of the iris is not a very strong one, and may be detached by injury without damage to the other structures. It is also easily detached in the operation of *iridectomy*, where a radiating portion of iris is removed, producing a *coloboma*, bleeding being arrested by muscular contraction. *Congenital coloboma*, due to persistence of the chorioidal fissure, generally occurs at the lower and inner quadrant. After removal of the lens, the iris loses its chief support, and becomes 'tremulous.' Congenital absence of the iris, *irideremia*, may occur.

The CILIARY BODY connects the periphery of the iris with the chorioid. In structure it resembles the chorioid. Immediately behind the iris the ciliary body is thrown into a series of some seventy radiating folds—the *ciliary processes*—and is further rendered prominent by the development of the *ciliary muscle* in its middle coat. The ciliary processes contain large tortuous vessels, are covered with two layers of epithelium, continuous with that of the retina (*pars ciliaris retinæ*), and are supposed to secrete the aqueous humour. The ciliary muscle consists chiefly of radial fibres springing from the junction of cornea and sclerotic, and from the *ligamentum pectinatum*, to be inserted into the ciliary processes and *orbiculus ciliaris* (*q.v.*). Besides giving attachment to the iris anteriorly, the ciliary processes give attachment to the *suspensory ligament of the lens* posteriorly. The lens has an inherent tendency to become more convex, but is prevented by the tension kept upon it by the capsule. When, however, by a contraction of the ciliary muscle the ciliary processes are pulled forwards and inwards, the capsule is relaxed, and the lens becomes more convex. This contraction of the ciliary muscle occurs in *accommodation* for near objects, and is associated with contraction of the pupil. The portion of the ciliary body nearest the chorioid is called the *orbiculus ciliaris*, and here the ciliary processes fade into a large number

of faintly marked radiating ridges, which interdigitate with others in the zonule of Zinn, which invests the vitreous body at this part.

The CHORIOID, which is the most extensive part of the middle coat, reaching from the entrance of the optic nerve to about $\frac{3}{15}$ inch from the corneal margin, consists of three layers. The outermost layer, or *stratum vasculosum*, is pigmented, and contains large branches of the short posterior ciliary arteries and, more superficially, large veins, which in converging form whorls, and open into the *venæ vorticosæ*. The middle coat, or *lamina chorio-capillaris*, is composed of capillaries, while the innermost layer, or *lamina basalis* (membrane of Bruch), is transparent and almost structureless.

Externally the chorioid is in contact with the sclerotic, to which it is firmly attached at the point of entrance of the optic nerve, while in front of this it is loosely attached by the vessels and the loose *lamina fusca*. Internally it is in contact with the pigmented layer of the retina. Extensive *hæmorrhage* from injury, or sudden decrease of intra-ocular tension as in cataract operations, not infrequently occurs between the coats. The chorioid may be *ruptured* by a blow, and *melanotic sarcoma* may arise from it.

Owing to its rich vascular supply, the uveal tract is particularly prone to inflammatory affections. Thus *iritis* is not infrequently seen resulting from trauma or late secondary syphilis. Such inflammations are apt to spread to the ciliary region (*irido-cyclitis*), or to the entire uveal tract, destroying the eyeball (*phthisis bulbi*), and, in the septic type, by extension along the lymphatics of the optic tract, not infrequently involves the other eye (*sympathetic ophthalmia*). Hence excision of the affected eyeball is frequently performed as a preventive measure, or evisceration of the globe, leaving the posterior sclerotic to act as a cup for the artificial eye, may be done (Mule's operation). Owing to the extensive destruction which is apt to follow septic infection of the ciliary region, it has been termed the *dangerous area* of the eye. In *iritis* the anterior ciliary vessels are engorged, producing the characteristic red circumcorneal zone; the pupil becomes contracted from spasm; the inflammatory exudate infiltrates the iris itself, causes adhesions (*posterior synechiæ*) to the lens, and turbidity of the aqueous humour.

The RETINA constitutes the **innermost** of the three coats of the eyeball. Commencing at the point of entrance of the optic nerve, which lies to the nasal side of the direct optic axis, it ends in a wavy line, the *ora serrata*, a short distance behind the ciliary body. A prolongation from the retina, consisting of an outer pigmented and an inner epithelial layer, is, however, continued from the retina beyond the ora serrata over the ciliary body and posterior surface of the iris, and these are termed the *pars ciliaris retinae* and *pars iridica retinae* respectively. The retina, in which the fibres of the optic nerve are spread out, consists of an outer pigmented layer, which is attached to the chorioid externally, and an inner nervous layer, which is in contact with the hyaloid membrane of the vitreous internally. The point of entrance of the optic nerve, or *blind spot*, is marked by the *optic disc*, which is slightly raised peripherally and cupped centrally. The optic nerve, like the other cranial nerves, receives a sheath both from the dura and the pia-arachnoid, and these sheaths extend to the optic disc. Thus intracranial inflammatory or congestive conditions may easily affect the optic disc. In *optic neuritis* the optic disc, which normally is well defined and of a faint pink tint, which contrasts sharply with the red reflex of the fundus generally, becomes swollen and blurred, while the vessels become engorged and tortuous. Optic neuritis occurs in cases of cerebral tumour, and sometimes of abscess, and is said to be due to intracranial pressure. Where optic neuritis has persisted it may be followed by *optic atrophy*, in which the disc is sharply defined and brilliantly white, while the vessels become diminished in calibre. In glaucoma the normal cupping of the disc becomes much more marked, forming the *glaucomatous cup*.

The *central artery* of the retina, which supplies the retina with blood, runs forward, accompanied by its vein, in the optic nerve, until it reaches the papilla, where it divides into an upper and lower branch, each of which again almost immediately divides. As the anastomosis of the central artery is almost negligible, complete *thrombosis* or embolism of the central artery is followed by blindness. Both upper and lower branches of the artery supply blood to the yellow spot. In embolism of the central artery both the disc and the vessels become white.

The *macula lutea*, or yellow spot of the retina, is situated in the direct optical axis, is somewhat oval in shape, raised at the margin, and presents a central depression, the *fovea centralis*. In the macula, which constitutes the region of distinct vision, the structure of the retina is much modified, till in the fovea only the layers of cones and of cone fibres are present.

The retina sometimes becomes *detached* from blows on the eyeball and idiopathically. The only tumour which affects it is *glioma*, which occurs in young children and is very malignant. It increases the intra-ocular tension (*secondary glaucoma*), and may cause detachment of the retina. It involves the whole eyeball, and causes rupture, with formation of a fungus hæmatodes, and also involves the optic nerve, by which it may extend to the brain. Secondary deposits may be found in the liver. *Retinitis* of many forms occurs, such as hæmorrhagic, syphilitic, and albuminuric.

The space between cornea and lens, which is occupied by the aqueous humour, is divided into a large ANTERIOR and very small POSTERIOR CHAMBER by the iris. The AQUEOUS HUMOUR is secreted by the ciliary processes, situated behind the iris in the posterior chamber, passes thence between lens and iris and through the pupil of the iris into the anterior chamber, where it is absorbed peripherally by the spaces of Fontana, which communicate with the canal of Schlemm, and are situated in the angle between cornea and iris (*filtering angle*).

Glaucoma is a disease in which there is greatly increased *intra-ocular tension*. This increased tension is caused by obliteration of the filtering angle, preventing the escape of effete aqueous humour, which thus accumulates. It occurs generally in old persons, and is associated with marked cupping of the optic disc, which is surrounded by a glaucomatous ring. Iridectomy is frequently performed, with a view to restoring the filtering angle, and thus reducing the pressure.

The LENS is situated between the portion of the eyeball containing the aqueous humour in front and the portion containing the vitreous behind. The vitreous humour, enclosed in its hyaloid envelope, presents anteriorly a deep concavity, the *fossa patellaris*, into which the posterior surface of the lens fits. The lens is held in position by its *suspen-*

sory ligament, derived from the zonule of Zinn (*q.v.*), and is enclosed in a transparent *capsule*. This capsule separates it from the aqueous humour, and when it is ruptured by trauma the fluid enters the lens, causing swelling and opacity (*traumatic cataract*). The posterior surface of the lens is more convex than the anterior, which, however, becomes increasingly convex, owing to the elasticity of the lens, when the capsule is relaxed by the action of the ciliary muscle in accommodation for near objects. This elasticity of the lens diminishes with age, as does likewise the refractive power, and hence the near point (the nearest point from which it is possible to converge the rays upon the retina) becomes more distant. This condition is known as *presbyopia*, and requires for its treatment a convex lens. In later life diminished energy of the ciliary muscle is also a factor. The axis of the lens runs from before backwards through the centre of the pupil, and its extremities are termed the anterior and posterior *poles* of the lens, while the *equator* of the lens is its peripheral circumference. *Cataract* is the only disease of the lens. It consists of an opacity, which may be partial or complete. The partial forms are generally congenital, while the complete are most frequently due to senile changes, but also arise from diabetes and trauma, especially where the anterior capsule of the lens has been penetrated. The treatment is generally *extraction* of the affected lens, a strong convex lens being subsequently employed to correct the hypermetropia.

The VITREOUS BODY, consisting of a transparent gelatinous material, occupies the portion of the eyeball between lens and retina, which constitutes about four-fifths of the whole. In shape it is roughly spherical, save for the patellar fossa in front, and it is enclosed in the *hyaloid membrane*, which is in contact with the internal limiting membrane of the retina, and adherent to it at the optic entrance. In front of the ora serrata the hyaloid membrane becomes thickened and constitutes the *zonule of Zinn*. The zonule presents radiating ridges alternating and fitting between those of the ciliary processes. The ciliary ridges are adherent to the fossæ of the zonule, but the ciliary fossæ are not adherent to the zonular ridges, lymph spaces intervening. As it approaches the equator of the lens the zonule splits into two layers—an inner, which covers the anterior portion of the vitreous and

presents the fossa patellaris, and an outer stronger layer, which blends with the front of the lens capsule near the equator and constitutes the *suspensory ligament* of the lens. The suspensory ligament is fenestrated, and through the gaps in it the fluid in the anterior chamber can communicate with the *canal of Petit* (which is a sacculated lymph space surrounding the equator of the lens, situated behind the suspensory ligament), and also with the fossæ between the ciliary ridges. A lymph channel, the *hyaloid canal of Stilling*, which represents the foetal hyaloid artery, runs from the optic papilla, through the vitreous, to the posterior surface of the lens. Sometimes the hyaloid artery persists, but as a rule special treatment is necessary to render even the canal of Stilling visible. The vitreous may be affected by extension of inflammatory processes from other parts; by suppurative processes from penetrating wounds or the lodgment of foreign bodies; by hæmorrhages, and by undue fluidity. It may shrink from the retina, detachment of the retina frequently following. *Muscæ volitantes* are frequently complained of by myopics, and are due to minute remains of embryonic tissue in the vitreous, and motes are also frequently seen in commencing cataract.

The eyeball derives its BLOOD-SUPPLY from branches of the ophthalmic division of the internal carotid. These consist of (1) central artery of the retina, which supplies the retina, and anastomoses slightly at its margin with (2) the short ciliary arteries, some eight in number, which pierce the sclerotic near the optic nerve, and, breaking up into a capillary plexus, supply the chorioid; (3) the two long ciliary arteries, which, piercing the sclerotic to the outer side of the optic nerve, run forward to the base of the iris, anastomose with the anterior ciliary, and form the *circulus arteriosus major*, which supplies the ciliary muscle, and send branches into the iris to form the *circulus arteriosus minor*; (4) the anterior ciliary arteries, small twigs from the muscular and lachrymal branches of the ophthalmic, which penetrate the sclerotic near the corneal junction, and anastomose with the posterior ciliary. They supply the conjunctiva and the plexus round the circumference of the cornea. This plexus is normally invisible, but in iritis it forms a pink circumcorneal zone of fine, closely-set, nearly parallel vessels.

The *canal of Schlemm* is a circular venous channel embedded in the corneo-scleral junction, which communicates with the anterior chamber by the spaces of Fontana. Its blood is removed by the anterior ciliary veins, which fall into the *venæ vorticosæ*.

The *venæ vorticosæ*, some four or five in number, are the chief veins of the eyeball. They run in the outer layer of the chorioid (external to the arteries), and pierce the sclerotic near the equator of the globe, to fall into the *ophthalmic vein*.

The NERVES of the eyeball are derived from the nasal branch of the ophthalmic of the fifth, which sends in two long ciliary nerves, and also supplies a root to the ciliary ganglion (sensory). The motor root of the ganglion is supplied by the third nerve, and there is also a sympathetic root. From the ganglion some twelve short ciliary nerves pass to supply the various coats of the eyeball, the third nerve enervating the ciliary muscle and the circular (contractor) fibres of the iris, and the sympathetic the radial or dilating fibres of the iris.

In inflammatory affections of the globe pain is frequently referred to both upper branches of the fifth, affecting the circumorbital, nasal, and temporal regions, and the upper jaw and teeth, and is accompanied by profuse lachrymation and blepharospasm from communications between the fifth and seventh nerves. Irritation of the nasal branch of the fifth also frequently leads to watering of the eye.

The PUPIL is contracted by the third nerve, and dilated by the cervical sympathetic, these effects being involuntary, except in so far as they can be brought into action by accommodation. *Accommodation* is required for near objects, the lens being rendered more convex by the action of the ciliary muscle, acted on by the third nerve, while the iris contracts. One can therefore make the iris contract by accommodating for a near object. In locomotor ataxy the reflexes are lost, and therefore the pupil will not contract to light, as such contraction is reflex, but it will contract on accommodation for near objects, as accommodation is voluntary. This condition is known as the *Argyll-Robertson pupil*.

The pupil is *contracted* in normal sleep, in those following occupations necessitating close attention to small work (weaver's eye), in conditions where the brain is engorged with blood, in coma, in bleeding under the tentorium, and in small

lesions of the pons. It is also contracted in irritation of the third nerve or paralysis of the cervical sympathetic. Certain drugs also cause contraction, eserine acting locally, morphia probably both locally and generally, and chloroform and alcohol (coma) generally. The effect of CHLOROFORM on the pupil is of particular importance surgically, as, when the pupil is contracted and fixed the reflexes are abolished, and one may safely operate. The alcoholic pupil is contracted, but not fixed, as it will slowly dilate on stimulation of the patient.

The pupil is *dilated* in nightmare, generally in blindness, in anæmia of the brain, faintness, and concussion. It is also dilated by paralysis of the third nerve or irritation of the cervical sympathetic. Atropine causes dilatation by acting locally. The pupil becomes dilated and fixed when chloroform is pushed too far, and, speaking generally, it dilates in all cases where death is impending.

The ORBITAL CAVITY, consisting of a strong bony margin anteriorly, but of very thin, delicate bones internally, is subject to fractures and to affection by some tumours. The *orbital plate of the frontal* is frequently broken by extension of *fractures* of the vault, and by thrusts of sharp-pointed instruments into the eyeball, the anterior lobes of the brain being sometimes thereby involved. Effused blood in such cases may cause proptosis, and ultimately find its way forward under the conjunctiva and under the eyelids. It is distinguished from black eye by its much slower appearance, its patchiness, and by its not being circumscribed at the orbital margins. The *inner orbital wall* may be similarly fractured, and, if the nasal mucous membrane be torn, may give rise to emphysema of the orbital tissues, while in fracture of the *inferior orbital wall* the superior maxillary nerve is apt to be damaged, and the antrum of Highmore opened into. The outer and upper margin of the orbit is the most common site of *dermoid cysts*. *Ivory exostoses* sometimes occur about the orbital margin, giving rise to displacement of the eyeball, with proptosis. *Sarcomata* springing from the orbit itself, or invading it from the antrum of Highmore, the base of the sphenoid, or the temporal or zygomatic fossæ, have similar effects. The contents of the orbital cavity consist of the eyeball, optic nerve, muscles, nerves, and vessels ensheathed in fatty tissue and fascia.

THE NOSE.

The *skin* of the nose is thin and movable over the nasal bones, but below is thick and adherent to the cartilage, and abundantly supplied with sweat and sebaceous glands. The lower portion is frequently affected by *acne rosacea*, which in cases of chronic dyspepsia sometimes causes considerable hypertrophy, to which the misleading name of 'grog-blossoms' has been given. *Lipoma nasi* is a diffuse irregular enlargement of the same portion, all the tissues, but especially the fatty elements, hypertrophying. *Suppurative processes* in this region are generally very painful, owing to the density of the tissue and the abundant nerve-supply. The upper part is supplied by the infratrochlear branch of the nasal, the middle by branches of the infra-orbital, and the lower by the nasal. The nasal nerve, being a branch of the ophthalmic of the fifth, explains the watering of the eyes, which occurs from painful affections of the nostril. The skin of the nose is plentifully supplied with blood by branches of the ophthalmic and facial arteries, and hence healing of *wounds* occurs very readily. Indeed, a portion of nose which had been cut off, but kept warm, has been successfully stitched on after an interval of nearly half an hour. On the other hand, on account of its exposed position, the nose is sometimes affected by *frost-bite*. The nose tends to become engorged with blood, especially in alcoholics, and sometimes becomes livid in persons suffering from obstructive heart disease, etc. While rodent ulcer sometimes attacks the skin at the junction of the ala and cheek, the cartilaginous portion of the nose is not infrequently destroyed by tubercular (*lupus*) and syphilitic *ulcerations*. Each ALA of the nose is supported by an upper and lower lateral cartilage and several accessory cartilages. The upper cartilage is attached to the nasal bone and superior maxilla, and the lower one does not extend as far as the nostril. A nasal *speculum* should not be introduced beyond the limits of this cartilaginous portion. Various plastic operations (*rhinoplasty*) have been devised to remedy defects of the nose. In the *Tagliocotian* operation a flap is raised from the front of the upper arm, which is fixed in front of the face, and not separated from the arm until it has united to the face. A flap also has been cut from the forehead, and turned down to

form a nose, the frontal artery supplying it with blood. The NASAL BONES are not infrequently *fractured* by direct violence, especially in their lower third. Such fractures are generally accompanied by considerable deformity, and, as the mucous membrane of the nose is generally lacerated, are compound. Free epistaxis and emphysema of the surrounding tissues, especially on blowing the nose, are liable to occur. As the nasal bones heal very readily (about seven days, according to Hamilton), an early attempt should be made to rectify any deformity, and as the meatus is rendered particularly narrow by the swelling of the parts, only a fine instrument (stout probe) should be introduced to aid the process. In some very severe injuries the nasal septum may also be damaged. The nasal bones are frequently affected in infancy by hereditary syphilis, causing a permanent depression of the bridge of the nose, while the infant also 'snuffles.'

The NASAL FOSSÆ, separated by the septum, include the anterior and posterior nares. The *anterior nares*, or apertures of the nostrils, are small, directed downwards, and are on a lower level than the fossæ. The *posterior nares*, choanæ, or posterior outlets, communicate with the naso-pharynx.

The NASAL SEPTUM consists of the nasal spine of the frontal bone, vertical plate of the ethmoid, rostrum of the sphenoid, the vomer, and the palatal crests of the palate and superior maxillary bones, while the interval is filled in by the cartilaginous septum.

The *cartilaginous nasal septum* is generally deflected after the seventh year, due probably to continuation in vertical growth in the bones after they have met, or perhaps to the habit of blowing the nose with one hand. It is frequently attacked in acquired syphilis, producing *perforation* or even destruction, with consequent flattening of the nose, chrome-workers sometimes suffering from a similar affection. Congenital syphilis generally produces a depression of the bridge of the nose, and both forms may involve the bony framework, sometimes causing perforation of the hard palate.

The *roof* of the nasal fossæ is arched, and formed anteriorly by the groove in the nasal bones, then by the cribriform of the ethmoid, and posteriorly by the sphenoidal turbinates. Its narrowness ($\frac{1}{8}$ inch) protects it to a large extent from injury from all but sharp-pointed instruments. The *lym-*

phatics of the nose run along the sheaths of vessels and nerves through the cribriform to the meninges, and thus *meningitis* may follow a septic condition in the nose.

Fracture involving the cribriform plate is sometimes associated with escape of cerebro-spinal fluid, the membranes being ruptured. *Meningoceles* occasionally protrude through the nasal roof, and may be mistaken for polypi; but they more frequently present externally at the root of the nose through the suture between the nasal and frontal bones, where they have been mistaken for *nævi*.

THE OUTER WALL.—Extending upwards and inwards from the anterior nares to the bony apertures of the fossa are the *vestibules*, which are lined with skin containing numerous stout hairs and sebaceous glands. Skin and mucous membrane meet at the junction of vestibule with *atrium*, which latter leads particularly into the middle meatus, its upper portion leading to the superior meatus, being partially cut off by a prominence known as the *agger nasi*.

The *nasal (Schneiderian) membrane* is covered throughout by columnar ciliated epithelium, and consists of *olfactory* and *respiratory* portions. The former invests the upper portion of the cavity and both walls to the level of the centre of the middle turbinate. It is thin, of a yellow colour, and contains olfactory glands of Bowman, and olfactory cells which are directly continuous with the terminal nerve filaments of the olfactory nerve, and end in olfactory hairs. The respiratory portion is thick and more vascular, especially over the lower borders of the middle and inferior turbinates, where the tissue is practically cavernous. The portion covering the inferior turbinate is called the *erectile body*. On account of its vascularity the mucous membrane readily becomes congested, even in ordinary colds, causing blocking of the nose, and in long-continued cases gives rise to a *hypertrophic rhinitis*. The posterior end of the inferior turbinate is particularly prone to hypertrophy, and may project into the posterior nares, block the Eustachian tube, and be mistaken for a tumour. In *ozæna*, or *atrophic rhinitis*, there is a persistent purulent discharge from the nostril, the offensive nature of which is not perceived by the patient, as his sense of smell is lost. In such cases it is frequently necessary to wash out the nose. This is done by use of the *nasal douche*, the nozzle of which

is introduced through one nostril, while the patient keeps the mouth wide open. The palate then arches up and shuts off the cavity of the nose from the pharynx, and so the fluid runs up one nostril, turns posteriorly, and comes down the other.

Nasal polypi are generally myxomatous, covered with columnar ciliated epithelium, and grow from the lower border of the middle turbinate. *Malignant tumours* are generally sarcomatous, and often spring from the base of the skull, from whence they invade the nasal cavities, distending them and giving the patient a 'frog face.'

The *blood-supply* is derived from the spheno-palatine branch of the internal maxillary artery, which enters the fossa posteriorly through the spheno-palatine foramen and supplies the outer wall and septum, and also from the ethmoidal branches of the ophthalmic and small branches of the superior coronary of the facial and of the descending palatine of the internal maxillary. The veins carry the blood forwards to the facial, backwards to the spheno-palatine, and upwards to the ethmoidal veins. These latter are very important, as they communicate with the veins of the dura and of the brain itself, as is likewise an inconstant communicating vein which runs from the nose through the foramen cæcum to the superior longitudinal sinus.

The *lymphatics* lead chiefly to the deep cervical glands, so that retropharyngeal abscess may arise from septic infection of the nose, but those from the olfactory region communicate with the subarachnoid space. Thus, both through the venous and lymphatic channels mischief may reach the brain from the nose.

Bleeding from the nose, or epistaxis, may be very troublesome and profuse, and even fatal. The fact that it is sometimes checked by holding the hands above the head is supposed to be due to the increased suction action of the chest lessening the venous congestion.

Beyond the atrium the outer wall is complicated by the TURBINAL BONES, the two upper of which belong to the ethmoid, while the inferior is a separate bone. These bones project inwards and downwards from the outer wall toward the septum, which, however, they do not touch, a space intervening, through which part of the inspired air passes. They are curled on themselves, so that their free margins are

directed outwards. They each, therefore, roof over a meatus, which is named from the bone which forms its roof. The superior turbinal is the smallest, extending forward to about the centre of the cribriform; the middle turbinal extends forward to the level of the anterior end of the cribriform; while the inferior extends anteriorly to within $\frac{3}{4}$ inch of the anterior nares and posteriorly to within $\frac{3}{8}$ inch of the Eustachian tube.

If these bones be removed, the meati can be examined. The SUPERIOR MEATUS is very small, and presents apertures leading into the posterior ethmoidal cells. The MIDDLE MEATUS presents anteriorly a thin grooved ridge of bone, curving downwards and backwards. This is the *uncinate process* of the ethmoid, and it is separated from the *bulla ethmoidalis* (a rounded prominence containing some ethmoidal cells which lies posteriorly and above the uncinatè process) by a deep groove, the *hiatus semilunaris*. This hiatus opens along its outer surface into the *infundibulum*, which has the same boundaries and with which it runs parallel. At its upper and anterior extremity the infundibulum generally receives the *fronto-nasal duct* leading from the frontal sinus and the *ostia* of the anterior ethmoidal cells. At its lower end, beneath the bulla, and concealed by the uncinatè process, the ostium of the maxillary sinus opens into it. One or two small apertures above the bulla lead to the middle ethmoidal cells. The bulla sometimes hypertrophies, presses the middle turbinal against the septum, which may yield, thus leading to considerable blockage of the nose. The middle meatus has a wide anterior opening, which favours the passage of inspired air along it, and in passing an instrument into the nose, unless care be taken to keep its point on the nasal floor, it is very apt to pass into the middle fossa. The INFERIOR MEATUS has a curved *roof*, the highest point being at the junction of its anterior and middle thirds. At this point also the outer wall frequently bulges into the antrum, thus increasing the size of the meatus. Here the *nasal duct* opens by a narrow slit close to the meatal roof, $\frac{3}{4}$ inch above the floor. This height of the meatus should be kept in mind in introducing a *Eustachian catheter*, which might not pass if too much curved. The *floor*, composed of the palatal processes of the superior maxillary and palate bones, is over $\frac{1}{2}$ inch in width, is smooth, slightly concave from side to side, and slopes gently

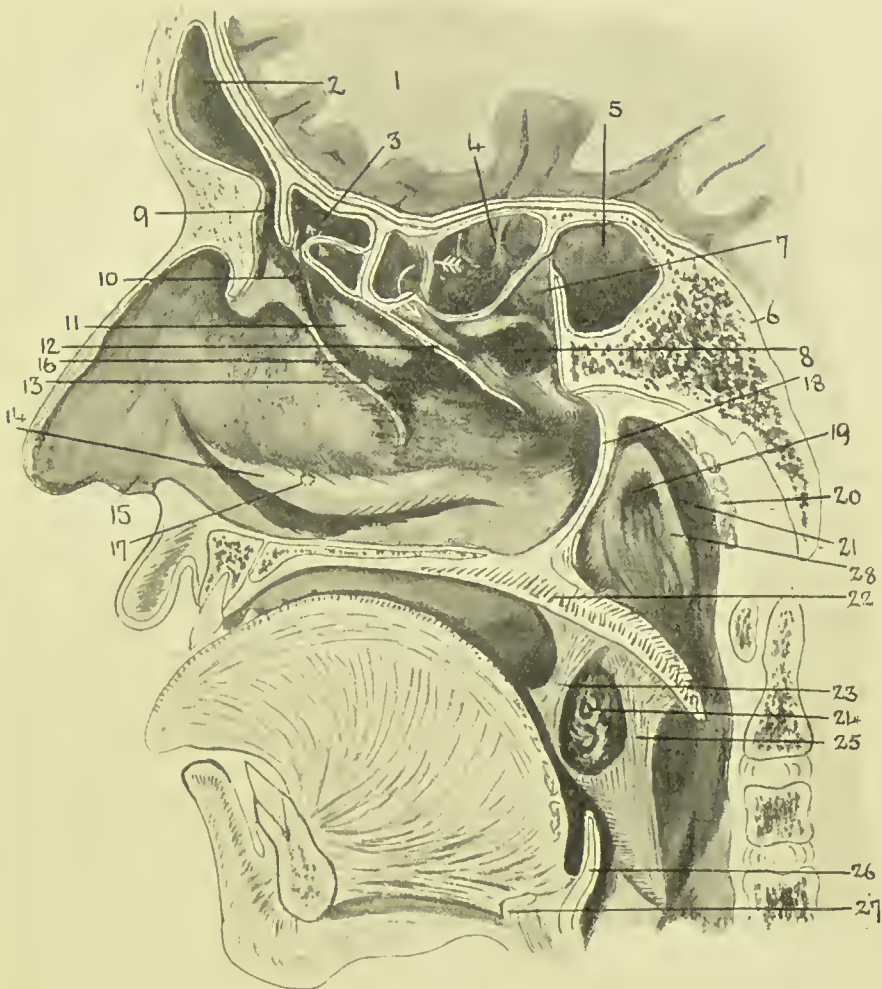

FIG. 9.—DIAGRAM OF NASAL CAVITY, ETC.
(Modified from Turner, etc.)

- | | | |
|---------------------------|--|--|
| 1. Brain (frontal lobe). | 12. Cut edge of middle turbinal bone. | 20. Pharyngeal tonsil. |
| 2. Frontal sinus. | 13. Processus uncinatus. | 21. Lateral recess, or fossa of Rosenmüller. |
| 3. Ant. ethmoidal cells. | 14. Inferior turbinate bone. | 22. Palate. |
| 4. Post. ethmoidal cells. | 15. Vestibule. | 23. Ant. pillar of fauces. |
| 5. Sphenoidal sinus. | 16. Hiatus semilunaris. | 24. Tonsil. |
| 6. Sphenoid bone. | 17. Position of orifice of nasal duct. | 25. Post. pillar of fauces. |
| 7. Spheno-ethmoid recess. | 18. Posterior edge of nasal septum. | 26. Epiglottis. |
| 8. Superior meatus. | 19. Orifice of Eustachian tube. | 27. Hyoid bone. |
| 9. Fronto-nasal duct. | | 28. Salpingo-pharyngeal fold. |
| 10. Infundibulum. | | |
| 11. Ethmoidal bulla. | | |

downwards and backwards. It is frequently necessary to *plug the posterior nares* in cases of bleeding. This is done by passing a loop of stout thread by means of a special sound or ordinary catheter through the nose to the pharynx, where it

is caught from the mouth and drawn forwards. A plug of a size to fit the posterior nares, which measure about $1\frac{1}{4}$ inches vertically and $\frac{1}{2}$ inch transversely, is then fixed to the loop, by which it is drawn up into the nares. The ends are then tied to another plug applied over the nostril. It is well to attach a single thread to the plug for the posterior nares before pulling it into position, by which it may be withdrawn when done with. The nasal cavities may be *explored* by passing one finger up the nostril and another through the mouth, and *polypi* may sometimes be so removed. Where it is necessary to get a full view of the nares an almost median dorsal vertical incision may be made through the nostril (Kocher), or the upper lip may be everted, mucous membrane incised, and soft parts shelled up (Rouge). An ordinary *examination* may be made by introducing a speculum, elevating the nostril and tip of the nose, and using a forehead mirror. The posterior nares may be inspected by *posterior rhinoscopy*, using the forehead mirror and a small laryngeal mirror introduced through the mouth behind the soft palate. Foreign bodies are not infrequently found in the nose, some of which may have lodged there for many years, and these sometimes form the nucleus for a deposition of calcareous matter, such masses being called *rhinoliths*. The *olfactory nerve* supplies the upper or olfactory portion of the nose, and, as little air passes through this portion in ordinary respiration, it is usual to sniff when endeavouring to perceive an odour. The loss of ability to dilate the nostril, as in sniffing, may explain the partial loss of smell in facial paralysis. As already explained, the relationship of the nerve supply of the eye and nose derived from the ophthalmic of the fifth is very close. Thus, when the nose is irritated the eye waters, as in taking snuff, and when the eye is exposed to bright sunlight sneezing is sometimes produced. In *nasal obstruction*, not merely is respiration interfered with, but the voice is altered, and smell and taste suffer, while a form of asthma also sometimes develops. This asthma is probably due to a reflex from the fifth along fibres of the vagus derived from the fifth, and is generally cured on removal of the nasal obstruction.

The **ACCESSORY SINUSES** of the nose are important on account of their frequent involvement in nasal affections. The sinuses to be considered consist of two groups—a posterior,

opening above the middle turbinate, and consisting of the sphenoidal and posterior ethmoidal ; and an anterior, opening below the middle turbinate, and consisting of anterior ethmoidal, frontal, and superior maxillary. With the exception of the ethmoidal cells, which, unlike the others, are not formed by absorption of diploic cancellous bone, these sinuses are either non-existent or rudimentary at birth—the antrum of Highmore, for example, consisting of a slit-like indentation.

The Posterior Group.—The SPHENOIDAL SINUSES occupy the anterior portion of the body of the sphenoid, and are separated from one another by an osseous septum. Occasionally one or both may be absent, and they vary considerably in size. When large, the olfactory peduncle, optic commissure, pituitary body, and pons lie on the thin roof, while the optic nerve and ophthalmic artery lie on the superior external aspect, and the internal carotid artery, cavernous sinus, and structures occupying the sphenoidal fissure are in relation to the external lateral wall. The floor is sometimes thin, and under it lies the Vidian nerve. The sinus is sometimes invaded by tumours of the pituitary, and, on the other hand, septic conditions of the sinus may lead to involvement of the optic nerves, cavernous sinus, etc. The *ostium* is situated on the anterior wall, near the roof, and opens into the spheno-ethmoid recess on the internal surface of the superior turbinate. It does not, therefore, facilitate drainage ; it is sometimes so small that it will not admit a probe, and it is generally necessary to remove a portion of the middle turbinate before an instrument can reach it from the nose. It lies fully 3 inches from the nasal vestibule, at an angle of nearly 45 degrees upwards and backwards from the nasal floor.

The ETHMOIDAL CELLS, situated in the lateral mass of the ethmoid, vary in number and size, and are divided into posterior and anterior sets, which, as a rule, do not communicate, by an oblique lamina of bone. Externally they are bounded by the os planum of the ethmoid, internally by the superior and middle turbinates, above by the orbital plate of the frontal, and below by the orbital plate of the superior maxilla. Anteriorly they are closed in by the nasal process of the superior maxilla and the lachrymal bone, and posteriorly by the sphenoidal spongy bones.

The *posterior ethmoidal cells* rarely communicate with the

sphenoidal sinus, but sometimes project into the body of the sphenoid, giving rise, when infected, to symptoms similar to those of sphenoidal sinus infection.

These cells open into the superior meatus by one or more ostia and are very inaccessible. A purulent discharge may find its way posteriorly into the naso-pharynx or anteriorly into the nose.

The *anterior ethmoidal cells* are closely related to the floor of the frontal sinus, in which they not infrequently form a projection called the *bullæ frontalis*. They may also project upwards along the roof of the orbit, and downwards into the roof of the antrum of Highmore, and may thus, when infected, cause symptoms simulating disease of these sinuses, which may actually become involved by destruction of the thin bony septa.

The *ethmoidal bulla*, already spoken of, situated at the antero-inferior border of the lateral mass, also contains one or more cells, and further cells may be found in the middle and inferior turbinate bones. These latter (owing to blockage of the duct in nasal catarrh) sometimes become transformed into *mucocèles*, which may be so large as to obstruct the nasal passage.

Several ostia open into the infundibulum on its outer and posterior aspect, and not infrequently the infundibulum itself originates in the cells forming the *bullæ frontalis*. Other ostia open directly into the middle meatus. Inflammatory conditions of the cells are frequently associated with the presence of soft polypi in the nose, and with dacryocystitis (inflammation of the lachrymal sac), while extension to the orbit or cranial cavity is to be feared.

The **FRONTAL SINUSES** are situated immediately above the root of the nose, between the tables of the frontal bone. They are separated by a septum and vary greatly in size, to which the prominence of the superciliary ridge is no guide. Sometimes one or both are absent. One sinus is often much larger than the other; the cavities are frequently subdivided by incomplete septa, and, while the main septum is generally mesial, it is sometimes deflected. If a sinus be present it can generally be reached by making a horizontal skin incision at the level of the eyebrow, and going down immediately above the root of the nose in the angle between the middle line and

the inner third of the supra-orbital margin. Care should be taken to clear out all the subdivisions of the sinus. The posterior wall of the sinus is in relation to the frontal lobe of the brain, and the floor forms part of the roof of the orbit.

Inflammatory conditions of the sinuses may involve the brain, and, where the bone is affected, perforation often takes place at the inner angle, the eyeball being pushed down and outwards, and diplopia resulting. Not infrequently the orbital cavity is involved in disease, tubercular or otherwise, originating in the sinus, the pus generally pointing at the inner side of the upper eyelid. The sinuses may be *fractured* without the cranial cavity being involved, and emphysema of the surrounding tissues may arise therefrom when the mucous membrane is torn.

The *fronto-nasal duct*, which varies much in size, begins at the lowest part, close to the septum, thus favouring drainage. It may open into the infundibulum or into the middle meatus direct, the ostium varying from a slit to an aperture $\frac{1}{4}$ inch in diameter. The introduction of a probe is not always an easy matter, it being frequently necessary to remove the middle turbinate, while the probe is also liable to enter the ostia of the anterior ethmoidal cells.

The ANTRUM OF HIGHMORE presents three walls, a roof, and a floor. The *anterior*, or facial wall, is limited externally by the malar ridge, and below by the alveolar border. It is thin, and presents a prominence for the canine tooth, which is separated from the molar ridge by the canine fossa, and the infra-orbital canal, which transmits the infra-orbital vessels and nerves. The position of the latter may be defined by taking a point on Holden's line (drawn from the supra-orbital notch to the internal between the bicuspid teeth of both jaws), $\frac{1}{4}$ inch below the lower orbital margin. The *nasal wall* forms the outer boundary of the inferior and middle meati. The portion bounding the inferior meatus is osseous, and is thinnest immediately beneath the attachment of the inferior turbinate, where, at a point $\frac{1}{2}$ inch behind its anterior extremity, the antrum is best tapped from the nose. Above the inferior turbinate the wall is partly osseous and partly membranous, and presents the ostium, which opens into the antrum close to its roof, and into the nose at the most dependent portion of the infundibulum. It therefore follows that suppurative

processes in the frontal sinus or anterior ethmoidal cells are very apt to secondarily infect the antrum of Highmore, the pus travelling down the naso-frontal duct to the infundibulum, and thence through the maxillary ostium. Once the pus enters here, it does not readily escape, owing to the position of the ostium, save when the head is laid on the opposite side, the pus then frequently coming away in a gush. The ostium varies in size, but averages $\frac{1}{8}$ inch vertically and $\frac{1}{4}$ inch antero-posteriorly. Not infrequently an accessory ostium is present, and is sometimes the larger of the two. When present it is situated below the other, and facilitates the escape of pus into the throat. Neither ostium is easily reached from the nares by catheter.

The *roof* forms the floor of the orbit, is thin, and presents the canal from the superior maxillary nerve and vessels. This canal is sometimes invaded or crushed in antral disease, giving rise to severe neuralgia, while later the tumour or pus may invade the orbital cavity or ethmoidal cells. The *floor* is the alveolar border of the superior maxilla, and is on the same level as the nasal floor. The bone is generally thinnest over the fangs of the first and second molars, while the fang of the canine generally lies in front of the antrum. Probably the second molar bears the most constant close relation to the antrum, a point to bear in mind in entering the antrum from the mouth. Disease of the fangs of the molar teeth sometimes gives rise to antral suppuration. The antrum varies much in size, and, where small, the walls, particularly the alveolar, are thicker, and *vice versa*. When large the cavity may extend mesially into the palatal plate of the maxilla. The walls are supplied by blood from the periosteum, which lines both the inner and outer surfaces, and from the walls numerous septa pass into the cavity, thus partially subdividing it. This subdivision, combined with the position of the ostium, renders *antral suppuration*, as a rule, intractable. It has already been stated that the antrum may be reached through the nose or through the socket of one of the molars. Probably the most efficient mode of dealing with antral suppuration, however, is to evert the upper lip, cut through the junction of gum and lip, and shell all the tissues upwards with a periosteal elevator until close to the infra-orbital foramen, when an opening can be made by trephine or simply

crushing in the canine fossa. This opening may be sufficiently large to permit of thorough exploration and removal of disease, but if a permanent-opening be required, it is best made through the nose.

THE FACE.

The SKIN of the face varies in character at different parts. In the orbital region it is very thin, and possesses but little subcutaneous tissue ; in the cheeks it is thicker, and possesses a single thick layer of subcutaneous tissue, which extends down to the periosteum of the bone, and contains much fatty tissue. A special pad of fat which lies between the anterior border of the masseter and outer aspect of the buccinator, and which is separated from the rest of the fatty tissue of the cheek by a layer of fascia from the parotid capsule, is known as the *sucking or buccal pad of Bichat*. It is not much affected in general emaciation, and accordingly becomes very prominent, especially in emaciated children. In the lips and chin the skin is thick, and the subcutaneous tissue is largely occupied by muscular tissue. The skin of the face is richly supplied with fat and sweat glands, and is a common seat of *acne*.

Superficial abscesses are generally small, while subcutaneous effusions can spread readily in the lax tissues of the eyelids and cheeks, but meet with resistance in the chin. The swelling of the lower eyelid, which occurs in some renal conditions, is well known. *Cancrum oris*, a rapidly progressing gangrene seen occasionally in neglected children, begins on the inside of the cheek, and rapidly spreads to the outside and peripherally, causing complete destruction of the parts. *Malignant pustule*, caused by anthrax, frequently affects the face. *Rodent ulcer* frequently attacks the parts above a line drawn from the nostril to the lobe of the ear, while *lupus* affects the parts below this line. The face is richly supplied with blood by the *facial artery*, which, arising from the external carotid, crosses the lower jaw along the anterior border of the masseter, the vein lying some distance posterior. It runs up toward the angle of the mouth, and then to the inner canthus of the eye, its course being very tortuous, and many branches being given off, which anastomose with (a) those of the opposite side, (b) branches from the temporal

and internal maxillary, and (c) ophthalmic of the internal carotid. *Bleeding* from wounds of the face is accordingly free, it being frequently necessary to secure both ends of a divided vessel. *Nævi*, both capillary and cavernous, not infrequently affect the face, especially the lips. The *facial vein* is of importance, as it has no valves, tends to remain patent on section, and because it communicates with the internal jugular in the neck, and with the cavernous sinus, both (a) through the *angular vein*, which communicates with the superior ophthalmic vein, which opens into the sinus, and (b) through the *deep facial vein*, which runs to the pterygoid plexus, which is connected with the cavernous sinus by little veins traversing the foramen ovale. Thus, septic affections of the face may readily give rise to great septic absorption and *sinus thrombosis*. The *lymphatics* of the inner portions of the face drain chiefly to the submaxillary and superficial cervical glands, while the outer portions drain to the parotid region.

Congenital *cavernous lymphangiomata* are occasionally met with in the face.

Nerve-Supply.—The *facial* is the motor nerve of the face. Having traversed the temporal bone, it emerges at the stylo-mastoid foramen, runs forwards, and forms the pes anserinus in the parotid gland, from which radiating branches are given off. A unilateral FACIAL PARALYSIS may result from an affection of (a) centre in the brain, when the side of the face affected is opposite to that of the lesion and the paralysis is incomplete, the mimetic play of the features being retained; (b) the nerve in the temporal bone, where the paralysis is on the same side and is complete once the nerve is destroyed; (c) an affection of the peripheral portion of the nerve from exposure to cold: here the paralysis comes on suddenly, and is generally complete, and often very intractable. In a complete paralysis of one side the eyelid cannot be closed; the eyeball appears prominent; tears may overflow on to the cheek (epiphora) from drooping of the lower eyelid and corneal irritation, and the brow droops; the natural furrows of the face disappear; the nostril does not expand on inspiration, and hence sense of smell is impaired; the patient cannot whistle; he frequently complains that when taking fluid the material runs out of the corner of his mouth; and when he smiles, the

muscles of the unaffected side draw the affected portions toward them, and thus cause distortion. Speech, also, is generally thick. In incomplete facial paralysis, on the other hand, while the patient may be unable to close the eye voluntarily, he generally does so bilaterally, as in blinking, and when he smiles, the affected side of the face responds slightly and is not mask-like. The sensory nerve-supply is from the *trigeminal*, of which the ophthalmic division supplies the brow, nose, canthi, and upper eyelid; the superior maxillary division supplies the lower eyelid, cheek, side of nose, and upper lip; the inferior maxillary division supplies the skin of the temporal region, that covering the masseter muscle, lower lip, and chin, and the mucous membrane of the cheek and lower lip.

The *supra-orbital nerve* comes out through the supra-orbital foramen, at the junction of the middle and inner thirds of the upper orbital margin. A line drawn from this to the interval between the bicusps of both jaws (Holden's line) passes through the *infra-orbital* foramen, which lies about $\frac{1}{4}$ inch below the lower orbital margin, and through the *mental foramen*, which transmits the terminal branches of the third division, and which lies midway between the alveolus and lower border of the jaw.

Facial neuralgia may be caused by affections of the Gasserian ganglion, which give rise to a severe trigeminal type; by tumours, such as sarcomas, springing from the base of the skull, or osteomas projecting into one of the nerve canals; or by peripheral irritation, such as caries of the teeth or inflammatory conditions surrounding the exit of one of the foramina.

Sometimes the neuralgia gives rise to spasms (*tic douloureux*), and is frequently associated, when severe, with flushing and swelling of the affected parts and watering of the eye and nose, and, as these parts are then extremely sensitive, the patient's condition is very miserable. In severe *trigeminal* cases it is generally necessary to excise the *Gasserian ganglion*, and this operation, if successful, is followed by complete relief. Sometimes, also, *Meckel's ganglion* is removed, or peripheral portions of the nerves excised, as a rule with only temporary success, unless the cause be peripheral. Meckel's ganglion lies in the sphenomaxillary fossa, and is generally

reached by following up the infra-orbital nerve and artery (Carnochan's operation). The ganglion, a small reddish body about $\frac{1}{5}$ inch in diameter, lies in front of the foramen rotundum, and the Vidian canal of the sphenoid (which transmits the Vidian nerve to the ganglion) below the second division of the fifth nerve. To its outer side lie the terminations of the internal maxillary artery, the external pterygoid muscle, and the pterygo-maxillary fissure (which communicates with the fossa of that name), and to its inner side the vertical plate of the palate and the sphenopalatine foramen (which communicates with the nasal fossa and transmits the artery of that name) and the nasal branches of the ganglion. In addition to orbital and nasal branches, it gives off three palatine nerves—anterior, posterior, and external—which supply the palate, posterior arch of the fauces, and tonsil. As the branches of the fifth overlap one another in distribution, excision of a division is followed by very limited anæsthesia.

The face is developed from five processes : an upper central, or fronto-nasal ; two upper lateral, or maxillary ; and two lower lateral, or mandibular. The fronto-nasal process grows down and forms the nose, central portion of the upper lip, and pre-maxilla, which carries the upper central incisor teeth. The maxillary processes grow inwards and join the fronto-nasal process, forming the upper jaw, cheek, and palate, while the mandibular processes grow inwards, fuse centrally, and form the lower jaw. A *hare-lip* is produced when the fronto-nasal and maxillary processes do not fuse properly at their lower extremities. A *coloboma facialis* is produced by a want of union between the fronto-nasal process and the superior maxillary process throughout their length. It presents below as an ordinary hare-lip, then passes up around the ala of the nose to the orbital cavity, forming a coloboma of the lower eyelid. *Macrostoma*, or transverse facial cleft, is a partial persistence of the cleft between the maxillary and mandibular processes, and extends upwards and outwards from the angle of the mouth. *Microstoma* is produced by excessive union of the processes.

THE UPPER JAW.—While composed largely of thin bone, and containing the antrum of Highmore, the upper jaw, owing to the arrangement of buttresses by which the force of blows is distributed, is not frequently *fractured*. In severe blows

on the malar bone the zygoma may give way and the malar be driven into the antrum, and in fractures of the superior maxilla the infra-orbital nerve may be caught, or involved subsequently in callus, or the lachrymal sac may be torn. The maxilla tends to heal readily, with minimal callus formation. The upper jaw may be involved primarily or secondarily by *tumours*, particularly sarcomata. These frequently invade the antrum, which is distended, giving rise to neuralgia, and later, when the orbital cavity is involved, to exophthalmos and diplopia, owing to the displacement of the affected eyeball.

Frequently, also, the palate becomes involved, the teeth may come out, and the fungating mass project into the mouth, while it may also project backwards and inwards to the naso-pharynx. Where the disease is not very extensive, it may be treated by *excision of the upper jaw*, in which the greater portion of the jaw, together with portions of the malar, lachrymal, ethmoid, and palate, is removed. It is desirable, wherever possible, to save the floor of the orbit, in order to preserve the eyeball in its proper position, and, where this can be done, the operation is generally followed by but little deformity. The MALAR BONE is rarely fractured alone; generally it is driven into the upper jaw.

THE PAROTID REGION.—The main part of the PAROTID GLAND lies in a *recess* bounded in front by the ramus of the jaw, with the masseter externally and the internal pterygoid internally; the mastoid process and the sterno-mastoid muscle behind; the temporo-maxillary joint and external auditory meatus above; and a horizontal line from the angle of the jaw to the sterno-mastoid below. By extending the head and pushing forward the lower jaw the space is increased in size, while by opening the mouth widely the upper portion of the space is increased by gliding forward of the condyle, and the lower portion is diminished. The gland is enclosed in a process of the *cervical fascia*, which splits to enclose it, and which sends in numerous septa, subdividing the gland. The superficial layer is very dense, and is continuous in front with the sheath of the masseter and behind with that of the sterno-mastoid, while above it is attached to the zygoma. The deep layer is thin, and is attached above to the periosteum of the auditory meatus and glenoid fossa,

and forms the *stylo-maxillary ligament*, which extends from the tip of the styloid process to the posterior surface of the angle of the jaw, between the insertions of the masseter and pterygoid muscles. The deep surface of the gland sheath is related to the posterior belly of the digastric muscle, the styloid process and muscles rising from it, the external and internal carotid arteries and internal jugular vein, and the ninth, tenth, eleventh, and twelfth nerves. The gland generally sends several *processes* in different directions. Thus a facial process frequently projects forwards toward the *socia parotidis*, which latter lies on the masseter above Stenson's duct; cervical and glenoid processes project in the directions indicated by their names; while a pharyngeal process is of importance, as it passes deeply inwards in front of the styloid process and above the stylo-maxillary ligament toward the pharynx and tonsil. *Within the gland* are numerous structures, of which the most important are: (a) The external carotid artery, which enters the deep surface of the gland at the junction of the middle and lower third of the posterior border of the ascending ramus of the jaw, passes outwards and backwards from under cover of the ramus, until, on reaching the neck of the condyle, it divides into the internal maxillary and superficial temporal arteries. (b) The facial nerve, which, after leaving the stylo-mastoid foramen, immediately enters the gland and breaks into its branches, crossing superficial to the external carotid artery. The temporo-maxillary vein, the occipital and posterior auricular branches of the external carotid artery, and small branches of the superficial temporal and internal maxillary, a few nerve branches, and lymphatic glands (draining the temporal, scalp region, outer portion of the eyelids, posterior part of the cheek, and ear), are also present in the gland.

Owing to the projecting process of the parotid toward the pharynx, *post-pharyngeal abscesses* sometimes find their way into the parotid gland; while, on the other hand, owing to its dense anterior capsule, suppurative processes in the parotid not infrequently extend toward the pharynx. In other cases *parotid abscesses* point in the temporal or zygomatic fossæ or in the neck, while sometimes they burst into the meatus, or even find their way along the divisions of the fifth nerve to the Gasserian ganglion. Parotid abscesses generally arise

from septic infection conveyed along the duct from the mouth. *Inflammatory conditions* of the parotid occasionally supervene on disease or injury to the pelvic viscera, and on some fevers, especially typhoid, while the affection of the gland called 'mumps' is well known. Owing to the tense capsule, all of these affections are very painful, the auriculo-temporal and great auricular nerves being pressed on, while, where the condition is not relieved by operation, sloughing of the gland may occur, or even ulceration of one of the large vessels, with consequent severe hæmorrhage. Movement of the jaw aggravates the pain, altering, as it does, the size and shape of the space. In *opening a parotid abscess* care is necessary, owing to the important structures contained. A horizontal incision, as low as possible, so as to avoid Stenson's duct and the facial nerve, is generally best, and then, when the capsule is reached, it is penetrated with sinus forceps (Hilton). *Penetrating wounds* in the parotid region should generally be treated as serious, owing to the various important structures which may be injured. Bleeding in such cases is frequently very severe, and the vessel difficult to get at. *Parotid fistula* is apt to result from injury to the gland or duct. The most common form of TUMOUR occurring in the parotid is one of a mixed type, and is peculiar in that it generally contains cartilage in addition to fibrous, adenomatous, and myxomatous tissue. Sometimes these tumours are sarcomatous, and rapidly infiltrate the various structures, causing limitation of movement of the jaw, neuralgia, and later anæsthesia and paralysis. They are generally fixed, so that they cannot be moved about in the gland substance, and they sometimes perforate the external auditory meatus. Removal is difficult or impossible. STENSON'S DUCT begins at the anterior margin of the gland by the junction of two main branches proceeding respectively from the upper and lower segments, and runs forwards and slightly downwards to the anterior margin of the masseter, where it bends nearly at right angles, pierces the fatty tissue, buccinator muscle, and mucous membrane of the cheek, and ends by an elliptical orifice on the level of the second upper molar tooth. It is about $2\frac{1}{2}$ inches long and $\frac{1}{8}$ inch thick, has a firm feel, by which it may sometimes be detected through the skin, lying about $\frac{1}{2}$ inch below the zygoma, and its course may be represented by a line drawn from the lower border

of the tragus to a point midway between the nostril and the red margin of the lip. In its course it is accompanied by the transverse facial artery, which lies above it, and infra-orbital branches of the facial nerve, which lie above or below it. *Wounds* of the duct are very apt to lead to *salivary fistulae*, which are treated, where practicable, by establishing an opening between duct and mucous membrane on the proximal side of the fistula. Subcutaneous rupture of the duct leads to extravasation of saliva. Where the duct becomes blocked by calculus a painful *retention cyst* is apt to develop. In passing a probe it is best to evert the cheek so as to straighten the duct.

THE LOWER JAW.—Congenital complete absence of the lower jaw has occurred; also partial defects and incomplete development, the jaw remaining of small size. *Fracture* occurs most commonly at or near the mental foramen, the bone being weakened by the foramen and the fossa for the canine tooth. It is practically always compound, owing to the close adherence of the mucous membrane to the bone, but the displacement is generally slight, the mylo-hyoid, which is attached to both fragments, modifying the displacement. As a rule, therefore, the inferior dental nerve, running in the interior of the bone through the *inferior dental canal*, escapes severe injury at the time of the accident, though it may become involved in callus later. The tendency toward displacement, however, is for the anterior fragment to be drawn downwards and backwards by the digastric, mylo- and genio-hyoid, and genio-hyo-glossus, while the posterior fragment is raised by the masseter, internal pterygoid, and temporal. *Fracture* of the *neck* of the *condyle* occurs occasionally from blows on the chin. The *glenoid fossa*, situated in front of the osseous meatus and behind the eminentia articularis of the zygoma, which separates it from the zygomatic fossa, is divided into an anterior articular and posterior non-articular portion by the Glaserian fissure. The articular portion is separated from the middle fossa of the skull by a very thin plate of bone, and cases have occurred in which the condyle of the jaw has been driven up through this plate into the cranial cavity. The *condyle of the jaw*, whose long axis is directed inwards and backwards, is separated from the glenoid by an interarticular fibro-cartilage, on either surface of which is a synovial cavity.

The cartilage is attached to the capsule and to the condyle, with which it moves forwards and backwards on opening and shutting the mouth. It sometimes becomes displaced forwards, especially in delicate women, causing a *subluxation of the jaw*. The *capsule* is thin, especially in front, but is strengthened externally by the external lateral ligament, which is directed downwards and backwards from the zygoma to the condyle. The accessory ligaments consist of: (a) The spheno-maxillary (internal lateral), from the spine of the sphenoid to the ligula and ascending ramus of the jaw. Between it and the neck of the jaw the internal maxillary artery and vein, the inferior dental vessels and nerve, the auriculo-temporal nerve, and external pterygoid muscle, are situated. (b) The stylo-maxillary (deep parotid fascia), from styloid process to angle of the jaw. (c) The pterygo-maxillary, from hamular process of sphenoid to base of ligula. *Dislocation of the jaw* is nearly always forwards through the weak anterior portion of the capsule, and is said to be more frequently bilateral. Dislocation in other directions is generally associated with fracture. The forward variety occurs when the mouth is widely open, and is said to be largely due to the action of the external pterygoid muscle, which draws the condyle forward beyond the articular eminence into the zygomatic fossa (the articular cartilage remaining behind), where it is pulled up by the internal pterygoid, temporal, and masseter muscles. In reduction, therefore, it is first necessary to depress the condyle before pushing it backwards. *Suppurative conditions* may extend from the ear or parotid gland and involve the joint. Abscesses usually point at the front of the joint, and suppurative processes not infrequently lead to ankylosis. The joint is frequently affected in *rheumatoid arthritis*, giving rise to 'creaking' during mastication in slight cases and excessive movement or complete ankylosis in severe ones. In such cases an *excision of the condyle* through a curved incision along the posterior portion of the upper border of the zygoma may be necessary. Fixation of the jaw may also arise from spasms of the muscles (*trismus*), as in tetanus (*risus sardonicus*), and sometimes from reflex irritation from the lower teeth (caries or cutting a wisdom tooth), as the third division of the fifth nerve, by its motor root, supplies the muscles of mastication. *Dental caries* has also been known

to cause torticollis, strabismus, areas of hyperæsthesia, patches of grey hair, etc., through reflex action. *Tumours* of the lower jaw frequently arise in connection with the teeth (dentigerous cysts, etc.) Of the tumours involving the jaw itself, fibroma, osteoma, and enchondroma are met with, and also sarcoma. The latter may spring from the periosteum, often about the dental margin (*malignant epulis*), when it is generally of round or spindle-cell type; or it may be of the myeloid type and originate in the medulla of the bone, the bone becoming gradually expanded, while the patient experiences progressive toothache as the various dental nerves become involved. In such cases *excision of half of the lower jaw* may be necessary. This is generally performed through an incision extending through the lip to the chin, and then carried along the lower border of the jaw and superficially up along the posterior margin of the ascending ramus to the lobule of the ear. Unless the sarcoma be periosteal, a subperiosteal excision of the half jaw is next performed, the jaw being cut through near the symphysis and then forcibly depressed, when the insertion of the temporal muscle into the coronoid process is cut and the condyle is disarticulated by a twisting movement, the capsule and external pterygoid muscles being cut. Reformation of the bone may follow such an operation.

The *blood-supply* of the lower jaw is derived from the facial (which sends a submental branch along the inferior border of the jaw to anastomose with the mental artery) and one of the terminal branches of the external carotid, the internal maxillary, which sends the inferior dental artery to accompany the nerve of that name, and the masseteric to the masseter muscle. The nerve-supply is through the inferior maxillary.

TEETH.—The time of eruption of the MILK TEETH is variable. The lower central incisors appear about the sixth to ninth month, upper incisors tenth month, lower lateral incisors and first four molars about twelfth to fourteenth month. Then come the canines and four second molars, the set being completed by the end of the second year. Of the PERMANENT TEETH of the lower jaw, the first molars appear about the sixth year, and central incisors about the seventh, lateral eighth, first premolars ninth, second premolars tenth, canines eleventh, second molars twelfth, third molars about

seventeenth year, but may be much later or may not erupt. Those of the upper jaw appear a little later than those of the lower. The first milk tooth is cut about the seventh month, and the first permanent tooth at the seventh year. The milk teeth are twenty in number, while the permanent teeth number thirty-two.

A *tooth is formed* by a dipping in of epithelium, which becomes cupped at its extremity, forming the enamel organ, a process of the underlying connective tissue growing up into it and forming the dentine papilla. The tooth, composed of enamel produced by the enamel organ, and of dentine by the papilla and its contained cells (odontoblasts), is contained in a tooth sac or follicle supplied by the jaw itself, which forms an alveolar periosteum for the root, which is partly formed by the papilla and partly by the deposit of cement upon it by the alveolar periosteum. The remains of the papilla form the pulp, which occupies the pulp cavity.

As the permanent teeth approach the surface, the milk teeth generally fall out, owing to absorption of their roots.

The upper incisors and canines and the lower bicusps have cylindrical roots, and hence in extracting are first loosened by a rotatory movement. The roots of the lower incisors and canines and the upper bicusps are flattened, necessitating a lateral movement to loosen them. The roots of the upper molars are three in number, whereas those of the lower molars are two, and the roots of the two first upper molars are frequently divergent, while those of the wisdom teeth of both jaws, but particularly the lower, are convergent and curved backwards. After extraction of a permanent tooth, absorption of the alveolar margin of the jaw generally occurs.

Alveolar abscess frequently occurs in connection with the fangs of the teeth. Where the tooth has a single fang the pus may travel along the fang to the surface, but in other teeth it tends rather to burrow through the alveolus, pointing in some cases through the gum, but more generally through the cheek.

The chief forms of *tooth tumours* are *odontomes*, which occur during the developmental period, and consist of dental tissue, and *dentigerous cysts*, which consist of an expansion of the follicle of an unerupted tooth, which is found generally within the cyst.

Hereditary syphilis affects chiefly the permanent upper

central incisors, which, instead of presenting a narrow neck and broad crown, have a broad base and taper toward the crown (peg-shaped), which is frequently notched ('Hutchinson teeth').

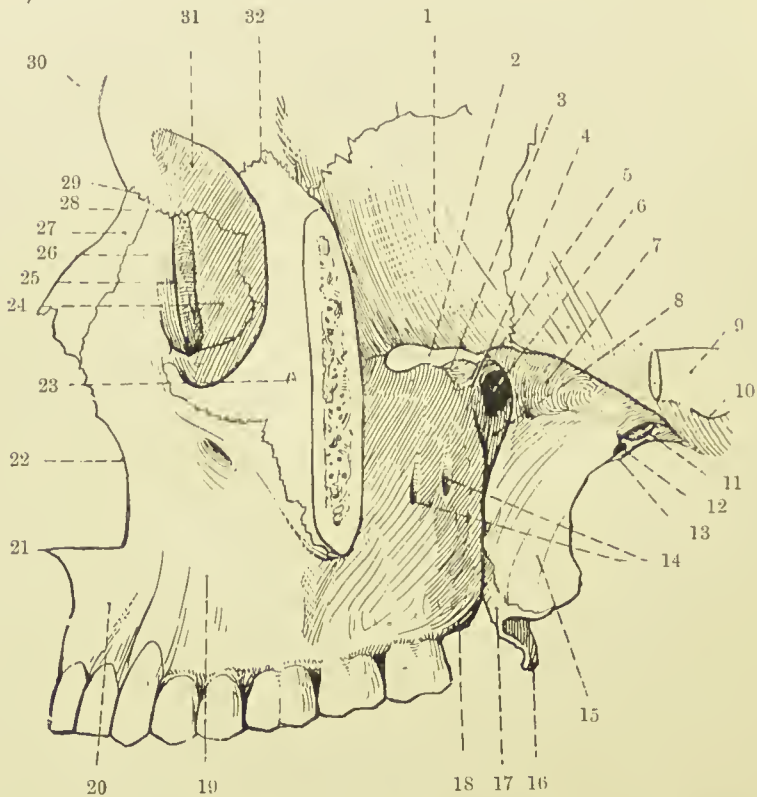


FIG. 10.—THE ZYGOMATIC AND SPHENO-MAXILLARY FOSSÆ.
(From Buchanan's "Anatomy.")

- | | |
|--|--|
| 1. Great wing of sphenoid. | 17. Tuberosity of palate bone. |
| 2. Spheno-maxillary fissure. | 18. Tuberosity of superior maxilla. |
| 3. Back part of infra-orb. groove. | 19. Canine fossa. |
| 4. Spheno-maxillary fossa. | 20. Incisor fossa. |
| 5. Infratemporal crest. | 21. Anterior nasal spine. |
| 6. Spheno-palat. foramen. | 22. Nasal notch. |
| 7. Zygom. surf. of great wing of sphenoid. | 23. Malar foramen. |
| 8. Pterygo-maxillary fissure. | 24. Orbital surface of lachrymal bone. |
| 9. Zygoma. | 25. Lachrymal groove. |
| 10. Preglenoid tubercle. | 26. Nasal plate of superior maxilla. |
| 11. Foramen ovale. | 27. Nasal bone. |
| 12. Foramen spinosum. | 28. Fronto-maxillary suture. |
| 13. Spine of sphenoid. | 29. Fronto-nasal suture. |
| 14. Openings of posterior dental canals. | 30. Glabella. |
| 15. External pterygoid plate of sphenoid. | 31. Orbital plate of frontal. |
| 16. Hamular process. | 32. Fronto-malar suture. |

The **PTERYGO-MAXILLARY OR ZYGOMATIC FOSSA** is a comparatively small space, bounded anteriorly by the zygomatic surface of the superior maxilla; internally by the external pterygoid plate and pterygo-spinous ligament, which

frequently ossifies; posteriorly by a line from the foramen spinosum to the tubercle of the zygoma; and externally by the zygomatic arch and ramus of the inferior maxilla. Above it is partially bounded by the great wing of the sphenoid and a small portion of the squamous of the temporal, and it is quite open below. *It communicates* anteriorly with the sphenomaxillary fossa by the *pterygo-maxillary fissure* (which is a vertical fissure between the superior maxilla and the external pterygoid plate), and with the orbit by the *spheno-maxillary fissure* (which is a horizontal fissure running at right angles to the pterygo-maxillary, separating the great wing of the sphenoid from the orbital margin of the maxilla). Above it is continuous with the temporal fossa beneath the zygoma, and below with the parotid region. *Indirectly* the space is continuous with the nasal fossa through the *spheno-palatine foramen* (from sphenomaxillary to nasal fossa), and with the cranial cavity through the *sphenoidal fissure* (from cranial cavity to orbit), and thus *suppurative processes* may find their way through it to or from the nasal, orbital, temporal, parotid, or cranial regions. *Zygomatic abscess* may point on the face, neck, or in the pharynx. The pterygo-maxillary fossa is occupied by the two pterygoid muscles and a small portion of the temporal, the internal maxillary artery and branches, the pterygoid venous plexus, and the third division of the fifth nerve.

The *temporal muscle*, which is inserted into the coronoid process of the lower jaw, is situated chiefly in the temporal fossa, and is covered externally by a dense fascia, the temporal fascia. This fascia is continuous above with the occipitofrontalis aponeurosis, which is attached along the temporal crest and covers the muscle as far as the zygoma, to which it is attached in two layers, a quantity of fat intervening between them. This fascia is very dense, and, like the occipitofrontalis aponeurosis, may, when cut through, give the sensation of broken bone to the examining finger. Anteriorly the deep fascia loses itself on the face, and posteriorly it forms the thin masseteric fascia and the thicker parotid capsule. Lying behind the temporal fascia and muscle is a quantity of fat, continuous with that in the pterygo-maxillary fossa, the absorption of which produces the prominent malar bone and zygoma seen in extreme emaciation. *Fracture* of the

zygoma may be due to direct or indirect violence. There is generally little displacement, owing to the attachment of the temporal fascia above and masseter muscle below, but a fragment may be detached and driven into the temporal muscle, and cause pain on mastication. *Abscesses* in the temporal fossa tend to point in the pterygo-maxillary region or in the neck. The *external pterygoid muscle* runs backwards from its origins from the great wing of the sphenoid and external pterygoid plate, to be inserted into the neck of the lower jaw and the interarticular fibro-cartilage, and has the internal maxillary artery on its outer side, as a rule, while the branches of the third division of the fifth nerve surround it. The internal maxillary artery gives off the *middle meningeal artery*, which ascends through the foramen spinosum, at which point it is sometimes caught in fracture of the skull, and the *inferior dental*, which enters the inferior dental canal, and numerous muscular and other branches.

The *pterygoid venous plexus* is situated chiefly beneath the upper origin of the external pterygoid, its blood being removed by the internal maxillary vein. It forms a venous communication between nose, orbit, and cranium, including the cavernous sinus. The *internal pterygoid muscle*, arising from the deep surface of the external pterygoid plate and from the tuberosity of the upper jaw, is quadrilateral in form, and is directed downwards and backwards on the deep surface of the external pterygoid to the inner surface of the lower jaw near the angle.

The *third division of the fifth nerve* is joined by the motor root immediately after its exit from the foramen ovale. At this point it lies on the deep surface of the external pterygoid, and then breaks into two divisions, an *anterior*, which is almost entirely motor, and supplies the muscles of mastication, excepting the buccinator (which is supplied by the facial), and a *posterior sensory*, which gives off the auriculo-temporal nerve to the parotid gland, ear, etc.; the inferior dental, which supplies the teeth, and gives off a mental branch; and the lingual, which crosses between the ramus of the jaw and external pterygoid to the tongue, sublingual and submaxillary glands. While it supplies the tongue with sensation, it also has some taste fibres derived from the chorda tympani. The *inferior dental nerve* is sometimes *divided for neuralgia*, being

reached either through the mouth by a vertical incision along the inner side of the ascending ramus of the jaw or by trephining through the central point of the ascending ramus, and so reaching the nerve as it enters the canal. The *lingual nerve* is sometimes sectioned for the relief of pain and salivation in carcinoma linguæ. It may be reached through the mouth by an incision $\frac{1}{2}$ inch below and behind the last molar tooth, or through the neck by an incision similar to that for ligature of the lingual artery, after which the capsule of the sub-maxillary gland is divided, the gland turned up, and the nerve found at the point at which it is connected with the sub-maxillary ganglion. The *inferior maxillary trunk*, and also the *Gasserian ganglion*, have been attacked through the pterygo-maxillary space. The zygoma is cut and turned down with the masseter, the coronoid process is cut and turned up with the temporal, and the external pterygoid is shelled from its attachments. If the Gasserian ganglion is to be attacked (Rose's operation), it is further necessary to trephine the skull close to the foramen ovale. In these operations hæmorrhage from the internal maxillary artery and pterygoid venous plexus is generally very great, frequently necessitating postponement of the complete operation, and even ligature of the common carotid. The Gasserian ganglion has also been attacked by turning down a large flap of bone from the temporal region (Hartley-Krause method), but here also the hæmorrhage is generally very great. Attention has already been drawn to the method of attacking the ganglion through an incision in the face (p. 13).

The **SPHENO-MAXILLARY FOSSA** is a small triangular space situated beneath the apex of the orbital cavity at the angle of junction of the speno-maxillary and pterygo-maxillary fissures, which communicates with the orbit by the former, with the zygomatic fossa by the latter, and with the nasal fossæ by the *spheno-palatine foramen*.

It is bounded above by the body of the sphenoid and orbital process of the palate bone ; in front by the superior maxilla ; behind by the base of the pterygoid process and great wing of the sphenoid ; and internally by the vertical plate of the palate. Three foramina open on its posterior wall—*foramen rotundum* above, *Vidian canal* below, and *pterygo-palatine canal* below and internal. Two foramina open on the inner

wall—spheno-palatine above and posterior palatine canal below.

The **CAVITY OF THE MOUTH** is described as consisting of two parts, an anterior, or *vestibule*, and a posterior, the mouth proper, or *buccal cavity*, which are separated from one another by the gums and teeth. When the mouth is tightly shut, the only available opening between the two, if the teeth be intact, is behind the last molar tooth. Through this interval between the last molar and the ascending ramus of the jaw patients affected with tetanus are frequently *fed by a tube*, and a similar mode is frequently adopted in cases of fracture of the lower jaw. The **lips** are very mobile, the mobility rendering them liable to contraction deformity, and they are composed from without inwards of skin, superficial fascia, orbicularis oris, submucous tissue containing many mucous glands, and the coronary branches from the facial artery and mucous membrane. Thus the *vessels* are close to the inside of the lip, and may be wounded against the teeth, and, as they possess a free anastomosis, considerable bleeding may result, the blood frequently being swallowed and subsequently vomited, causing internal injuries to be suspected. The *mucous membrane* of the lips rests on a loose subcutaneous tissue, which readily becomes infiltrated in inflammatory affections, causing considerable swelling. The glands in the submucous tissue are numerous, and their ducts, when blocked, may give rise to mucous cysts, which occasionally attain a large size, while a general hypertrophy of the glands may cause a uniform enlargement of the lip. *Nævi* frequently occur on the lips, and the lower lip is the most frequent seat of *epithelioma*. As the *lymphatics* of both lips drain to the *submaxillary glands*, it is there that evidence of secondary extension should first be sought. A congenital enlargement of the lip due to lymphatic hypertrophy is rarely met with, and is called *macrocheilia*. The upper lip derives its sensation from the second and the lower from the third division of the *fifth nerve*, labial *herpes* frequently occurring over the distribution of these nerves in cases of fever, gastric disturbance, etc. *Stenson's duct* opens on the mucous membrane of the cheek opposite the second upper molar tooth, and as it bends almost at a right angle just prior to opening, it is necessary, when passing a probe along it, to evert the cheek in order to remove

the bend. The *pterygo-maxillary* ligament can be seen running from above downwards toward the last molar tooth, when the mouth is widely open. The *lingual or gustatory nerve* lies just in front of this, below the last molar tooth and close to the bone, where it has been injured by slipping of the forceps in extraction of the last molar.

Normally the lips and cheeks press against the teeth and gums, thus rendering the cavity of the vestibule only potential. In *facial paralysis*, on the other hand, the lips and cheeks fall away from the teeth, permitting the accumulation of food in the vestibule, while, owing to the inability to close the lips firmly, fluid is generally permitted to run out at the side of the mouth.

Hare-lip is a uni- or bi-lateral defect in the upper lip, varying from a slight notch in the margin of the lip to a gap extending into the nostril, due to imperfect fusion between the fronto-nasal and superior maxillary processes. A continuation of the defect by the side of the nose upwards to the lower eyelid, which may be involved, is called a *coloboma facialis*.

A *median hare-lip* is rare. In the upper lip it is due to persistence of a little cleft at the extremity of the fronto-nasal process (globular process), and in the lower lip to failure of fusion of the two mandibular processes.

Macrostoma, a lateral continuation of the aperture of the mouth, is due to imperfect fusion between the maxillary and mandibular processes, while *microstoma* is due to excessive fusion.

The **gums** are normally firm and vascular. They are frequently affected in scurvy and in mercurial and chronic lead-poisoning, a blue line forming at the junction of teeth and gum in the latter affection, especially if the mouth be not kept clean. The *mucous membrane* covering the gums is thin and adherent, save at the reflections, and is generally torn through in fracture of the lower jaw.

The **buccal cavity** communicates anteriorly with the vestibule, as already described, and posteriorly, through the isthmus of the fauces, with the pharynx. It contains the tongue, and presents the openings of several salivary ducts. When the mouth is shut, and breathing is conducted through the nose, the tongue practically fills the whole cavity, render-

ing it, like the vestibule, potential. *Wharton's duct* from the submaxillary gland opens on a soft papilla on the under surface of the tongue, at its base and close to the middle line. A ridge, the *plica sublingualis*, runs outwards and backwards from this point on either side. It is caused by the underlying sublingual gland, the numerous ducts from which (*ducts of Rivini*) open near the crest of the ridge. Rarely a large duct (*Bartholin's*) comes from the sublingual gland and opens close to or along with Wharton's duct. Wharton's duct is indistensible, and, when blocked by a *calculus*, causes considerable pain. *Ranula*, a mucous cyst found on the floor of the mouth, may be due to dilatation of Wharton's duct or of one of the sublingual ducts, or to occlusion of one of the mucous follicles which are numerous under the tongue

Dermoids, due to persistence of the upper end of the *thyroglossal duct*, sometimes occur on the floor of the mouth. An acute form of submaxillary cellulitis, called *Ludwig's angina*, sometimes occurs, involving both sides of the floor of the mouth, causing great swelling, which pushes the tongue upwards and backwards, and giving rise to danger from sloughing, hæmorrhage, pyæmia, and even asphyxia when the larynx is involved. It is best treated by median external incision between the chin and hyoid, and Hilton's method of opening may often be employed with advantage.

The **tongue** is almost entirely a muscular organ, which has the hyoid bone as a point of attachment, both for several of its muscles and for the hyo-glossal ligament. It plays an important part in mastication, keeping the food between the teeth with the help of the lips and cheeks, and in swallowing, in which act it guides the food backwards, and, pushing down the epiglottis, to which three folds of mucous membrane run (*glosso-epiglottidean folds*), covers over the upper end of the trachea. It is curious to note that the soft yielding tongue is a potent factor in moulding the rigid jaw, which latter, after excision of the tongue, frequently falls in. While the tongue certainly plays an important part in speech, it is by no means essential for that purpose, patients frequently being able to speak excellently after excision of the tongue, and even swallowing is managed with practically no difficulty. The *mucous membrane* of the tongue presents on the dorsum anteriorly a large number of filiform and a less number of

fungiform papillæ, and posteriorly a row of circumvallate papillæ arranged in a V-shape, with the apex directed backwards. The *foramen cæcum* is situated at the apex, while the limbs stretch out and forwards toward the anterior palatine arches. Behind the circumvallate papillæ it is smooth but nodular, owing to the presence of the *lingual tonsil* beneath the surface. This posterior third of the tongue is almost vertical, and forms the anterior wall of the oral pharynx. When swollen, it may interfere with the action of the epiglottis, to which it is connected by a median fold of mucous membrane, the *frenulum epiglottidis*. The mucous membrane of this region is continuous laterally with that of the tonsils and pharynx. In many debilitated conditions the surface epithelium of the tongue accumulates and becomes sodden and stained, producing a *furred tongue*; while the *strawberry tongue* of scarlet fever is due to the bright red colour of the sparse fungiform papillæ scattered throughout the fur. While the surface normally is fairly smooth, save for the median raphe, it becomes much *fissured* in syphilis of the tongue, and is frequently associated with *leucoplakia*, in which the villi are generally destroyed and the epithelium becomes thick and white, resembling white oil-paint. The foramen cæcum is a remnant of the *thyro-glossal duct*, from which *cystic tumours*, some of which are malignant, and *dermoids* have developed. The latter have occasionally been so large as to protrude the tongue from the mouth.

The UNDER SURFACE of the tongue is covered with smooth, comparatively lax mucous membrane, and presents a median fold of mucous membrane, the *frenulum linguæ*, which extends from it to the floor of the mouth toward the lower jaw. This frenulum is sometimes very short, giving rise to the condition known as '*tongue-tie*,' which, when pronounced, may cause the infant difficulty in sucking. If it be necessary to cut it, this should be done with care close to the jaw, as a free incision may wound the ranine vessels, and even permit the tongue to turn over into the pharynx. On either side of the frenulum the *ranine vein* may be seen, lying near the surface, while the *arteries* run somewhat parallel, but much more deeply. The tongue is richly supplied with blood, and is a frequent seat of *nævi*. In addition to the lingual vessels (which send off a dorsal branch proximal to the usual place of ligature in the

neck, which supplies the root of the tongue and the tonsil), it receives blood by anastomosis with small branches of the ascending pharyngeal and facial arteries. The tongue possesses a rich *lymphatic* supply, the channels from the posterior half following the ranine vein to discharge into the deep cervical glands beneath the sterno-mastoid and angle of the jaw, while those from the anterior portion (that most frequently affected by carcinoma) pass through the mylo-hyoid muscle into the submaxillary glands. A great increase in the lymphatics, occurring congenitally, is known as *macroglossia*. It is a rare condition, and the tongue has become so much enlarged in such cases as to protrude several inches from the mouth, and even cause dislocation of the jaw. The tongue is occasionally affected by *parenchymatous glossitis*, in which it becomes greatly swollen, possibly protruding between the teeth, and tending to cause suffocation by backward pressure and œdema of the aryteno-epiglottic folds.

The *nerve-supply* of the tongue is rather complex. The twelfth is the motor nerve, supplying all the muscles (except the palato-glossus, which is supplied by the pharyngeal plexus). This nerve leaves the skull by the anterior condylar foramen, at which point it has been damaged by injury to the back of the head, giving rise to atrophy of half of the tongue. The lingual (fifth) supplies the anterior two-thirds of the tongue with common sensation, and tactile sensation is more sensitive at the tip of the tongue than in any other part of the body. In painful affections of the anterior portion of the tongue pain is frequently referred to the auditory meatus and skin of the surrounding parts (supplied by the auriculo-temporal branch of the fifth). The lingual may also supply taste to this portion, but it is more probably due to the chorda tympani (given off by the facial in the aqueduct of Fallopius), and in support of this view is the fact that the destruction of the chorda in the aqueduct has been followed by loss of taste in the tongue on that side, while stimulation caused sensations of taste. The chorda has also an effect on nutrition of the tongue (including the circumvallate papillæ). The epiglottis and base of the tongue are partially enervated by the internal laryngeal (of tenth).

The *muscles of the tongue* may be considered in three groups—intrinsic, extrinsic, and accessory. The *intrinsic* are com-

posed of a cortical layer of longitudinal fibres (with which the hyo- and stylo-glossi blend) and a central core of transverse and vertical fibres (with which fibres of the genio-glossi blend), which are divided into two lateral masses by the *septum*. The *extrinsic* consist of the hyo-, genio-hyo-, stylo-, and palato-glossi muscles, which largely compose the root of the tongue. The *accessory* consist of the muscles which act indirectly on the tongue through the hyoid bone—omo-, mylo-, genio-, stylo-, and sterno-hyoid, and digastric.

Unilateral paralysis of the tongue results in deflection to the affected side when the organ is protruded. *Complete paralysis* of the tongue, which is generally due to a central lesion, produces rapid atrophy and difficulty in swallowing. In the second stage of *anæsthesia* the tongue frequently tends to fall back, pushing down the epiglottis over the trachea. In such cases pushing forward the angle of the jaw is frequently effective, acting, as it does, on the extrinsic and accessory muscles of the tongue.

In addition to simple pyogenic ULCERS, which occur on the mucous membrane of the tongue and lips, the tongue is affected by tubercular, syphilitic, and carcinomatous ulcers. The syphilitic ulcers generally affect the dorsum, and can be comparatively easily differentiated, whereas tubercular and epitheliomatous ulcers generally affect the margin, are not always easy of differentiation, and generally demand excision of the tongue. Tubercular ulcers, however, are not so common as carcinomatous, and affect generally younger subjects. As a *carcinomatous growth* increases in size it tends to spread to the floor of the mouth, tonsil, etc. Pain over the anterior two-thirds, supplied by the lingual nerve, and salivation are generally pronounced in advanced cases, and to relieve these section of the lingual nerve has been done. *Hæmorrhage*, also, is sometimes serious. In EXCISING THE TONGUE it is generally well to begin by ligaturing both lingual arteries in the neck, and, at the same time, to remove the *submaxillary salivary gland* on the affected side, as it contains numerous lymphatic glands, which are generally involved at an early stage, and any other lymphatic glands in the submaxillary region, while, if necessary, by prolonging the posterior end of the wound upwards and backwards, the internal jugular and the glands surrounding it may be exposed. The facial artery

is almost necessarily cut if this be done. The mylo-hyoid muscles may next be cut through, and then the mucous membrane of the floor of the mouth, taking care to cut it close to the jaw on the diseased side. The two wounds in the neck are then packed with iodoform gauze. The tongue can now be drawn well forward in the mouth, and divided as far back as possible, care being taken to pass a stitch through the stump to prevent its falling back upon the epiglottis, and, with the same end in view, it is generally desirable to leave the genio-hyoids and genio-hyo-glossi intact on at least one side. The tongue has also been removed, after dividing the lower jaw, and by cutting out from the mouth by *écraseur*, or scissors, without previous ligature of the lingual.

The **palate** separates the buccal from the nasal cavities, and consists of two parts—hard and soft. The hard palate is formed by the palatal processes of the superior maxillary and palate bones, which present at their junction in the middle line the *palatal crest*, while the premaxillary bone forms the portion in the centre, anterior to the anterior palatine canal, which bears the upper incisor teeth. The *anterior palatine canal* transmits the naso-palatine nerves. The **HARD PALATE** becomes thinner posteriorly, and presents the posterior nasal spine projecting backwards from it. The *posterior palatine canal*, which transmits the vessels of that name (from internal maxillary), and the anterior palatine nerve (from Meckel's ganglion), is situated at the postero-external angle of the hard palate just inside the alveolus of the wisdom tooth. The hard palate is covered by a firm *muco-periosteum*, bound together by a quantity of connective tissue, which contains numerous mucous glands. It is nourished by the posterior palatine vessels, which run forward close to the bone to the anterior palatine foramen. The *arch of the palate* varies considerably in different individuals, and is said to be very high in congenital idiots. The **SOFT PALATE** is continued backwards from the posterior end of the hard palate, and consists anteriorly of a firm aponeurosis covered by mucous membrane, while posteriorly it contains muscles, etc., and is very movable. Its posterior free border presents two arches, folds of mucous membrane—the *pillars of the fauces*—on either side surrounding the *isthmus of the fauces* or entrance

to the pharynx. The *anterior* pillar contains the palato-glossi muscles and fuses with the dorsal aspect of the tongue, and the *posterior* contains the palato-pharyngei muscles and fuses with the pharyngeal wall. Between the pillars of the fauces the tonsils are lodged. Where the soft palate is cleft, the cleft is *narrowed* in swallowing by the superior constrictor. The levator palati and tensor palati muscles, on the other hand, arise near together from the Eustachian tube, and tend to *widen* it. The former passes down and inwards into the palate, while the latter descends to the *hamular process* (which is situated behind and to the inner side of the wisdom tooth), round which its tendon turns to run inwards. The soft palate derives its *blood-supply* from the posterior palatine of the internal maxillary and the ascending palatine of the facial, which latter accompanies the levator palati to the soft palate, and is cut in operations dividing that muscle. The palate itself is *enervated* by palatine branches from Meckel's ganglion, while the tensor palati is supplied by the third division of the fifth through the otic ganglion, and the levator palati, palato-pharyngei, and palato-glossi and azygos uvulæ by the eleventh through the pharyngeal plexus.

Cleft palate consists of a median cleft, which may vary from a bifid uvula to a complete separation, involving both soft and hard palates, and extending up to the premaxilla. Complete cases may be either uni- or bilateral, the nasal septum frequently fusing with one side in the former. When the cleft is quite complete, it generally passes on either side of the premaxilla, which then projects forwards, the condition being usually associated with *double hare-lip*. It is well to note, however, that the anterior extremity of the cleft generally does not run between the lateral incisor and canine, but between the central and lateral incisors, owing to a want of union between the two centres of which each lateral mass of the premaxilla is composed (the central or central incisor portion being called the endo-gnathion, and the lateral the meso-gnathion, while the rest of the maxilla is called the exo-gnathion). Sometimes this splitting involves the tooth germ of the lateral incisor, a supernumerary incisor being produced.

The height of the *arch of the palate* is of importance in some cases where an *osteoplastic* flap is used to remedy the condition, those cases presenting a high arch being the more hope-

ful. Sometimes a *muco-periosteal* flap is taken. The operation, where the hard palate is involved, is called *uranoplasty*, and in either case the incision is made close to the alveolar border and not extended as far back as the position of the wisdom tooth, so as to preserve the blood-supply.

Staphylorrhaphy is the refreshing and bringing together of the edges of a cleft of the soft palate. In such cases it is frequently necessary to divide the tensor and levator palati muscles in order to relax the parts, and this may be done by a lateral cut with scissors parallel to the cleft (Bryant), or by introducing a narrow-bladed knife, with the edge upwards, in front and to the inside of the hamular process till the point presents at the upper part of the cleft, which cuts the tensor, and then on withdrawing it cuts the levator posteriorly (Pollock). In Ferguson's method a knife with the blade at right angles to the handle is passed up through the cleft, and the levator cut on the posterior surface of the palate, the tensor being left intact.

Tonsil.—The tonsil is composed of lymphoid tissue, and is situated between the pillars of the fauces, being kept in position by fibrous bands, which connect its deep surface with the muscles of the palatine arches. This deep surface is closely in relation to the superior constrictor of the pharynx, but is not as near the external carotid artery, which lies in loose, fatty tissue about an inch behind, and considerably external to the tonsil. Thus there is practically no possibility of wounding the carotid in the operation of *tonsillotomy*, save where, in old age, the vessel has become very tortuous. The facial or ascending pharyngeal arteries or glosso-pharyngeal nerve are in greater danger of being wounded. The inner or free surface is convex, and presents numerous depressions corresponding to the orifices of the crypts. A small depression at the upper extremity is known as the *supratonsillar fossa*, and is said to represent the pharyngeal extremity of the second branchial cleft. The *blood-supply* is abundant, being derived from branches of the facial, ascending pharyngeal of the external carotid, descending palatine branches of the internal maxillary and small branches of the dorsalis linguæ. The veins form a plexus on the deep surface, and communicate with the pharyngeal veins. The *lymphatics* communicate with the deep cervical glands which overlie the large vessels

behind the angle of the lower jaw. The tonsil varies considerably in size within normal limits, and in *tonsillitis* or *cynanche tonsillar* may become very much enlarged, the two tonsils meeting in the middle line, and leaving a very small breathing space, while swallowing becomes very difficult. Where the enlargement becomes chronic, tonsillotomy has frequently to be performed. *Deafness* is frequently complained of in cases of enlarged tonsils, being due, probably, to accompanying hypertrophy of the lining membrane of the Eustachian tube rather than to direct pressure. Decomposition of secretions retained in the crypts frequently occurs, giving rise to foetid breath, and *calculi* may form, and give rise, through irritation of the glosso-pharyngeal nerve, to a spasmodic cough. *Tonsillar abscesses*, which not infrequently complicate scarlet fever, occur interstitially or between the tonsil and the pharyngeal wall. Movements of the jaw are interfered with, and the glands at the angle of the jaw enlarge. Such abscesses may perforate the pharyngeal wall, and assume a large size, the greatest danger being septic periarteritis of the internal carotid, with consequent bursting and fatal hæmorrhage. In *opening such abscesses* the edge of the bistoury should be turned toward the uvula, the incision being made from without inwards toward the middle line. *Lympho-sarcoma* sometimes occurs in the tonsil de novo. *Carcinoma* is generally secondary, and rapid involvement of the glands of the neck generally follows. Such cases may be treated through an oblique incision in front of the sternomastoid, which enables one to deal with primary disease and affected glands.

The **PHARYNX** extends from the basis cranii to the lower border of the sixth cervical vertebra. It is about 5 inches long, and is very distensible. It is common to both respiratory and digestive tracts, and may be divided into naso-pharyngeal, buccal, and laryngeal portions.

The NASO-PHARYNGEAL portion is situated above the soft palate and behind the nasal fossæ. Its postero-superior wall is formed by the basis cranii, anterior arch of the atlas, and body of the axis, together with their muscles and ligaments. The *Eustachian tubes* project on the lateral walls, while from their lower borders folds of mucous membrane, known as the *salpingo-pharyngeal* folds, extend downwards. Behind the

Eustachian tubes, and beneath the petrous bones, are lateral recesses known as the *fossæ of Rosenmüller*, and here the pharynx is widest.

The **BUCCAL PORTION** extends from the arch of the soft palate to the epiglottis and upper extremity of the larynx. In front it communicates with the mouth through the isthmus of the fauces, below which it is bounded by the dorsum of the tongue, while laterally it is bounded by the pillars of the fauces and tonsil.

The **LARYNGEAL PORTION** extends the whole length of the larynx from its upper extremity to the lower border of the cricoid. It is the longest but least capacious portion. On each side, in front, below the great cornu of the hyoid and between the larynx and pharyngeal wall is the *pyriform fossa*. The pharynx is *narrowest* at its junction with the œsophagus, just at the cricoid cartilage, and here, therefore, *foreign bodies* are most apt to lodge. This point is about 6 inches from the teeth, and cannot be reached by the finger. The walls of this portion of the pharynx are in contact, save in swallowing, forming a crescentic slit, with the concavity directed forwards.

The *pharyngeal wall* consists of mucous membrane, pharyngeal aponeurosis, and muscles. Outside of these is the thin *bucco-pharyngeal fascia*, which invests the buccinator in front. The *mucous membrane* is vascular, prone to inflammatory affections, which may spread to the Eustachian tube, and so to the ears, and contains much lymphoid tissue, which—in the child, at least—forms a distinct mass in the posterior wall of the pharynx, stretching between the Eustachian tubes, known as the *pharyngeal tonsil of Luschka*. It frequently becomes hypertrophied, giving rise to *post-nasal adenoids*, which may block the posterior nares or Eustachian tubes, causing deafness.

The *pharyngeal aponeurosis* is a thin fibrous sheet, which is best developed posteriorly where the muscles are weakest. The *muscles* consist of the stylo- and palato-pharyngei, together with the three constrictors, which latter overlap one another from below upwards. The *bucco-pharyngeal fascia* has very lax connections with the surrounding parts, and so permits of considerable movement, while it also favours the spread of inflammatory affections, which may extend to the posterior mediastinum, or even to the diaphragm.

A *retro-pharyngeal lymphatic gland* is situated in the loose tissue opposite the axis, which receives lymph from the nares, and is prone to suppuration. An *acute post- or retro-pharyngeal abscess* may originate in the cellular tissue or from this gland, in front of the prevertebral layer of deep cervical fascia, and present on the posterior pharyngeal wall, causing difficulty in respiration and in swallowing. *Chronic abscess* in this situation generally arises from cervical caries, and is, therefore, behind the prevertebral layer of the deep cervical fascia. Retro-pharyngeal abscesses generally burst into the mouth, but may pass behind the great vessels, and present to one side or other of the sterno-mastoid. The acute abscess is best *treated* by a vertical mesial incision through the mouth, keeping the head low to prevent the pus reaching the larynx. In order to prevent sepsis, the tubercular abscess is best evacuated through an incision along the posterior border of the sterno-mastoid, beginning at the tip of the mastoid process. The deep structures are divided by a blunt dissector, care being taken to avoid the great vessels, until the abscess is reached. Lateral pharyngeal abscess may be similarly treated, care being necessary to diagnose between abscess and aneurism of the internal carotid.

Posteriorly the pharynx is in relation to the six upper cervical vertebræ, anterior common ligament, prevertebral muscles and fascia, and retro-pharyngeal glands. *Laterally* it is related to the internal carotid artery, internal jugular vein, and ninth, tenth, eleventh, and twelfth cranial nerves and sympathetic. These structures may be wounded by instruments, introduced through the mouth, penetrating the pharynx. The pharynx is also in relation to the styloid process and muscles which arise from it, the posterior belly of the digastric and internal pterygoid muscles, and the parotid gland. Toward its lower extremity it is more superficial, and is related to the common carotid and its branches, the first portions of the lingual and facial arteries, the laryngeal nerves, and lateral lobe of the thyroid. *Pharyngotomy* may be performed for the removal of tumours, either laterally, through an incision similar to that for ligature of the lingual artery, or mesially. The tumours likely to occur are *naso-pharyngeal fibroma and sarcoma*, the latter frequently invading the nasal cavities and orbit.

THE NECK

Surface Anatomy.

The **neck** is bounded above by a line drawn along the lower border of the lower jaw to the angle, thence to the mastoid process, and so to the superior curved line and external occipital protuberance; below, by a line from the suprasternal notch along the upper border of the clavicle to the acromion, and from thence to the spine of the vertebra prominens (seventh cervical). It is pretty constant in length—generally about 5 inches.

The *hyoid bone*, which is on the level of the fourth cervical vertebra, divides the anterior portion of the neck into two triangles, of each of which it forms the base—an upper, or **SUBMAXILLARY**, which is best seen when the head is thrown back, whose sides are formed by the rami of the jaw, and a lower, or **INFRA-HYOID**, whose sides are formed by the sternomastoid muscles. The latter, again, is divided into two *carotid* triangles by the *middle line of the neck*, which presents several points of importance. Between the hyoid bone and thyroid cartilage the *thyro-hyoid membrane* extends. The *vocal cords* are situated about the level of the middle of the thyroid crest. The lateral lobes of the *thyroid gland* lie to either side of the thyroid cartilage. Below the thyroid cartilage comes the *crico-thyroid membrane* which connects these structures, and through which *laryngotomy* may be done, by means of a small transverse incision as close to the cricoid as possible, so as to avoid damage to the crico-thyroid vessels. The *cricoid cartilage* forms a prominent and useful landmark, even in infants. It is on a level with the fifth or sixth cervical vertebra, and the commencement of the oesophagus lies behind it. Foreign bodies too large to be swallowed frequently lodge at this level. The carotid artery is conveniently ligatured just above the point where it is crossed by the omo-hyoid muscle on a level with the cricoid cartilage, the tubercle of the sixth cervical vertebra forming a further guide. The lower margin of the cricoid corresponds

with the junction of larynx and trachea. The *trachea* is not easily made out superficially, as it passes in deeply, lying about $1\frac{1}{2}$ inches from the surface at the suprasternal notch, above which point lie the first seven rings of the trachea. The *inferior thyroid vein* lies in front of the trachea, below the isthmus of the thyroid. The *suprasternal notch* is generally opposite the lower border of the second dorsal vertebra, but may be opposite the third. The *anterior jugular veins*, which commence in the submaxillary region, descend on the sternohyoid muscles to either side of the middle line, and then pierce the fascia just above the clavicle. Behind the *sterno-clavicular joint* lie the commencement of the innominate vein, the innominate artery on the right and the carotid on the left, and, more deeply, the lung and pleura.

The STERNO-MASTOID REGION is that which is covered by the muscle of that name. The muscle presents a small fossa—the *fossa supraclavicularis minor*—between its two heads and just above the sterno-clavicular articulation, the base of which corresponds on the right side with the bifurcation of the innominate, and on the left is in front of the common carotid, while the internal jugular vein lies a little external. Thus these important structures are in danger in subcutaneous tenotomy of the sternal head. The *external jugular vein* crosses the muscle superficially from above, downwards and backwards, in a line drawn from the angle of the jaw to the middle of the clavicle, while the *anterior jugular vein* generally runs along the anterior border of the muscle. On its deep surface the *spinal accessory nerve* passes obliquely down and backwards, and enters the muscle, which it supplies, about $1\frac{1}{2}$ inches below the mastoid process, at the junction of its anterior and middle thirds. On leaving the muscle, it enters the posterior triangle of the neck midway between the occiput and clavicle, to end in the deep surface of the trapezius.

The posterior border of the sterno-mastoid nearly corresponds with that of the scalenus anticus, the guide to the subclavian artery.

The *apex of the lung* rises well into the neck, extending generally $1\frac{1}{2}$ inches above the clavicle, under cover of the clavicular portion of the sterno-mastoid, sterno-thyroid, and part of the scalenus anticus, and first part of the subclavian vessels.

The **POSTERIOR TRIANGLE** of the neck is the space bounded by the sterno-mastoid in front, the trapezius behind, and the middle third of the clavicle below. The surface of the triangle is depressed above the clavicle forming the *supra-clavicular fossa*, which is traversed by the subclavian vessels and cords of the brachial plexus. The *subclavian artery*, lying on the first rib, may be felt in this depression, close to the border of the sterno-mastoid, and may be compressed against the rib by pressure applied downwards and inwards. The posterior belly of the *omo-hyoid* can be felt, and sometimes seen, as a thin cord just above, and running parallel to, the clavicle. In the upper part of the fossa the transverse process of the *seventh cervical vertebra* may be felt on deep pressure.

The **POSTERIOR REGION** of the neck is bounded on either side by the anterior edge of the trapezius, and presents two lateral masses, formed by the trapezius and complexus muscles on either side, separated by a slight central depression, under which lies the *ligamentum nuchæ*, extending from the occipital protuberance to the spine of the *vertebra prominens* (seventh cervical). The *spine of the axis* may be felt on deep pressure at the upper end of the central depression.

The **skin** of the neck is smooth, and freely movable in front, and particularly so in the submaxillary region, where advantage is taken of this in performing certain plastic operations about the mouth, while the same property favours cicatricial contraction and deformity. The *platysma myoides* is quite subcutaneous, and by its connections causes turning in of the edges of wounds made across the line of its fibres, which run upwards and forwards. Sometimes the accumulation of *subcutaneous fat* in this region may be great, and give rise to a pendulous fold known as a 'double chin.' At the back of the neck the skin is thicker and more adherent, contains numerous sebaceous glands, is generally exposed to friction, and is a favourite seat of *boils* and *carbuncles*. As the subcutaneous tissues are dense, and the blood-supply not very abundant, these affections are frequently painful, and sloughing is not uncommon.

The **cervical fascia** consists of three principal layers :
 (1) A superficial investing layer, which, attached to the ligamentum nuchæ behind, runs round the neck, splitting as it

does so to enclose the trapezius and sterno-mastoid muscles, to join its neighbour of the opposite side in front, where it

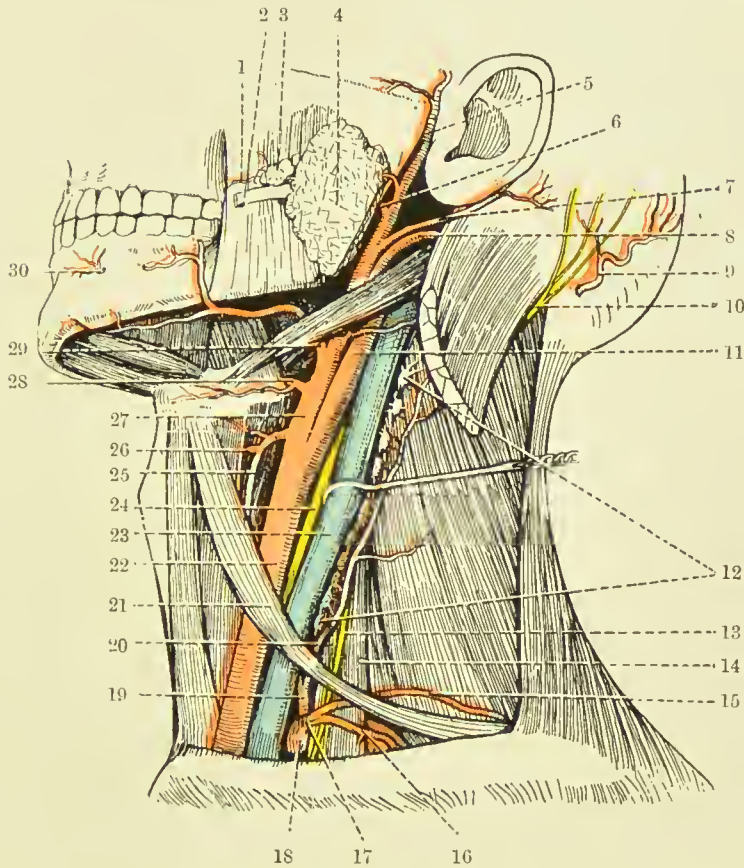


FIG. II.—DEEP DISSECTION OF THE LEFT SIDE OF THE NECK
(Buchanan, after Spalteholz.)

- | | |
|---------------------------------|------------------------------------|
| 1. Transverse facial artery. | 16. Suprascapular artery. |
| 2. Stensen's duct. | 17. Thyroid axis. |
| 3. Socia parotidis. | 18. Subclavian artery (first part) |
| 4. Parotid gland. | 19. Inferior thyroid artery. |
| 5. Superficial temporal artery. | 20. Ascending cervical artery. |
| 6. Internal maxillary artery. | 21. Anterior belly of omo-hyoid. |
| 7. Posterior auricular artery. | 22. Common carotid artery. |
| 8. Occipital artery. | 23. Internal jugular vein. |
| 9. Occipital artery. | 24. Pneumogastric nerve. |
| 10. Great occipital nerve. | 25. Superior thyroid artery. |
| 11. Internal carotid artery. | 26. Superior laryngeal artery. |
| 12. Deep cervical glands. | 27. External carotid artery. |
| 13. Phrenic nerve. | 28. Lingual artery. |
| 14. Scalenus anticus muscle. | 29. Facial artery. |
| 15. Transverse cervical artery. | 30. Mental artery. |

has an attachment to the hyoid bone. Above, following it from behind, it is attached to the superior curved line of the

occiput, mastoid process, and cartilage of the external auditory meatus; then it splits to enclose the parotid gland, (*parotid capsule*—the anterior layer being attached to the zygoma and the posterior to the styloid process and angle of the jaw, forming the stylo-maxillary ligament), and finally is attached to the margin of the lower jaw. Below it is attached to the clavicle and manubrium sterni, the fascia splitting close to its insertion into the latter to enclose the sternal head of the sterno-mastoid, some lymphoid tissue, and the anterior jugular vein. The anterior layer is attached to the front of the manubrium and the posterior to the back of the bone, and it is this compartment which is opened into in dividing the sternal head of the sterno-mastoid. This superficial layer supplies a *capsule* to the *submaxillary gland*.

(2) A PRETRACHEAL LAYER lies immediately under the superficial layer in front, and invests the anterior group of muscles (sterno-hyoid, etc.). It also furnishes a capsule for the thyroid gland, helping to connect it with the cricoid cartilage, and laterally forms the anterior portion of the carotid sheath. Above, it is attached to the hyoid bone; below, it passes behind the sternum into the thorax, where it fuses with the fibrous pericardium. This layer extends into the posterior triangle of the neck, where it invests the posterior belly of the omo-hyoid. Above this it fuses with the deep aspect of the sterno-mastoid sheath (layer No. 1), while below it is attached to the clavicle and sheath of the subclavius muscle (whence it becomes continuous with the costo-coracoid membrane).

(3) A PREVERTEBRAL LAYER runs across the neck in front of the prevertebral muscles, forming a partition between the posterior muscular and anterior visceral segment of the neck. Above, it is attached to the basis cranii, and below it is continued into the thorax. Laterally, this layer fuses in the upper part of the neck with the carotid sheath, the posterior part of which it forms; while in the lower portion of the neck it extends laterally into the posterior triangle lying over the subclavian vessels and cords of the brachial plexus, and accompanying them into the axilla. As the deep cervical fascia is very tense and strong, *abscesses* in the neck have generally difficulty in reaching the surface, except those which occur in the front of the neck just under the superficial investing layer, which is thin at this part. In many instances,

therefore, abscesses, especially those occurring between layers Nos. 2 and 3, instead of coming to the surface, penetrate some of the structures in the neck, such as the trachea and œsophagus, and sometimes the pleura, or even the great vessels. A *prevertebral abscess*, lying as it does behind layer No. 3, might be guided by it down into the posterior mediastinum, or, following the layer covering the subclavian vessels, reach the posterior triangle or the axilla. Not infrequently, however, these abscesses point in the pharynx or œsophagus. Layers Nos. 2 and 3 form a compartment for the pharynx, larynx, and great vessels, etc., and as these lie loosely in this space, surrounded by connective tissue, they are free to move with respiration and deglutition, and to accommodate themselves to pressure of tumours, etc.

The **muscles of the neck** may be considered in three groups: (1) Trapezius and sterno-mastoid, constituting the superficial group; (2) sterno- and omo-hyoid, the anterior group; (3) prevertebral, scalene or lateral vertebral, and post-vertebral, the deep vertebral group.

Of these the STERNO-MASTOID is the most important. The two heads, one arising from the front of the manubrium as a rounded tendon, and the other from the inner third of the clavicle as a mixed muscular and tendinous bundle, are at first separate, but the sternal portion, as a rule, rapidly widens out, and conceals the other. The *clavicular head* is in relation below to the subclavian vein and to the external jugular vein on its way to join it; the *interspace*, to the bifurcation of the innominate on the right, which, however, lies deeply. The great vessels of the neck and vagus nerve lodged in the carotid sheath, and the sympathetic lying behind it, are overlapped by the anterior border of the muscle over a considerable portion of their extent, while the spinal accessory nerve runs obliquely downwards and backwards behind it, about a couple of inches below the mastoid process. The deep lymphatic glands of the neck are covered, and the lateral lobe of the thyroid is overlapped by it. On the anterior border of the muscle at the level of the great cornu of the hyoid the internal jugular vein is joined by its lingual, facial, and superior thyroid branches. From the centre of the posterior border of the muscle several nerves, derived from the cervical plexus, radiate: (1) The small occipital runs upwards along

the posterior border of the muscle. (2) The great auricular runs vertically upwards across the muscle to the ear. (3) The superficial cervical runs transversely across the muscle; and (4) the descending suprasternal, clavicular, and acromial

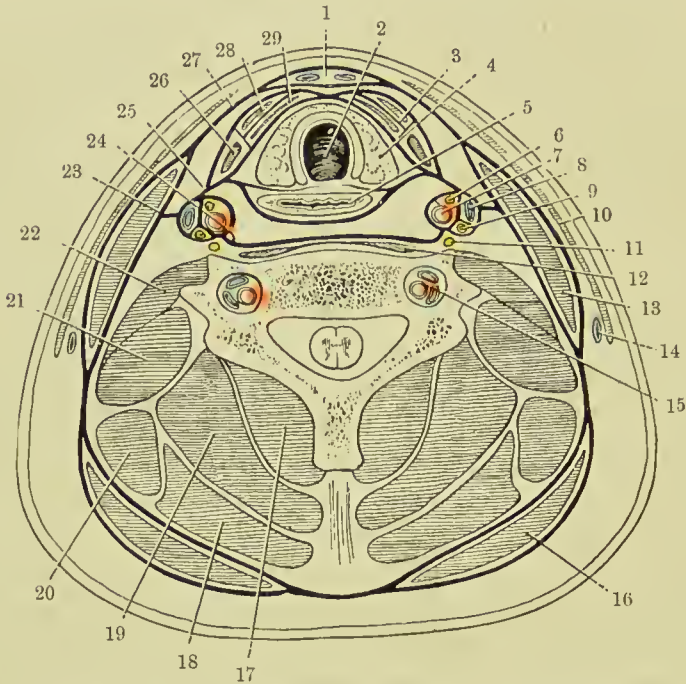


FIG. 12.—DIAGRAM OF A TRANSVERSE SECTION OF THE NECK AT THE LEVEL OF THE SEVENTH CERVICAL VERTEBRA, SHOWING THE ARRANGEMENT OF THE DEEP CERVICAL FASCIA, AND THE POSITIONS OF OTHER STRUCTURES.

(From Buchanan's "Anatomy.")

- | | |
|----------------------------------|------------------------------------|
| 1. Burns's space. | 16. Trapezius. |
| 2. Trachea. | 17. Semispinalis. |
| 3. Muscular compartment. | 18. Splenius. |
| 4. Lateral lobe of thyroid body. | 19. Complexus. |
| 5. Esophagus. | 20. Levator anguli scapulae. |
| 6. Descendens cervicis nerve. | 21. Scalenus medius. |
| 7. Common carotid artery. | 22. Scalenus anticus. |
| 8. Internal jugular vein. | 23. Carotid lamina of fascia. |
| 9. Pneumogastric nerve. | 24. Prevertebral lamina of fascia. |
| 10. Platysma myoides. | 25. Pretracheal lamina of fascia. |
| 11. Sympathetic nerve. | 26. Anterior belly of omo-hyoid. |
| 12. Longus colli. | 27. Superficial lamina of fascia. |
| 13. Sterno-cleido-mastoid. | 28. Sterno-hyoid. |
| 14. External jugular vein. | 29. Sterno-thyroid. |
| 15. Vertebral vessels. | |

branches radiate downwards to the parts indicated. In *torticollis*, or wry-neck, which is generally due to spasm of the muscles, the head is leant to the affected side, and slightly bent forwards, while the face looks toward the sound side.

The muscle, and particularly its sternal head, becomes very prominent, and a lateral curvature of the spine frequently exists. In some of the more severe cases the trapezius and scalene muscles may also be affected. The condition may be due to some affection of the muscle itself (permanent torticollis), or may be due to irritation of the spinal accessory nerve (spasmodic torticollis). The *spasmodic* form is sometimes induced by reflex irritation, such as lymphadenitis in the posterior triangle affecting one of the cervical nerves, of which the second supplies the muscle, in addition to the spinal accessory. In the *permanent* types of torticollis the sternal head of the muscle may be divided either subcutaneously by a puncture $\frac{3}{4}$ inch above the clavicle in front of the muscle, the tenotome being made to cut out, or by an open incision also $\frac{3}{4}$ inch above the clavicle. In the spasmodic type the *spinal accessory nerve* may be divided or resected, an incision being made along the anterior border of the muscle, and the posterior belly of the digastric and transverse process of the atlas being taken as guides. Sometimes it is also well to cut the communicating branches of the third and fourth cervical nerves. The muscle may also be affected by a *congenital tumour*, sometimes associated with shortening, and consequent torticollis, which may be due to syphilis or to injury during delivery.

Of the prevertebral muscles the SCALENE MUSCLES arise from the transverse processes of several of the cervical vertebræ, the ANTICUS from the anterior tubercles, and the MEDIUS and POSTICUS from the posterior. The two former are inserted into the first rib, the subclavian artery, cords of the brachial plexus, and the pleura lying between them, while the subclavian vein passes in front of the anticus. The scalenus posticus is inserted into the second rib. They are all supplied by the lower cervical nerves. The MUSCLES OF THE BACK OF THE NECK are in direct continuity with those of the back generally, and form two large lateral masses, with a median vertical depression opposite the spines of the vertebræ. These muscles, as seen in transverse section of the neck, may be considered as forming *five layers*, the *most superficial* being formed by the trapezius, the *second* by the splenius capitis and colli (the levator anguli scapulæ interdigitating between the trapezius and the splenius colli in

front), the *third* by the complexus, *fourth* by the semispinalis colli, and the *fifth* by the multifidus spinæ. More anteriorly, behind the splenius colli and anterior end of the complexus, lie from without inwards the transversalis cervicis and the trachelo mastoid. Between the complexus and semispinalis colli lie the profunda cervicis artery and vein (from superior intercostal or subclavian). The infra-hyoid muscles comprise the sterno-hyoid and thyroid, omo-hyoid, and thyro-hyoid. Of these the STERNO-THYROID, arising from the deep surface of the sternum, is deeply placed, and runs parallel to the larynx and trachea. The THYRO-HYOID practically continues the preceding muscle up to the hyoid. The STERNO-HYOID arises from the clavicle and also from the deep surface of the sternum, but superficial to the sterno-thyroid, and passes up to the hyoid bone internal to the omo-hyoid. The OMO-HYOID is important surgically, as its anterior portion crosses the common carotid artery at the level of the cricoid cartilage, where the vessel is ligatured, and divides the *anterior triangle* into muscular and carotid triangles, while the posterior belly divides the *posterior triangle* into occipital and subclavian triangles, the latter containing the portion of subclavian selected for ligature of that artery. It is inserted above into the hyoid between the thyro-hyoid and sterno-hyoid, and below into the superior border of the scapula, while the tendon is held down by a process of deep cervical fascia. The omo-hyoids are said by their action to render the pre-tracheal layer of the deep cervical fascia tense, and so protect the deep veins from the pressure of the sterno-mastoids when contracting. The DIGASTRIC is also of importance, as with the lower border of the jaw it forms the boundaries of the *triangle* of that name. Attached posteriorly to the digastric groove beneath the mastoid process and muscles rising from it, it runs forwards and downwards to the hyoid bone (to which its tendon is attached by a process of cervical fascia), crossing the carotid artery and hypoglossal nerve in its course, and then turns forwards and upwards to the lower border of the chin. The MYLO-HYOID lies under the digastric, and runs downwards and forwards from the jaw to the hyoid bone and to a median raphe, forming a diaphragm for the floor of the mouth, part of its inner surface being covered with mucous membrane, and separated from the hyo-glossus by a deep

portion of the submaxillary gland, sublingual gland, and Wharton's duct, and lingual and hypoglossal nerves. The *HYO-GLOSSUS*, running upwards and forwards from the hyoid bone to the side of the tongue, is visible behind the posterior margin of the mylo-hyoid, with the hypoglossal nerve and ranine vein running horizontally across it, the former being generally the upper. The *lingual artery* runs on the deep surface of the *hyo-glossus*.

Submaxillary Region.—The submaxillary region may be divided into a median submental triangle, common to both

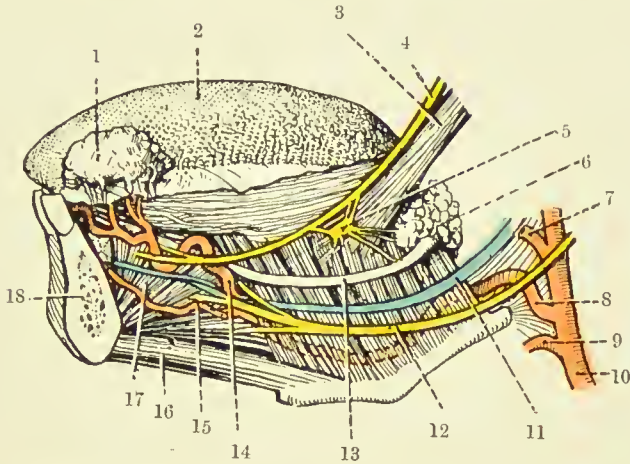


FIG. 13.—DEEP DISSECTION OF THE LEFT SUBMAXILLARY REGION.
(From Buchanan's "Anatomy.")

- | | |
|------------------------------------|-------------------------------|
| 1. Sublingual gland (turned up). | 10. External carotid artery. |
| 2. Dorsum of tongue. | 11. Ranine vein. |
| 3. Stylo-glossus muscle. | 12. Hypoglossal nerve. |
| 4. Lingual nerve. | 13. Wharton's duct. |
| 5. Submaxillary ganglion. | 14. Ranine artery. |
| 6. Submaxillary gland (deep part). | 15. Sublingual artery. |
| 7. Facial artery. | 16. Genio-hyoid muscle. |
| 8. Lingual artery. | 17. Genio-hyo-glossus muscle. |
| 9. Superior thyroid artery. | 18. Mandible (in section). |

sides, a digastric triangle, and a space between the stylo-hyoid and digastric which widens posteriorly. The sides of the *SUBMENTAL TRIANGLE* are formed by the anterior bellies of the digastric, the base by the hyoid bone, and the apex by the symphysis. The floor is formed by the median raphe and portions of both mylo-hyoids. One or two submental lymphatic glands are generally situated at the apex of the triangle. The sides of the *DIGASTRIC TRIANGLE* are formed by that muscle with the stylo-hyoid, the base being the lower border of the jaw and stylo-mandibular ligament,

the apex being the intermediate tendon of the digastric. On exposing the triangle, the *submaxillary gland* is found to occupy most of the space, and particularly where infected by carcinoma may overlap the margin of that triangle. On turning the gland upwards, we find that the floor is formed in front by the fibres of the *mylo-hyoid* running downwards and forwards, while behind it, and on a deeper plane, are the fibres of the *hyo-glossus*, running downwards and backwards, and crossed by the hypoglossal nerve and ranine vein (the former generally above the latter), running parallel forwards, to disappear beneath the posterior border of the mylo-hyoid. Behind the hyo-glossus, and still deeper, are the fibres of the *superior constrictor* of the pharynx, also running downwards and backwards. The *lingual artery* is given off just opposite the tip of the great cornu of the hyoid, and, running on the deep surface of the hyo-glossus, pursues the same course as the vein, which is superficial to the muscle, and is accordingly taken as a guide. The artery is generally ligatured at this point in the so-called *lingual triangle*, formed by the ranine vein as a base, the posterior belly of the digastric posteriorly, and the posterior border of the mylo-hyoid anteriorly, the fibres of the hyo-glossus being separated in order to get at the artery. The ligature of the artery on each side generally forms a preliminary to excision of the tongue.

The *facial artery* is given off immediately above the lingual, and runs up to the angle of the jaw, and then runs parallel to and just under the ramus of the jaw to the anterior border of the masseter. It lies on the deep surface of the submaxillary gland, which separates it from its vein. The submental branch of the facial runs along the under border of the jaw to the symphysis, and supplies the submaxillary and sublingual glands. The submaxillary *lymphatic glands* lie on either surface of the submaxillary gland, with which they are closely connected, some being situated within the capsule of the gland or incorporated in the gland substance. The superficial ones drain the nose, cheek, and lips, while the deeper drain the salivary glands, anterior part of the tongue, and floor of the mouth. These glands are frequently the seat of tubercular and secondary carcinomatous infection. They and their ducts are also infected by inflammatory affections, a very acute form being known as *Ludwig's angina*.

The *hyoid bone* possesses very considerable mobility, and hence is not frequently *fractured*, save by severe direct violence, as in throttling. As a rule, the great cornu is the part broken off. Where fracture occurs, the patient has much difficulty in speaking and other movements of the tongue, and especially in swallowing, owing to want of support to the middle constrictor. The bone presents many attachments: to the tongue (by the hyo-glossus and genio-hyo-glossus and hyo-glossal ligament); to the epiglottis (by the hyo-epiglottic ligament); to the lower jaw; base of the skull, sternum, and scapula; larynx (by the thyro-hyoid muscles and membrane); pharynx (by the middle constrictor).

The Infra-Hyoid Region.—The *thyro-hyoid membrane* extends between the posterior aspect of the upper border of the hyoid bone and great cornu, and the upper border of the thyroid cartilage, and is rather over an inch in vertical depth. This arrangement permits of the ascent of the larynx behind the hyoid in deglutition. Between the under surface of the hyoid bone and the anterior aspect of the membrane the *thyro-hyoid bursa* is placed. This sometimes becomes enlarged, necessitating removal. The membrane is superficial in front, is covered laterally by the sterno-, thyro-, and omohyoid muscles, and is pierced by the superior laryngeal artery and internal laryngeal nerve. The deep surface is connected by a pad of fatty tissue with the epiglottis and aryteno-epiglottic folds. The membrane is not infrequently divided in *suicidal wounds*, as are likewise the epiglottis and anterior wall of the pharynx. The superior thyroid artery and internal laryngeal nerve frequently suffer, while the larger vessels, owing to their mobility, escape. Division of the internal laryngeal nerve causes anæsthesia of the laryngeal mucous membrane, and permits particles of food to enter the air passages and set up septic pneumonia. An incision made through the membrane affords access to the upper portion of pharynx and larynx, and is sometimes useful in removing foreign bodies or tumours from these parts.

The **larynx** moves up and down in certain movements of the head and neck, in deglutition, slightly in respiration, and laterally from passive movement. It is more highly placed in children and women than in men, the cricoid being at the level of the lower border of the fourth cervical in the infant,

while by puberty it has reached the adult position, opposite the lower border of the sixth. It is lined with mucous membrane, which is continuous with that of the pharynx above and trachea below. In the middle line it is quite superficial, being covered only by skin, subcutaneous tissue, and deep fascia, but laterally is covered by the sterno-, thyro-, omohyoid, and sterno-thyroid muscles, and the lateral lobes of the thyroid gland. Posteriorly, the *lumen* of the larynx is maintained at the expense of that of the pharynx, which is generally flattened. Laterally, on each side, there is a recess, the *pharyngo-laryngeal*, the upper extremity of which (situated above and external to the aryteno-epiglottic folds, and in which foreign bodies may lodge) is known as the *pyriform fossa*. The *upper aperture* of the larynx, when at rest, looks almost directly backwards. It is bounded in front by the *epiglottis*, laterally by the aryteno-epiglottic folds, and posteriorly by the arytenoid cartilages and the notch between them. The *interior* of the larynx is lined by *mucous membrane*, which varies much in thickness and laxness, according to the amount of subcutaneous tissue. The thickest portions are at the *aryteno-epiglottic folds*, the ventricle, false cords, and laryngeal portion of the epiglottis, and these are particularly affected in laryngitis and *œdema of the glottis*. The latter affection is a very serious one, which specially affects the aryteno-epiglottic folds (not the vocal cords), and so may cause asphyxia. At the true vocal cords the mucous membrane is firmly adherent, and presents stratified epithelium, whereas at other parts it is lined with ciliated epithelium. *Epithelioma* is not infrequently found at the point of junction of the two forms of epithelium, and this position is also a favourite one for *papilloma*. The mucous membrane is rich in mucous glands, except at the vocal cords, and these glands are specially numerous in the regions of the arytenoids, ventricle, and base of the epiglottis. The *glands* become affected in chronic glandular laryngitis, clergyman's sore-throat, etc. The mucous membrane receives its chief *nerve-supply* from the two internal laryngeal nerves (from the superior laryngeal of the vagus), and is extremely sensitive to contact with a foreign body, calling forth spasm and reflex expulsive cough, by which entrance of such bodies to the trachea is prevented. When these nerves are divided, this

sensation is lost, foreign matter may enter the lungs, and so set up a septic broncho-pneumonia. As these nerves are also inhibited to a considerable extent by chloroform, it is necessary for the administrator to see that no blood, mucus, or other foreign matter is inspired during narcosis. The other branch of the superior laryngeal is the external laryngeal, which supplies the crico-thyroid, while the *recurrent laryngeal*, also a branch of the vagus, supplies all the intrinsic muscles, except the crico-thyroid. The mucous membrane receives its *blood-supply* from three vessels on either side—superior laryngeal and crico-thyroid from the superior thyroid, and inferior laryngeal from the inferior thyroid—and is very vascular, save at the true vocal cords. The *lymphatics* from parts above the glottis pass upwards and outwards through the thyro-hyoid membrane to end in glands under the great cornu of the hyoid, or at the bifurcation of the common carotid; while those from below the glottis terminate in glands on either side of the trachea. The mucous membrane is thrown into two antero-posterior folds on either side, forming the vocal cords, which divide the larynx into three compartments—an upper, or *vestibule*, which extends from the aryteno-epiglottic folds to the false cords; a *middle*, between the false and true cords; and a *lower*, which extends from the true cords to the lower border of the cricoid. The upper pair of cords, or *false cords*, are not so markedly developed, do not closely approach one another, and do not produce the voice. The *true vocal cords*, or inferior thyro-arytenoid ligaments, are inserted together anteriorly in the angle of junction of the thyroid alæ, midway between the median notch and the lower border, while posteriorly they diverge, and are inserted into the *processus vocales* of the arytenoid cartilages. They consist of white fibrous tissue, covered with stratified mucous membrane. The lateral wall of the larynx, in the middle compartment, presents a recess, or pocket, on either side—the *ventricle*, from which, anteriorly, is given off a small diverticulum, the *laryngeal saccule*, which extends upwards between the false vocal cord and the ala of the thyroid cartilage. The *rima glottidis* is the fissure formed anteriorly by the true vocal cords (*glottis vocalis*), and posteriorly by the bases and vocal processes of the arytenoids (*glottis respiratoria*). It is the narrowest part of the larynx, being about

$\frac{1}{3}$ inch at its widest part, and is nearly 1 inch long antero-posteriorly. It is situated rather below the centre of the cavity, and forms the communication between the middle and lower compartments of the larynx. In making a *laryngoscopic examination*, the tongue is pulled forwards and downwards, and the warmed mirror is introduced, pushing the soft palate upwards and backwards. Light from the forehead mirror having been thrown on it, the base of the tongue, epiglottis, and glosso-epiglottic folds are seen with the vallecula on either side of the median glosso-epiglottic fold (in which may lodge a foreign body). Then the aryteno-epiglottic folds, presenting posteriorly the elevations due to the cuneiform cartilages externally, and those of Santorini internally, are seen. The false cords appear fairly wide apart, and of a pink colour, while the true cords project inwards toward one another, are of a pearly-white colour, and are wide apart when the patient says 'ah,' and close together when he says 'ee.' Between the false and true cords a dark interval indicates the entrance to the ventricle. When the glottis is wide open, it is sometimes possible to see as far as the bifurcation of the trachea.

The THYROID CARTILAGE is composed of hyaline cartilage, but begins to ossify about the twentieth year near the crico-thyroid joint. As ossification progresses with age, the cartilage becomes brittle, and may occasionally be *fractured* in old persons by violence, such as throttling, a vertical median fracture generally resulting, which may be accompanied by displacement inwards of the fragments, swelling of the mucous membrane, and consequent asphyxia. The operation of *thyrotomy*, or median vertical incision of the cartilage, including part of the thyro-hyoid and crico-thyroid membranes, is performed with the object of removing foreign bodies in the larynx, or tumours of the cord, etc. *Laryngotomy* is performed by making a vertical incision through the soft parts from the middle of the thyroid to the lower border of the cricoid, and then incising the crico-thyroid membrane transversely close to the cricoid, so as to avoid the small crico-thyroid vessels. This operation is sometimes performed where the patient is being choked by some foreign body lodged in the larynx. It does not afford much room, and is above the level at which the membrane is often formed in

diphtheria. The larynx has occasionally been *extirpated* successfully in cases of malignant disease (a preliminary low tracheotomy having been generally performed) through a vertical incision from the hyoid to the isthmus of the thyroid gland, and a transverse one at the upper extremity from one sterno-mastoid to the other. The flaps, consisting of skin, with platysma, deep fascia, and anterior jugular veins, are reflected, as are likewise the sterno- and omo-hyoid muscles. The sterno-thyroid, thyro-hyoid, stylo- and palato-pharyngei, and inferior constrictor muscles, and thyro-hyoid membrane are divided, and the larynx set free by separating the attachments of the epiglottis to the tongue and thyroid bone. The larynx is now drawn forward, the superior laryngeal arteries and internal laryngeal nerves divided, and a careful separation of larynx and pharynx is made, the connecting mucous membrane being divided. Then the inferior laryngeal arteries and recurrent laryngeal nerves are divided, and the trachea is cut across and closed, or opened into the lower end of the wound.

The **trachea** commences at the lower border of the cricoid opposite the sixth cervical vertebra, recedes from the surface as it descends, being $1\frac{1}{2}$ inches from it at the suprasternal notch, and ends opposite the lower border of the fourth dorsal by bifurcating into two bronchi. The length of the cervical portion varies with the position of the head, but averages nearly 3 inches (about the eighth ring—in a child, from $1\frac{1}{2}$ to 2 inches). It is covered *in front* by skin, superficial tissue, anterior jugular veins, deep fascia, sterno-hyoid and thyroid muscles, thyroid isthmus (in front of the second, third, and fourth rings), and below the isthmus by the thyroidea ima artery, the inferior thyroid venous plexus, and, at the level of the notch, by the innominate artery and the left innominate vein, and in children, and occasionally in adults, by the thymus gland. *Posteriorly*, the trachea is in contact with the œsophagus, the sulcus between them being occupied by the recurrent laryngeal nerves, while the *lateral surface* of the trachea is compressed slightly by the lateral lobes of the thyroid, and below this is in relation to the common carotid arteries. The tissues surrounding the trachea are very lax, permitting fairly free movement, both vertically (as in swallowing) and laterally. Thus, in performing tracheotomy, the trachea has been unwittingly retracted to one side by an assistant, and the

œsophagus exposed. TRACHEOTOMY may be necessitated in respiratory obstruction from tumours, foreign bodies, or diphtheria. It may be either high (above the thyroid isthmus) or low (below it). The former is generally easier and safer, owing to the more superficial position of that part and the smaller number of important structures in close relationship to it, but leaves a more prominent scar. The operation is performed by placing a small pillow behind the neck so as to throw it forward, keeping the head absolutely straight and steady, and then making a vertical incision exactly in the middle line. The skin and fasciæ are cut through, the muscles are separated, the thyroid isthmus displaced downwards, after making two slight lateral cuts in the laryngo-thyroid suspensory fascia, and then a sharp hook is inserted into the first ring of the trachea, and an opening made by cutting from below upwards away from the great vessels. A tube of suitable size is then taken (not exceeding $\frac{1}{6}$ inch in diameter under eighteen months, and $\frac{1}{4}$ inch in a child under four years of age), and introduced like a catheter, with the plate directed downwards toward the sternal notch and almost touching the skin, so as to present the nozzle vertically into the wound. Then, by tilting the plate upwards like the handle of a catheter, the point slides into position. Care is required not to introduce the point into the cellular tissue in front of the trachea. Where additional room is required, it may be had by cutting through the cricoid and crico-thyroid membrane, or by dividing the thyroid isthmus. The latter is not in itself a dangerous proceeding, but large transverse vessels are not infrequently found arising at the level of the isthmus. The operation is particularly difficult in children, owing to the short fat neck, the closer relationship to vessels, etc., and the softness and mobility of the trachea itself.

The THYROID GLAND lies in front of the trachea (under the sterno-hyoid and thyroid muscles and part of the sterno-mastoids), and is enclosed in a sheath of cervical fascia, which connects it to the lower part of the larynx and upper part of the trachea. Owing to this connection, the gland moves up and down with deglutition, as, of course, do most tumours of the gland. It consists of two *lateral lobes*, of which the right is generally the larger, and an isthmus. The borders are rounded on their outer surface, and broader below than above. They

are about 2 inches long, $1\frac{1}{4}$ inches broad, and $\frac{3}{4}$ inch thick. The apex rests against the upper and posterior part of the

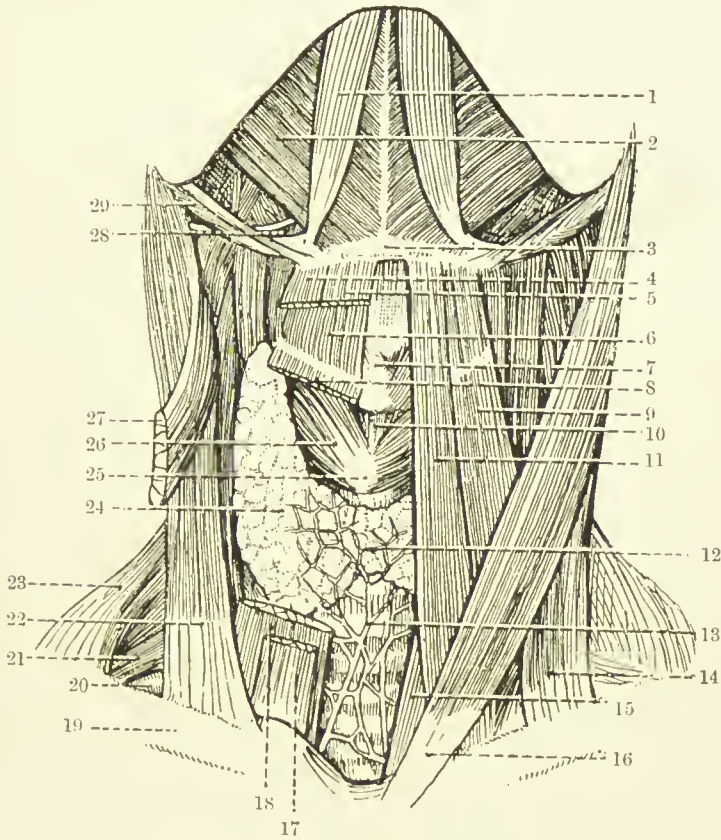


FIG. 14.—DISSECTION OF THE FRONT OF THE NECK.

(The area bounded on either side by the anterior belly of the digastric and below by the body of the hyoid bone is the submental triangle.)

(From Buchanan's "Anatomy.")

- | | |
|---|---|
| 1. Anterior belly of digastric. | 17. Sterno hyoid. |
| 2. Mylo-hyoid. | 18. Sterno-thyroid. |
| 3. Body of hyoid bone. | 19. Clavicle. |
| 4. Anterior belly of omohyoid. | 20. Subclavian artery (third part). |
| 5. Sterno-hyoid. | 21. Brachial plexus. |
| 6. Thyro-hyoid. | 22. Clavicular head of sterno-cleido-mastoid. |
| 7. Isthmus of thyroid cartilage. | 23. Trapezius. |
| 8. Sterno-thyroid. | 24. Lateral lobe of thyroid body. |
| 9. Anterior belly of omohyoid. | 25. Cricoid cartilage. |
| 10. Crico-thyroid membrane. | 26. Crico-thyroid muscle. |
| 11. Sterno-hyoid. | 27. Sternal head of sterno-cleido-mastoid. |
| 12. Isthmus of thyroid body. | 28. Hyo-glossus muscle and hypoglossal nerve. |
| 13. Inferior thyroid plexus of veins. | 29. Posterior belly of digastric and stylo-hyoid. |
| 14. Clavicular head of sterno-cleido-mastoid. | |
| 15. Sterno-thyroid. | |
| 16. Sternal head of sterno-cleido-mastoid. | |

thyroid cartilage, and receives the *superior thyroid vessels* (from the external carotid). The base is at the level of the sixth ring

of the trachea, and receives at its external border the *inferior thyroid vessels* from the thyroid axis. The blood is returned by *three veins*—superior, middle (to internal jugular), and inferior thyroid (to innominate). The inner surface is moulded against the trachea and œsophagus below, with the inferior laryngeal nerve between them, and the larynx and pharynx above. The external rounded border is deeply grooved posteriorly by the common carotid artery (which frequently transmits pulsation to enlargements of the gland), and is in relation to the inferior thyroid artery, sympathetic cord, and prevertebral muscles. The *isthmus* lies about the level of the third tracheal ring, and in the middle line is superficial. As the vascular system of the thyroid does not extend from side to side, the isthmus may safely be divided in the middle line. A communicating branch of the superior thyroid artery of either side, however, frequently crosses immediately above it, and should be avoided. The *thymus gland* in the child lies in close contact with its lower border, which also is related to the inferior thyroid veins. A small *pyramidal lobe*, arising from the upper border of the isthmus and part of a lateral lobe, sometimes projects upwards in front of the larynx, being attached at its apex to the hyoid bone by a ligamentous structure. The gland is *enervated* by branches of the cervical sympathetic, which probably communicate in the medulla with those supplying the eye, thus helping to explain the *exophthalmos* seen in some forms of goitre. The *lymphatics* run to the deep cervical and superior mediastinal glands. The gland is generally larger in females than in males, and may increase in size during menstruation. Pathological enlargements of the thyroid are generally called *goitres*, and these are of various types. They occur more commonly in females, and particularly on the right side. Such enlargements may compress and cause deviation of the trachea, thus giving rise to dyspnoea; the œsophagus, causing dysphagia; and the recurrent laryngeal nerve, causing paralysis of the intrinsic muscles of the larynx and consequent aphonia. The thyroid vessels enlarge, and are thin walled; the large vessels of the neck are displaced laterally, and the tumour may extend down beneath the sternum and clavicles. In cases of goitre a *thyroidectomy*, or partial excision of the gland, may be performed through a transverse

curved incision over the swelling, with the convexity downwards, which extends through the skin, platysma, and deep fascia, including the anterior jugular veins, outwards over the anterior border of the sterno-mastoid muscles. The lateral muscles and deep fasciæ are now shelled laterally from the capsule of the tumour, or divided, and the lateral mass is projected forwards, the upper cornu defined, and the vessels ligatured. Then the isthmus is divided in the middle line, the mass turned outwards, and the inferior vessels ligatured as far from the larynx as possible to avoid injury to the recurrent laryngeal nerve. If a local anæsthetic be used, it is a further safety to ask the patient to say 'ah' while ligaturing these vessels, as the ability to say this ensures that the nerve is acting. The other lobe may then be treated, taking care to leave in all cases a portion of gland to prevent occurrence of myxœdema.

Developmentally, the gland consists of three segments, the middle being represented by the isthmus and the pyramidal lobe when present, which latter communicates by the thyroglossal duct with the base of the tongue at the foramen cæcum. *Thyroid cysts* not infrequently arise in connection with the remains of this duct, and accessory lobules are sometimes also found in the hyoid region. The *parathyroid bodies* are two small round masses found on either side toward the lower border of the lateral lobes.

The **œsophagus** is about 10 inches in length, and commences opposite the sixth cervical vertebra, pierces the diaphragm opposite the tenth dorsal vertebra, and immediately afterwards terminates at the cardiac orifice of the stomach. The *cervical portion* varies in length, like the trachea, with the position of the head. In front of it lies the trachea, behind it (and deep fascia) the prevertebral muscles. While at its commencement it is mesial, it soon deviates to the left, where it is more closely related to the thyroid gland, common carotid artery, and recurrent laryngeal nerve, than on the right. On either side are numerous lymphatic glands, which drain this portion of the œsophagus, and are liable to enlarge in carcinomatous disease, and so cause pressure on the œsophagus. Its *lumen* is compressed antero-posteriorly. It is narrow at its commencement ($\frac{1}{2}$ inch), and hence impaction of foreign bodies and acid burns, causing subsequent *cica-*

tricial stenosis, occur most generally at this point, which is situated about 6 inches from the teeth, and is hence beyond the reach of the finger. In carcinomatous disease of this portion of the œsophagus the left recurrent laryngeal nerve is often pressed on, and when stricture of the tube results, a left-sided *œsophagotomy* may be done to relieve it (or to remove an impacted foreign body). An incision is made internal to the anterior margin of the sterno-mastoid from the thyroid cartilage to the sterno-clavicular articulation. The subcutaneous tissues, platysma, anterior jugular vein, and deep fascia, are divided, the sterno-mastoid retracted outwards, the sterno-hyoid and -thyroid retracted inwards, and the omo-hyoid and pretracheal fascia divided. The thyroid gland is now drawn forwards and inwards, the common carotid outwards, the inferior thyroid artery divided, the trachea, and the œsophagus dilated by a bougie, recognized, and a vertical incision made in the latter near its vertebral aspect, so as to avoid the recurrent laryngeal nerve. Where a portion is cut out the operation is known as *œsophagectomy*, and where an opening on to the neck is established, *œsophagostomy*. Save for the removal of a foreign body or very limited growth, a gastrostomy is a better operation as a rule.

The Carotid Region.—The COMMON CAROTID ARTERIES extend in the neck from the sterno-clavicular articulation to the upper border of the thyroid cartilage, a distance of about $3\frac{1}{2}$ inches. In the lower part of their course they are placed deeply, and about $\frac{3}{4}$ inch apart, while in the upper part they are superficial, and about 2 inches apart. On the right side the vessel arises as a terminal branch of the innominate, and is in front and to the right of the trachea; while on the left it is given off from the arch of the aorta, and is more deeply placed, being situated to the side of the œsophagus. The vessel is enclosed in the *carotid sheath*, which is triangular in section, and is derived from the deep cervical fascia. In the sheath and accompanying the artery lies the *internal jugular vein*, situated to the outside of the artery, and the *vagus nerve* behind and between the artery and vein. Within the sheath, and closely associated with the vein, a number of small *lymphatic glands* frequently exist, which are often enlarged in tubercular disease. Outside the sheath, on its anterior surface, the *descendens noni* nerve runs downwards

and inwards, and numerous *lymphatic glands* lie in this position, while posterior to the sheath the *cervical sympathetic* runs. Other posterior relations are the inferior thyroid and vertebral arteries, prevertebral fascia and muscles, the transverse processes of the cervical vertebræ, and, on the right side, the recurrent laryngeal nerve. On the left side the nerve is internal. Anteriorly, the sheath is crossed by the omohyoid muscle and a branch of the superior thyroid artery, at the level of the sixth cervical. The artery is generally *ligatured* above this point, as it is more superficial, being overlapped by the sterno-mastoid, while below this point it is covered by the sterno-hyoid, thyroid, and mastoid muscles, the lateral lobe of the thyroid, and thyroid veins. This point, therefore, is an important one surgically, and is defined deeply by the tubercle on the transverse process of the sixth cervical (*Chassaignac's tubercle*), which forms a reliable guide to the artery in ligaturing, and against which the artery may be compressed. The common carotid is sometimes affected by *aneurism*, which occurs generally at the bifurcation, where there is normally a dilatation, or at the root of the neck. The pressure exerted on the surrounding structures by the tumour may give rise to spasm of the larynx, and of the diaphragm, contracted pupil (sympathetic), œdema, and lividity of face and arm, and anæmia of the brain. Ligature of the common carotid may be performed for aneurism affecting the vessel itself, for aneurism of the innominate (Wardrop's operation), for wounds of the vessel, and profuse hæmorrhage from the neck or throat (sarcoma, etc.). Where possible the artery should be ligatured above the omohyoid (seat of election). The line of the artery is from the sterno-clavicular articulation to a point midway between the angle of the jaw and the mastoid process, and a 3-inch incision is made along this line, with its centre opposite the cricoid. The deep fascia is divided, the sterno-mastoid drawn back, the omohyoid drawn down, the sheath cleared, opened on its inner side, and the needle passed from without inwards to avoid the vein, the vagus also being avoided. The subsequent *anastomosis* is between the superior and inferior thyroid vessels, branches of the two external carotids, a branch of the occipital of the carotid, and the superior intercostal of the subclavian; but is frequently not sufficient, notwithstanding the circle of Willis, to keep

the brain sufficiently supplied with blood, syncope occurring at the time of the operation, or cerebral softening some days later.

The EXTERNAL CAROTID is the smaller terminal branch, and at its commencement is in front of, and to the inside of, the internal. It curves forwards as it ascends, and divides within the parotid recess of the lower jaw into the temporal and internal maxillary arteries. It is about $2\frac{1}{2}$ inches long; passes beneath the digastric and stylo-hyoid muscles; is separated from the internal carotid by the stylo-glossus and -pharyngeus muscles, stylo-hyoid ligament, and glosso-pharyngeal nerve and pharyngeal branch of the vagus. *Ligature* of the external is less serious than that of the common carotid, and may be performed as a preliminary to operations on parotid tumours. The artery is generally ligatured in its first part, which is below the digastric, and is about 1 inch long. An incision is made in the line of the artery from the angle of the jaw to the upper border of the thyroid cartilage through the skin, superficial and deep fascia, the latter being very strong at this level, and drawing the sterno-mastoid toward the angle of the jaw. The sterno-mastoid muscle and the parotid gland are now retracted, and the digastric tendon exposed. The hypoglossal nerve, giving off its descending branch, the laryngeal and facial veins, and one or two lymphatic glands, lie in front of the vessel; while the internal laryngeal nerve lies behind, and the submaxillary gland and great cornu of the hyoid internally, the latter forming a valuable guide to the vessel. The sheath is opened at the level of the hyoid cornu, and the needle passed from without inwards, the internal laryngeal nerve being avoided. The *circulation* is maintained by the branches from either side (facial, occipital, etc.); anastomosis between facial and branches of the ophthalmic (internal carotid), and between a branch of the superior intercostal and of the occipital.

The INTERNAL CAROTID is the larger branch, and extends within the cranium to the anterior clinoid process, where it divides into anterior and middle cerebrals. In the carotid triangle, where it might be ligatured, it is deeper and posterior to the external, and has the same relations to the internal jugular vein and vagus nerve as the common carotid. It is crossed by the occipital and posterior auricular arteries

and hypoglossal nerve, and is separated from the external carotid by the stylo-glossus and pharyngeus muscles, stylo-hyoid ligament, glosso-pharyngeal, and pharyngeal branch of the vagus nerves. The INTERNAL JUGULAR VEIN begins in the jugular fossa of the petrous as a bulb or dilatation at the junction of the lateral and inferior petrosal sinuses. At its exit from the skull it is separated from the internal carotid artery by the ninth, tenth, and eleventh nerves, and it joins the subclavian vein behind the sterno-clavicular articulation to form the innominate. The internal jugular vein is occasionally in danger of *wounding* in operations for extensive tubercular disease of the glands of the neck. During inspiration the vessel is collapsed, and looks like connective tissue, while during expiration it may become greatly distended. In such cases the danger from hæmorrhage is not so great as that from *air embolism*, air being sucked in through the wound in inspiration, and leading to embolism of the coronary arteries, etc. The connection of the vein with tubercular glands has already been referred to. It is frequently affected by *thrombosis* extending from the sigmoid, and becomes tender and palpable as a thickened cord in the neck. Where, as generally happens, the clot is septic, infection is very apt to be carried to the lungs, or sometimes to other parts of the body.

The **posterior triangle of the neck** is bounded in front by the posterior border of the sterno-mastoid, behind by the anterior border of the trapezius, and below by the clavicle, beneath which and between it and the first rib it communicates with the axilla. Superficially, branches of the cervical plexus, the external jugular vein, and some lymphatic glands are found. The *omo-hyoid* lies a little deeper, and divides the triangle into two, the lower or SUBCLAVIAN being bounded in front by the sterno-mastoid and—deeper—the scalenus anticus, below by the clavicle and subclavius, and above and behind by the omo-hyoid. The *pretracheal fascia*, which ensheaths the omo-hyoid, is continued down to the clavicle, to which, together with the sheath of the subclavius and of the subclavian vein, it is attached, and sometimes binds the omo-hyoid so closely to the clavicle as almost to obliterate the subclavian triangle. Under this fascia lies a chain of lymphatic glands, which communicate with the mediastinum;

axilla, and deep parts of the neck, and the suprascapular and transversalis colli arteries cross the triangle, the former behind the clavicle and the latter behind the omo-hyoid. This triangle is of importance, as the SUBCLAVIAN ARTERY in its third stage is *ligatured* in it for axillary aneurism, wounds, etc., by an incision made along the clavicle, the skin having previously been pulled down. The skin is then pulled up, and the incision deepened until the triangle is exposed. The anterior scalene is made out, the artery lying behind it and the vein in front of it, and the finger is run down its external border till it rests at its insertion on the *scalene tubercle* (tubercle of Lisfranc) of the first rib, which is the guide to the artery. The height of the artery above the clavicle varies greatly in different individuals, and in different positions, occasionally being so prominent as to suggest the presence of an aneurism. The best position for ligature is with the shoulder depressed and the arm thrown behind the back, while the head is turned to the opposite side. The needle is passed from above downwards and backwards, taking care not to confuse a cord of the brachial plexus or the omo-hyoid muscle for the artery—mistakes which are frequently made in operations on the cadaver. When the posterior scapular artery presents in the wound, it is better to ligature it also, lest secondary hæmorrhage occur. The *collateral circulation* is by suprascapular and posterior scapular, with acromio-thoracic, subscapular, and dorsalis scapulæ; and superior and aortic intercostals and internal maxillary, with long thoracic and scapular arteries. The PLEURA lies close to the subclavian artery, and, indeed, the apex of the lung extends some $\frac{1}{2}$ inch above the clavicle, behind the sterno-mastoid, particularly on the right side. Thus injury to the pleura may result from ligature of the artery, or removal of a tumour or adherent tubercular glands, while it also has been injured by stabs in the neck, severe fracture of the clavicle, etc. The lung may occasionally produce an appreciable swelling in the neck during severe coughing.

The portion of the posterior triangle which lies above the omo-hyoid is known as the OCCIPITAL TRIANGLE. It is bounded in front by the posterior border of the sterno-mastoid, behind by the anterior border of the trapezius, and below by the omo-hyoid. The floor is formed from above downwards by

the splenius capitis, levator anguli scapulæ, and scalenus medius and posticus. Superficially it is covered by the skin and fascia, with platysma in the lower portion, and presents superficial branches of the cervical plexus—namely, lesser occipital, great auricular, transverse cervical (all emerging from posterior border of sterno-mastoid), and supraclavicular branches (in lower part of the triangle). Lying deeply along the posterior border of the sterno-mastoid are the *glandulæ concatenatæ*.

The anterior portion of the neck is formed *embryonically* by the growing forward of five branchial arches, with clefts—or, in the human embryo, grooves—both external and internal (called 'recesses'), between them. The first arch forms the lower jaw and malleus. The second, or hyoid arch, which forms the incus, styloid process, and part of the hyoid, grows rapidly, and, as flexion of the neck occurs at this period, soon overlaps the other arches, which become buried, and ultimately lose their epiblast. A *cervical fistula* leading down to these arches persists for a time, however, and in some cases permanently, as a fine channel, with small opening a little above the sterno-clavicular articulation, which penetrates a varying distance. Various forms of *cysts*, also, with epithelial lining, may arise from the included epiblast of these buried arches, and are sometimes alluded to as *hygromas*, or *hydroceles of the neck*, and occur most frequently in the posterior triangle. The first *external* groove forms the external auditory meatus, the membrane between it and the internal groove forming the tympanic membrane. The *internal* grooves between the arches disappear early, with the exception of the first, which persist as the tympanic Eustachian passage. The second leaves traces in the fossa of Rosenmüller in the pharynx and the supratonsillar fossa, and the fourth in the pyriform fossa at the pharyngo-laryngeal junction. *Cervical ribs* occasionally occur, especially in connection with the seventh cervical vertebra—sometimes ankylosed to the transverse process, and sometimes movable; sometimes short and resembling an exostosis, at others long and well formed. In the latter case the subclavian artery passes over the rib, and so projects, simulating aneurism, and the scalene muscles may be attached to it. Even the smaller forms may, however, present a projection in the neck

if the subject be thin, and they sometimes give rise to trouble from pressure on the cords of the brachial plexus.

The neck communicates with the thorax anteriorly, many of the structures passing directly from the one to the other. On the right side the innominate vessels are comparatively superficial, and the vagus nerve passes down in front of the subclavian artery. On the left side the separate carotid and subclavian are much deeper, and the vagus passes down between them. The INNOMINATE artery is about $1\frac{1}{2}$ inches long, and extends up and outwards to the sterno-clavicular articulation, where it divides, being at first in front of the trachea, and then to its outer side. In front of the vessel are the left innominate and inferior thyroid veins. To its right side are the right innominate vein, vagus nerve, and pleura, while to its left are the left cornu of hyoid, carotid artery, and trachea. It is occasionally affected by *aneurism*, causing dyspnoea, cough from pressure on the recurrent laryngeal, difficulty in swallowing, etc. The condition is best treated by needling, but *ligature* has been done through an incision along the lower end of the anterior border of the sterno-mastoid, and then out along the inner one-third of the clavicle, cutting the sterno-mastoid, hyoid, and thyroid muscles, and the anterior jugular vein. *Collateral circulation* would take place by the superior with aortic intercostals; internal maxillary with deep epigastric and aortic intercostals; circle of Willis, etc. Between the sterno-mastoid and the scalenus anticus lie the phrenic nerve, omo-hyoid muscle, transversalis colli, and suprascapular arteries, external jugular, and subclavian veins. Behind the scalenus anticus, and between it and the other scalenes, pass the subclavian artery and cords of the brachial plexus. The SUBCLAVIAN ARTERY arises from the innominate on the right and the aorta on the left, and reaches the inner border of the scalenus anticus in its first stage, passes behind the muscle in its second, and in its third extends to the outer border of the first rib, beyond which point it is known as the axillary. The first stage, therefore, differs considerably on the two sides. On the left it is larger, deeper, and more vertical; the internal jugular vein and vagus nerve run parallel instead of crossing it at right angles; the recurrent laryngeal nerve lies to the inner side, instead of looping round the deep aspect; and the

oesophagus and thoracic duct only form relations on this side. In its first stage it gives off (1) the *vertebral artery*, which ascends between the scalenus anticus and longus colli to the foramen in the transverse process of the sixth cervical. It has been *ligatured* in some cases of epilepsy by an incision along the posterior border of the sterno-mastoid, just above the clavicle, the carotid tubercle of the transverse process of the sixth cervical forming a guide. This vessel is surrounded by vaso-motor nerves from the inferior cervical ganglion, and higher up is in close connection with the hypoglossal and suboccipital nerves. (2) The *internal mammary*, which originates at the inner border of the scalenus anticus, and passes down behind the first costal cartilage to the thorax, where it runs parallel to and $\frac{1}{2}$ inch from the sternal border. It may be wounded, and give rise to fatal hæmorrhage, and is most easily treated through the second intercostal space. (3) The *thyroid axis*, which arises opposite the internal mammary, and divides into inferior thyroid, suprascapular, and transversalis colli. (4) The *superior intercostal* arises from either first or second stage, passes upwards and backwards over the pleura, and then descends into the thorax in front of the neck of the first rib, and supplies the first two intercostal spaces. It anastomoses with a branch of the occipital. The subclavian is occasionally affected by *aneurism*, especially on the right side, in its third part, forming a pulsating tumour in the posterior triangle, and, as it increases, produces pressure symptoms, including spasm of the diaphragm from pressure on the phrenic nerve. When it is necessary to ligature the vessel, this should, where possible, be done in the third part, as already described. Ligature of the first part is difficult and dangerous.

THE VERTEBRAL COLUMN

The vertebral column supports the head, connects the upper and lower segments of the trunk, gives attachment to the ribs, is extremely flexible, and contains and protects the spinal cord.

The spinous processes projecting behind, and the transverse processes projecting laterally, form two deep vertical grooves, which lodge the powerful muscles which support and control the movements of the column. In the adult the column presents *four curves*—two primary, thoracic and sacral, which are also present in the foetus, are due to the shape of the bones, and whose concavity is directed forwards; and two secondary, cervical and lumbar, which are acquired after the assumption of the erect posture, are due to the shape of the intervertebral discs, and whose convexity is directed forwards. In infancy, prior to the formation of the secondary curves, the spine generally presents a slight general backward convexity, which in rickety children may proceed to form a pronounced *KYPHOSIS*. In old persons, in whom the discs have atrophied, the spine frequently assumes a slight general backward convexity; and in cases of rheumatoid arthritis affecting the spine the various joints may become fused, producing a rigid spine, which is frequently fixed in a kyphotic curve. As the spines of the vertebræ vary in length, a line joining them would not repeat the curves of the column. The junction of the fifth lumbar vertebra with the sacrum forms a marked projection—the *sacro-vertebral angle*—which is frequently felt in abdominal palpation. Sometimes the lumbar vertebræ slip forward from the sacrum at this point, owing to defective development of the last lumbar vertebra, producing *spondylolisthesis*. Even normally a slight lateral curve of the spine in the dorsal region, with the convexity toward the right, and compensatory curves above and below with the convexity to the left, may be present. This lateral curve has been attributed to the greater use of the right arm, and to the pressure of the thoracic aorta on the dorsal vertebræ.

SCOLIOSIS consists of an exaggeration of this lateral curve, the convexity of the curve being generally to the right, while the vertebræ rotate, so that their bodies are directed to the convexity of the curve. The ribs move with the vertebræ, and thus the angles of the ribs on the side of the convexity are prominent, and make the angle of the scapula project, while on the concave side they are depressed. Correspondingly, the front of the chest on the side of the convexity is flattened, while it is prominent on the concave side. The ribs are also

separated from one another on the convex side, and hence the shoulder is raised, while they are crowded together on the concave side, the shoulder being depressed. The condition is due to loss of tone of the muscles (erector spinæ attached to the transverse processes and ribs, and the multifidus spinæ, etc., to the spinous processes) and ligaments, and is frequently associated with flat-foot, which is due to a similar condition, and is frequently an exciting cause.

The VERTEBRAL DISCS, twenty-three in number, make up nearly one-quarter of the length of the spine, act as buffers and springs, form the cervical and lumbar curves, and assist in the formation of the intercentral articulations. These are amphiarthrodial joints, and while the movement permitted in each individually is slight, the spine as a whole is capable of very considerable movement, particularly in the cervical and lumbar regions, where not only antero-posterior but lateral and rotatory movements are possible.

LORDOSIS, or an exaggeration of the normal lumbar curve, with the convexity forwards, is frequently seen in hip disease, where all the movement permitted in the limb may be derived from the lumbar spine, and not from the hip-joint.

The BODIES of the vertebræ are the most frequent site of tubercle of bone. Generally two contiguous bodies are affected, the pus escaping anteriorly between the ligaments to form a psoas or other abscess (according to the position—retro-pharyngeal in the cervical region, psoas in the dorsal or upper lumbar), and the bodies collapsing, forming an *angular* projection or 'curvature' of the spine, known as POTT'S DISEASE. The bodies of the vertebræ are also markedly eroded by the pressure of thoracic aneurism, whereas the intervertebral discs are comparatively resistant to such pressure.

SPRAINS of the column are generally produced by indirect violence, and occur most frequently in the cervical and lumbar regions, owing to the mobility of these parts, and their proximity to the head and pelvis respectively. Sprained back frequently causes pain and inconvenience to a patient for a considerable time after an injury, owing, perhaps, in some cases to implication of some of the spinal joints, and in others to damage to the muscles. The condition may be simulated in rheumatic affections of the muscles—lumbago—

and is one which causes considerable difficulty in medico-legal work. Sprains are seldom associated with much destruction of the parts, a fracture dislocation generally occurring in such cases.

Most of the severe damages met with in the vertebral column from injury are of the nature of FRACTURE DISLOCATIONS, the contained cord adding greatly to the gravity of the condition. The cord, however, occupies a neutral position between the bodies and the spines, and thus frequently escapes, unless an actual displacement of one or more vertebræ occurs. While fracture can occur without dislocation, dislocation very rarely occurs without fracture, except in the case of the first, second, and fifth cervical vertebræ, and of the lumbo-sacral articulation.

Fracture dislocations may be caused by either *direct* or *indirect violence*. The latter are by far the more common, and are generally due to violent forced flexion of the spine, the injury occurring about the junction of a flexible and a rigid portion of the column, as at the cervico-dorsal (frequently between the fifth and seventh cervical) from falls on the head, or dorso-lumbar from weights falling on the shoulders. Owing to the forward flexion, the broad vertebral bodies tend to be crushed together, and the narrow tough laminae and spines, with their strong ligaments, tend to be torn apart, while the cord lies in comparative security between these two forces. As a rule, the upper body is displaced down and forwards, complete dislocation being prevented by locking of the posterior processes. The affected vertebral bodies are partially crushed, and the intervertebral discs lacerated, as likewise the anterior and posterior common ligaments in more severe cases. The laminae, or spines, are broken, and the supra- and interspinous and capsular ligaments and ligamenta subflava torn. The articular processes are generally broken in the dorsal region, but escape in the cervical and lumbar regions. Replacement by forcible extension and manipulation is frequently successful, although perhaps most difficult in the lumbar region.

Direct violence may produce an injury at any part of the spine, the mechanism of the indirect form being reversed. A blow on the back tends to crush the posterior segment, and to tear the bodies in front apart; much displacement is un-

common, and the cord, therefore, more frequently escapes. The occipital bone has been dislocated from the atlas, and more commonly, as in hanging, the atlas has been dislocated forwards from the axis, the odontoid process being broken. The *spinous processes* of the lower cervical and dorsal regions may be broken off by direct violence. Where injuries to the column cause pressure upon the spine, it may be necessary to perform a laminectomy for its relief (*q.v.*).

THE CORD

In the adult the cord is generally about 18 inches long, extending from the foramen magnum to the lower border of the body of the first lumbar vertebra. It sometimes ends about the depth of a vertebral body above or below this point, and in flexion it is raised about $\frac{2}{5}$ inch. At the foramen magnum it becomes continuous with the medulla, while below it tapers to a point—the *conus medullaris*—from which the *filum terminale*, composed of pia mater, containing in its upper half nerve elements and continuation of central canal of the cord, is prolonged to the back of the coccyx, running down amidst the cords of the upper sacral nerves, to which the term *cauda equina* is applied. The spinal meninges extend to the second piece of the sacrum, and thence form a closed cover for the filum terminale. The third sacral spine, therefore, marks the lowest level to which cerebro-spinal fluid may descend in the spinal canal. In early foetal life the cord occupies the whole canal, and at birth it reaches the third lumbar vertebra. The *cervical enlargement* is most prominent opposite the sixth cervical, and the *dorsal enlargement* opposite the twelfth dorsal. The former measures about $\frac{1}{2}$ inch from side to side, and the latter slightly less. The space between the spinal dura and the bone is occupied by loose areolar tissue, containing a VENOUS PLEXUS. These veins communicate through the ligamenta subflava with the dorsal spinal veins, which receive blood from the integument and muscles of the back, and thus a thrombosis, or even meningitis, may spread inwards from deep external septic processes. Extensive hæmorrhage may result from injury involving these veins, the blood gravitating toward the lower end of the canal, and occasionally causing pressure.

The DURA, continuous with that of the medulla, is strong and tough, and but loosely attached to the bone. The ARACHNOID is closely attached to the dura, the *subdural space* being practically only potential, while the *subarachnoid space* is extensive and continuous with that of the brain, whence inflammatory conditions (meningitis) and effusions of blood

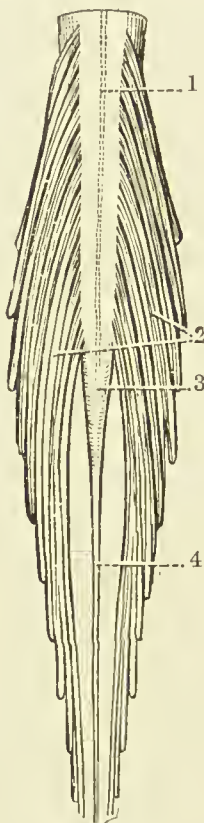


FIG. 15.—THE TERMINAL PART OF THE SPINAL CORD, AND THE CAUDA EQUINA.

(From Buchanan's "Anatomy.")

1. Linea splendens.
2. Cauda equina.

3. Conus medullaris.
4. Filum terminale.

may readily extend. Great increase in pressure may arise in meningitis, and may be relieved by LUMBAR PUNCTURE, the same procedure being adopted for obtaining specimens of cerebro-spinal fluid for investigation in certain diseases, while spinal anæsthesia is produced by injecting local anæsthetics into the spine by a similar puncture. The needle is introduced a little to the side of the spinous processes, on a level

with the iliac crests, up and inwards between two of the processes (third to fifth lumbar), the ligamenta subflava between two laminae being perforated, until the subarachnoid space is reached, the patient meanwhile bending forward. The needle enters the membranes below the termination of the cord, which is thus safe from injury. Normally the cerebro-spinal fluid contains 0.05 per cent. of albumin, and is under slight pressure. If the pressure be much reduced, convulsions may follow, as is seen in some cases of spina bifida, with extensive leakage of fluid.

The PIA MATER closely envelopes the cord and in it ramify the VESSELS supplying the cord, which are derived from the vertebral, intercostal, lumbar, ilio-lumbar, and lateral sacral arteries. Both dura and pia send prolongations along the nerve cords leaving the spine, which in the case of the larger plexuses extend a considerable distance.

SPINA BIFIDA is a congenital malformation of the cord or its membranes, associated, as a rule, with defect in the union of the laminae of one or more vertebrae. The most common form is said to be the *myelocoele*, in which the central canal of the cord opens on to a shallow depression on the skin surface. As the cerebro-spinal fluid escapes freely from the aperture, death generally occurs early. The central canal of the cord may dilate and form a protrusion of cord and membranes, known as a *syringo-myelocoele*. *Meningo-myelocoele* is the most common form which survives, and consists of a protrusion of membranes and cord, the latter lying as a flattened band on the posterior wall of the cyst. Where the membranes alone are protruded the condition is known as *meningocoele*, and where there is a defect in the vertebral arches, but no protrusion of membranes or cord, the condition is known as *spina bifida occulta*. Spina bifida generally affects the lumbar region, but may occasionally occur in the cervical, and very rarely in the dorsal.

The cord lies free within its sheath, suspended in its position by the various nerve roots which it gives off, and surrounded by the arachnoid water-bed.

CONCUSSION OF THE CORD may arise from severe shaking, giving rise to molecular changes in the cord substance, which may result, generally after some time has elapsed, in serious consequences.

WOUNDS of the cord, without accompanying fracture of the column, are uncommon, save between the occiput, atlas, and axis, unless the wound be made to correspond with the inclination of the spines and laminae, as in lumbar puncture.

CRUSHING OF THE CORD is generally associated with a lesion of the column, which may either be due to trauma or to disease. In the case of *trauma*, fracture dislocation is the most common cause, the lesion generally affecting the upper portion of the cord. Thus in the atlo-axoid region death frequently results, as in *hanging*, while severe injury to the cord often accompanies damage to the cervico-dorsal region, owing to the mobility of the spine and small size of the bodies permitting of considerable displacement. In the lower dorsal region displacement is less likely to occur, but is generally pronounced when it does occur, while the cord only extends to the upper extremity of the lumbar region, where displacement is easily caused by very severe injury. In traumatic cases the lesion is produced suddenly, and, the cord having no time to adapt itself to the pressure, a small lesion is likely to produce graver results than in chronic cases. *Chronic conditions* may be due to Pott's disease, with marked angular deformity; less often to extreme scoliosis, rheumatoid arthritis, etc.; while tumours growing in connection with the membranes similarly may cause pressure on the cord. It is often of importance surgically to be able to DIAGNOSE THE SITE OF A LESION from the symptoms, where the external evidence of injury does not afford a sufficient guide. In this connection it is necessary to remember that the nerve trunks generally arise from the cord some distance above the POINT OF EMERGENCE from the canal. Thus, while the first and second cervical run almost horizontally outwards, the other nerves gradually pursue more oblique courses, until the lowest trunks run almost vertically downwards. The first seven cervical nerves emerge above their corresponding vertebrae, while the eighth emerges between the seventh cervical and first dorsal vertebrae. The dorsal, lumbar, and sacral nerves all emerge below their respective vertebrae. The points of origin of the various nerves are given in Fig. 16 (*q.v.*). As each nerve runs down within the canal from its point of origin to its exit, a nerve belonging to a higher segment may be damaged by an injury at a lower level, thus producing

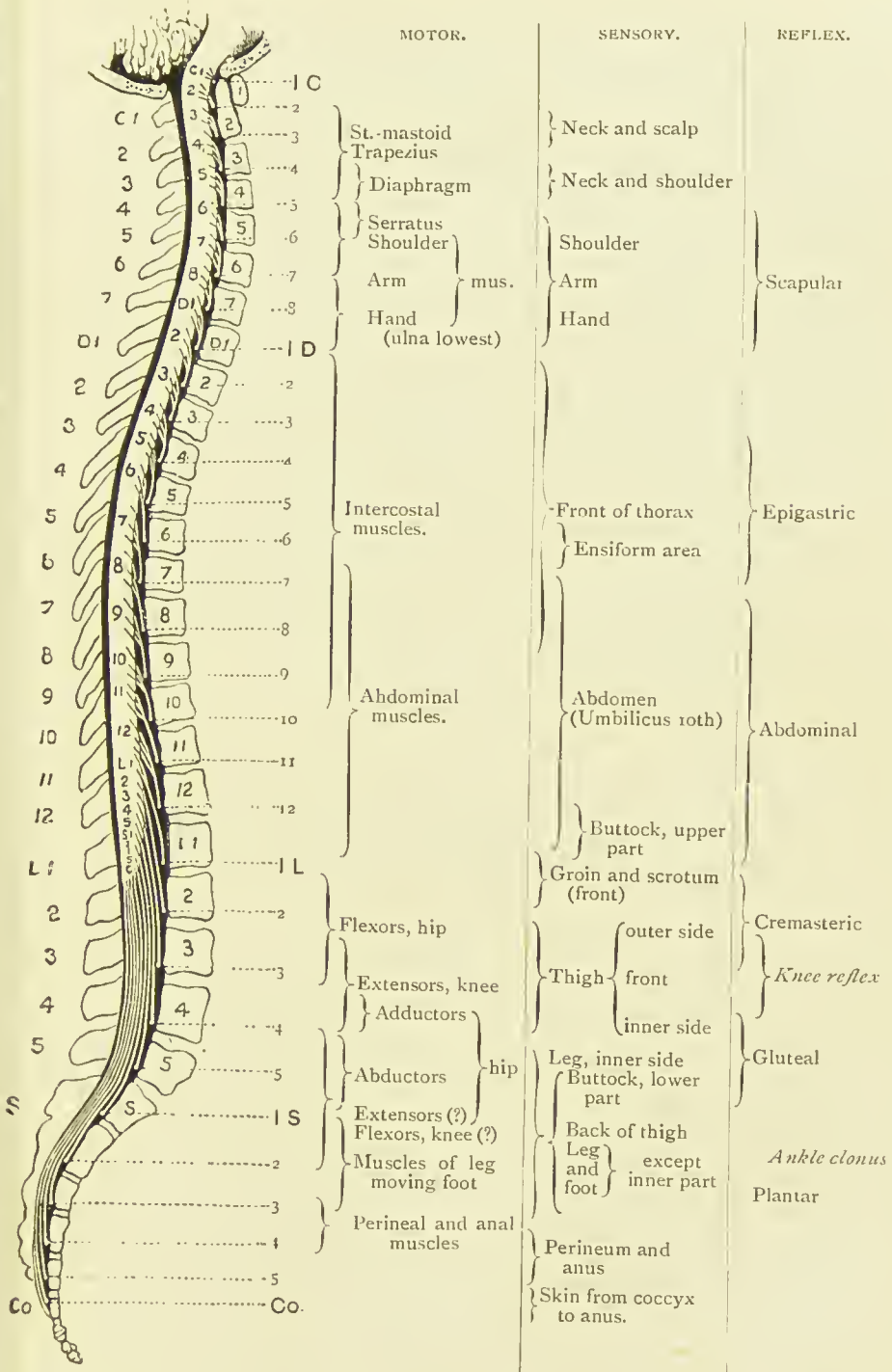


FIG. 16.—THE APPROXIMATE RELATION TO THE SPINAL NERVES OF THE VARIOUS MOTOR, SENSORY, AND REFLEX FUNCTIONS OF THE SPINAL CORD. (From Gowers' "Nervous System.")

what might at first appear to be a mixed lesion ; while sometimes the cord may escape, and the nerves alone be damaged. In fracture dislocations due to indirect violence the motor columns generally suffer more than the sensory, and may alone be affected. *Loss of reflex action* in the part of the body supplied by the damaged segment generally points to destruction of the grey matter at that point, with loss of the reflex arc. From want of proper control, also, the reflexes below the point of lesion are generally exaggerated. The effects of lesions at various levels are given in tabular form :

CERVICAL 1 TO 3 :

Often instant death.
Complete paralysis below head.
Asphyxia.

CERVICAL 3 TO DORSAL 2 :

Motor and sensory paralysis, including arms if above second dorsal.
Diaphragmatic breathing if below fourth or fifth cervical (*a*).
Slow pulse (*b*).
Contracted pupils.
Vomiting and persistent hiccough (*b*).
Incontinence of urine and fæces (*c*).
Priapism.

DORSAL 2 TO 10 :

Motor and sensory paralysis of abdomen and lower limbs.
Diaphragm assisted by intercostals below sixth dorsal.
Incontinence of urine and fæces (*c*).
Priapism.

DORSAL 11 AND 12 AND LUMBAR :

Incomplete paraplegia and anæsthesia, with zone of hyperæsthesia.
Bladder distended at first, with subsequent control (*c*).

(*a*) Phrenic nerve arises from third, fourth, and fifth cervical, but especially fourth.

(*b*) Effects upon vagus via spinal accessory, which is given off about sixth or seventh cervical.

(*c*) The vesical and rectal centres are situated in the lumbar enlargement. Normally, when these viscera become distended, a sensory impulse is conveyed to the centres in the lumbar enlargement. These centres, however, are controlled from the brain, and hence cannot act without volition on the part of the patient. Where the cord is damaged above the centre, the inhibitory fibres from the brain cannot control the centre, which then (after the first shock of the accident, producing retention, has passed off) acts automatically without any volitional control, emptying these viscera when distended. If the centres or the nerves between them and the bladder and rectum be damaged, then there is complete loss of control, with incontinence of urine and fæces.

When the cord is crushed by injury or disease, it may be necessary to perform a *laminectomy* for the relief of the condition. A median incision is made over the affected spines, the muscles shelled on either side, the laminae of several vertebrae divided, and an osteo-ligamentous flap lifted up, after cutting the supra- and interspinous ligaments and ligamenta subflava between the flap and the part to be lifted (Macewen). The parts are then inspected, the cord being cautiously turned to either side for inspection of the underlying structures, and then the bony projection or tumour removed. The operation is not likely to be successful, unless the spinal pulsation is fairly restored. It is undesirable to open the membranes, unless the lesion be situated within them. In this manner pressure from dislocations, angular curvature, tumours, etc., may be removed, and in some cases the primary focus in Pott's disease may thus be successfully eradicated. Hæmorrhage is not excessive, and is quite controllable.

SECTION II

THORAX

THE THORAX

THE SKIN of the chest is freely movable on the underlying structures, owing to the lax nature of the subcutaneous tissues, which are particularly abundant over the posterior and lateral regions. While the skin over the front and sides of the chest is thin and fine, that over the shoulders is thick (nearly $\frac{1}{4}$ inch) and coarse, and contains many sebaceous glands, *acne* frequently occurring in this region. The shoulders are also a favourite site for *lipomas*, which frequently develop in the subcutaneous tissues. As a rule, the two sides of the thorax are not symmetrical, the right being the larger. In the female the general capacity is less, and the sternum is shorter than in the male. In a transverse section of the chest the vertebræ are seen to project far forward toward the sternum, the shape resembling the Greek omega. The *sternal notch* corresponds with the disc between the second and third dorsal vertebræ, and at this point there is a space of only slightly over 2 inches between the sternum and vertebræ.

The chest overlaps the neck in front and the abdomen below. In the neck the apex of the lung rises about $\frac{1}{2}$ inch above the clavicle, while, owing to the dome-like obliquity of the diaphragm, which is attached to the xiphoid in front, and the cruræ and lumbar vertebræ behind, there is a region common to both thorax and abdomen, which is thoracic posteriorly, and abdominal anteriorly.

DEFORMITIES of the chest are seen in association with various diseases. Thus, in *emphysema* it is described as being barrel-

shaped. In *pigeon-breast* the sternum and cartilages are prominent, while a sulcus exists along the costo-chondral line, due, it is supposed, to yielding of this, the weakest part, where there is some impediment to respiration. Deformities of the spine often have a marked effect upon the thorax. In *Pott's disease*, with angular curvature of the spine, the sternum may project forwards, increasing the antero-posterior diameter, and the ribs may be crowded together, so as even in very severe cases to overlap the iliac crests. In *scoliosis*, or lateral curvature of the spine, in which the vertebræ rotate so that their bodies point to the convexity of the curve, the ribs, being firmly attached to the vertebræ by the costo-vertebral and transverse ligaments, move with them, rendering the angles very prominent and the front of the chest flattened on the convex side, while on the concave side the angles are flat and the front of the chest prominent. Further, on the convex side the ribs are wide apart, while they are crowded together on the concave.

The Sternum.—Behind the MANUBRIUM there is little or no lung, the space being occupied chiefly by the vessels, etc. The left innominate vein is most superficial, and lies just below the upper border of the manubrium. Then come the main branches of the aortic arch, then the trachea bifurcating at the manubrio-gladiolar junction, and, most deeply, the œsophagus. The highest portion of the aortic arch is about 1 inch below the upper border of the manubrium, and the course of the innominate artery is indicated by a line from the right sterno-clavicular articulation to the middle of the manubrio-gladiolar junction.

The junction of the manubrium and gladiolus sterni is marked by a transverse ridge, which can nearly always be felt, and which indicates the level of the cartilage of the second rib, the bifurcation of the trachea, and the disc between the fourth and fifth dorsal vertebræ. The two bones generally lie at an angle to one another, which is supposed to be particularly marked in pulmonary affections, and which is referred to as the ANGULUS STERNALIS. They do not become firmly united until middle life, and *dislocation* occasionally occurs, the gladiolus and ribs being displaced forwards. *Fracture* of the sternum is uncommon, is generally transverse, and due to violent flexion forwards or backwards. It also occurs

generally about the manubrio-gladiolar junction, and owing to the thick periosteal covering of the bone, displacement is generally slight. The bone has occasionally been *penetrated* by stabbing, and has been *trepined* with the object of reaching the mediastinum and pericardium, a similar operation having been suggested for ligature of the innominate.

As most segments of the gladiolus are developed from two lateral centres of ossification, want of union between these sometimes occurs, giving rise to wide *median fissures* of the bone, leaving the heart uncovered by bone, the condition occasionally being associated with *ectopia cordis*. In less severe cases an aperture may be met with in the gladiolus, through which deep suppurative processes may pass to the surface, or superficial infections may gain access to deeper parts. Deep *indentations* also are met with in the sternum, resulting from regular pressure applied to it in certain trades, as joiners and bootmakers.

The Ribs.—The anterior extremities of the ribs are generally on a much lower level than their posterior. Thus, the anterior end of the first rib is on a level with the head of the fourth, the second with the sixth, the third with the seventh, and the seventh with the eleventh. The first rib is the shortest, the seventh the longest, and the ninth the most oblique. In *counting* the ribs it is useful to remember that the manubrio-gladiolar junction denotes the position of the second costal cartilage. The *malc nipple* is generally situated between the fourth and fifth ribs. When the arm is raised, the first visible digitation of the serratus magnus corresponds to the sixth rib. The scapula covers the second to the seventh rib inclusive, and when the arm is at rest and applied to the side, its angle reaches the level of the eighth rib. The twelfth rib is occasionally absent, and, on the other hand, *accessory ribs* may be present. These generally occur in the lumbar or cervical region. The latter are generally met with in connection with the seventh cervical vertebræ, and sometimes give rise to trouble from irritation of the cords of the brachial plexus, necessitating their removal.

The ribs are very elastic, and this quality is increased in young persons by the elastic costal cartilages, and hence they frequently escape fracture, even when the violence is sufficient to damage the underlying organs. As a rule, *fractures* of

ribs occur in older persons. Where fracture is caused by direct violence, the pleura is apt to be injured by driving in of the fragments; whereas in fracture from indirect violence, where the fracture frequently occurs between the angle and the centre of the bone, the fragments tend to be driven out, and the pleura generally escapes. In addition to the pleuræ, the lungs, heart, and even the liver and spleen may be damaged in severe cases of fracture. The ribs most frequently fractured are the sixth, seventh, and eighth, while the first is very rarely fractured, and the second and third, and also the fourth, eleventh, and twelfth generally escape.

As a rule, the fracture is not attended with displacement, save in severe injuries, where several ribs have been damaged, and possibly driven in. Ribs have been occasionally fractured by muscular violence, as in sneezing and coughing, but probably in such cases have been affected by disease—as, for example, *tubercle*—which very frequently affects the ribs (insane rib), giving rise to superficial *cold abscesses*, which, owing to the laxness of the subcutaneous tissues, may attain a considerable size.

The *rickety rosary* is a bilateral enlargement of the ribs at the costo-chondral junction, due to rickets.

The COSTAL CARTILAGES increase in length up to the seventh or eighth, and then again decrease, and the lower cartilages run obliquely upwards from the ribs to the sternum. The cartilages are occasionally *fractured* in older persons by direct violence, producing a sharp transverse fracture, which generally heals by tissue containing osseous matter.

The INTERCOSTAL SPACES are wider in front than behind, and increase in breadth from above downwards. The widest space is the third, then the second and first. They are increased on inspiration, by emphysema, pleural effusions, etc. When collapse of the lung has occurred, on the other hand, the ribs become flattened and crowded together, while the diaphragm ascends.

Paracentesis (tapping of the chest), or *thoracotomy* (incision into the chest through an intercostal space), is generally performed in the sixth or seventh space and in the midaxillary line, the instrument being entered during inspiration as close to the upper border of the lower rib as possible, so as to avoid the intercostal vessels. Tapping should not be

performed behind the angles of the ribs, owing to the thick layer of muscles, and owing to the oblique course of the intercostal artery, nor should it be performed through the lower spaces, owing to the danger of wounding the diaphragm. When done in the eighth or ninth space, the puncture should be made just in front of the line of the angle of the scapula. Where more space is required, a portion of one or more ribs may be excised subperiosteally, so as to avoid damage to the vessels.

The intercostal spaces are occupied by the INTERCOSTAL MUSCLES, which consist of an external and internal layer. The fibres of the external set, like those of the external oblique of the abdomen, run downwards and forwards, and extend from the tubercles of the ribs posteriorly to the costo-chondral junctions anteriorly, beyond which a *membranous layer* extends forwards to the sternum. The fibres of the internal layer, like those of the internal oblique, run at right angles to those of the external, and extend from the sternum to the angles of the ribs, beyond which a membranous layer extends backwards to the vertebræ. *Pus* arising from disease of the vertebræ, or adjoining portions of ribs, may be conducted along between these muscular layers, and thus present anteriorly. A thin layer of connective tissue (the *endothoracic fascia*) exists between the ribs and intercostal muscles and the parietal pleura.

The INTERCOSTAL ARTERIES are given off from the aorta, with the exception of the first two, which arise from the superior intercostal of the subclavian. The arteries of the right side cross the front of the vertebral column behind the œsophagus, thoracic duct, and vena azygos major. Each runs out and backwards on the side of the vertebral body to the intercostal space behind the pleura and sympathetic cord, and then ascends to the lower border of the rib forming the upper boundary of the space, whence it runs forward in the subcostal groove, at first between the pleura and the posterior intercostal membrane, and then, having pierced the membrane, between it and the external intercostal muscle, and, farther out, between the two muscles. In the groove the artery is accompanied by the *vein*, which lies above it, and the *nerve*, which lies below it. At the anterior end of the space it anastomoses with the intercostal branches of the internal

mammary. The third, fourth, and fifth intercostal arteries give off *mammary branches*, which supply the breast, and become enlarged during lactation.

The INTERNAL MAMMARY ARTERY arises from the subclavian artery at the inner border of the scalenus anticus, and runs downwards, inwards, and forwards, the phrenic nerve crossing it in front, to the under surface of the first costal cartilage, and then runs downwards about $\frac{1}{2}$ inch beyond the border of the sternum, in front of the pleura and triangularis sterni muscle. It anastomoses with the intercostal arteries, and with the artery of the other side, and sends off perforating branches to the pectoralis major and mammary gland, that in the second space being generally the largest, and ends in the musculophrenic artery, which supplies the diaphragm, and the superior epigastric, which anastomoses with the deep epigastric. These *anastomoses* are of importance, as they come into play after ligature of the subclavian or axillary, and common or external iliac vessels. The internal mammary is most easily *ligatured* through the second intercostal space.

The anterior mediastinal LYMPHATIC GLANDS, generally two in number for each intercostal space, lie round the artery. They receive lymph from the diaphragm, anterior portions of the intercostal spaces, and inner portion of the mammary gland. This latter communication should be remembered in cases of extensive tubercular or carcinomatous *affections of the breast*, and the possibility of involvement of these glands considered. While the five upper INTERCOSTAL NERVES supply the chest-wall and integument (the intercosto-humeral of the second supplying the skin on the inner and posterior aspects of the upper two-thirds of the arm), the lower six extend to the abdomen, supplying skin, muscles, and parietal peritoneum. *Painful affections* of these latter nerves, therefore, frequently give rise to abdominal tenderness and rigidity, which may be mistakenly regarded as arising from peritonitis, and somewhat similar symptoms are not infrequently manifested in the early stages of spinal caries, the patient referring the pain to the region of the umbilicus. A painful affection of the upper intercostal nerves is termed 'intercostal neuralgia,' and may be followed by herpes along the course of the nerve (herpes zoster, or shingles). The *triangularis sterni* muscle rises from the deep surface of the lower portion of the sternum,

xiphoid, and fifth, sixth, and seventh costal cartilages, and is inserted into the deep surfaces of the second to fifth costal cartilages.

The **MAMMARY GLAND** is of epiblastic origin, and retains its rudimentary condition of a number of branching ducts with little glandular tissue until puberty, when the gland tissue rapidly increases. A further marked increase of gland at the expense of fibrous tissue takes place during pregnancy. Between pregnancies, and after the menopause, the gland tissue decreases in bulk, fatty tissue taking its place. In the male the gland maintains a rudimentary condition, as a rule. The gland consists of some FIFTEEN LOBULES, which are surrounded and separated from one another by vascular septa of fibrous tissue, which bind them together, forming a *capsule*, and also form many fine connections with the deeper portions of the skin (*suspensory ligaments of Cooper*), with the periglandular connective tissue, and a very loose connection with the subjacent pectoral fascia. A *bursa* occasionally exists between the gland and the *pectoral fascia*, and in the loose connective tissue a *submammary abscess* sometimes develops. The main portion of the gland is pyramidal, its base lying on the fascia of the pectoralis major from the second to the sixth rib. A considerable portion of the gland overlaps the pectoralis major externally, and rests on the serratus magnus within the axilla, extending upwards frequently to the upper border of the third rib, while internally and below it overlaps the rectus abdominis and external oblique. *Isolated portions* of the gland tissue may be found penetrating or even under the pectoral fascia in contact with the fibres of the pectoralis muscle. The NIPPLE is normally situated in the fourth intercostal space, $\frac{3}{4}$ inch from the costo-chondral junction, at the summit of the breast; but as the chest-wall rises more than the breast on inspiration, the nipple is then opposite the fifth space. In nulliparæ it frequently projects but slightly, but may be elongated in multiparæ, projecting forwards and outwards. It contains erectile and unstriped muscular tissue, and is covered by thin skin, on which the orifices of the fifteen milk, or lactiferous, ducts present. Within the nipple each duct presents an *ampulla*, or dilatation, and on leaving the nipple the ducts radiate outward to the various lobes. Hence in *incising* a breast it is important to make the incision

radiate from the nipple, so as to avoid division of these ducts. The AREOLA is circular in outline, measures from 1 to $1\frac{1}{2}$ inches in diameter, and is covered by thin skin, which may be pink in colour or pigmented, and becomes darker during pregnancy. A number of subcutaneous sebaceous glands (*of Montgomery*) frequently give a fine nodular appearance to the areola.

The SKIN of the breast is normally thin, smooth, and freely movable, the subjacent veins being frequently visible through it, especially during lactation. The BLOOD-SUPPLY of the breast is from (1) the external mammary branches of the long thoracic of the axillary; (2) anterior perforating branches of the internal mammary through the second, third, and fourth spaces; and (3) the lateral branches of the second, third, and fourth intercostal arteries. The veins join the internal mammary and axillary, while some small ones join tributaries of the external jugular.

The **lymphatic supply** of the breast is of the greatest importance surgically, as it is along this system that *carcinoma* spreads from the breast to invade the general system. Fine lymphatics surround the acini and ducts, and communicate with larger channels in the interlobular connective tissue, which in turn communicate with those in the subcutaneous tissues (by running along the suspensory ligaments), and submammary tissues, and those which penetrate the pectoral fascia. The efferent vessels pass from the margin of the gland to the pectoral group of the *axillary lymphatics* situated along the anterior border of the axilla, and the central superficial group, and thence to the deep glands grouped round the axillary vein, some lymphatics passing to this deep group direct. A few lymphatics lead to the *infraclavicular glands*, which lie around the termination of the cephalic vein between the pectoralis major and deltoid, and from thence beneath the clavicle to the lower *deep cervical glands*, which are grouped round the lower portion of the internal jugular vein. Lymphatics from the deep axillary group probably also reach this deep cervical group, and from thence the lymph on the right side is poured into the *right lymphatic duct*, and on the left into the *thoracic duct*. Lymphatics also pass from the inner side of the breast to the *anterior mediastinal glands* in the first four intercostal spaces, which are grouped round the internal mammary artery. Thus it will be seen that, in a

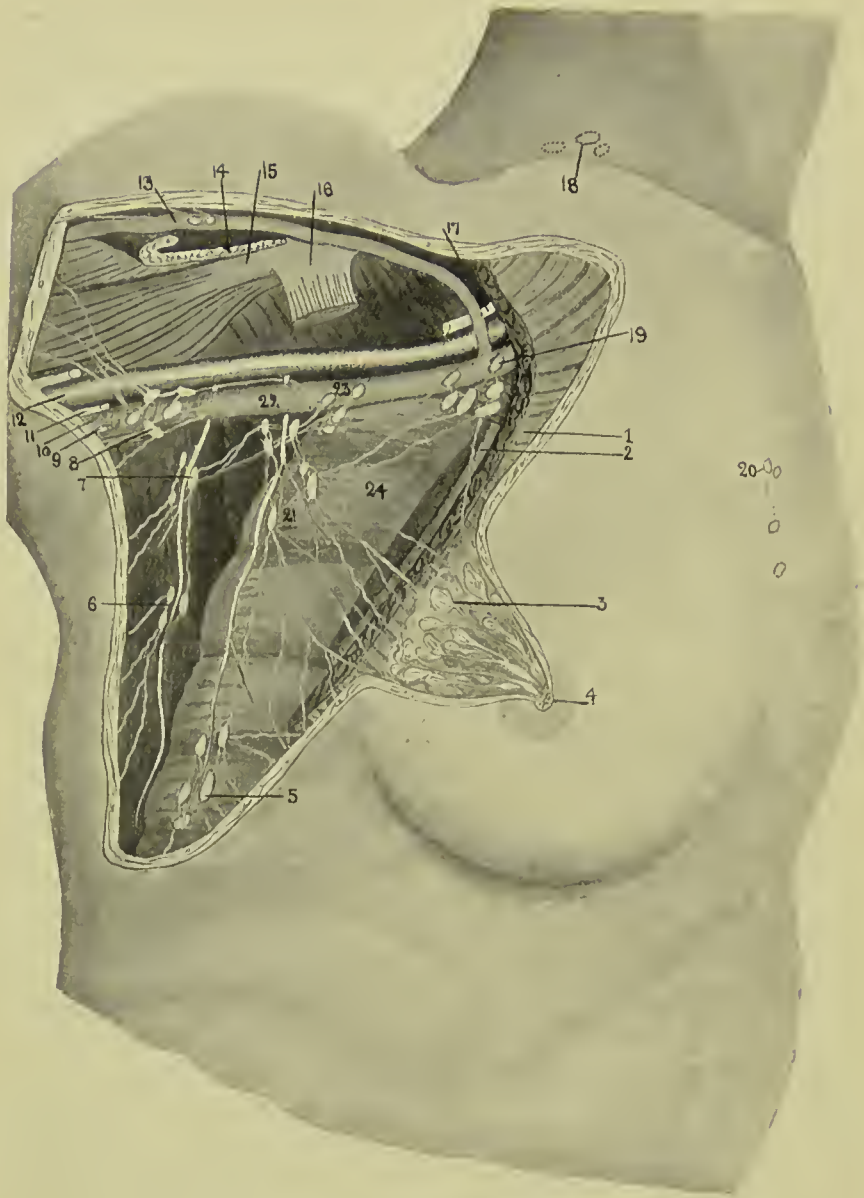


FIG. 17.—DIAGRAM OF BREAST LYMPHATICS.

(Much modified from Testut.)

- | | | |
|---|--|--|
| 1. Pect. major. | 6 and 7. Subscapular group surrounding subscapular artery. | 16. Pect. minor tendon. |
| 2. Pect. minor. | 8. Deep brachial group. | 17. Brachial plexus. |
| 3. Breast dissected, showing acini, ducts, and ampullæ. | 9. Nerve of Wrisberg. | 18. Supraclavicular group (deep cervical). |
| 4. Areola and nipple, showing openings of ducts. | 10. Axillary vein. | 19. Infraclavicular group. |
| 5. Inferior thoracic group surrounding external mammary artery (long thoracic). | 11. Ulnar nerve. | 20. Anterior mediastinal group. |
| | 12. Axillary artery. | 21. Pectoral group. |
| | 13. Cephalic vein. | 22. Central superficial group. |
| | 14. Pect. major tendon. | 23. Deep group. |
| | 15. Coraco-brachial and biceps. | 24. Serratus magnus. |

case of carcinoma of the breast, we may have lymphatic affection in the axilla, under the clavicle, above the clavicle, and thence to the lymphatic duct, whence the infection would become general. The *mass in the axilla* causes œdema of the arm from pressure on the vessels and lymphatics, and pain over the back of the arm above the elbow from pressure on the intercosto-humeral nerve which traverses the central axillary glands; while the brachial plexus may also become involved, and spreading to the anterior mediastinum may occur. The lymphatics traversing the pectoral fascia become involved, the gland then becoming *fixed* to the underlying structures, and so rendered immovable. The carcinoma may also spread by the *lymphatics in the suspensory ligaments* (which become contracted, causing sometimes an *orange-skin appearance* of the overlying skin, or at others a general flattening), and those surrounding the ducts (producing *retraction of the nipple*). The *subcutaneous lymphatic system* is most prone to infection after ulceration of the skin has occurred, and once it is affected dissemination is very rapid, nodules being scattered over the skin of the chest and trunk generally, producing, if the carcinoma be of the scirrhous type, the condition known as *cancer en cuirasse*, in which great contraction of the whole skin occurs, crushing the chest and killing by suffocation.

Carcinoma is the most common tumour of the breast, and it occurs in many different forms—scirrhous, in which there is abundant fibrous tissue; adeno-carcinoma, which is glandular in microscopic section, and clinically presents one or more bosses on the breast, covered by shiny, discoloured skin; acute carcinoma, which rapidly involves the whole breast, and is not unlike an abscess clinically, while microscopically it presents masses of loosely-packed cells with but little stroma; Paget's nipple, which begins as an eczema of the nipple and areola, and gradually spreads throughout the ducts.

Sarcoma, frequently of the adenomatous type, sometimes occurs in the breast, and, as it is generally encapsulated in the early stages, is of slow growth.

Of the simple tumours, various forms of *adenoma* are most common, and where situated in the lower segment, and deeply in the breast substance, are best removed through a curved incision along the lower border of the breast, the gland being

lifted up, and the tumour extracted from its under surface (Thomas). *Cysts* also occur, either simple retention cysts, due to blocking of the milk ducts (galactocoele), or papillomatous cysts.

Inflammation of the breast (*mastitis*) may be followed by *abscess*, which is generally INTRAMAMMARY, but may be supra- or inframammary, the latter being not infrequently due to tubercle, and sometimes occurring in the bursa beneath the breast. The typical pyogenic abscess is intramammary.

The breasts are frequently *unsymmetrical*, the left being generally the larger. *Absence* of one or both breasts (amazias) is very rare, but the presence of *supernumerary nipples* (polythelia) and glands (polymazia) is more common. The additional glands generally lie below and inside the normal, but may occur at any point along a line extending from the axilla to the groin. They have also been found on the thigh, back, buttock, etc.

In *palpating the breast* it is important to remember that, if the breast be taken between the finger and thumb, the normal breast tissue will give a sensation not unlike that of a tumour. The correct method, therefore, is to lay the palm of the hand and fingers flat on the breast, allowing the nipple to project between the fingers, and then to palpate the gland against the chest-wall.

The *nerve-supply* of the breast is from the fourth, fifth, and sixth intercostals, by which filaments of the dorsal sympathetic also reach it.

The **THORACIC CAVITY** contains the lungs, which are separated by the mediastinum, containing the heart, vessels, trachea, etc. The **mediastinum** extends from the sternum to the spine, forming a complete septum between the lungs, and is deflected somewhat toward the left. It is bounded by the diaphragm below, but is open above, while laterally it is bounded by the pleuræ. Its *upper part* contains the aortic arch and great vessels, innominate veins, and upper portion of the superior vena cava; trachea, œsophagus and thoracic duct; phrenic, pneumogastric, left recurrent laryngeal and cardiac nerves; and thymus gland. The *lower part* is chiefly occupied by the heart and pericardium and phrenic nerves placed centrally. In front of the pericardium and behind the gladiolus the mediastinum is practically non-existent in its

upper segment, owing to the pleuræ coming in contact, but below the fourth costal cartilage the pleuræ diverge. This anterior portion contains areolar tissue and lymphatic glands and vessels. Behind the pericardium the lower mediastinum communicates with the upper, and contains the descending thoracic aorta, azygos veins, œsophagus, thoracic duct, and two pneumogastric nerves. The *azygos veins* commence below in the lumbar veins, and communicate with the iliacs, renals, etc.; receive blood from the intercostal veins; and discharge into the superior vena cava. They may be of great assistance where the main trunk is obliterated, and when themselves pressed on tend to cause œdema of the chest-wall from engorgement of the intercostal veins. The mediastinum is sometimes the seat of *abscesses* which may develop from the contained glands or the dorsal vertebræ, or may extend to it from the neck. Such abscesses are generally chronic, and become of large size, pressing upon the trachea, bronchi, or œsophagus. *Sarcomatous tumours* and *aortic aneurism* also give rise to pressure symptoms, the effects on the veins being often particularly obvious, the face, neck, and upper limbs becoming œdematous from pressure on the superior vena cava, and innominate, while the veins of the trunk also become distended from the increased flow of blood through them. The vagus, recurrent laryngeal, and sympathetic nerves also become affected.

The FIBROUS PERICARDIUM, of inverted conical shape, is attached above to the roots of the great vessels, and below to the central tendon of the diaphragm. *Laterally and anteriorly* it is bounded by the pleuræ, while posteriorly it is largely free. *Above*, the fibrous pericardium is lost upon the great vessels about the level of the centre of the manubrium, whence, however, it becomes connected with the pretracheal layer of the deep cervical fascia (*cervico-pericardiac fascia*). This connection between larynx, pericardium, and diaphragm explains why the *larynx descends* slightly on inspiration. *Below*, owing to the base sloping downwards and forwards to the left, it has indirect relationships to the left lobe of the liver and upper wall of the stomach. This latter relationship helps to explain the cases of *fainting* which sometimes occur from flatulent distension of the stomach pressing directly upon the heart. The lower extremity of the *thymus gland* rests upon

the upper portion of the anterior surface, and a small portion of this anterior surface to the left of the middle line, and behind the sternum and fourth, fifth, and sixth ribs, comes into relationship with the chest-wall. The *posterior surface* is

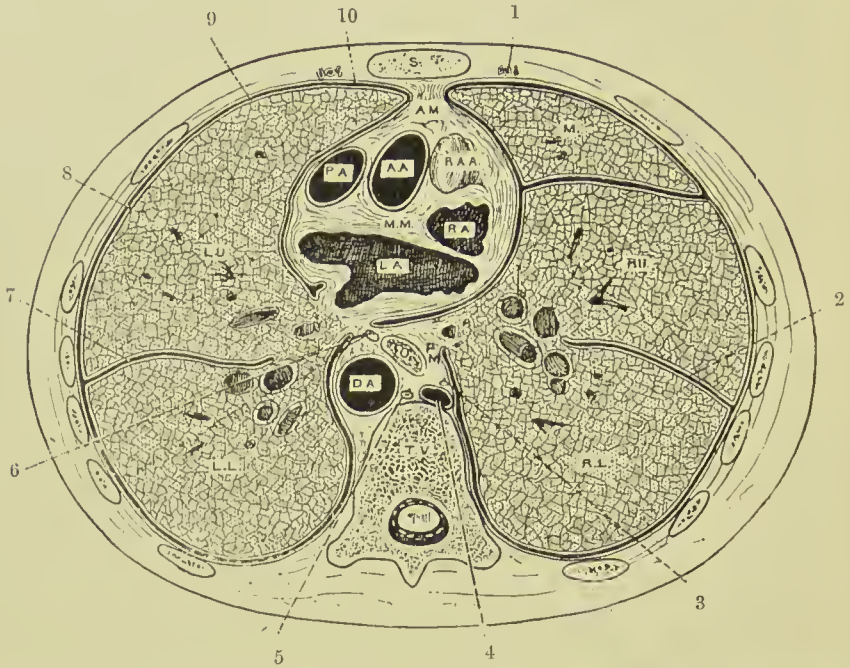


FIG. 18.—TRANSVERSE SECTION OF THE THORAX THROUGH THE SECOND STERNEBRA IN FRONT AND THE BODY OF THE NINTH THORACIC VERTEBRA BEHIND, SHOWING THE REFLECTIONS OF THE PLEURÆ AND THE POSITION OF THE VISCERA.

(From Buchanan's "Anatomy.")

- S. Sternum.
- A.M. Anterior mediastinum.
- A.A. Ascending aorta.
- P.A. Pulmonary artery.
- R.A.A. Right auricular appendix.
- R.A. Right auricle.
- M.M. Middle mediastinum.
- L.A. Left auricle.
- 1. Internal mammary vessels.
- 2. Right chief pulmonary fissure.
- 3. Right vagus nerve.
- 4. Right azygos vein.
- 5. Thoracic duct.

- P.M. Posterior mediastinum.
- O. Oesophagus.
- D.A. Descending thoracic aorta.
- T.V. Thoracic vertebra.
- M. Middle lobe of right lung.
- R.U. Right upper lobe.
- R.L. Right lower lobe.
- L.U. Left upper lobe.
- L.L. Left lower lobe.
- 6. Left vagus nerve.
- 7. Left pulmonary fissure.
- 8. Pulmonary pleura.
- 9. Pleural interval.
- 10. Parietal pleura.

related to the thoracic aorta and duct, the oesophagus and vagi nerves, and the bifurcation of the trachea. Within the fibrous pericardium is the SEROUS PERICARDIUM, which, like the peritoneum, is a closed sac containing a little fluid, the *parietal layer* of which invests the inner surface of the fibrous

layer, while the *visceral* partially ensheaths the heart and great vessels. The aorta and pulmonary artery are enclosed together in a complete sheath of visceral layer, which is separated from the auricles, which lie in front, by a passage, called the *great transverse sinus*, running from right to left. The other vessels receive partial coverings, and also present sinuses separating them from the serous pericardium. The pericardium may be occupied by a considerable amount of *fluid* without pressing unduly upon the heart, the sac stretching, if time be given it, at the expense of the lungs, the above-mentioned sinuses, etc. In such cases the pericardium has been known to contain fully 2 pints of fluid, the superficial area of heart dulness being increased, and the heart, which has its root in the great vessels, being pushed upwards and backwards, its impulse becoming imperceptible, and the diaphragm being depressed. In examining such conditions it is important to know the *normal relationship* of the anterior surface of the heart to the chest-wall. The projection of the anterior surface, then, may be defined by four lines—*above*, across the sternum just above the upper borders of the third costal cartilages, and extending beyond it for $\frac{1}{2}$ inch on the right and 1 inch on the left; *below*, from a point on the right sixth costal cartilage, $\frac{3}{4}$ inch from the sternal margin, downwards to the left fifth intercostal space, $3\frac{1}{2}$ inches from mid-sternum (this latter point represents the position of the apex); *on the right*, from the extremities of the top and bottom lines, in a curve with the convexity outwards, which reaches at the level of the fourth costal cartilage, a point $1\frac{1}{2}$ inches from the mid-sternal line; *on the left*, also curved with the convexity outwards, and joining the extremities of the top and bottom lines. A small triangular portion of the heart, chiefly right ventricle, is left *uncovered* by lung, and is defined by drawing a vertical line along the mid-sternum from the lower border of the fourth costal cartilage to the junction of the gladiolus and xiphoid, and joining either extremity of this with the apex in the fifth intercostal space. Where effusions come on rapidly, serious consequences may follow even comparatively slight accumulations, and in such cases it may be necessary to *tap the pericardium*, or, where the fluid is purulent, to drain it. Tapping is best done through the sixth left intercostal space, keeping close to the sternum, so as to avoid the internal

mammary artery. The space is narrow, and the needle should not be introduced much more than an inch, lest the heart be wounded. Where it is necessary to open up the pericardium (*pericardotomy*) for draining or stitching cardiac wounds, a vertical incision along the left margin of the sternum, from the fourth to seventh costal cartilage, is made, and the sternum and cartilages exposed. The fifth cartilage is first cut close to the sternum, and then raised, the underlying tissues being carefully reflected from it, so as to avoid the internal mammary artery, and a piece cut out. The sixth cartilage is similarly treated. Then the *triangularis sterni* muscle is incised vertically, close to the sternal margin, the soft tissues carefully reflected, the pericardium exposed, picked up, and incised, also vertically, for about an inch, the pericardial edges being afterwards sutured to the subcutaneous tissues to prevent dissemination of purulent material. It should be remembered, however, in connection with operations on the pericardium, that the area left uncovered by the pleura varies, the left pleura occasionally overlapping practically the entire pericardium.

The **HEART** is somewhat pyramidal in shape, its long axis being nearly horizontal, and directed downwards, forwards, and to the left. The *anterior surface* presents itself when the pericardium is opened from the front, and consists of the right auricle, and occupying most of the surface, the right ventricle; the tip of the left auricular appendix, and a comparatively small portion of the left ventricle, separated from the right ventricle by the anterior interventricular furrow (which lodges a branch of the left coronary artery, and the great cardiac vein, surrounded by fatty tissue). The other structures exposed from the front are (a) the *pulmonary artery*, whose *valve* is situated behind the upper edge of the third left costal cartilage close to the sternum; (b) the *ascending aorta*, whose *valve* is behind the left border of the sternum close to the lower edge of the third cartilage. The trunk ascends behind the second right cartilage, and arches over the pulmonary arteries, the convexity of the arch corresponding to the junction of the manubrium and gladiolus. It gives off the innominate and left carotid arteries opposite the centre of the manubrium, which vessels run up to either sterno-clavicular joint; (c) to the right of the aorta, a small portion of the

superior vena cava. The *tricuspid valve* lies behind the middle of the sternum, about the level of the fourth costal cartilage, and the *mitral* behind the third intercostal space, 1 inch to the left of the sternum. All the valves, therefore, are so situated that the mouth of an ordinary stethoscope placed over the left margin of the sternum at the third intercostal space will cover a portion of each. It will be remembered that the orifices of the venæ cavæ are practically *valveless*. The *superior vena cava* begins opposite the lower border of the first right cartilage, by the union of the two innominate veins, and descends, curving slightly to the left, to the third right costal cartilage, where it enters the right auricle. These relationships are of importance with reference to *wounds* of the chest. Where the heart is involved, the right ventricle most frequently suffers, then the left ventricle, and then the right auricle. Wounds of the ventricles tend to be less serious than those of the auricles, owing to the thicker and more muscular coat, and such wounds have been successfully sutured. In some cases death from cardiac wounds is possibly due to nervous shock rather than to bleeding.

The *posterior surface* of the heart presents the auricles, particularly the left, and the orifices of the four pulmonary veins and of the venæ cavæ. It extends from the fifth to the eighth dorsal spine. The *lower surface* presents chiefly the left ventricle, and small portions of the right ventricle and auricle. In front, near the apex, the heart is in relation with the upper wall of the stomach, the diaphragm and pericardium intervening, while behind it lies over the left lobe of the liver. *Congenital displacements* of the heart are occasionally met with. In some cases of transposition of the viscera the heart may be displaced to the right (*dextrocardia*), or, associated with congenital sternal fissure, an *ectopia cordis* may occur, the heart projecting forwards through the aperture. *Pathologically*, the heart is most frequently *displaced* laterally by pleural affections, such as effusion or pneumothorax; cirrhosis of the lung, by shrinking, tends to drag it toward the affected side, while emphysema depresses the diaphragm, and with it the heart. The heart may also be displaced upwards by gaseous distension of the stomach, ascites, etc. Changes of the heart itself, such as *dilatation* and *hypertrophy*, also affect the position, and it should be remembered that the position of

the normal heart is influenced by respiration and position of the body.

The **THORACIC AORTA** consists of three parts—ascending, arch, and descending. The **ascending portion**, about 2 inches long, runs upwards, forwards, and to the right to the level of the upper border of the second right costal cartilage. It lies within the pericardium, and is invested, along with the pulmonary artery behind which it lies at its origin, by the serous layer. At its commencement it presents three hemispherical projections, the *aortic sinuses* of Valsalva, and also a prominence of the right lateral wall, called the *great aortic sinus*. In front are the pulmonary artery, right auricular appendix, pericardium, right pleura and lung, mediastinal tissue and sternum ; behind, the right branch of the pulmonary artery and right bronchus ; on the right, the superior vena cava and part of the right auricle ; on the left, the pulmonary artery.

The **arch of the aorta** commences opposite the upper border of the second right costal cartilage, and ends opposite the lower border of the fourth dorsal vertebra. The highest point is opposite the centre of the manubrium and third dorsal spine. The concavity of the arch is directed downwards, and also backwards and to the right. A constriction between the origin of the left subclavian and the obliterated ductus arteriosus is called the *isthmus*, and the expanding portion beyond the *spindle*. In front and to the left are the left mediastinal pleura, phrenic nerve, inferior cardiac branch of vagus, superior cardiac branch of sympathetic, vagus trunk, and superior intercostal vein, remains of thymus, lung, and pleura, mediastinal tissue, and manubrium. Behind and to the right are trachea, œsophagus, thoracic duct, and left recurrent laryngeal nerve ; above are the innominate and left common carotid and subclavian arteries, and left innominate vein ; below are the bifurcation of the pulmonary artery, obliterated ductus arteriosus, left recurrent laryngeal nerve, and root of the left lung.

The **descending portion**, commencing at the lower border of the fourth dorsal vertebra, lies in close relationship to the left side of the column, but inclines to the middle line as it approaches the aortic opening in the diaphragm. In front are the root of the left lung, œsophagus, base of heart, and

pericardium ; on the right, œsophagus, vena azygos major, thoracic duct and pleura ; on the left, pleura and lung ; and behind, vertebral column.

The thoracic aorta is a frequent seat of ANEURISM. When the ascending portion is affected, the tumour ultimately projects on the right margin of the sternum, at the level of the second and third costal cartilages, all of which structures may become eroded, while the clavicle may be displaced forwards. Owing to pressure upon the superior vena cava, there is engorgement of the veins of the head, neck, and upper limbs. This form may rupture into the pericardium, and cause death by pressure on the heart.

Where the arch is affected, the tumour presents at the root of the neck and suprasternal notch. Pressure on the veins produces engorgement ; on the left recurrent laryngeal nerve, spasm of the cords with high-pitched voice, and dyspnœa, and, later, aphonia from crushing of the nerve. Pressure on the trachea produces harsh breathing, dyspnœa, and cough ; on the left bronchus, dyspnœa ; on the œsophagus, dysphagia ; and on the phrenic nerve, hiccough, and, later, paralysis of the left side of the diaphragm. *Tracheal tugging*, detected on slightly raising the cricoid cartilage with the finger and thumb, is due to the expansile pulsation affecting the trachea. Owing to irritation of the cervical sympathetic, which conveys fibres to the eye from the lower cervical and upper dorsal regions of the cord (through the rami communicantes, to the carotid plexus, and so to the ciliary ganglion within the orbit), there is dilatation of the pupil on the affected side, while, should the sympathetic fibres be destroyed by increased pressure or stretching, the pupil contracts from unopposed action of the third nerve. Where the descending aorta is affected, the bodies of the vertebræ are frequently eroded, while the intervertebral discs are comparatively resistant. There is intense gnawing pain in the back, referred to the areas supplied by the intercostal nerves involved, and herpes zoster may develop.

In all cases where there is external swelling, pulsation of an expansile character is a feature which serves to distinguish aneurism from most tumours or abscesses. In addition to presenting the symptoms mentioned, the deep forms may be diagnosed by X rays. *Treatment* by needling, with the object of slightly injuring the sac wall and producing the formation

of a white thrombus with subsequent formation of firm fibrous tissue, is hopeful if the case be got early (Macewen).

The **THORACIC TRACHEA** lies in the posterior portion of the superior mediastinum, separated from the vertebræ by the œsophagus. In front it is related to the aortic arch at the level of the fourth dorsal vertebra, the great vessels, left innominate vein, and remains of the thymus. Immediately above the bifurcation the deep cardiac nerve plexus lies in front and laterally. On the right side it is in relation to the vagus and pleura, and on the left to the subclavian artery and recurrent laryngeal nerve. The bifurcation of the trachea lies opposite the interval between the third and fourth dorsal spines, about the level of the sternal angle in front. The two **bronchi** proceed down and outwards towards the hilus of the corresponding lung, the left bronchus generally being twice as long as the right, which is the wider. The vena azygos major arches over the right bronchus, and the aorta over the left, while the interval between the two is occupied by a group of bronchial lymphatic glands. On the left side the pulmonary artery crosses above all the collateral branches of the bronchus, while on the right side the first collateral bronchus lies above the artery, and the others below it.

Foreign bodies, small enough to pass the glottis, sometimes drop into the trachea, lodging probably about the bifurcation, and giving rise to dyspnœa and cough. When small enough to enter the bronchus, it is generally the right one which is affected, owing to its larger size, and the position of the septum, which lies rather to the left of the middle line.

The **pleuræ** are closed sacs which line the chest-walls (parietal) and the surfaces of the lungs (visceral). They consist of elastic and connective tissue, lined with flat endothelium, the parietal and visceral layers being in contact, save for the interposition of a little clear serous fluid at all points, except at the incisura of the left lung, and at the lower and anterior portion on both sides (*pleural sinuses*).

While the visceral pleura is intimately adherent to the lung, the parietal pleura is generally comparatively free. The *cervical* portion of the parietal pleura is connected to the spine and first rib by fibrous bands which support it: the *costal* portion, which is the strongest, is separated from the chest-wall by a layer of connective tissue, the *endothoracic fascia*; the

diaphragmatic portion is fairly adherent, but does not extend to the bottom of the groove between the thoracic wall and diaphragm. The *mediastinal* portion is loose above the pericardium, and extends direct from sternum to spine. Over the *pericardium*, however, it is adherent, and it is invaginated, over the root of the lung to join the visceral layer. This dipping in of the parietal pleura to meet the visceral continues from the root of the lung to the base, and the two layers, which thus come in contact, form a vertical fold, the *ligamentum latum pulmonis*. The LINES OF REFLECTION of the pleura from the chest-wall are of considerable importance. *Anteriorly*, on the right side, the line begins opposite the interval between the two heads of the sterno-mastoid, runs down and inwards behind the sterno-clavicular articulation, to meet its fellow at the manubrio-gladiolar junction, generally a little to the left of the middle line, whence it descends almost vertically to the sixth intercostal space, and then curves outwards, becoming continuous with the costo-diaphragmatic reflection. On the left side it behaves similarly, save that at the level of the fourth costal cartilage it deviates outwards behind the inner extremities of the fifth and sixth intercostal spaces, which thus are in contact for a short distance with the pericardium. *Below*, starting from the sternal end of the sixth intercostal space, the reflection on the right side runs down and outwards, crosses the junction of the seventh rib and its cartilage, crosses the seventh space in the mammary line, and so runs down to the tenth rib behind the midaxillary line. Then it runs inwards to the vertebral end of the twelfth rib. On the left side this reflection commences behind the sixth costal cartilage, but otherwise resembles the right. Generally speaking, a line from the lower end of the gladiolus over the cartilage of the ribs to the lower border of the last rib indicates this reflection with sufficient accuracy. *Posteriorly*, the pleuræ extend to the costo-vertebral junctions. The *lowest part* of the pleural sac is posterior, behind the twelfth rib, but operations on the pleura at this part are rather dangerous, as, owing to the rapid arching of the diaphragm, a trocar introduced would almost certainly penetrate both layers of pleura and diaphragm, and enter the abdomen—probably the stomach, if done on the left side. It is well to remember, however, that the lower level of the pleura reaches the twelfth

rib, even when that rib is rudimentary, and occasionally it descends to the transverse process of the first lumbar vertebra, thus rendering it liable to wounding in operations on the kidney in the lumbar region. The pleura extends further down in the child than in the adult, and slightly further on the left side than on the right. Normally, except at the pleural sinuses, the pleural surfaces are in contact with one another, save for the interposition of a thin layer of serous fluid. As a result of the smooth, polished surfaces which the pleuræ present to one another, and the intervening thin layer of fluid, the force of *cohesion* between the two layers is very great. This force is not merely sufficient to counterbalance the *contractile elasticity* of the lung substance, but tends to *extrude* any accumulation of fluid which may exist between the two surfaces. Thus, it is quite safe to remove two or three ribs, and expose the visceral pleura; not only will the lung not collapse, but if there be a recent accumulation of fluid between the layers this will be expelled, the lung being pulled out to its original size by the cohesive force acting on the pleuræ. In some cases, due possibly to forced expiratory efforts, the lung has even protruded from an opening in the chest (*hernia of lung*).

Pneumothorax, or air in the pleural cavity, is generally produced by a valve-shaped wound, as in some cases of compound fracture of the ribs, the respiratory action forcing air in between the layers of pleura, and so separating them. In severe cases the pneumothorax may be so great as to threaten *collapse of the lung*, and produce urgent dyspnoea. In such cases the wound should be laid freely open, thus destroying the valve; the chest-wall compressed so as to express the air, and restore the condition of cohesion between the layers of pleura, when the lung will expand to its normal size. Sometimes it is sufficient to introduce a trocar and cannula, leaving the latter *in situ*. It is noteworthy that in some cases of wound of the chest involving the pleura an actual bulging forwards, or *hernia of the lung*, has occurred, and elaborate theories have been advanced to account for such phenomena. Where, from any cause, cohesion is destroyed, collapse of the lung may occur readily. Thus, wounds of the pleura affecting the *pleural sinuses* are particularly prone to result in collapse, air at these points getting most readily between the two surfaces.

Emphysema of the subcutaneous tissues frequently results from such valve-shaped wounds as mentioned, the air being pumped by the respiratory movements into the tissues. It may also arise from valved superficial wounds which do not communicate with the pleura or lung, the chest movement supplying the pumping action. *Pleural effusions* sometimes result in soldering of the two surfaces together. On the other hand, they may force the two surfaces apart, and produce grave changes in the serous membranes. This is well seen in *empyema*, or accumulation of pus in the pleural cavity, which sometimes is of great size, causing bulging of the chest-wall on the affected side, collapse, more or less complete, of the lung, and thickening of the pleuræ and roughness of their surfaces. The thickening of the pleuræ tends to prevent re-expansion of the lung, while the roughness of the surface destroys the force of cohesion, thus rendering it difficult to keep the lung expanded, even if it tends to do so. Empyemas, however, are frequently localized, the two layers of pleura becoming soldered round the periphery by fibrous exudation. A similar soldering frequently prevents the formation of a pneumothorax in cases of perforation of the visceral pleura from tubercular disease of the lung. An untreated empyema may burst through the chest-wall or into the lung or pericardium, or sometimes may extend into the abdomen through the internal arcuate ligament.

Empyema is generally *treated* by evacuation through the sixth or seventh intercostal space in front of the posterior axillary fold. Incisions made lower down may wound the diaphragm, or even penetrate the abdomen, owing to obliteration of the lower portion of the pleural cavity from disease; and even if this should not occur, the diaphragm frequently ascends after the empyema has been evacuated, rendering the communication very oblique. Where the empyema is localized, its site is generally determined by percussion, and confirmed by an exploring needle. The operation may consist of an incision along the intercostal space, keeping near the upper border of the lower rib, or a portion of rib may be excised. As already stated, however, changes frequently occur, after empyema has been present for some time, in the pleura, and disease may be present in the lung, so that even after evacuation of the pus the lung may not tend to expand.

In such cases healing is very slow, the chest not collapsing readily, and a large cavity remaining in the chest, from which there is a continual discharge. In these circumstances a *thoracoplasty* is performed—a large flap being raised from the chest-wall, several ribs removed subperiosteally, the abscess cavity cleared out thoroughly, and the two refreshed surfaces brought into contact by collapsing the chest-wall (Estlander).

The **LUNGS**, roughly conical in shape, occupy the thoracic cavity, being separated from one another by the mediastinum. The right lung is broader, shorter, and slightly larger than the left. The **APEX** projects into the root of the neck, corresponding posteriorly to the spine of the seventh cervical vertebra, and anteriorly to a point nearly 1 inch above the inner end of the clavicle. The lines of the anterior borders correspond to those of the pleural reflections already given (*q.v.*). The anterior border of the left lung presents a notch or *incisura* corresponding to the cardiac apex, which is thereby left uncovered by lung. The **BASES**, however, do not reach as low as the pleuræ. Thus, on the right side the base of the lung extends from the sixth intercostal space in front to the lower border of the eighth rib in the axillary line, and that of the tenth rib in the scapular line, and then runs horizontally inwards to the vertebral extremity of the eleventh rib, the lowest level reached being the ninth intercostal space in front of the scapular line. The lower border of the left lung is similar, but rather lower. In consequence of the pleuræ descending below the lower limit of the lung, it is possible to get *wounds* which involve the pleura, but do not damage the lung. Both lungs present a deep **FISSURE**, which commencing posteriorly about 3 inches below the apex, opposite the third dorsal spine, extends first horizontally on a level with the vertebral extremity of the spine of the scapula, and then is directed downwards and forwards, dividing the lung into two **LOBES**, and terminating in front at the level of the lower border of the sixth rib just in front of the mammary line. The right lung generally presents a second fissure, which divides the upper lobe into two. It thus presents **THREE LOBES**. The *mediastinal surface* of each lung is concave, and particularly on the left is deeply indented by the pericardium. The left lung is also grooved *above the hilum* by the arch of the aorta and left subclavian artery, while *behind the hilum* the

right is grooved by the vena azygos major and œsophagus, and the left is in relationship to the œsophagus and thoracic duct. The HILUM is situated on the inner surface, rather above and posterior to the centre of the lung, opposite the fifth, sixth, and seventh dorsal spines. It is oval in section, and is continuous below with the *ligamentum latum pulmonis*. The structures forming the ROOT OF THE LUNG are the bronchus, pulmonary artery, and three pulmonary veins, the artery lying below the bronchus on the right side, and above it on the left, while the veins on both sides lie below the other structures. The branches of the *pulmonary vessels* follow the bronchi, break up into fine capillaries, which project into the lumen of the alveoli, thus producing the oxygenation of the blood, which then returns by the *pulmonary veins* to the left auricle. In addition to the structures mentioned, there are small bronchial arteries and veins and lymphatic glands, pulmonary lymphatic vessels and nerves, and a small amount of connective tissue. The *bronchial arteries* supply the lung tissue, and vary from one to three for each lung, being derived from the aorta or an intercostal vessel. They lie on the posterior surface of the bronchus. The blood is returned partly by the pulmonary and partly by the *bronchial veins*, which latter open into the azygos veins. The *pulmonary nerves* are derived from the vagus and sympathetic.

Wounds of the lung are occasionally met with, and cases are recorded where *rupture* of the lung has occurred without either external wound or fracture of the ribs. In *bleeding* from the lung the blood may be effused into the tissue of the organ, giving rise to *pulmonary apoplexy*, or into the alveolar spaces, and so to the bronchi, causing *hæmoptysis*, or, where the visceral pleura is wounded, into the pleural cavity, causing *hæmothorax*. In cases of desperate bleeding from the lung, it may be necessary to open the chest-wall, and collapse the lung. The lung is frequently affected by *emboli* brought to it by the systemic veins, or from the right side of the heart. These get arrested in the pulmonary capillaries, and, if septic (as would be the case when conveyed from septic sigmoid sinus thrombosis), give rise to lung *abscesses*, or, where they have been detached from some sarcomatous tumour, give rise to secondary *tumours* in the lung. Thus, the lung should be carefully examined, where extension either of a venous

septic process or of sarcoma is suspected. Fat *emboli* from injury to the medulla of bone, and air emboli from wound of one of the large veins in the neck, also occur in the lung, and the latter frequently give rise to *asphyxia*.

Where from any cause—as, for instance, in mitral or aortic disease—the return flow of blood from the lungs is obstructed, the lung becomes greatly engorged. The bronchial vessels anastomose with the pulmonary, but they are of small size, and only serve to supply the lung tissue.

Cavities in the lung arise perhaps most frequently from tubercular disease, but may also be caused by abscesses, or gangrene, following pneumonia, the entrance of foreign bodies, or by extension from the liver. *Hydatid cysts* are also sometimes met with. In such cases a *pneumotomy* may be performed in order to reach and drain the cavity. Such an operation is generally best performed in two stages—the first opening the pleural cavity, and the second, after the pleuræ have become soldered round the edges, opening into the lung substance, the cautery being sometimes used for this purpose, where serious bleeding is feared. On the other hand, where the lung is affected—for example, by a primary sarcomatous tumour—it may be necessary to excise a portion, or, where it is riddled with tubercle, it is occasionally advisable to remove the whole lung. This operation is known as *pneumonectomy*, and consists, first, in the removal of several ribs, as in Estlander's operation, and, at a later stage, of ligature of the affected portion and its removal, or, where complete extirpation is required, ligature of all the structures at the root of the lung, and removal of the lung *in toto* (Macewen). Such an operation on a healthy lung would probably cause immediate death of the patient, but, in disease, the lung is almost, if not entirely, functionless at the time of its removal, and good results are hence obtained, the more normal lung frequently benefiting by the removal, as cross infection by the bronchi and trachea is arrested.

The **ŒSOPHAGUS** is normally about 10 inches long and $\frac{1}{2}$ inch wide, and presents two constrictions, one at the beginning, and the other at the point where it is crossed by the left bronchus, each capable of admitting an instrument $\frac{4}{5}$ inch in diameter. Foreign bodies are most apt to lodge at these points. But for the pylorus, it is the narrowest and one of

the most muscular portions of the alimentary tract. It extends from the termination of the pharynx, opposite the sixth cervical vertebra, to the cardiac orifice of the stomach, opposite the eleventh dorsal vertebra; presents an antero-posterior curve in conformity with the vertebral curve, and also two lateral curves to the left, the first at the lower portion of the neck and upper portion of the thorax, and the second behind the pericardium, where it also passes forwards to reach the œsophageal opening in the diaphragm. In addition to the portion in the neck, thoracic, diaphragmatic, and abdominal portions are described.

In the thorax it lies close to the vertebral column in the superior mediastinum, while in the posterior mediastinum it comes forward into contact with the posterior surface of the pericardium. The trachea and left bronchus also lie in front. Behind lie the longus colli muscle and vertebral column above, while below the vena azygos major, thoracic duct, and aorta intervene between the œsophagus and column. On the left side the thoracic duct, pleura, and left subclavian artery lie superiorly, then the aorta, and again the pleura. On the right side lie the arch of the azygos vein and pleura. The *pneumogastric nerves* form with the sympathetic the œsophageal plexus (plexus gulæ), and then pass to the stomach along with the œsophagus, the left nerve lying in front, and the right behind.

The œsophagus passes through the diaphragm very obliquely, and laterally and posteriorly is in contact with the walls of the orifice for a distance of $\frac{1}{2}$ inch. The abdominal portion is possibly $\frac{1}{2}$ inch in length.

Dysphagia, or difficulty in swallowing, may be due to (1) spasmodic stricture (œsophagismus); (2) organic stricture, which may be fibrous (resulting perhaps from swallowing a corrosive, and situated generally at the upper part of the tube, or due to syphilis, etc.), or may be carcinomatous; (3) pressure on the œsophagus from without, as by a tumour or aneurism; (4) impaction of a foreign body.

In order to ascertain the condition of the œsophagus in such conditions, a stethoscope may be placed over the back, and the patient asked to swallow. Normally the act of swallowing is almost silent, whereas in stricture a sound of dripping, as succeeding drops pass the stricture, is frequently audible.

An œsophageal *bougie* is frequently passed, care being taken before doing so to exclude the possibility of aneurism, which might otherwise be ruptured. In passing the bougie the head should be flexed forwards, and not thrown backwards, so as to prevent the bougie from entering the larynx, and the point guided by the finger past the back of the throat. False passages may be formed if sufficient gentleness be not exercised. While it is possible to attack the œsophagus in the thorax from the back, portions of ribs being resected, and the pleura carefully avoided, it is generally desirable in cases of œsophageal stricture to alleviate the condition by performing a gastrostomy.

SECTION III
ABDOMEN AND PELVIS

THE ABDOMEN

THE abdomen is bounded above by the ensiform cartilage and costal arches ; below by the crest of the ilium, Poupart's ligament, and the crest and symphysis pubis ; and behind by the lumbar spine. For convenience it is generally arbitrarily divided into *nine sections* by two vertical and two horizontal lines. The two vertical lines run upwards from the centre of Poupart's ligament on either side, while the upper horizontal line runs across at the level of the most dependent portion anteriorly of the thoracic framework (tenth costal cartilages), and the lower at the highest point of the iliac crest (about $2\frac{1}{2}$ inches behind the anterior superior spine). The three upper divisions so obtained consist of a middle epigastric division, and right and left hypochondriac regions ; the three central, of a middle umbilical and two lateral lumbar regions ; and the three lower of a middle hypogastric, and two lateral iliac regions.

THE ABDOMINAL PARIETES.

The **skin** of the abdomen is thin, smooth, and movable. In certain abdominal affections, such as ascites, or in pregnancy, the skin becomes stretched and glazed, and presents dark horizontal marks from stretching of the connective tissue bundles. On removal of the distending cause, these present a pale cicatricial appearance, and are known as *lineæ albicantes*.

The **subcutaneous tissues** consist of two layers, a superficial

continuous with the general subcutaneous fatty layer or *panniculus adiposus*, which varies greatly in amount in different individuals, particularly in the parts below the umbilicus, and a deeper, less fatty layer, which constitutes the deep layer of superficial fascia, and which is attached below to the crest of the ilium and Poupart's ligament, but is continued over the penis and scrotum to the perinæum, where it forms *Colles' fascia*. Thus, extravasated urine may find its way up on to the abdomen, being limited to one side, however, by the median attachment, while it is kept from the thigh by the attachment to Poupart's ligament.

In very stout persons two deep *transverse furrows* run across the abdomen, one at the level of the umbilicus, which is thereby concealed, and the other just above the pubic fat. The point of intersection of this latter line with the linea alba indicates the position for the introduction of the trocar in tapping the bladder above the pubes.

The **anterior abdominal wall** is composed of the two recti muscles in front, and laterally of three muscular planes. The LINEA ALBA forms a vertical median furrow, marking the interval between the recti muscles, which are generally slightly separated above the umbilicus, but close together below it. Hence the line only extends from the ensiform to the umbilicus, or slightly beyond it. Along this line the abdominal wall is thin, aponeurotic, and free from bloodvessels, and accordingly it is a favourite site for abdominal incisions. Lying under it from above downwards are the left lobe of the liver, the stomach when distended, the transverse colon (generally above the umbilicus, but very variable), the great omentum covering the small intestines, and the bladder when distended. Spaces sometimes exist in the linea alba, through which small masses of subperitoneal fat may project and simulate irreducible herniæ, and *ventral herniæ* do occasionally protrude through it. The *umbilicus* is nearer the pubes than the xiphoid, and corresponds to the interval between the third and fourth lumbar vertebræ. Normally it is above the central point of the whole body. The parts are supplied with *blood* by small branches from the internal mammary and lower intercostals above, and by three branches of the femoral (superficial epigastric, circumflex iliac, and external pudic) below, together with twigs from the lumbar arteries and perforating branches of the deep epigastric.

Some of the *superficial veins* are of importance, as connecting links between the systemic and portal systems. Thus, the superficial epigastric vein is connected to the portal vein by its communication with the deep epigastric vein at the umbilicus, and so with the para-umbilical veins which run along the round ligament to the liver, where they join the portal. A small vein sometimes runs vertically from the umbilicus to the ensiform, connecting the para-umbilical with the internal mammary vein. In cases of portal obstruction the flow of blood through these veins may be greatly increased, and in consequence they may become distended and somewhat varicosed, the condition being known as *Caput Medusæ*. The long superficial thoracico-epigastric vein communicates below with the femoral or superficial epigastric, and above with the long thoracic, and is sometimes greatly dilated, especially when there is obstruction of the vena cava. Its valves are so arranged as to direct the blood from its upper part to the axilla, and from its lower part to the thigh.

The superficial abdominal *lymphatics* drain the portions under the umbilicus to the inguinal glands, and those above the umbilicus to the axillary glands.

The LINEA SEMILUNARIS marks the outer boundary of each rectus muscle, and corresponds to the splitting of the internal oblique aponeurosis to enclose the rectus. It extends from the tip of the ninth costal cartilage in a slight curve, with the convexity outwards, toward the spine of the pubes, passing about 3 inches outside the umbilicus. It disappears some distance above the pubic spine. Here, as in the case of the linea alba, the abdominal wall is thin and comparatively bloodless, and accordingly the incision for certain operations on the gall-bladder, stomach, and kidney is made through it. The RECTI MUSCLES extend from the xiphoid, and fifth, sixth, and seventh costal cartilages to the crest of the pubes and symphysis. Each presents two or more *lineæ transversæ*, or transverse tendinous intersections, the first being situated about the lowest level of the tenth rib, or about 4 inches above the second, which is situated about the level of the umbilicus. A spasmodic contraction of one of these sections of the rectus muscle, which occurs most frequently in hysterical subjects, has been mistaken for a projecting *abdominal tumour*. The *sheath* of the rectus muscle over three-fourths of the abdominal

wall is derived from the aponeurosis of the internal oblique, which splits at the linea semilunaris to enclose it, the anterior division being joined by the aponeurosis of the external oblique, while the posterior division is joined by that of the transversalis. Below the level of a point midway between the umbilicus and pubic crest, however, the aponeurosis of the internal oblique does not split, but, accompanied by that of the transversalis, passes entirely in front of the rectus muscle, to form the CONJOINED TENDON. The sheath, therefore, is deficient posteriorly from this point downwards, the lowest limit of the posterior layer forming a crescentic margin, called the *fold of Douglas*. Further, the aponeurosis of the external oblique also separates, and becomes distinct from the other layers about this level. The portion of the rectus which lies on the chest-wall is only covered anteriorly by a layer of aponeurosis derived from the external oblique. The sheath of the rectus contains the deep epigastric and superior epigastric arteries, and the terminations of the six lower intercostal and last dorsal nerves.

A *separation* of the recti, rarely extreme, occasionally occurs below the umbilicus, particularly after numerous pregnancies. The muscle is sometimes *torn* by muscular or other violence, the opisthotonos of tetanus, etc.

The *pyramidalis muscle* lies in front of the rectus, and within its sheath. It is triangular in shape, arising, when present, from the crest of the pubes to be inserted into the linea alba.

POUPART'S LIGAMENT is indicated by a fold running in a slight curve with the convexity downwards from the anterior superior spine of the ilium to the spine of the pubes. PETIT'S TRIANGLE is situated above the middle of the iliac crest, and is formed by the external oblique in front, and the latissimus dorsi behind, while its floor is formed by the internal oblique. Lumbar abscesses, and occasionally herniæ, may point through the triangle.

In addition to the recti muscles, the anterior abdominal wall presents the external and internal oblique and transversalis muscles. It is important to remember the direction of the fibres of these muscles, as in many abdominal operations it is desirable to split the fibres of the muscles rather than cut them. The three sets of fibres present a Union Jack on the abdomen; those of the external oblique run downwards

and inwards in the direction of the fingers when the hand is laid naturally on the front of the abdomen, those of the internal oblique run at right angles to those of the external, while those of the transversalis, as the name implies, run transversely. The EXTERNAL OBLIQUE arises from the eight lower ribs, and, becoming tendinous, is inserted into the outer lip of the iliac crest, Poupart's ligament, pubic spine, front of

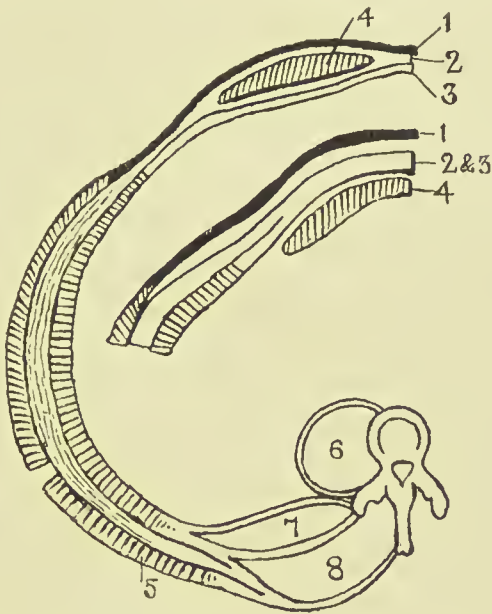


FIG. 19.—SCHEME OF ABDOMINAL MUSCLES (IN SECTION).

- | | |
|----------------------|------------------------|
| 1. External oblique. | 5. Latissimus dorsi. |
| 2. Internal oblique. | 6. Psoas. |
| 3. Transversalis. | 7. Quadratus lumborum. |
| 4. Rectus. | 8. Erector spinae. |

The semicircle presents the arrangement of the abdominal muscles below the level of the umbilicus. Note anteriorly how the tendon of the internal oblique splits to enclose the rectus muscle, the anterior portion being joined by the tendon of the external oblique and the posterior portion by the tendon of the transversalis. The smaller diagram presents the arrangement of these parts about an inch above the pubes. Note how the tendon of the external oblique is separate and distinct from the others; how the tendon of the internal oblique does not split to enclose the rectus, but, fused with that of the transversalis to form the conjoined tendon, passes in front of the rectus.

the symphysis (some fibres crossing to the opposite side at this point), and linea alba, or anterior sheath of the rectus. The INTERNAL OBLIQUE arises from the lumbar aponeurosis, anterior half of the iliac crest, and outer half of Poupart's ligament, and is inserted into the last three ribs, and, splitting to form the rectus sheath, into the seventh, eighth, and ninth costal cartilages and linea alba. The fibres arising from

Poupart's ligament go chiefly to form the conjoined tendon, along with the transversalis. A few of the lower fibres, however, are continued down in loops over the cord and testicle, and are finally inserted into the pubic spine and surrounding fascia. These fibres are generally named the CREMASTER MUSCLE, and in the female, being chiefly represented by fascia, constitute the CREMASTERIC FASCIA. The TRANSVERSALIS muscle arises from the under surfaces of the lower six ribs, the lumbar fascia, the anterior half of the inner lip of the iliac crest, and the outer one-third of Poupart's ligament. It is inserted into the posterior sheath of the rectus, and so to the linea alba and ensiform; and the lower fibres, joined by those of the internal oblique, form the conjoined tendon. These three muscles are separated from one another by loose connective tissue, in which pus or other fluid may easily spread to the various insertions enumerated above, *intraparietal herniæ* also occurring occasionally between the layers. The deep surface of the transversalis is lined by the thin TRANSVERSALIS FASCIA. The transversalis fascia lines the inner surface of the abdominal wall, being best developed in the lower abdomen and in front, and becoming lost above upon the diaphragm, and posteriorly upon the fasciæ of the quadratus lumborum and psoas. Below the semilunar fold of Douglas it is in intimate contact with the rectus until close to the symphysis, where it separates, leaving a *triangular interval* occupied by fatty tissue. Internally, it is attached to the crest of the pubes, and to Gimbernat's ligament, and externally to the outer half of Poupart's ligament, but between these points it extends into the thigh, forming the anterior layer of the femoral sheath. The EXTRA- or SUB-PERITONEAL TISSUE is a layer of fat-laden connective tissue which separates the fasciæ of the abdominal muscles from the peritoneum (parietal portion), and also extends into the various mesenteries (visceral portion). It is further continued on the vessels, nerves, etc., which pass out from the abdomen. In this loose tissue *abscesses* arising from abdominal organs, particularly such as, like the kidney, are only partially covered by peritoneum, may readily spread. Abscesses arising from the appendix, kidney, and gall-bladder may also spread in this layer. The laxity of this tissue used also to be taken advantage of in *ligaturing* the external and common iliac vessels

without opening the peritoneum, the latter membrane being pushed aside until the vessels were reached.

The abdominal wall is supplied by the lower seven dorsal and first lumbar NERVES, which run forwards and downwards between the internal oblique and transversalis. Thus, the sixth dorsal supplies the region of the ensiform cartilage, the tenth dorsal the umbilicus, and the first lumbar the pubis, the various areas overlapping one another. These nerves supply both the skin and the underlying muscles, and thus any irritation of the skin, such as cold or a blow, produces an immediate contraction of the muscles, which thus tend to protect the underlying viscera. Further, the first six of these nerves are intercostal nerves, and control the respiratory movements to a considerable extent, so that when the skin of the abdomen is irritated there is a tendency to inspiration and fixation of the lower portion of the chest. When, therefore, it is desired to subject the abdomen to deep palpation, the hands should be warm, and should be laid flat on the surface, the fingers afterwards being gently pressed in. On the other hand, these same nerves are associated with the abdominal *viscera* through the sympathetic system, and thus in painful affections of these viscera there is generally rigidity of the abdominal muscles, sometimes very marked, the respiration being entirely thoracic, while the pain is referred along these nerves to the parietes, generally in the region of the umbilicus, the skin frequently being tender to the touch.

The abdominal viscera are connected through the solar plexus, splanchnic nerves, and rami communicantes with the segments of the spinal cord from the sixth dorsal to the first lumbar, while the pelvic viscera are connected with those from the fifth lumbar to the third sacral through the *nervi erigentes*. (It will be noted that the second to the fourth lumbar nerves have no visceral connections.)

The stomach communicates with the sixth to the ninth dorsal, the liver and gall-bladder with the seventh to the tenth dorsal, the intestine with the ninth to the twelfth dorsal, and the testicle and ovary with the tenth dorsal. The kidney and ureter communicate with the tenth to the twelfth dorsal and the first lumbar; the uterus with the tenth to the twelfth dorsal, first lumbar, and third and fourth sacral; the rectum with the second to the fourth sacral.

It is important to remember that in spinal injuries and disease, such as tubercle or tumour formation, pain may be referred to the parietes over certain organs which may accord-

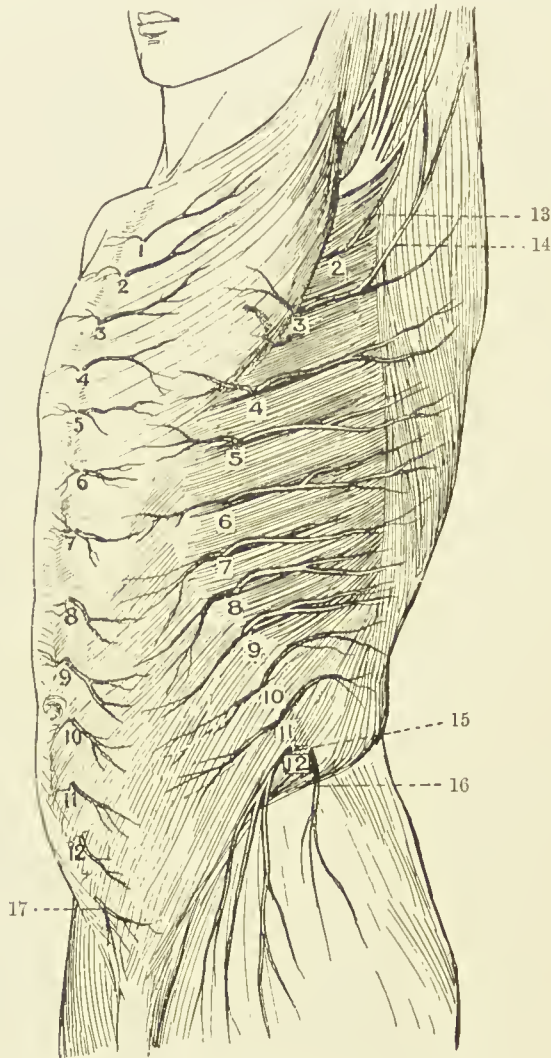


FIG. 20.—CUTANEOUS NERVES OF THE TRUNK ANTERO-LATERAL VIEW
(After Henle.)

- | | |
|--|---|
| 1-12. Anterior cutaneous. | 2-12. Lateral cutaneous. |
| 13. Intercosto-humeral. | 16. Iliac branch of ilio-hypogastric. |
| 14. Additional intercosto-humeral. | 17. Hypogastric branch of ilio-hypogastric. |
| 15. Lateral cutaneous of twelfth thoracic. | |

ingly be presumed to be diseased. Thus, a sense of abdominal constriction, amounting in some cases to actual pain, and referred to the region of the umbilicus, may arise in Pott's

disease, and be mistaken for intestinal colic, while pain from a lesion lower down might be mistaken as pointing to some affection of the kidney or bladder.

The ilio-hypogastric and ilio-inguinal nerves are derived from the first lumbar, the former supplying part of the skin over the ilium and over the external ring, while the latter runs forward under the external oblique to supply the skin of the scrotum or labium majus, and of the upper and inner aspect of the thigh.

DEEP VESSELS.—The two lower intercostal, the subcostal, and the four lumbar arteries, run forward between the transversalis and internal oblique, and anastomose with the internal mammary, deep epigastric, and circumflex iliac, and with one another.

The **DEEP EPIGASTRIC** arises from the external iliac just above Poupart, and to the inside of the internal abdominal ring, and runs upwards and inwards along with its venæ comites to pierce the fascia transversalis, and enter the rectus sheath above the fold of Douglas, where it anastomoses with the internal mammary, which anastomosis is of importance in *ligature* of the common or external iliac.

The **DEEP CIRCUMFLEX ILIAC** arises from the outer side of the external iliac, nearly opposite to the deep epigastric, and, accompanied by its venæ comites, runs in a groove between the transversalis and iliac fasciæ outwards, just above Poupart's ligament, to the anterior superior spine, where it pierces the transversalis, and runs back and breaks up, anastomosing with the lower intercostal and lumbar arteries, and the ilio-lumbar of the internal iliac. It should be noted that not merely do these vessels anastomose with one another, but that they also anastomose with the vessels supplying some of the abdominal viscera. Thus, the lower intercostal arteries communicate with the hepatic, renal, and suprarenal arteries, while the lumbar and circumflex iliac vessels anastomose with those supplying the ascending and descending colon.

The **umbilicus** is the last portion of the abdominal cavity to become closed, and through it, by means of the umbilical cord during foetal life, the embryo receives nourishment and oxygen, from the yolk-sac and blood-supply, while excreted matter passes out along the allantois. In the embryo of three months all the abdomen, save the umbilical ring, has closed, and through this fibrous ring the cord passes. Externally the *cord* is invested with amnion, which latter becomes

continuous with the abdominal wall at the umbilicus, and the structures contained within it are (a) TWO ARTERIES AND ONE VEIN. These structures separate at the umbilicus, the arteries running downwards and outwards, one on either side, to become the common iliac trunks, while the vein runs upwards to the liver. In true *congenital umbilical hernia* the bowel generally passes out between these three structures which are spread over its surface. After birth the two arteries become the OBLITERATED HYPOGASTRIC ARTERIES, while the vein forms the ROUND LIGAMENT of the liver. As the abdomen increases in size, these structures do not tend to grow along with it, and thus the umbilicus is pulled inwards and downwards, carrying the vein along with it, so that in the adult the upper segment of the umbilicus is left free. (b) Up to the third month the midgut is in communication with the yolk-sac, or umbilical vesicle, by the VITELLO-INTESTINAL DUCT, the loop of bowel, which is known as the *umbilical loop*, lying outside the body wall at first. About the third month, however, this communication should disappear, and the bowel retire within the abdomen. Where for any reason the bowel does not retire, a *congenital hernia* is formed. Sometimes, on the other hand, a portion of the duct may persist. This persistent portion forms what is known as *Meckel's diverticulum*, which varies in length, and arises from the ileum from 1 to 4 feet from the ileo-cæcal valve. Sometimes the free end of the diverticulum is connected to the umbilicus by a fibrous cord (which is an occasional cause of strangulation), and in other cases the duct remains patent right up to the umbilicus, causing a *fæcal fistula*. *Cystic adenomata* occasionally occur about the umbilicus in connection with the remains of the duct. (c) The ALLANTOIS grows out from the ventral aspect of the hind gut, and when the placenta is formed its vessels convey the blood between the embryo and the placenta. Normally the allantois shrivels, save its lower end, which forms the *urinary bladder*. A fibrous cord running up in the middle line between the two hypogastric arteries from the apex of the bladder to the umbilicus represents the shrivelled intra-abdominal stalk, which is known as the URACHUS. Sometimes the urachus remains patent, giving rise to a *urinary fistula* at the umbilicus. In other cases the urachus becomes obliterated at either extremity, while the central portion becomes distended, forming a *cyst* of the

urachus. (*d*) The cord, as stated above, is covered by a layer of *amnion*, and, in addition to the structures enumerated, contains a mass of fibro-myxomatous tissue, known as *Wharton's jelly*.

Three forms of HERNIA may be met with at the umbilicus. (1) *Congenital*. This may be associated with some grave defect in the abdominal wall, the viscera remaining exposed, or covered by only a thin membrane. Sometimes the viscera lie outside the abdominal cavity (ectopia or exomphalos). In other cases the abdominal wall may be normal, but a loop of bowel, as already described, may project within the cord for some distance beyond the umbilicus, and thus be liable to ligature with the cord, giving rise to intestinal obstruction. Where such herniæ are recognized, and do not easily return to the abdomen, great care must be taken in cutting the parts at the umbilicus to increase the aperture, as important structures practically surround the bowel. (2) A small *infantile* form of umbilical hernia is not infrequently met with, the condition arising soon after birth from stretching of the umbilicus. It is generally cured by the steady application of pressure for some time. (3) As already stated, the umbilical scar tends to become invaginated and pulled downwards as the patient grows, even the vein arising from the lower border in the adult. Thus, in *acquired umbilical hernia* the protrusion takes place above these structures, through the upper portion which is comparatively weak and thin. A further possible cause for hernia selecting this upper portion is the occasional presence of an *umbilical canal*, which is a small median diverticulum of the fascia transversalis, lined by peritoneum, the mouth of which is directed upwards, while the blind extremity is directed toward the upper margin of the umbilicus. Such herniæ are generally loculated and thin-walled, the peritoneum being very adherent to the skin.

The **INGUINAL REGION** is of much importance surgically on account of the frequency with which hernia occurs in it. The arrangement of the abdominal muscles has already been given, and attention will now be directed to the parts particularly concerned in **hernia**. The chief of these is the **INGUINAL CANAL**—a slit, triangular in section, between the conjoined tendon behind and the external oblique in front, with Poupart's ligament as a base—which commences in the abdomen at the internal ring, and ends externally over the

crest of the pubes at the external ring. It transmits the *cord* in the male, and the *round ligament* in the female, and, normally, the whole space of the canal is occupied by these structures. The parts are best studied from the abdominal side, and for this purpose we shall suppose in the first place that peritoneum, subperitoneal fat, transversalis fascia, and other structures have been removed, leaving the bones, ligaments, and muscles exposed, and that the abdominal wall is viewed from behind.

POUPART'S LIGAMENT is a strong fibrous band, which runs from the anterior superior spine to the spine of the pubes. GIMBERNAT'S LIGAMENT is a reflection from its inner, or pubic

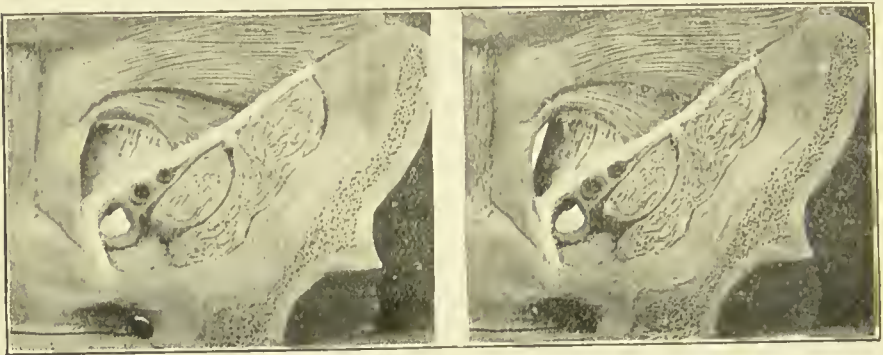


FIG. 21.—STEREOGRAM OF ABDOMINAL WALL, GIVING AN EXAGGERATED VIEW OF THE INGUINAL, FEMORAL, AND OBTURATOR CANALS. (For references, see Fig. 22.)

The figure may be viewed through an ordinary stereoscope or may be seen stereoscopically by holding it about 2 feet from the eyes (for normal vision), relaxing the accommodation (the pupils meanwhile dilating), and then slightly converging the eyes. Three figures will be seen, of which the central one is stereoscopic. A piece of card of the necessary length extending up vertically from the interspace between the two figures to the nose of the viewer facilitates the operation. The figures must be equally lit while viewing.

end, on to the ilio-pectineal line, which fills in the angle between Poupart and the bone, and which presents a crescentic free border. It should be borne in mind that the ILIO-PECTINEAL LINE runs not merely outwards, but also backwards—out, that is to say, from the plane of a diagram toward the observer—as otherwise this point is apt to lead to confusion. The TRANSVERSALIS MUSCLE arises from the outer one-third of Poupart, while the INTERNAL OBLIQUE arises from the outer half of Poupart, and thus part of both of these muscles is seen. They rise from Poupart, arch over, and then, fusing to form the CONJOINED TENDON, pass almost directly downwards, to be inserted into (a) the crest of the pubes, in front of the rectus

(which, therefore, hides this portion from view), but behind the external oblique; (*b*) spine of the pubes; and (*c*) the first $\frac{1}{2}$ inch of the ilio-pectineal line along with but behind Gimbernat's ligament. Thus, this latter portion of the conjoined tendon does not lie in the plane of a diagram, but projects outwards and backwards from it (see stereogram). The fibres of the transversalis and internal oblique, as just stated, arch above Poupart between their origin from it and their insertion as conjoined tendon, and through this arch the fibres of the EXTERNAL OBLIQUE can be seen, as this muscle arises from the whole extent of Poupart's ligament. But for the external oblique, there would be an aperture through the wall at this point. If the finger be passed through this arch downwards and inwards toward the middle line, between the conjoined tendon and the external oblique, it will lie in the position of the inguinal canal. If we pass the finger still further in, we find that it will emerge on the anterior abdominal wall through the EXTERNAL RING—an aperture in the external oblique situated over the crest of the pubes, which is hidden from view by the conjoined tendon and the rectus, and which therefore will be described later. To complete the inguinal canal, the TRANSVERSALIS FASCIA must be in position. When in position, we find an aperture in it, situated over part of the arch already described, $\frac{1}{2}$ inch above Poupart, and midway between the anterior superior spine and the symphysis. This is the INTERNAL ABDOMINAL RING, and through it the cord passes to enter the inguinal canal. As it does so, it receives from the transversalis fascia a covering, which assists in supporting and suspending the cord in the canal. To this covering the name of INFUNDIBULIFORM FASCIA is given. It is simply a tubular projection of the transversalis fascia, whose mouth is the internal ring. Running upwards along the inner border of the internal ring is the DEEP EPIGASTRIC ARTERY, which has arisen from the external iliac (which lies directly beneath the ring), and is running upwards and inwards to pierce the transversalis fascia, and so enter the sheath of the rectus. This artery forms the outer boundary of a triangle, formed internally by the outer border of the rectus, and below by Poupart's ligament. It is known as HESSELBACH'S TRIANGLE. When a hernia, instead of taking the ordinary course of entering the inguinal canal by the internal ring as the cord does, enters it

through some portion of this triangle, it is called a DIRECT HERNIA, in distinction to the ordinary form which is called OBLIQUE. The neck of a direct hernia lies to the inside of the deep epigastric artery, whereas that of an oblique lies to its outside. Hesselbach's triangle is divided into TWO PORTIONS, an outer and an inner, by the OBLITERATED HYPOGASTRIC ARTERY, which runs upwards from the side of the bladder to the umbilicus. A direct hernia may pass through either of these divisions. When it passes through the portion external to the obliterated hypogastric, it is called an external direct inguinal hernia, and pushes before it a covering of the true transversalis fascia, instead of infundibuliform fascia, as in the case of an oblique hernia. When it passes through the portion internal to the obliterated hypogastric, it is known as an internal direct inguinal hernia, and pushes before it not merely a process of transversalis fascia, but also either perforates or pushes before it a layer of conjoined tendon. When the peritoneum is in position, the inguinal region presents *three fossæ* when viewed from behind: external, external to the deep epigastric; middle, between deep epigastric and obliterated hypogastric; and internal (supravesical), between obliterated hypogastric and urachus. We may next trace the course of an oblique inguinal hernia from the abdomen to the scrotum, see what coverings it receives, and then look at the parts concerned in hernia from the outside. An OBLIQUE HERNIA then first pushes before it a layer of parietal peritoneum (and extra-peritoneal fat), which forms the proper *sac* of the hernia, and then, passing through the internal ring alongside the cord, receives a covering of infundibuliform fascia, which we have already seen is a finger-like projection of transversalis fascia along the cord. The hernia is now in the inguinal canal, with the external oblique to the outside, the transversalis fascia, and, later, the conjoined tendon to its inner side, while Poupart's ligament is below. As the hernia passes down the canal, it receives a covering from the cremasteric fascia (partly cremaster muscle, partly fascia), and then, arrived over the crest of the pubes, it emerges from the canal by the external ring in the external oblique muscle, receiving as it does so a layer of intercolumnar fascia. Its other coverings are the superficial fascia and skin. If now the abdominal wall be examined from the front, it is seen that the external oblique

is fused with the whole length of Poupart's ligament, but that there is an aperture in its insertion into the crest of the pubes—this is the external ring. The EXTERNAL RING is bounded by two pillars, formed of external oblique aponeurosis—an external, which is inserted into the spine of the pubes; and an internal, which is inserted into the symphysis (some fibres crossing to the pubic crest of the opposite side form the *triangular fascia*). These two pillars are bound together above by the *intercolumnar fascia*, which consists of a series of arching fibres which cross from one pillar to the other. Thus the NECK OF AN INGUINAL HERNIA lies inside the spine of the pubes and above the crest of the pubes and Poupart's ligament, whereas the NECK OF A FEMORAL HERNIA lies outside the pubic spine and below Poupart's ligament. An inguinal hernia is called incomplete, or a *bubonocoele*, when it does not enter the scrotum, and is spoken of as complete, or *scrotal*, when it does. In the female it enters the labium when complete, and is called *labial*.

As the anatomical relationships of **femoral hernia** are closely allied to those of inguinal, it will be well to study these now, although, anatomically, they belong to the thigh. Looking once more at the internal surface of the abdominal wall, it has been seen that the TRANSVERSALIS FASCIA forms the innermost covering—if we except the peritoneum from which it is separated by extraperitoneal tissue—and that it is attached externally to the inner lip of the iliac crest and outer half of Poupart's ligament, while internally it is attached to the iliopectineal line along with Gimbernat's ligament. Between these attachments, however, the fascia turns under Poupart's ligament, to be continued into the thigh as the ANTERIOR PORTION of the SHEATH OF THE FEMORAL VESSELS. The POSTERIOR PORTION of the femoral sheath is formed by the FASCIA ILIACA, which, descending in front of the iliacus muscle, fuses both externally and internally with the fascia transversalis at the insertions mentioned, but separates from it between these points to permit of the passage of the vessels which it accompanies into the thigh. Were the sheath thus formed just of sufficient size to accommodate the vessels, the possibility of femoral hernia occurring would be slight. As a matter of fact, however, the sheath is divided into THREE COMPARTMENTS, the outer of which contains the artery,

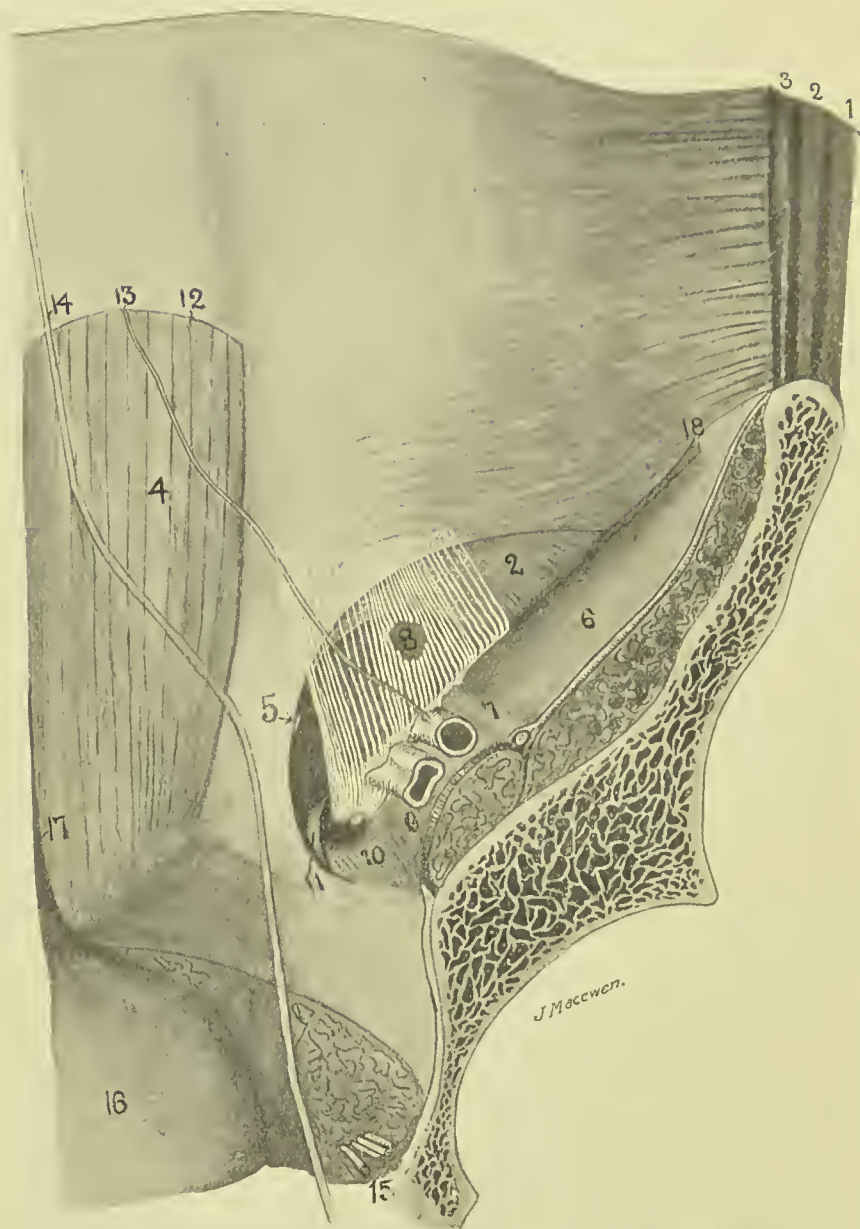


FIG. 22.—DIAGRAM OF ABDOMINAL WALL FROM BEHIND.

1. External oblique.
2. Internal oblique.
3. Transversalis.
4. Rectus.
5. Conjoined tendon, with indicator to tip of external ring.
6. Iliac fascia covering iliopsoas muscle.
7. Iliac fascia covering anterior crural nerve, external iliac artery to its inner side.
8. The internal ring, an opening in the fascia transversalis, a small portion of which is shown in white.
9. Iliac fascia covering psoas muscle; external iliac vein above it.
10. Pectineus muscle, with crural canal above it (formed by transversalis and iliac fascia).
11. Gimbernat's ligament.
12. Semilunar fold of Douglas.
13. Deep epigastric artery.
14. Obliterated hypogastric artery.
15. Obturator vessels.
16. Bladder.
17. Urachus.

the middle the vein, while the inner forms the **femoral or crural canal**, and it is through this latter inner compartment that the femoral hernia makes its way to the thigh. As it does so, it pushes before it parietal peritoneum, and then a covering of SEPTUM CRURALE—a layer of extraperitoneal tissue, which covers the ring, or mouth, of the canal. Its relations here are—Poupart's ligament above and in front; the bone, covered by pectineus muscle and fascia lata below and behind; Gimbernat's ligament to the inside, and the femoral vein to the outside. The deep epigastric artery lies just above and outside the ring, and gives off a small pubic branch, which frequently runs down along the inner border of the crural ring. In about 3 per cent. of cases the OBTURATOR ARTERY from the external iliac is absent, and then this pubic branch of the deep epigastric enlarges to take its place, passing round the inner (and sometimes the outer) border of the ring to gain the obturator foramen. Were it necessary in such a case to notch Gimbernat's ligament for the relief of a strangulated femoral hernia, this abnormal vessel might be cut, and several cases of fatal *hæmorrhage* from such an accident have been recorded. This pubic artery, or *aberrant obturator* as it is called when enlarged in the manner described, is accompanied by the pubic vein which communicates between the obturator and external iliac veins. The femoral, or crural canal, is funnel-shaped, and only extends about $\frac{1}{2}$ inch down the thigh, terminating under the saphenous opening of the fascia lata of the thigh, which must next be described. The FASCIA LATA splits at its upper end into two portions, an outer, or iliac, and an inner, or pubic, which overlap one another to form the oval SAPHENOUS OPENING. The outer, or iliac, portion is the more superficial, lying in front of the femoral sheath, and is inserted above into the iliac crest and Poupart's ligament. The inner fibres of this iliac portion are strongly developed, and arch upwards and inwards, to be inserted into the inner half of Poupart, forming what is known as the *falciform ligament*, while their free concave margin constitutes the *superior cornu* of the saphenous opening. If the margin of this superior cornu be followed downwards, it is seen to sweep round the lower margin of the saphenous opening, thus forming its *inferior cornu*, and then to run up the thigh again as the outer margin of the pubic portion, this

time extending upwards and outwards beneath the sheath of the vessels, and in front of the pectineus and adductor longus, to be inserted into the ilio-pectineal line along the insertion of Gimbernat's ligament, and into the capsule of the hip-joint. The saphenous opening thus formed is covered by a special thin perforated lamina, which is known as the *cribriform fascia*, and which is perforated by the *internal saphenous vein*, which dips in here to join the femoral vein. A femoral hernia, then, on reaching the lower extremity of the short femoral canal, turns forwards, carrying a covering of cribriform fascia before it as it does so, and presents under the skin and superficial fascia. A curious point is that, as femoral herniæ come forward, they also tend to turn upwards over Poupart's ligament, thus making MISTAKES IN DIAGNOSIS between femoral and inguinal herniæ possible. Of course, the neck of a femoral hernia is below Poupart, and external to the spine of the pubes. Various reasons have been adduced to explain this upward tendency. The unyielding character of the saphenous cornua and the traction upon the mesentery are probable causes. The femoral canal is rendered most lax when the thigh is flexed, adducted, and rotated inwards, a point to remember in applying TAXIS, when it should also be recollected that the sharp unyielding edge of Gimbernat's ligament is frequently the constricting cause, and may wound the bowel if undue force is exercised. Both *bladder and ovary* form occasionally the contents of femoral herniæ.

A less common form of hernia is the OBTURATOR, in which the bowel, pushing the parietal peritoneum, extraperitoneal fat, and pelvic fascia before it, passes downwards, forwards, and inwards through the *obturator canal*, where it may remain under the obturator externus, or, perforating or going to one side of this muscle, may present under the pectineus, behind and to the inner side of the femoral vessels, and about a finger-breadth beneath the position of exit of a femoral hernia. The obturator vessels and nerve are generally to the outer side of the sac, and pressure on the nerve may occasion pain on the inner side of the thigh, and on moving the hip-joint. This form of hernia occurs most frequently in females, and while it generally consists of bowel, may contain bladder or ovary. The hernia is generally small, and may produce no external swelling even when strangulated. In such cases pain on

the inner side of the femoral vessels and inner aspect of the thigh may assist the diagnosis, while the inner aspect of the canal may be examined per vaginam in the female, or per rectum in the male, and the hernia possibly even reduced in this manner. In *operating* for obturator hernia a vertical incision is made midway between the femoral vein and pubic spine, the fascia lata divided, and the interval between the pectineus and adductor longus defined. The muscles are separated, the pectineus being partially divided if necessary with great care, and the hernia exposed and treated. Cutting to relieve strangulation must always be done with care, as the relation of the vessels to the sac varies.

In order to more fully explain certain forms of inguinal hernia, and as an introduction to the study of the abdominal cavity, it is necessary to turn shortly to the relationship of the peritoneum to the abdominal viscera, and to the descent of the testicle. The PERITONEUM, then, is a shut sac, which has no contents, but whose walls are capable of great invagination. We may imagine this closed sac (or balloon) placed in the abdominal cavity, after which the viscera to obtain room would require to push the sac wall before them, and in so doing would receive a covering from it. Thus, a loop of bowel projects itself into this hollow sac, and in so doing receives a covering of peritoneum—its *serous layer*—while the track of its projection is lined by a double layer of peritoneum—the *mesentery*—in which the vessels to supply the bowel with blood, etc., run. Unfortunately, however, the covering of peritoneum which the invaginating portion of bowel receives is not taken into account when speaking of various peritoneal layers, but is simply spoken of as the serous coat of the bowel itself. Thus, to get at the bowel through an abdominal incision, we only cut the *parietal peritoneum*; the various loops of bowel then present, but each is covered by its serous layer of peritoneum, which we neglect to regard as such. The *testicle* in the foetus is an abdominal organ, situated at the lower end of the kidney. Thus, like the other viscera, it is outside the peritoneum, and, like the kidney, it is only partially covered by it. The testicle gradually descends from this position (pulled, it is supposed, by a foetal structure called the *gubernaculum*), until at birth it occupies the scrotum, having descended through the inguinal canal. In its descent it drags

out a finger-like process of peritoneum with it (this, then, is an evagination, and not an invagination), which forms an open peritoneal canal running through the inguinal canal,

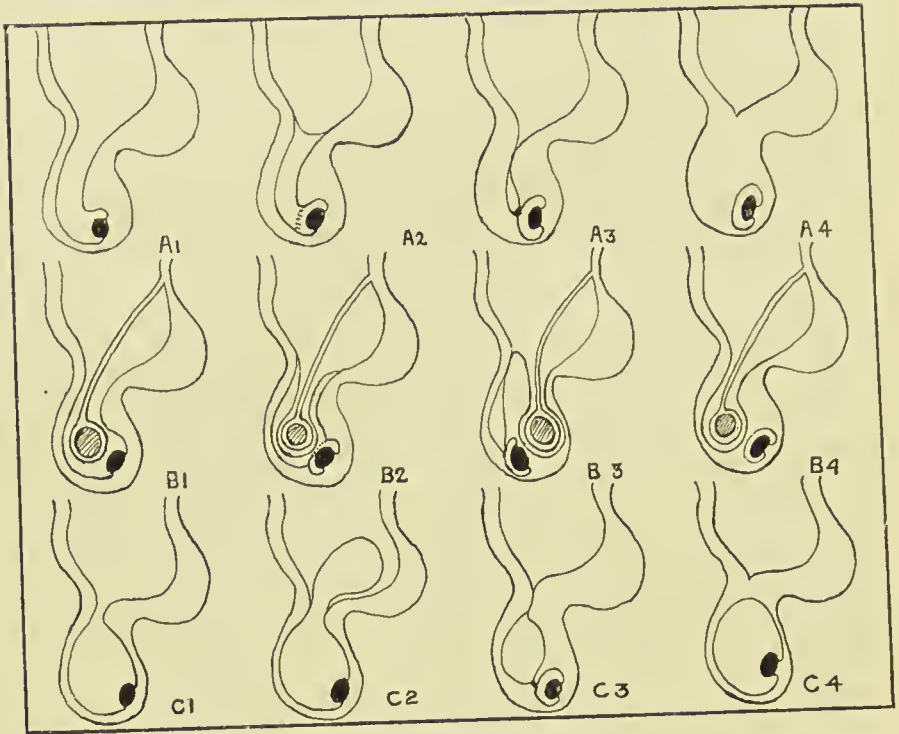


FIG. 23.—DIAGRAM ILLUSTRATING THE DEVELOPMENTAL OBLITERATION OF THE FUNICULAR PROCESS (SERIES A), AND THE FORMS OF INGUINAL HERNIA (SERIES B), AND HYDROCELE (SERIES C) WHICH MAY ARISE THEREFROM.

SERIES A.—NORMAL DESCENT OF TESTICLE.

1. Funicular process entirely open (congenital).
2. Funicular process closed by septum at internal ring, and partially so at junction with tunica vaginalis (infantile).
3. Funicular process closed both above and below (infantile).
4. Funicular process entirely obliterated (adult).

SERIES B.—DEVELOPMENTAL VARIETIES OF INGUINAL HERNIA.

1. Congenital (one layer of peritoneum to cut through).
2. Infantile (encysted) (two layers of peritoneum to divide).
3. Infantile (possibly three layers of peritoneum to divide; testicle in front).
4. Adult (one layer of peritoneum to divide).

SERIES C.—DEVELOPMENTAL VARIETIES OF HYDROCELE.

1. Congenital.
2. Infantile—bilocular; scrotal, and intra-pelvic.
3. Infantile—encysted of cord.
4. Adult of tunica vaginalis.

called the FUNICULAR, OR VAGINAL, PROCESS, the inner end of which opens into the general peritoneal cavity, while the outer expanded end is closed, and partially invests the testicle.

This is the condition of affairs at birth, and a hernia may come down through this patent peritoneal canal into the scrotum. This would constitute a CONGENITAL HERNIA, the bowel (covered by its serous coat) would be in contact with the testicle (covered by its serous coat), and there would only be one layer of peritoneum between it and the outer coverings. Similarly the lower portion of this canal may distend with serous fluid, which may reach it from the abdominal cavity, with which it freely communicates, and form a CONGENITAL HYDROCELE. Soon after birth, in a normal case, this patent funicular process becomes obliterated, leaving the lower end, however, to form the TUNICA VAGINALIS of the testicle, which thus becomes entirely separated from the peritoneum. The obliteration of the funicular process commences usually at the internal ring, and a little later just above the epididymis, septa forming at these points. If the intervening portion of the process becomes distended with fluid, an (infantile) ENCYSTED HYDROCELE OF THE CORD is formed. On the other hand, bowel may enter the unobliterated portion from the abdomen, pushing the upper septum before it. Such a form of hernia is called an ENCYSTED INFANTILE HERNIA. In it the bowel is quite separate from the testicle, and is enclosed by two peritoneal layers (counting the stretched septum as one, but not reckoning the serous coat of the bowel). Again, a hydrocele may form in the common funicular process and tunica vaginalis, and push the septum at the neck of the process before it into the abdomen, forming an infantile *bilocular hydrocele*. In another form of INFANTILE HERNIA the bowel does not come down into the funicular process, but comes down behind it, pushing a layer of parietal peritoneum before it as it does so, or taking advantage of a peritoneal diverticulum, which Lockwood states occurs in that position from the action of the gubernaculum. Here, also, the bowel is quite apart from the testicle, and in operating from the front three layers of peritoneum require to be cut through before the serous coat of the bowel is reached. Although these forms of hernia and hydrocele are called congenital and infantile, they do not necessarily occur at birth or in infancy, but may occur in after life. Sometimes the testicle does not descend into the scrotum until some years after birth, but the funicular process may do so notwithstanding, and along it a

congenital hernia may descend. The inguinal canal in the fœtus is relatively shorter than in the adult, while in the female it is rather longer but narrower than in the male.

In the female the canal is occupied by the round ligament, along which a process of peritoneum, called the CANAL OF NUCK, descends in the fœtus for a short distance. A congenital form of inguinal hernia in the female may occur into this sac. It should be remembered that inguinal hernia is by no means uncommon in women, and that femoral hernia is frequently met with in men, although, as a rule, perhaps inguinal hernia is more common in men and femoral in women. Where a hernia is STRANGULATED by some constricting band about the inner opening of the peritoneal sac, it is frequently necessary to make a slight cut in the band in order to relieve the constriction. In the case of inguinal hernia, the blade of the knife should generally be directed upwards and outwards so as to avoid the deep epigastric artery, while in femoral hernia it should be directed upwards and inwards so as to keep clear of the femoral vein, and in acquired umbilical hernia directly upwards.

A RICHTER'S HERNIA is one in which only a portion of the circumference of the bowel is in the sac. Some apply the term *Littre's hernia* to the same condition, or to a hernia of a small knuckle of bowel, or of a diverticulum.

With regard to the OPERATIVE TREATMENT OF INGUINAL HERNIA, many methods of dealing with the sac and of closing the inguinal canal have been devised. In children simple ligature of the sac as far up as possible has been found to yield good results. In adults the sac is variously removed, drawn to some abnormal position, or placed as a pad on the inner surface of the abdominal wall, with the object of obliterating the funnel-shaped orifice of the canal, which may be said to 'tempt' the hernia (Macewen). With the object of further removing 'temptation,' redundant omentum is generally removed, as omentum frequently opens out the path for bowel to follow. In this connection also it may be said that abnormal length of mesentery is generally looked upon as a predisposing cause of hernia. The closure of the canal is generally accomplished by drawing the arching conjoined tendon down behind Poupart's ligament, and stitching up the external ring (Macewen), which latter in many operations is first slit up to give

easier access to the conjoined tendon (Bassini). The cord is variously treated, being left at the inner side of the portion of conjoined tendon which has been pulled down (in which case it occupies a small natural channel, which cannot be obliterated owing to the vertical direction of the conjoined fibres at that point, and so is relieved from pressure) (Macewen), or brought out at the position of the internal ring, and then passed between the stitched conjoined, and external oblique (Bassini), or even taken out to the anterior superior spine by others (Halsted).

In FEMORAL HERNIA there is less tendency to recurrence if care be taken to invaginate or otherwise treat the sac so as to remove its gaping mouth. Some have tried to obliterate the canal by turning up a flap of pectineus and its fascia over the mouth of the canal, and attaching it above to Poupart's ligament (Cheyne), while others seek to do so by suturing the tense ligament down to the subjacent bone.

Before leaving the subject of hernia some of the rarer forms may be mentioned. In *pudendal hernia* the bowel descends between the ascending ramus of the ischium and the vagina to the posterior portion of the labium. In *perineal hernia* it perforates the anterior fibres of the levator ani, and appears between the prostate and rectum, carrying the recto-vesical (and anal) fasciæ before it. A *sciatic hernia* passes through the great sacro-sciatic notch, and appears under the gluteus maximus. A *lumbar hernia* presents through the triangle of Petit between the latissimus dorsi and external oblique, just above the highest point of the iliac crest, and in front of the quadratus lumborum, and either carries before it or perforates the fascia lumborum and internal oblique. *Diaphragmatic hernia* is most usually congenital, occurring through some developmental defect, and is more common on the left side owing to the presence of the liver on the right, passing through connective tissue intervals between sternal and costal origins of the diaphragm in front; or vertebral and costal origins behind; or the oesophageal foramen. It does not invade the aortic or vena caval foramina. The stomach, or transverse colon, forms the most common contents of the protrusion.

THE ABDOMINAL CAVITY.

The **peritoneum** is a single closed serous sac, composed of a thin fibrous layer, lined on its inner surface with endothelium. This closed sac is divided into two portions—a greater sac and a lesser sac—by a constricted neck (called the foramen of Winslow), through which the two portions communicate. This neck is twisted, so that the small sac lies behind the great sac; and below the level of the stomach, which separates them, the great sac is invaginated by a process of the small sac, the two together (invaginated and invaginating) forming the *great omentum*. This sac has no contents, the various surfaces being practically in contact, save for a little serous fluid which lubricates them, and renders the free movements of the viscera possible. The **GREATER SAC** lines the greater part of the abdominal cavity. That portion lining the anterior abdominal wall is comparatively smooth and free from interruption, whereas that lining the posterior abdominal wall is thrown into folds by the various viscera which, carrying it before them, project into and completely fill the abdominal cavity, and thus, so to speak, obliterate the cavity of the peritoneal sac. The **ABDOMINAL VISCERA** are either *fixed directly* by connective tissue to the posterior abdominal wall, or are *suspended from it* by bloodvessels. Where viscera are **FIXED DIRECTLY** to the posterior abdominal wall, the peritoneum is generally pushed before or invaginated by them, the reflections of the peritoneum from the abdominal wall to a viscus being frequently termed *ligaments*. The organs vary very much in the extent to which they are covered by peritoneum, the spleen having a very complete coat, while the kidney and pancreas have only partial coats, it being possible, therefore, for *abscesses* in connection with these latter organs to discharge externally without involving the peritoneal cavity. In this connection it is interesting to note that while the interior of the peritoneal cavity is very prone to microbic infection, the exterior is very resistant, and this holds true even of the serous peritoneal coat of bowel, etc. Thus, a large pelvic abscess may fail to cause peritonitis, and a perforating ulcer of the appendix may find its progress stopped by the thin serous layer. As an example of the **SUSPENDED TYPE** of viscus the bowel may be taken. It is projected into the

abdominal cavity, invaginating the posterior layer of the peritoneal sac, and carrying a visceral layer of peritoneum before it, which is then considered as the serous coat of that viscus, and is no longer spoken of as the peritoneum. Covering over the various branches of the bloodvessels, which, arising from the aorta, run forwards to supply the bowel, is a double layer of invaginated peritoneum, which is called the **MESENTERY**. Thus it will be understood that all viscera lie outside the cavity of the peritoneum, which forms a covering for all the viscera which are projected into it. There is one exception to the statement that the peritoneum is a closed sac—the Fallopian tubes open into it.

The **FORAMEN OF WINSLOW**, through which the greater sac communicates with the less, is situated below and behind the portal fissure of the liver, while the first part of the duodenum and hepatic artery lie below it. Owing to a twist at the foramen of Winslow, the **SMALL SAC** is situated behind the large one, and occupies the space between the posterior wall of the stomach and the posterior abdominal wall. Above this point it extends upwards between the liver and abdominal wall, but while crossing from the upper border of the stomach to the under surface of the liver its anterior wall comes in contact with the posterior wall of the great sac (which comes up over the anterior surface of the stomach to extend to the liver), and these two layers together are called the **LESSER OMENTUM (GASTRO-HEPATIC OMENTUM)**. Below the stomach the lesser sac invaginates the greater sac, and thus we have extending from the lower border or greater curvature of the stomach a double layer of peritoneum, the descending portion being composed of an anterior layer of great sac and a posterior of lesser sac. This double layer extends down a variable distance in front of the other viscera, and then, turning on itself, runs up again, the ascending and descending layers being in close contact with one another. When the two ascending layers meet the transverse colon, they split to enclose it, but again unite to form what is called the **TRANSVERSE MESOCOLON**. The long process, composed of layers of both sacs, is called the **GREAT OMENTUM (gastrocolic)**. It forms an apron in front of the small intestine of very variable length, is generally loaded with fat, and is of considerable importance surgically. Thus, a very long omentum is generally considered a predisposing, if

not actual, cause of *hernia*, as it is frequently found to precede the appearance of the bowel, not infrequently forming an *omental sac* over the bowel, which may thus be said to be 'encouraged' by the omentum forming a path for it. Sometimes also a hernial protrusion contains only omentum, no bowel being present (*epiplocele*). Lockwood states that under the age of forty-five the omentum can rarely be drawn down below the pubic spine, whereas in later years it can be. Venous

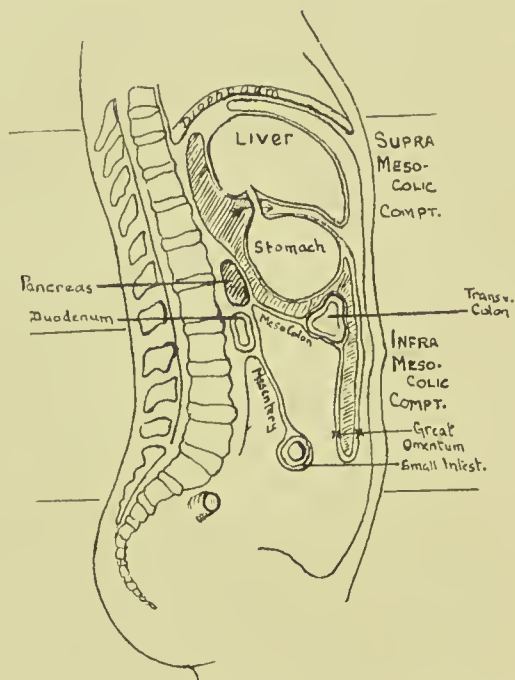


FIG. 24.—DIAGRAM OF PERITONEUM, ITS SACS AND FOLDS.

Lesser sac is shaded. Arrow through foramen of Winslow. Note how transverse colon with its mesocolon forms a diaphragm dividing the abdominal cavity into supra- and infra-mesocolic compartments, the stomach occupying the former and the small intestine the latter.

congestion frequently produces great increase in the size of a herniated *omental mass*, and the same cause occasionally produces a *varicose condition* of its veins, the mass therefore simulating varicocele. On the other hand, omentum has a very definite effect upon *inflammatory affections* of the abdominal cavity. In many cases it takes a large share in walling off suppurative processes, and thus protecting the general peritoneal surface from infection. In some cases the extremity

of the omentum may become adherent to some of the pelvic organs, and subsequently, owing to movements of the intestine, may become twisted into a rather *tense cord*, under which a loop of bowel may become strangulated. Bowel may also become strangulated by passing through an *aperture* in the mesentery or omentum. Where any structure becomes adherent to the omentum, it may derive a large proportion of its *blood-supply* from it. This may occur in the case of the sac of an omental hernia; in ovarian tumour, with twisted pedicle, etc. In *abdominal wounds* the omentum may protrude, block up the opening, and so prevent the escape of blood.

It has been stated above that the stomach is interposed between the two sacs, the great sac lying in front and the smaller behind. This relationship of the posterior wall of the stomach to the lesser sac is a point of much surgical importance, as, when a *gastric ulcer* ruptures on the posterior wall, it opens into the lesser sac, and the escaping contents are much circumscribed, adhesions generally forming rapidly, which limit the process; whereas, when the rupture occurs on the anterior wall the large anterior sac and contained viscera are very apt to be affected, adhesions occurring here much less readily.

The **STOMACH** lies in the supramesocolic compartment of the abdomen, almost entirely to the left of the middle line, occupying a space immediately under the left dome of the diaphragm and left lobe of the liver, and extending down into the epigastric region. The space which it occupies, and to a less extent its relations, vary greatly according to its state of distension. The **CARDIA**, or junction between the œsophagus and the stomach, is the most fixed point, and is situated deeply, about 4 inches behind and 1 inch outside the junction of the seventh left costal cartilage with the sternum, about the level of the eleventh dorsal vertebra. From this point the **LESSER CURVATURE**, or upper and right border, curves round the spine downwards, forwards, and to the right to the pylorus, giving attachment above to the *lesser, or gastro-hepatic, omentum*. The **GREATER CURVATURE** is at first directed backwards and upwards, forming an angle with the cardia, and then sweeps round, to run from left to right, and slightly forwards and downwards, and finally it runs up to the pylorus.

It gives attachment to the *great omentum*, and on the left to the *gastro-splenic omentum*. The *level* of the greater curvature varies greatly, according to the amount of distension, and it carries with it the *transverse colon*, which lies in close relationship to it. When not distended, it generally corresponds to a

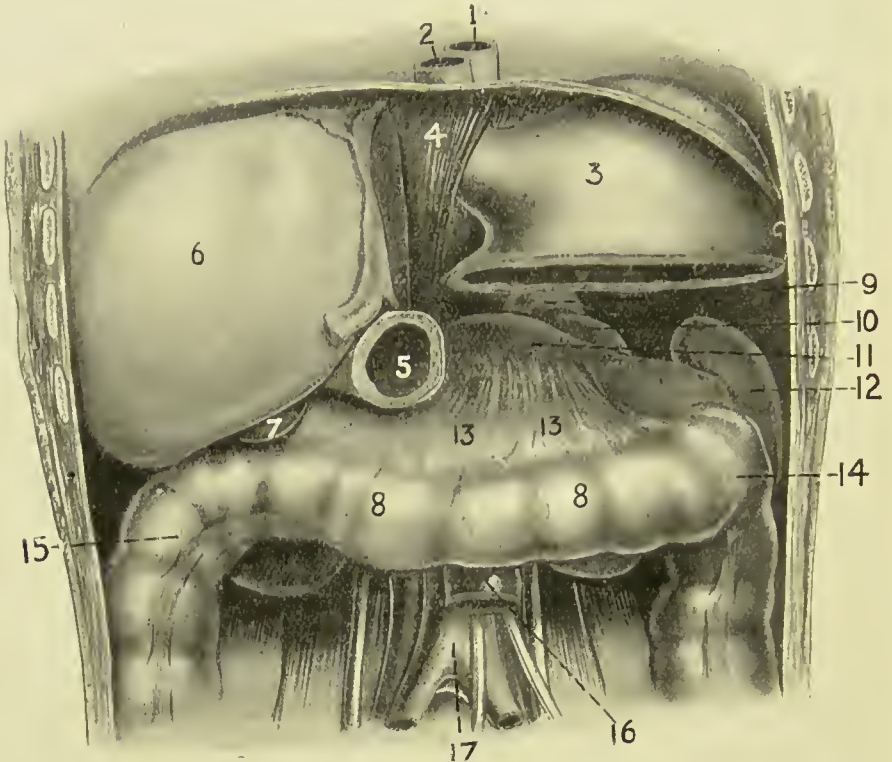


FIG. 25. — THE SUPRAMESOCOLIC COMPARTMENT OF THE ABDOMEN. PORTIONS OF STOMACH AND LIVER HAVE BEEN REMOVED TO DISPLAY THE DIAPHRAGM FORMED BY THE TRANSVERSE COLON AND MESOCOLON WITH KIDNEY, SPLEEN, AND PANCREAS.

- | | | |
|-------------------------|----------------------|--|
| 1. Aorta. | 7. Gall-bladder. | 13. Transverse mesocolon (forming shelf or diaphragm). |
| 2. Esophagus. | 8. Transverse colon. | 14. Splenic flexure. |
| 3. Stomach. | 9. Suprarenal. | 15. Hepatic flexure. |
| 4. Diaphragm. | 10. Kidney. | 16. Duodeno-jejunal junction. |
| 5. Pylorus. | 11. Pancreas. | 17. Descending aorta. |
| 6. Right lobe of liver. | 12. Spleen. | |

horizontal line, joining the tips of the tenth costal cartilages. This greater curvature sometimes presents a **DISTINCT NOTCH**, which indicates the division between the body of the stomach and the pyloric portion. The expanded portion of the stomach which lies to the left of the cardia is called the **FUNDUS**, and its highest point lies beneath the diaphragm just above and

inside the apex of the heart. The portion lying between fundus and pylorus is called the BODY. The PYLORIC END of the stomach is more movable than the cardiac, and varies in *position*, according to the amount of distension of the stomach. Generally it lies about $\frac{1}{2}$ inch to the right side of the mid-point between the suprasternal notch and symphysis, or $2\frac{3}{4}$ inches above the umbilicus, being situated below and anterior to the cardia. It is described as consisting of a wider *antrum*, or *vestibule*, to the left, and *canal* on the right, leading up to the valve. The pyloric valve is marked on the surface by a slight constriction, is directed from before backwards, and lies upon the neck of the pancreas with the liver above it, and the gall-bladder on its right.

The stomach may be said to occupy a *wedge-shaped space* (supramesocolic compartment of the abdomen), with rounded angles at the base; the apex, situated on the right side, being formed by the junction of the liver and the transverse colon. Above, from left to right, are the diaphragmatic dome, and then the left lobe of the liver sloping down to the right to meet the colon. Below lie the spleen behind and to the left, and more to the front the upper surface of the pancreas, while the left suprarenal and kidney fill a slight interval between the two posteriorly. In front of the pancreas are the transverse mesocolon and transverse colon. Thus a FLOOR is formed for the stomach of spleen, kidney, and pancreas behind, with transverse mesocolon and colon in front, these latter structures forming almost a DIAPHRAGM, separating the stomach above in the supramesocolic compartment from the underlying small intestine in the submesocolic compartment. The base of the wedge, situated on the left side, is formed by the spleen and the diaphragm. This space is closed in, in front, by the diaphragm, the fifth to the eighth ribs and the costal cartilages, and a portion of the anterior abdominal wall and of the liver.

The whole BLOOD-SUPPLY of the stomach, which is very abundant, is derived directly or indirectly from the *cæliac axis*. The *coronary artery* arises from it directly, and runs along the lesser curvature to join the pyloric branch of the hepatic. The arch thus formed gives off several large branches. On the greater curvature an arch is formed by the *gastroduodenal* of the hepatic giving off the right, and the splenic giving off the left *gastro-epiploic* arteries, which vessels freely anasto-

mose, and, in addition to the vasa brevia from the splenic, supply branches to the stomach wall. The coronary and the pyloric vein join the portal trunk; the right gastro-epiploic joins the superior mesenteric, the left the splenic, along with the vasa brevia veins.

The LYMPHATICS run to the superior and inferior gastric glands, situated along the lesser and greater curves respectively, and the splenic, and finally join the cœliac glands.

The NERVE-SUPPLY is from the *pneumogastrics*, the left lying on the front, and the right on the posterior surface of the œsophagus, and then reaching the upper and lower stomach surfaces respectively, which they supply after joining with the sympathetic fibres of the *cœliac plexus*. The sympathetic nerves are associated with the *seventh and eighth spinal segments*, and thus in stomach diseases the skin supplied by these segments may become tender or even painful, pain being complained of below the angle of the scapula.

Not infrequently the stomach may be found to be abnormally contracted or dilated. CONTRACTION is generally met with in cases of stricture of the œsophagus, where it may occur to such an extent as to render certain operations almost impossible. Also on account of its small size, and the fact that the transverse colon frequently ascends in front of it, it may be difficult to find after the abdomen has been opened. In such cases it is advisable to run the finger upwards and backwards until the under surface of the liver is reached, and then push forwards the structure in front of it. In cases of contraction the pylorus generally lies almost in the middle line. When the stomach DILATES, the fundus pushes the diaphragm upwards, and thus sometimes causes *faintness* in flatulent distension from actual pressure on the heart. The body of the stomach also ascends while the greater curvature comes forwards, displacing the colon and small intestines downwards. The pyloric segment is displaced further to the right, and becomes markedly curved. Acute or chronic dilatation may arise from a variety of causes, such as pyloric obstruction (stenotic gastrectasis) and atony of the muscular coats (atonic gastrectasis), etc. As a rule, there is first a period of muscular hypertrophy, but this is generally followed by atrophy, after which the stomach may become very large,

pressing upwards on heart and lungs, causing palpitation and dyspnoea, while below it may reach almost, if not quite, to the pubis (ptosis). The pylorus also becomes dragged down, so as to be *palpable* in some cases through the abdominal wall.

The stomach is frequently affected by *ULCERS*, which occur most often on the *posterior wall* toward the lesser curvature, but may occur at any part, and which also very frequently affect the pylorus and duodenum. Such ulcers may be chronic, and beyond causing occasional hæmorrhage by involving some of the larger vessels in the mucous or sub-mucous coats, may not call for surgical interference. In healing they frequently cause considerable contraction, which, when situated in the body of the stomach, may give rise to an *hour-glass deformity*, or, when situated over the pylorus, may cause pyloric obstruction. In other cases the ulcer may be very acute, and rapidly proceed to *perforation*, and if this occurs on the *anterior surface*, general peritonitis is set up. Where, however, the ulcer is situated in its more usual site on the posterior wall, adhesions generally form, which tend to limit the process, and even if rupture does occur, the contents are discharged into the lesser sac, to reach which it is generally best to lift forward the transverse colon, and perforate the transverse mesocolon.

Adhesions may take place between the stomach and other abdominal organs or diaphragm. The former may lead, if the ulcer progress, to involvement of some large vessel, even apart from those of the stomach, such as the splenic artery or portal vein, and cause death from *hæmorrhage*. The latter may occasion *septic affections* of the pleuræ or pericardium, the septic matter traversing the lymphatics which penetrate the diaphragm, and sometimes the lungs or even the heart may become affected. Adhesions, by limiting the general spread of septic infection, may give rise to a localized abscess. In this way *subphrenic abscesses* may arise between the stomach and left lobe of the liver below and diaphragm above, or an abscess may arise between stomach and liver.

Carcinoma most frequently affects the pyloric region, and, as a rule, is not palpable until so far advanced as to render radical operation impossible. Where carcinoma affects the œsophagus, the operation of *gastrostomy*

is frequently performed, a portion of stomach being drawn up through the rectus muscle, and sutured to the skin. After the wound has healed the stomach is opened, a tube passed in, and the patient fed through it. The rectus abdominis acts as a sphincter, preventing ejection of food, and to enhance this effect the portion of stomach is generally bent at an angle as it comes through the rectus, and is finally brought out to a new small skin incision over the margin of the ribs, the first wound being stitched up. *Gastrostomy*, or simple incision of the stomach, may be required for treatment of an ulcer, removal of a foreign body, etc. *Gastrectomy* consists of the removal of a portion or the whole of the stomach. Even the latter operation has been repeatedly successful.

Wounds of the stomach, particularly if inflicted when it is distended with food, generally cause profound collapse and death, with general acute peritonitis from escape of the contents. Where, however, the stomach is empty, and where the wound is of a punctured nature, as from a rifle-bullet, the patient may, once he gets over the preliminary shock, make an uninterrupted recovery. It is supposed that in such cases the mucous membrane projects and forms a plug, closing the wound.

The PYLORIC VALVE, by means of its sphincter muscle, controls the passage of food from the stomach into the intestine, preventing, as a rule, the passage of food until after the peptic digestion has taken place. It is apparently irritated by very acid stomach contents, at such times becoming almost entirely closed, and, at the close of normal peptic digestion, it permits of the passage of food only in very small quantities at a time, so that they may be thoroughly acted on by the bilious and pancreatic juices. The valve then apparently plays an important function in the digestive process, but not infrequently it become *constricted* from chronic irritation, ulcerative contraction, or carcinomatous tumour, rendering operative treatment necessary. It also is occasionally constricted *congenitally* by a form of tumour which also causes lengthening, and is generally fatal unless promptly recognized and treated. Normally, the pylorus should admit the passage of the forefinger, but even forks and keys have been known to pass through it. Needles,

when swallowed, appear to make their way through the wall of the stomach, and may eventually project through the skin.

Where the contraction of the pylorus is non-malignant, the operative treatment may consist of performing a *pyloroplasty*. Here a longitudinal incision is made through all the coats, the central points of the upper and lower margin of the incision are caught by forceps, and pulled apart until the wound, from being longitudinal, becomes vertical, and then the wound is sutured in the new position. Thus a long and narrow pylorus is converted into a short and wide one. The advantage of this operation is that the pyloric valve, and also the bile and pancreatic ducts, are not disturbed in their relationship to food. Forcible dilatation of the pylorus, either through an incision through the stomach wall or by invaginating the wall, is dangerous, and has been almost discarded.

In carcinoma of the pylorus the whole pylorus may be removed (*pylorectomy*), and the upper end of the duodenum attached to the pyloric end of the stomach, which is narrowed to fit it. For pyloric stenosis some prefer the operation of *gastrojejunostomy*, and, of course, this operation is called for where the pylorus is the seat of an inoperable carcinoma. The object of this operation is to make a communication between the stomach, lying above the transverse colon and mesocolon, and the jejunum lying beneath. The abdomen having been opened, the great omentum and transverse colon are turned up, and the duodeno-jejunal junction sought for to the left of the spine between the mesocolon and mesenteric attachment. A portion is selected, a few inches beyond the junction to which the ligament of Treitz (*q.v.*) forms a valuable guide, and may either be carried in front of the colon to be attached to the anterior wall of the stomach (anterior gastro-jejunostomy), or the transverse mesocolon is perforated, the posterior wall of the stomach exposed, and the junction made at this point. The latter operation is probably the better, regurgitation of food and vicious circle being less apt to be established. To obviate regurgitation, some recommend that the jejunum must be so placed that its direction of peristalsis shall correspond with that of the stomach, while others recommend that the bowel be entirely divided, the distal end being stitched to the stomach

opening, and the proximal portion being opened into the distal some distance below the junction with the stomach.

The **DUODENUM** is described in three sections, the whole being nearly a foot in length, and describing a rough circle, or sometimes being of a **U** or **V** shape, with the apex downwards. It has been suggested that it acts as a kind of syphon-

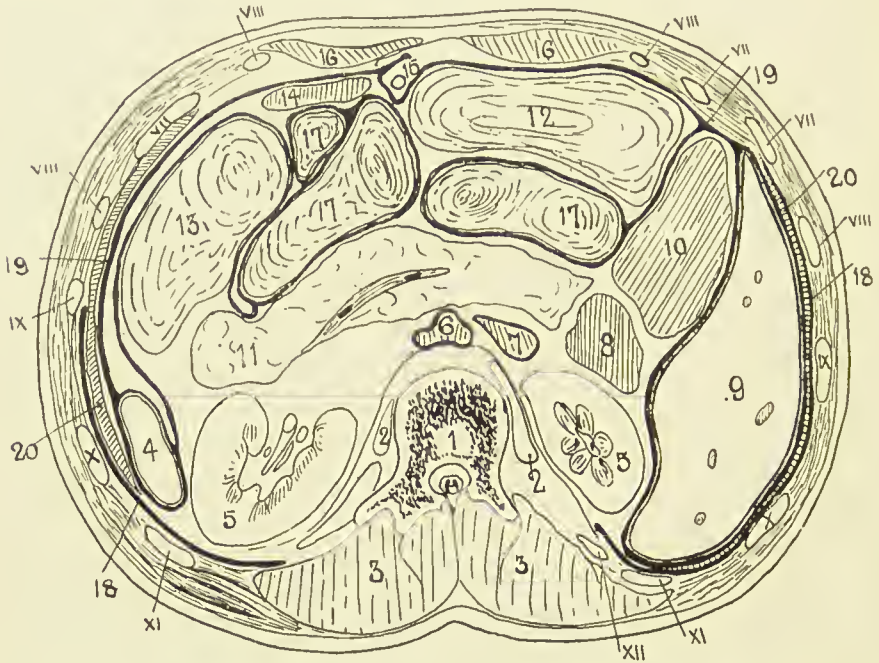


FIG. 26.—TRANSVERSE SECTION OF THE ABDOMEN AT THE LEVEL OF THE FIRST LUMBAR VERTEBRA.

(After Braune.)

1. First lumbar vertebra.
2. Psoas muscle.
3. Erector spinæ, etc.
4. Spleen.
5. Kidney.
6. Aorta.
7. Vena cava.
8. Duodenum.
9. Liver.
10. Ascending colon.
11. Pancreas, containing splenic vein.

12. Transverse colon.
13. Splenic flexure and descending colon.
14. Stomach.
15. Round ligament of liver.
16. Rectus abdominis.
17. Small intestine.
18. Pleura.
19. Peritoneum.
20. Diaphragm.

Roman numerals indicate ribs.

tap, to prevent regurgitation of gases into the stomach. It is wider than the jejunum, and only the first part is movable, and that slightly. The **FIRST** is 2 inches long, and passes horizontally backwards and to the right on the level of the first lumbar vertebra to near the upper end of the right kidney. It is wider in the centre than at either extremity, the dilated

portion being called the *duodenal antrum*. The quadrate lobe of the liver and gall-bladder are above it, and the neck of the pancreas below it. At the junction of the first and second portions is the *superior duodenal flexure*. The SECOND STAGE, about 3 inches long, descends in front of the inner border of the right kidney to the level of the third lumbar vertebra, and ends at the inferior duodenal flexure, where it joins the third portion. This *inferior flexure* is the lowest portion of the duodenum, and sometimes forms a considerable pouch. In front it is related to the transverse colon above and the small intestine below, and behind lie the kidney and renal vessels and right border of the inferior vena cava. The *bile and pancreatic ducts* open on a common papilla on the posterior and inner wall near the termination of this stage. The THIRD STAGE is curved, running first across the spine from right to left at the level of the third lumbar vertebra, to which it is closely moulded, and then, turning upwards, runs along the left side of the spine to the level of the second lumbar vertebra, where it bends forwards, forming the *duodeno-jejunal flexure*, which is situated behind, and close to, the duodeno-pyloric junction. This stage is related behind to the vena cava, aorta, inferior mesenteric artery, left spermatic and renal vessels and ureter; in front to the superior mesenteric vessels, small intestine, transverse mesocolon and stomach. It will be noted that the duodenum is closely related to many important structures which are liable to become involved in the various affections of this part. The relation of the second part to the *kidney* is thought to explain the sickness and vomiting associated with movable kidney, the duodenum being dragged upon and partially kinked. The PERITONEAL COVERING of the first portion is as in the stomach. The second stage is only covered by peritoneum in front, and is not covered where it is crossed by the transverse colon, and the third stage is covered in front, except where the superior mesenteric vessels cross it. The DUODENO-JEJUNAL JUNCTION is very firmly fixed, being held in position by a band of fibrous and unstriped muscular tissue descending from the left crus of the diaphragm, which also supports the mesentery (*ligament or muscle of Treitz*).

The duodenum is frequently the seat of *perforating ulcers*, in some cases following extensive burns. These occur chiefly

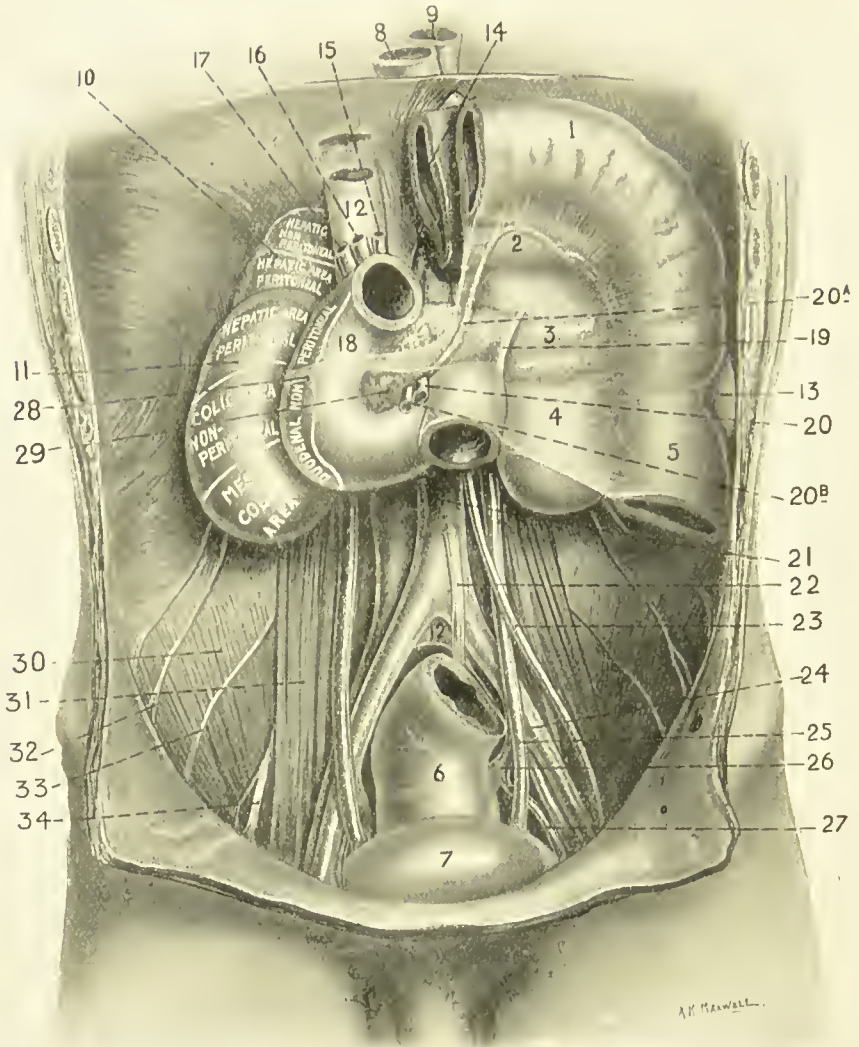


FIG. 27.—THE INFRAMESOCOLIC COMPARTMENT OF THE ABDOMEN. ON THE RIGHT A PORTION OF STOMACH, AND TRANSVERSE COLON CARRYING WITH IT TRANSVERSE MESOCOLON, ARE SHOWN TURNED UP AS FOR THE OPERATION FOR POSTERIOR GASTRO-JEJUNOSTOMY.

- | | | |
|--|---------------------------------|---|
| 1. Transverse colon turned up. | 13. Spleen. | 23. Spermatic artery. |
| 2. Stomach seen through transverse mesocolon. | 14. Stomach turned up. | 24. External iliac artery. |
| 3. Pancreas seen through transverse mesocolon. | 15. Hepatic artery. | 25. Ureter. |
| 4. Kidney seen through transverse mesocolon. | 16. Portal vein. | 26. Interior iliac artery. |
| 5. Descending colon. | 17. Bile-duct. | 27. Anterior division of interior iliac. |
| 6. Rectum. | 18. Duodenum. | 28. Attachment of transverse mesocolon. |
| 7. Bladder. | 19. Ligament of Freitz. | 29. Head of pancreas. |
| 8. Esophagus. | 20. Superior mesenteric artery. | 30. Iliacus muscle. |
| 10. Suprarenal. | 20a. Middle colic artery | 31. Psoas muscle. |
| 11. Kidney. | 20b. Superior mesenteric vein. | 32. Ilio-hypogastric and inguinal nerves. |
| 12. Inferior vena cava. | 21. Descending aorta. | 33. External cutaneous nerve. |
| | 22. Inferior mesenteric artery. | 34. Anterior crural nerve. |

in the first part of the duodenum, affecting particularly Brunner's glands, and hence generally involve the general peritoneal cavity. Severe *hæmorrhage* may also occur, and, where the affection is circumscribed, a *subphrenic abscess* may form. Healed ulcers may give rise to *stenosis*, and *congenital strictures* are also met with, particularly in the second portion above the common papilla, where the bowel may be entirely obliterated. Where cicatrization involves the *common duct*, serious jaundice, with rapid emaciation, would occur. It is noteworthy that perforating ulcers have also occurred after a severe attack of eczema. A congenital pouch sometimes occurs in the second portion above the common papilla. The duodenum is subject to *rupture* at any part from external abdominal injury, the general peritoneum being frequently not opened into. The duodenal *blood-supply* is from the pancreatico-duodenal arteries, the superior being derived from the hepatic gastroduodenal, and the inferior from the superior mesenteric.

As already explained, the **mesentery** consists of a double layer of peritoneum running out from the posterior abdominal wall to the intestine (of which it forms the serous coat), covering the vessels, nerves, lymphatic and lacteal vessels and glands supplying the bowel. The parietal attachment of the mesentery commences near the duodeno-jejunal junction, just to the left of the second lumbar vertebra, where it is supported by the ligament of Treitz. Passing from the third piece of the duodenum to this point, there is frequently seen a fold of peritoneum, enclosing a *triangular fossa*, with the apex downwards and the opening above, just below the duodeno-jejunal junction. The opening, normally, would admit the tip of the finger, and through it a *retro-peritoneal hernia* may occur, the jejunum pushing its way down between the posterior wall of the abdomen and the peritoneum. Such herniæ may be very large, occupying the left side, and reaching perhaps the promontory of the sacrum. Several somewhat similar fossæ may occur in this region, but that described is the most constant. From the point of its commencement the *mesenteric attachment* runs downwards and to the right for about 6 inches to the iliac fossa, where it ends indefinitely. The *upper, or right, layer* is continuous with the under layer of the transverse mesocolon; the *lower, or left,*

layer runs down over the descending colon, forms the sigmoid mesentery, and descends into the pelvis. This *oblique attachment* is of importance, as it directs effusions from the upper portion of the abdomen to the right iliac fossa. Thus, in a case of perforating pyloric ulcer the extruded matter may be conducted to the right inguinal region, over which the patient may chiefly complain of pain, thereby causing suspicion of appendicitis. The obliquity may also be taken advantage of surgically in *determining which is the upper end of a particular loop of bowel.* If the loop be straightened out, and care be taken that its mesentery is not twisted, then the end nearer the thorax is the upper. The average *length* of the mesentery is about 8 inches, while the lowest part, which supplies some 5 feet of bowel about the jejuno-ileal junction, is about 10 inches. This portion of bowel, therefore, generally hangs lowest, and is frequently found in *herniæ*. It is worthy of note, however, that where the mesentery is normal in attachment and length, no portion of bowel will readily come through the inguinal or femoral rings. The mesentery is relatively longer prior to puberty, and permits descent of the bowel more freely on the right side. In acquired hernia Lockwood states that the mesenteric attachment generally is found to have descended, causing *enteroptosis* (prolapse of the mesentery), rather than to have lengthened. *Apertures*, congenital, or acquired from injury, sometimes occur in the mesentery, particularly the portion connected with the lower ileum, through which a knuckle of the bowel may pass and become strangulated, and bowel has even become strangulated through the foramen of Winslow. Tubercle frequently attacks the peritoneum, generally causing *tubercular peritonitis*, while it may cause enlargement and caseation of the mesenteric glands. In some cases the mesentery becomes very much contracted, drawing the bowel close up to its attachments, and thus forming a shrunken and compact mass (*peritonitis deformans*). As a result of old tubercular disease and formation of adhesions, *fibrous bands* are frequently produced, which are sometimes a cause of *internal strangulation* of bowel.

The **SMALL INTESTINE** between the duodenum and caput cæcum is on an average about 22 feet long, and is divided into two portions—**jejunum and ileum**—the first being about

8 feet, and the latter 14 feet, in length. There is no definite point of junction between the two, the transition being gradual. The jejunum is about $1\frac{1}{4}$ inches in diameter, and the ileum 1 inch, but muscular contraction may render the bowel very narrow, while gaseous distension may render it very wide. The jejunum is about $\frac{1}{4}$ inch wider, thicker walled, heavier, and more vascular than the ileum. With regard to the arrangement of the bowel in the abdominal cavity, as a rule the coils on the left side of the spine and high up are jejunum, while these in the pelvis and right iliac fossa are ileum. In the region of the pubes may frequently be found that portion of bowel with the longest mesentery (about the jejuno-ileal junction), and also the lower portion of the ileum.

It is often of importance in abdominal operations to *determine roughly to what portion of the intestinal tract a loop which has been picked up belongs*. It is not easy to do this, but some guiding points may be mentioned. The *valvulæ conniventes*, or transverse folds of mucous membrane, are most marked in the upper portion of the jejunum; are fewer beyond that point; and absent, or almost so, beyond the middle of the ileum. These may be seen by transmitted light, if the bowel be fairly translucent. The *Peyer's patches*, which are oblong collections of lymphoid tissue, about 1 inch long and $\frac{1}{2}$ inch broad, situated opposite the mesenteric attachment, and numbering between twenty and thirty in all, are larger and more numerous in the ileum than in the jejunum. Further, the vessels supplying the lower ileum form one or even two sets of arches in the mesentery, prior to running into the bowel, and the mesentery becomes progressively more fat-laden toward the lower end, sometimes so much so as to obscure the vascular arches.

Peyer's patches are favourite sites for both *tubercle and typhoid* bacilli to settle in and cause *ulceration*. The former rarely perforate the serous coat, but do not respect the anatomical margins of the patch, tending to extend circularly round the lumen of the gut, and hence, in healing, to cause *stricture*. The latter are prone to perforation, remain localized to the patch, and heal generally with a flat cicatrix, stricture being an uncommon sequela.

Lieberkühn's glands occur throughout the entire intestinal

tract, and are a frequent starting-point both for adenoma and carcinoma of the intestine. Where it is necessary from gangrene or malignant growth to remove a portion of bowel (*enterectomy*), care should be taken to allow healthy mesentery to project beyond the cut end of the bowel on either side, and, further, to cut the bowel obliquely, removing more of the side opposite the mesenteric attachment, the object of these precautions being to secure sufficient blood-supply. In suturing (*enterorrhaphy*) care is taken to apply serous surfaces to one another, as these unite readily. The position where delay in healing generally occurs is at the mesenteric attachment, where, owing to divergence of the two layers of the mesentery ($\frac{5}{16}$ inch), there is no serous coat. As a rule, if more than a third of the total length of the intestine be removed, the patient's nutrition suffers. It may be necessary to open a piece of bowel (*enterotomy*) to remove an impacted body, or to short circuit a piece involved in a tumour.

Wounds of the small intestine are generally more serious the nearer the stomach they occur. Where the wound is small, particularly if punctured, no harm will probably result. Thus the bowel has been frequently punctured for tympanites without untoward consequences, and, even when the wound is a little larger, the mucous membrane generally protrudes into and fills up the wound. This protrusion of mucous membrane, together with muscular contraction, may prevent extrusion of material even in small incised wounds. As a rule, longitudinal wounds gape more than do transverse, the circular layer being the stronger. Transverse wounds gape most when situated opposite to the mesenteric attachment, and jejunal wounds generally gape more than those of the ileum.

VESSELS.—Both jejunum and ileum are supplied by the *superior mesenteric*, from which some fifteen to twenty branches run forward between the mesenteric layers, form numerous anastomosing arches, and then give off little straight vessels which run forward to the bowel, and then bifurcate at the mesenteric attachment, one little vessel running along either side of the bowel wall, first subperitoneally, and then in the submucous coat. The *veins* are similarly arranged, and run to join the superior mesenteric which, joining with the splenic, forms the portal vein. The **LYMPHATICS**, or lacteals, as they are here called, commencing in the villi of the mucous mem-

brane, and as lymphatic sinuses surrounding the bases of the solitary glands, form plexuses between each of the coats, submucous and subserous, and also between the two muscular coats, then pass between the mesenteric layers to the MESENTERIC GLANDS (which may number over 100, the larger ones lying close to the mesenteric attachment), and then, uniting to form one or more large vessels, open into the RECEPTACULUM CHYLI, which lies on the right side of the body of the second lumbar vertebra. In tubercular disease of the intestine the infection is frequently carried to these mesenteric glands, causing *tabes mesenterica*. The glands may become very large, and caseate, or, later, they may form large calcareous masses. The mesentery may shrink, causing *peritonitis deformans*, and even in less severe cases, symptoms resembling intestinal obstruction frequently arise. *Chyle cysts*, which may attain a large size, arise probably from blocking of some of the ducts. The NERVES are derived chiefly from the *solar plexus*, a few fibres coming from the *right vagus*, and pass as the *superior mesenteric plexus*, along with the superior mesenteric artery, to the bowel, where they form intermuscular (Auerbach's) and submucous (Meissner's) plexuses.

Meckel's diverticulum is produced by persistence of the intestinal end of the vitello-intestinal duct; is situated on the ileum, some 1 to 4 feet from the ileo-cæcal valve; and consists of a diverticulum of varying length, but generally only a few inches long, of the same structure and calibre as the bowel from which it springs. It may terminate in a free extremity, or may be continued toward the umbilicus as a fibrous cord. It is met with in about 2 per cent. of bodies, and is chiefly of importance from its tendency to cause *intestinal obstruction*: by twisting round some other portion of bowel; from its tip becoming adherent, and a loop of bowel slipping under the bridge so formed; from contraction of its adhesions, dragging upon and kinking the ileum from which it springs; or, by causing intussusception.

THE LARGE INTESTINE.—The CÆCUM is that portion of large intestine which lies below the entrance of the ileum. It is normally situated in the right iliac fossa, its most dependent part midway between the anterior iliac spine and symphysis pubis, and measures $2\frac{1}{4}$ inches ver-

tically, and 3 inches in diameter. When empty it is generally covered by other loops of bowel, but when full lies in contact with the abdominal wall. In herbivora the cæcum is very large, and developmentally in man the appendix forms the tapering extremity of the cæcum, this 'infantile type' sometimes persisting. The cæcum, like the colon, is possessed of *three longitudinal bands*, one of which is situated anteriorly, and the others postero-externally and internally respectively. The cæcum falls from these bands in saccular folds, and, in addition, owing to shortness of the internal band, it is curved, with the concavity to the left. In the adult type this *curving* becomes more marked, as does likewise the sacculation between the anterior and postero-external bands, until finally this saccule becomes the most dependent part, and the appendix appears tucked up and attached to the inner and posterior wall. As these bands are continued into the appendix, the *anterior* one is sometimes taken as a guide to the appendix. It should be remembered that developmentally the cæcum first lies on the left side, and then crosses to the right, lying at first in front of the right kidney, and then descending toward the pelvis. This fact may account for the cæcum being found occasionally in left-sided inguinal and umbilical herniæ. Further, as the cæcum is generally *entirely invested with peritoneum*, it is comparatively mobile. Sometimes it retains its foetal mesentery, and from this cause, also, may, along with the appendix, form the contents of a *hernia* on the right, or even on the left, side, or become affected by *volvulus*. *Foreign bodies* may sometimes lodge, and *concretions* may form, in the cæcum, and cause *ulceration*. Where there is *obstruction* in the large intestine, the cæcum tends to become *distended* with faecal matter, sometimes becoming very large, and occupying a large portion of the abdominal cavity. An examination, therefore, of the cæcum may, in a case of doubt, assist in *determining whether an obstruction exists above or below the ileo-cæcal valve*. If the former, the cæcum will be normal; if the latter, it will probably be distended; and in such cases it is prone to *stercoral ulceration*, which may lead to perforation. *Dysenteric and tubercular ulcers* also occur in it.

The **VERMIFORM APPENDIX** in the adult is situated on the inner and posterior aspect of the cæcum, and is normally

about $3\frac{1}{2}$ inches long, and about $\frac{1}{4}$ inch in diameter. Its position is very variable, even when the cæcum retains its normal situation, and it also varies greatly in length. It may lie curled up behind the cæcum and ileum, or its extremity may extend over the brim into the pelvis, or even be found on the left side of the abdomen, or up under the liver. The position of its orifice on the posterior and inner cæcal wall is about 1 inch below the ileo-cæcal valve, and generally presents a *valved aperture*. It is enveloped in peritoneum, its *mesentery*, which is derived from that supplying the lower end of the ileum, extending generally to the tip, although the terminal position may be represented by a slight ridge. Shortness of this mesentery may cause *bends* of the appendix.

The peritoneum in this neighbourhood presents several small *FOSSÆ*, which are possibly of importance in relation to herniæ and appendicitis. One of these, the *ileo-cæcal fossa*, whose orifice is directed away from the cæcum, is situated below the ileum, in the angle between it and the cæcum. It is bounded behind by the mesoappendix, and in front by a fold of peritoneum (the ileo-cæcal fold), which runs from the ileum down to join the front of the mesoappendix. The *ileo-colic fossa*, similar but smaller, is situated on the upper surface of the ileum, being bounded behind by the mesentery of the ileum, and in front by a small fold of peritoneum (the ileo-colic fold). *Retro-colic fossæ* are, occasionally, present, and are seen by turning the cæcum upwards. They lie behind the beginning of the colon on either its outer or inner margin, or both. When they are present, the appendix is said frequently to lodge in them, and so be more prone to appendicitis, presumably from becoming caught.

In *structure* the appendix closely resembles the large intestine. The lymphatic follicles are most prominent in younger subjects, and occur particularly at the distal portion of the appendix.

The *ileo-colic division* of the superior mesenteric artery branches to supply the lower end of the ileum, cæcum, appendix, and portion of the ascending colon. The branch which supplies the anterior surface of the cæcum runs down in the ileo-colic fold, and gives off the *appendicular artery*, which runs behind the ileum to reach the mesoappendix. It in turn gives off a recurrent branch, which runs in the ileo-cæcal fold to reach the ileum, and then runs forward supplying the

appendix to its tip by means of numerous branches. The *veins* are similar, and empty into the superior mesenteric.

The *nerves* of the cæcum and appendix are derived from the superior mesenteric plexus, and the *lymphatics* pass to the mesocolic glands, lying behind the ascending colon. The *common nerve-supply* of ileum and appendix should be noted. Thus in operative cases it has been seen that, when the lower portion of the ileum is stimulated, the secretion of the appendix comes in little jets, and, as the ileo-cæcal valve directs the intestinal contents, as they enter the cæcum, over the mouth of the appendix, they are thoroughly mixed with this secretion. While this secretion may have a purely digestive function, it has been suggested that the appendix may also exist as a culture chamber for the *Bacillus coli*, and that it impregnates the contents with the bacilli at this point (Macewen). Certainly a number of obscure digestive troubles have been traced to affections of the appendix, and it is well known that obstinate constipation frequently follows the removal of the appendix. It has further been noted in actual cases that mental impressions have a marked effect upon the secretion of appendix and cæcum, bad news producing an entire cessation of secretion for some hours. Thus the mental condition as a cause of indigestion cannot be disregarded. In cases of *mucous colitis* it is frequently of advantage to be able to wash out the colon, and this is readily done by bringing out the appendix through the abdominal wall, cutting off its tip after it has contracted adhesions, and then irrigating by means of a narrow tube passed down through the appendix (Macewen). In such cases it is possible to observe the appendix, and it is worthy of note that, save in cases of severe purgation, fæcal matter rarely finds its way into the appendix. Even in such purgation only a slight brown stain generally results. *Foreign bodies*, such as pins and orange-pips, do occasionally find their way into the appendix, but generally such bodies are composed of gradually accumulated fæcal matter, and are termed *coproliths*.

The appendix is a frequent seat of *inflammatory and suppurative mischief*, which sometimes subsides after the pus has become discharged into the bowel, or may proceed to *ulceration, or gangrene*, with localized or generalized *peritonitis*. As already explained, the omentum and various bowel loops frequently

take part in walling off an abscess arising in connection with the appendix, and thus preventing general peritonitis. Such *appendicular abscesses* may be found in almost any portion of the abdomen, and are frequently met with in the pelvis, and less commonly up under the liver, or diaphragm, or on the left side. A *subphrenic abscess* may arise from lymphatic extension from the appendix. When the appendix is inflamed, it may become attached to the *ovary*, and frequently it is difficult to discriminate between the two organs as the seat of pain. From the involment of the *psoas muscle and anterior crural nerve* the thigh is frequently flexed, and pain is referred to the inside of the knee, thus simulating hip disease. Again, when the abscess is up under the liver, the condition may be diagnosed as one arising in connection with liver or kidney, etc.

Why the appendix should thus be affected by inflammatory mischief is not easy to explain. Its blind extremity, narrow lumen, power of movement, unequal length and position of its mesentery, and abundant supply of *Bacillus coli* in its interior, may all be predisposing causes. In *operations* for appendicitis an incision is generally made with its centre over *McBurney's point*, situated 2 inches from the anterior superior spine on a line from the spine to the umbilicus. The incision runs obliquely downwards and inwards, and the abdominal muscles, where possible, are split, rather than cut, in the direction of their fibres. Where a *circumscribed abscess* exists, an incision farther out is generally better, it being frequently possible to evacuate the abscess without opening the general peritoneal cavity. The scar of a wound which has healed by connective tissue is liable to stretch and cause a *ventral hernia*. Such herniæ occur probably most often through appendix scars, where, owing to suppuration, the wound has been kept open and allowed to granulate.

The normal position of the **ileo-cæcal valve** is indicated on the surface by a point slightly above that midway between the anterior superior spine and umbilicus. It is situated somewhat posteriorly, at the junction of cæcum and colon, and consists of a narrow opening about $\frac{1}{2}$ inch long, the long axis lying horizontally, and the aperture, which is bounded by upper and lower crescentic margins, looking forwards and

to the right. At the junction of the upper and lower margins at each end of the valve, a ridge, or frenula, extends round the cæcum. While the peritoneal and longitudinal muscular coats of the bowel pass sharply from the ileum to the colon, the mucous and part of the circular muscular coats are invaginated at the valve into the cæcum to form the above-mentioned crescentic margins, a markedly pouting mouth being produced, which directs the bowel contents over the orifice of the appendix as they enter the cæcum. This mouth is also supposed to act in preventing regurgitation of food into the ileum, since, as the cæcum distends and the frenula becomes tight, the valve is mechanically closed for the time being. It is at this valve that *intussusception* most frequently occurs, the narrower ileum being, as a rule, projected into the wider colon, carrying the valve inwards as its apex (ileo-cæcal). To such an extent may the intussusception go that the valve may ultimately appear at the anus. Occasionally the valve retains its position, and the ileum alone forms the intussusception (ileo-colic); this, however, is not common.

The **COLON**, commencing at the ileo-cæcal valve, and terminating at the junction with the rectum, opposite the front of the body of the third sacral vertebra, is fully 3 feet long, and has a diameter ranging from $2\frac{1}{2}$ inches at the cæcum to $1\frac{1}{2}$ inches at the sigmoid flexure, its general shape being that of a capital **M**. The ascending and descending colon may, or may not, have a mesocolon, the proportions being about equal, while a mesocolon is rather more common on the left than on the right. As a mesocolon renders the operation of lumbar colotomy difficult, this would be one reason for avoiding that operation.

The **ascending colon**, about 8 inches long, ascends in front of the fascia iliaca, the fascia over the quadratus lumborum, and the lower and outer portion of the right kidney to the under surface of the right lobe of the liver, where is situated the hepatic flexure, at which the ascending communicates with the transverse colon. As it ascends it curves slightly with the concavity to the left, and while it is quite superficial near its commencement, the hepatic flexure is deeply placed, and is therefore not easily palpable. Where the cæcum has not descended, the ascending colon is absent.

The HEPATIC FLEXURE is generally an acute bend, situated between the lateral abdominal wall externally and the descending duodenum internally, which rests on the kidney posteriorly, and impresses the liver above. It may be supported by the hepato-colic ligament, a peritoneal band, which is occasionally given off to it from the right extremity of the gastro-hepatic omentum.

Commencing at the hepatic flexure, which, as stated, is deeply placed, the **transverse colon**, which is generally about 20 inches long, runs forward and to the left, thus once more becoming superficial and therefore palpable. While the general direction of the transverse colon is upwards towards the splenic flexure, which is placed on a higher level than the hepatic, its shape varies considerably, its right side portion being comparatively fixed while the left portion is largely influenced by the movements of the stomach. Normally, the umbilicus should indicate the *lower border* of the transverse colon, which, however, sometimes descends much below this, and even below the pubis, where it may contract adhesions to the pelvic organs (ptosis). It is not infrequently found in umbilical *herniæ*, and in herniæ through the foramen of Winslow, and has been present in a left inguinal hernia, while its presenting through incisions made for removal of the appendix or left inguinal colotomy has led to considerable confusion. At the hepatic end it is in relation to the liver and gall-bladder, and hepatic *abscesses* have discharged into the transverse colon, and fistulæ have occurred between the gall-bladder and transverse colon from large gall-stones ulcerating through. Posteriorly, also, at this part it is related to the descending duodenum, to the front of which, as well as the head of the pancreas, it is generally fairly fixed either by short mesentery or areolar tissue. Beyond this point the transverse mesocolon develops, and then the bowel becomes free, until close to the splenic flexure. Owing to its comparative *freedom of movement*, the transverse colon may occasionally, and particularly when distended with gas, lie in front of both stomach and liver, thus tending to obliterate the area of liver dulness.

At the SPLENIC FLEXURE the bowel runs upwards and backwards once again, becoming deeply placed, until the base of the spleen is reached, when it bends sharply down-

wards into the descending colon. At this point the colon lies deeply behind the stomach and under the spleen, being kept in position by the phreno-colic ligament which runs to it from the diaphragm. Dragging upon this ligament is supposed to be the cause of pain referred to the left scapular region in some cases of *chronic constipation*. The diaphragm is affected, and so impressions are conveyed to the cervical cord by the left phrenic nerve, whence they are referred to the distribution of the descending supra-acromial nerves.

The TRANSVERSE MESOCOLON conveys the blood-supply to the transverse colon, and also forms a *diaphragm* at the level of the descending duodenum and pancreas, which extends laterally to the kidneys and anteriorly to the transverse colon, dividing the abdominal cavity into two compartments, the lower of which contains the whole of the small intestine.

The **descending colon**, some 9 or 10 inches long, extends from the splenic flexure to the inner border of the psoas muscle at the brim of the pelvis. Curving at first downwards and inwards along the outer border of the kidney, it runs vertically to the iliac crest (this portion being about 4 to 5 inches long : descending colon proper), and then passes downwards and inwards in front of the iliacus muscle, crosses the psoas a little above the level of Poupart's ligament, and terminates at the pelvic brim in the pelvic colon (this ILIAC COLON portion is about 5 inches long). The descending colon, like the iliac, is generally devoid of mesentery, being only covered by peritoneum on the front and sides. Both portions are generally separated by loops of small bowel from the anterior abdominal wall, and they are narrower than the ascending colon.

The **pelvic colon**, which is continuous above with the iliac colon and below with the rectum, constitutes the SIGMOID FLEXURE proper. It commences at the inner border of the left psoas by crossing the external iliac vessels and dipping over the pelvic brim, and then runs in the pelvis from left to right, resting on the bladder or uterus. It then turns backwards along the right posterior wall of the pelvis till it reaches the middle line, where, at the level of the third piece of the sacrum, it becomes continuous with the rectum. It thus forms a loop which is supplied with a COMPLETE MESENTERY, which permits of considerable movement, its position varying with the amount of

distension of the bladder, etc. This portion varies in length from $\frac{1}{2}$ foot to nearly 3 feet, the average being about 17 inches. When very short, its course is more simple, while, when long, it may describe an **S**. When of normal length and shape, the *two ends* of the sigmoid are some 3 inches apart. Sometimes, however, they may, from natural or pathological causes, become approximated, and then the condition known as VOLVULUS, in which the two ends of the loop become twisted upon one another, is apt to occur. Here the bowel becomes enormously distended, while its vascular supply is cut off, and gangrene may supervene. Fæcal accumulations, carcinoma recti, etc., may also cause distension, the loop resembling a greatly dilated stomach. In some cases of great distension it may rise quite out of the pelvis, and even cause palpitation and dyspnœa by pressing upon the diaphragm. The mesentery of the loop is fan-shaped, its *attachment*, having the shape of an inverted **V**, running up the inner border of the left psoas to the bifurcation of the common iliac, and then turning sharply downwards to descend over the sacral promontory and front of the sacrum to the third piece, where it ends. At the apex of the inverted angle there is a small '*intersigmoid fossa*,' which lies under the mesentery, admits the tip of the little finger, and has rarely been the seat of strangulated hernia. On account of its freedom of movement, this portion of bowel is generally selected in the operation for inguinal colotomy. (This operation has almost entirely displaced the older operation of *lumbar colotomy*, in which the bowel is opened from behind through an incision parallel to the last rib, and passing through a point midway between the centre of the crest of the ilium and the tip of the last rib. The structures cut through are the latissimus dorsi and external oblique, internal oblique, transversalis muscle, fascia lumborum, and transversalis fascia, and the bowel is exposed between the psoas and quadratus lumborum.)

In INGUINAL COLOTOMY an incision about 2 inches long is made at right angles to a line joining the anterior superior spine and umbilicus, and $1\frac{1}{2}$ inches from the anterior superior spine. The two obliques and transversalis are split, the peritoneum opened sufficiently to admit the finger, and the sigmoid is drawn up and secured. Generally a glass rod is passed through its mesentery, partly to keep it up, and partly

to form a spur, which will tend to prevent fæcal matter passing beyond that point. It is generally wise to stitch the serous coat of bowel, peritoneum, and skin together to prevent leakage either into the peritoneal cavity or the muscular layers, when, subsequently, the bowel is opened, forming an *artificial anus*. In picking up a portion of bowel for this operation, it should be remembered that large intestine is *distinguished* from small intestine not merely by its greater size (which is variable) and thicker walls, but also by the longitudinal bands and the appendices epiploicæ. Sometimes it is necessary, from the extent of disease of the bowel on the left side, to do a colotomy on the *right side*. The operation is more difficult, the cæcum not coming so readily into the wound, and as the fæcal material is much more fluid and irritating at this point, the patient has difficulty in keeping the parts clean and the skin free from irritation. In connection with the statement made by physiologists that the large intestine only absorbs water and some salts, it is important to note that where the colon is opened on the right side the patient generally emaciates rapidly, whereas, when opened on the left, the patient may rapidly regain an excellent bodily condition.

Dysenteric ulcers occur generally in the large intestine, particularly toward the rectum and anus, and frequently give rise to *stricture*.

BLOOD-SUPPLY.—The cæcum and vermiform appendix are supplied by the ileo-colic; the ascending colon by the right colic; and the transverse colon by the middle colic of the superior mesenteric; while the descending colon is supplied by the left colic, and the iliac and pelvic colon by the sigmoid arteries of the inferior mesenteric. The rectum is supplied by the three hæmorrhoidal arteries. The *veins* present similar arrangements.

The *middle colic artery* supplying the transverse colon runs in the transverse mesocolon; and in performing a gastro-enterostomy, in which the mesocolon is perforated, care is necessary to avoid injury to the artery, which would probably be followed by gangrene of the transverse colon.

The **NERVE-SUPPLY** is derived from the superior mesenteric from the solar plexus, and from the inferior mesenteric from the aortic plexus.

The **LYMPHATICS** draining the bowel from cæcum to upper

portion of descending colon pass to the mesocolic glands, which lie behind the ascending and descending colon, between the layers of the transverse mesocolon. Those draining the lower half of the descending colon, and iliac and pelvic colons, join the left lymphatic trunk of the lumbar glands.

The **LIVER** lies under the diaphragm, occupying the right and central portions of the cavity formed by that dome-shaped muscle to which its convex parietal surface is moulded, while its visceral surface, of irregular shape and moulded to the abdominal viscera upon which it rests, looks down, backwards, and to the left. These two surfaces meet posteriorly in a curve, while anteriorly they meet at an angle, forming the inferior margin. The liver varies much in shape and size, but its *normal limits* in health, as ascertained by percussion, are : *Above*, from a point 1 inch internal to, and $\frac{1}{2}$ inch below, the right nipple, to a point 1 inch below the left nipple, the line dipping between these points to cross the sternum just above the gladiolar xiphoid junction. The *right border* corresponds to a curved line running downwards from the commencement of the line marking the upper limit to a point 1 inch below the tip of the tenth costal cartilage. Commencing from this point, the *lower border* runs to the left, corresponding with the margin of the ribs, until the ninth is reached, from the tip of the costal cartilage of which it runs in a curve, with the convexity downwards, reaching midway between the base of the ensiform and the umbilicus, till it reaches the tip of the eighth costal cartilage on the left, whence it runs outwards to meet the upper border.

The inferior margin of the liver, however, is thin, and overlaps the stomach and intestine, while the upper border is overlapped by the base of the right lung, and hence these are not always easily demarcated by percussion. Further, the lower border rises and falls with respiration, and also descends generally when the patient assumes the upright posture. It also descends when the liver is enlarged, as from tumour, and when the diaphragm is depressed, as in emphysema. Occasionally, in multiparous females with very lax abdominal walls, *hepatoptosis* may occur, the liver descending to the level of the umbilicus, or even the right inguinal fossa. In some cases, especially of tight-lacing, the lower border of the liver may become prominent, and even present a projecting process,

called *Riedel's lobe*, which may be mistaken for an abdominal tumour. On the other hand, the *upper border* of the liver may ascend, pushing the diaphragm and lung before it, the costo-diaphragmatic recess of the pleura becoming deepened, and the diaphragm lying in contact with the thoracic wall over a larger area. In such cases the liver may be opened through the chest wall, pleural sac, and diaphragm (*trans-pleural hepaticotomy*). The *left border* also varies in position, sometimes extending right across to the left lateral abdominal wall. The liver is divided into *two lobes*, right and left, by the falciform ligament. It has an intimate fibrous-tissue covering, which is most abundant where the serous coat is absent, and particularly so at the portal fissure, where it is known as *Glisson's capsule*, and surrounds the vessels entering the fissure, and accompanies them into the liver substance. It is entirely covered with *peritoneum*, save for a space on the posterior surface of the right lobe, which corresponds to the interval between the two layers of the coronary ligament, and is attached directly to the diaphragm by areolar tissue, through which the portal circulation of the liver communicates with the systemic circulation in the diaphragm. The left margin of the uncovered area is marked below by the suprarenal capsule of the right kidney, and immediately to the left of this is the *deep groove* through which the *vena cava* passes, this groove being sometimes converted into an actual tunnel by overlapping of the uncovered area on the right, and the Spigelian lobe on the left.

The left margin of the *Spigelian lobe*, in turn, is grooved by the *fissure of the ductus venosus*, which at this part separates the right lobe from the left lobe; and immediately to the left of it is the *œsophageal groove*, which leads down to the gastric impression on the visceral surface. The VISCERAL SURFACE of the left lobe rests upon the upper surface and lesser curvature of the stomach, which produces the gastric impression, while that of the right lobe is divided into two by the gall-bladder lying antero-posteriorly. To the right of the gall-bladder the visceral surface is marked by the colic impression in front and the renal impression behind, and the duodenal impression between the two and the gall-bladder. To the left of the gall-bladder, and between it and the falciform ligament, are, from before backwards, (I) the *quadratic lobe*, resting upon

the pylorus or the beginning of the duodenum ; (2) the *portal fissure*, through which the portal vein, hepatic artery, and hepatic duct enter the liver, the two layers of the lesser omentum lying attached to its borders ; (3) *caudate lobe* (lying between the portal fissure and vena cava), which is small, and rests on the foramen of Winslow. The INFERIOR MARGIN of the liver presents a *notch (umbilical)* at the attachment of the

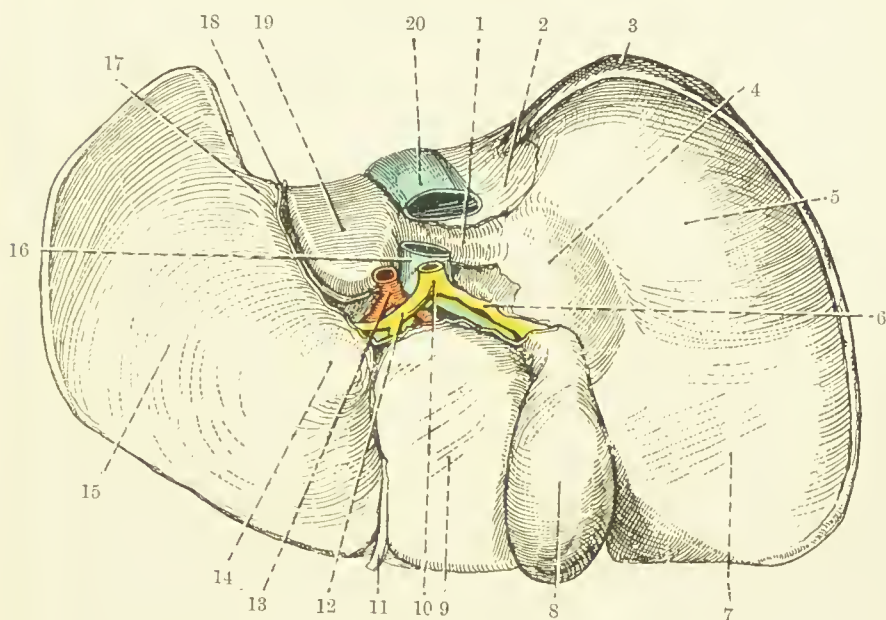


FIG. 28.—THE INFERIOR SURFACE OF THE LIVER.
(From Buchanan's "Anatomy.")

- | | |
|----------------------------------|--------------------------------------|
| 1. Lobus caudatus. | 11. Round ligament. |
| 2. Impressio suprarenalis. | 12. Hepatic duct. |
| 3. Uncovered area of right lobe. | 13. Hepatic artery. |
| 4. Impressio duodenalis. | 14. Tuber omentale. |
| 5. Impressio renalis. | 15. Impressio gastrica on left lobe. |
| 6. Cystic duct. | 16. Vena portæ. |
| 7. Impressio colica. | 17. Œsophageal groove. |
| 8. Gall-bladder. | 18. Venosal fissure. |
| 9. Lobus quadratus. | 19. Lobus Spigelii. |
| 10. Ductus communis choledochus. | 20. Inferior vena cava. |

round ligament. It is situated $1\frac{1}{2}$ inches to the right of the middle line. The notch marks the commencement of the LONGITUDINAL FISSURE of the liver, which divides the liver into right and left lobes, and which is composed anteriorly of the *umbilical fissure*, and posteriorly of the *fissure of the ductus venosus*. The deep umbilical fissure, lodging the round ligament, runs into the left extremity of the portal fissure, beyond

which point the separation into right and left lobes is continued by the fissure of the ductus venosus, which converges above to meet the fissure of the vena cava, and lodges the fibrous remains of the ductus venosus. The *round ligament* is the remains of the left umbilical vein (the right one disappearing altogether at an early stage), which runs from the umbilicus to the left branch of the portal vein. Like the round ligament, the *ductus venosus* is a foetal channel, and carries blood from the left branch of the portal vein to the vena cava direct, without going into the liver. It becomes obliterated at birth, and degenerates into a fibrous cord. Thus, round ligament (or umbilical vein) and ductus venosus in the foetus are practically continuous structures, blood passing direct from the placenta along the umbilical vein through the ductus venosus to the inferior vena cava, and so to the heart direct.

The *fossa lodging the gall-bladder* is usually devoid of peritoneum, the gall-bladder lying, as a rule, directly in contact with the liver (sometimes, however, it is suspended by a short mesentery), and situated at a point where the right Poupart line crosses the lower margin of the ribs (between rib margin and outer border of rectus). With the exception of the uncovered area, the gall-bladder fossa just mentioned, and a small area between the layers of the falciform ligament, the whole organ is invested with peritoneum, all derived from the great sac, except that covering the caudate and Spigelian lobes.

The liver is *maintained in position* by its adhesion to the under-surface of the diaphragm at the uncovered area; by the two coronary ligaments which are peritoneal processes reflected from its margin on to the diaphragm; the left lateral ligament running from the left lobe to the diaphragm, and the falciform ligament (both peritoneal); its attachments to the vena cava; and the upward pressure of other abdominal organs. The *falciform ligament* consists of a crescentic double layer of peritoneum, whose convex border is attached to the under surface of the diaphragm and anterior abdominal wall, about 1 inch to the right of the middle line; while the concave border, free, and containing the round ligament, extends from close to the umbilicus to the umbilical notch of the liver. The *gastro-hepatic omentum*, extending from the liver to the lesser

curvature of the stomach, consists of two folds of peritoneum—the anterior, derived from the greater sac; and the posterior, from the lesser sac—between which, at its right extremity, are the bile-duct, hepatic artery, and portal vein, with nerves and lymphatics. Notwithstanding its attachments, however, the liver has occasionally descended to the level of the umbilicus, or even into the iliac fossa (ptosis of the liver), the organ turning in its descent, so that its diaphragmatic surface becomes anterior.

Vessels.—The PORTAL VEIN, formed by the junction of the superior mesenteric and splenic veins, commences behind the head of the pancreas, ascends behind the first part of the duodenum, and then, accompanied by the bile-duct and hepatic artery, proceeds between the layers of the gastro-hepatic omentum to the transverse fissure, where it divides into right and left branches, of which the latter is connected with the round ligament and ductus venosus. The portal vein conveys blood from the stomach, intestines (excepting lower portion of rectum), spleen, and pancreas, and ramifies in the substance of the liver.

Portal obstruction may arise from pressure on the veins, from tumours of the head of the pancreas or adjacent parts, from cirrhosis or tumours of the liver itself, or from valvular disease of the heart (causing engorgement and 'nutmeg liver'). In such cases abdominal *ascites* generally occurs, the abdominal cavity becoming distended with free fluid. The *circulation* is so far relieved by (1) para-umbilical communication between veins of the abdominal wall and portal; (2) communication of portal and systemic veins at uncovered surface of liver; (3) similar communication between veins of the lower part of the œsophagus and those of the stomach; (4) similar communication between the superior (portal) with the middle and inferior hæmorrhoidal (systemic). In order to assist the circulation, an artificial anastomosis between portal and systemic venous systems has been made by bringing a portion of great omentum into contact with the subcutaneous tissues of the abdominal wall. *Hæmorrhoids* frequently occur in portal congestion.

The HEPATIC ARTERY arises from the cœliac axis, runs along the upper border of the pancreas, giving off pancreatic, pyloric, and gastro-duodenal branches, enters the

gastro-hepatic omentum, and so reaches the transverse fissure. It divides into right and left branches, the *cystic artery* being given off from the right division, which ramifies in the portal canals. The blood is conveyed from the liver to the inferior vena cava by the *hepatic veins*. The portal vein, hepatic artery, and bile-ducts are surrounded by connective tissue derived from the connective tissue which invests the surface of the liver, and is known as Glisson's capsule. Thus, these structures may collapse when cut, whereas the hepatic veins are embedded in liver tissue, and hence gape when cut, and, as they have no valves, may regurgitate blood from the inferior vena cava. This point is of importance in relation to *injury* of the liver, which is frequently ruptured from blows or crushes. If the capsule be torn, the patient may die from hæmorrhage, whereas if it remain intact, as not infrequently occurs, the patient may recover. *Considerable portions* of liver have been removed, however, by ligature, incision by cautery, and even by excision by knife, with success (hepatectomy), and in this connection it should be remembered that the blood-pressure in the liver is low. The liver is occasionally damaged by fractured ribs, and even extensive wounds of the liver may be recovered from. The liver very frequently becomes secondarily affected by carcinoma, many nodules forming, some of which may be easily palpated as they lie on the surface, while the organ becomes greatly enlarged. The infection of the liver is generally comparatively early in carcinoma of the stomach, from which the infection is believed to be conveyed by the portal vein (as is likewise conveyed infection from carcinoma recti).

The LYMPHATICS of the liver are arranged in two sets—superficial and deep. The former lie under the peritoneal covering, and drain to the hepatic glands in the lesser omentum, lumbar, anterior mediastinal glands, and right lymphatic duct. The latter accompany the hepatic and portal veins, and drain to the hepatic glands and to the thoracic duct. The NERVES are derived from the left pneumogastric and solar plexus.

The liver is not infrequently the seat of *abscesses*. These may occur in connection with *pyæmia*, when they are small, multiple, and superficial; or from *ulcerative conditions* of the bowel (the infection probably being conveyed by the portal

vein) or biliary passages, when the abscess is generally large, single, and deeply seated. The pyæmic multiple abscesses occur frequently in connection with pyogenic head affections—as, for example, suppurative sigmoid sinus thrombosis—but are rare in pyæmia from urinary affections or burns. ‘*Tropical abscess*,’ which occurs in connection with dysentery, is a good example of the solitary type. While at first deeply seated, the abscess may progress either *upwards* towards the diaphragm or *down* toward the peritoneum. In the first case, it gives rise to cough from irritation of the vagus filaments in the liver, and to pain in the right shoulder region from irritation of the right phrenic (both in the liver and the diaphragm), which communicates with the superficial descending cutaneous branches of the cervical plexus. The abscess may burst into the pleura, but, more generally, from soldering of its layers, bursts into the lung, and may be coughed up through the bronchi, or may cause suffocation. Where the abscess proceeds downwards, it may burst into the stomach, intestine, or peritoneal cavity. The abscess may be attacked through the abdomen (generally in two stages, to permit of soldering of the peritoneum round the wound, thus shutting off the peritoneum), or by the transpleural route.

The liver is the most common seat of *hydatid cysts*, the embryo boring its way from the intestine into the portal vein, and being thus conveyed to the liver. Such cysts may attain a large size, and sometimes burst into the lungs. They may be attacked by either of the routes mentioned for abscess. The large *bile-ducts* which converge to the transverse fissure, to form by their junction the right and left hepatic ducts, present numerous dilatations, which may act as reservoirs when the gall-bladder has been removed or rendered insufficient. The two *hepatic ducts* join to form the hepatic duct, which runs downwards for 1 inch in the portal fissure to the point where, joined by the cystic duct, it forms the *common bile-duct*.

The **gall-bladder** is a thin-walled, pyriform sac, about 3 inches long, lying obliquely on the under-surface of the liver, to which it is attached by connective tissue. Below, it is in contact with the transverse colon in front, and duodenum behind. It is invested with peritoneum, except, as a rule, on its upper surface. Its *tundus* is directed downwards, forwards,

and to the right, and when the bladder is full presents in the angle between the outer border of the rectus and the costal margin, opposite the ninth cartilage. The *neck* presents an S-shaped curve (and presents internally a somewhat spiral folding of the mucous membrane, which is said to obstruct the passage of gall-stones), and ends in the *cystic duct*, which is slightly narrower and longer than the hepatic duct which it runs backwards and inwards to meet. The two ducts join at the mouth of the portal fissure to form the COMMON BILE-DUCT, which, about 2 inches long, runs down in front of the foramen of Winslow, between the layers of the lesser omentum, with the portal vein behind and the hepatic artery to the left. It now descends behind the first part of the duodenum, and then between the pancreas and second portion of the duodenum, where it meets the pancreatic duct, along with which it runs obliquely through the duodenal wall, to open on a *common papilla* 4 inches beyond the pylorus. The gall-bladder is not infrequently *distended*, sometimes from the impaction of a stone in the cystic duct, or an accumulation of stones in the bladder itself, or from obstruction in the common bile-duct, by malignant growths of the duodenum, pancreas, etc. Where greatly distended, it has been mistaken for an ovarian cyst, the mass extending below the umbilicus. While at first the bladder is distended with bile, in long-standing cases, where the duct becomes occluded, it may only contain clear fluid. It also sometimes contains pus. The irritative process extends through the walls of the bladder to the surrounding structures, and thus the bladder may contract *adhesion* to the duodenum, colon, etc. In some cases where a large stone has been lodged in the gall-bladder, and such adhesions have formed, the stone has ultimately *ulcerated* its way through into the duodenum, and become impacted in the ileum, causing *intestinal obstruction*. In other cases it has ulcerated its way through the anterior abdominal parietes. In *operating* on the gall-bladder, an incision is made either vertically through the rectus or right semilunar line, or obliquely beneath the costal margin, and the bladder and ducts exposed and examined.

For the removal of stones in the bladder after aspiration of fluid contents, *cholecystotomy* may be performed, the bladder being subsequently closed by stitching; or a *cholecystostomy*, in which the opened bladder is stitched to the abdominal

wound, and allowed to heal by granulations. *Choledochotomy* is the operation for removal of a calculus in the common bile-duct by longitudinal incision, which is subsequently stitched (the part being surrounded by gauze packing, as leakage is common). One or two *lymphatic glands* lie in the gastro-hepatic omentum close to the neck of the gall-bladder, which, when enlarged or calcified, may be mistaken for gall-stones. Where the stone is lodged in the lower extremity of the common bile-duct (*ampulla of Vater*), it may be expressed into the duodenum or crushed. If a cutting operation be necessary, difficulty is experienced, the pancreas or duodenum frequently requiring to be cut into. *Cholecystectomy*, or removal of the gall-bladder by stripping the peritoneum and ligaturing the neck and cystic artery, may be performed for new growths, occlusion of the duct, etc. *Cholecystenterostomy* consists in joining the gall-bladder and duodenum so as to make a fistula in cases where the common bile-duct is obstructed. The *nerve-supply* of the gall-bladder is from the eighth and ninth segments of the cord through the great splanchnic and celiac plexus; and hence in passage of gall-stones pain may be referred to the parietes over the epigastrium, right hypochondrium, and lumbar region (biliary colic).

The **PANCREAS**, about 6 inches long, runs almost horizontally across the abdomen at the level of the first lumbar vertebra, about 3 inches above the umbilicus. The *tail* is in contact with the spleen; the *body* is prismatic in shape, one edge pointing anteriorly; while at the attenuated *neck* the organ describes a semicircle, so that the head is directed downwards and to the left, being lodged in the concavity formed by the loop of the duodenum. In front the head is in relation to the transverse colon, and behind to the vena cava, renal vessels, and aorta. The *uncinate process* of the head is sometimes separate, forming the lesser pancreas. The *neck* is narrow, lies in front of the portal vein, and presents a notch on the left side at its junction with the head, through which the superior mesenteric vessels pass, separating the head and neck from the duodeno-jejunal flexure. The *posterior surface of the body* has no peritoneal covering, but is attached by areolar tissue to the posterior abdominal wall and the organs lying on it—namely, aorta, and origin of superior mesenteric artery, left renal vessels, left suprarenal capsule, and left

kidney. The *splenic artery* (with the vein below it) runs behind the upper border of the pancreas. The *upper surface* of the body presents a small projection, the *tuber omentale*, at its junction with the neck. This upper surface is covered by the posterior layer of the lesser peritoneal sac, which separates it from the stomach which rests on it. The *inferior surface* is covered by descending peritoneum derived from the transverse mesocolon, and is in contact with the duodeno-jejunal flexure, small intestine, and splenic flexure of the colon. The *pancreatic duct* (of *Wirsung*) runs almost from the tail forward, till, on reaching the neck, it meets the bile-duct and opens, as already described, about 4 inches beyond the pylorus. It receives many branches in its course, and frequently an *accessory duct* (of *Santorini*) opens into the duodenum $\frac{3}{4}$ inch above the main duct, with which it previously anastomoses. The *blood-supply* is derived from the superior and inferior pancreatico-duodenal arteries (from the gastro-duodenal and superior mesenteric respectively), inferior pancreatic (from either gastro-duodenal or superior mesenteric), and branches from splenic and hepatic arteries. The *veins* open into the superior mesenteric, portal, and splenic veins. The *lymphatics* pass to the cœliac glands, and the *nerves* are derived from the solar plexus, through the superior mesenteric, cœliac, and splenic plexuses.

In addition to secreting the *pancreatic juice* for digestion of carbohydrates, the pancreas is supposed to supply an '*internal secretion*,' the destruction of the pancreas by disease giving rise to pancreatic diabetes. Owing to its important functions, obscurity of its pathological phenomena, and to its difficult position, the pancreas has not been much subjected to surgical interference. Recently attention has frequently been called to *pancreatitis*, sometimes giving rise to *suppuration*, and necessitating surgical interference to prevent peritonitis. *Pancreatic cysts* occasionally arise from obstruction of the duct, from a calculus or pressure on it from without. The cyst generally commences in the tail, and as it increases in size presents between stomach and transverse colon, pushing the great omentum before it. Such cysts sometimes attain a very large size. Both cysts and abscesses are generally best reached by a *median incision* above the umbilicus, and then opening through the omentum. *Carcinoma* not in-

frequently occurs in the head, rapidly involving the pancreatic and bile ducts, and pressing on the portal vein, pylorus, and other surrounding parts. *Removal* by operation is generally out of the question. Rarely it has been found in a *diaphragmatic hernia*, or sloughed off after having been invaginated into the sac. Attempts have been made in cases of pancreatic diabetes to *implant* portions of healthy pancreatic tissue in the subcutaneous tissues.

The **SPLEEN** is about 5 inches long and 3 inches broad. It may be compared in shape to a thick pancake, which, instead of being circular, is roughly triangular in outline, while its visceral surface presents marked indentations caused by pressure of adjacent organs. It is placed far back in the upper portion of the abdominal cavity, its long axis corresponding in direction to the posterior portion of the tenth rib, while its parietal surface is moulded to the back part of the diaphragm, by which, together with pleura and thin basal margin of lung, it is separated from the ninth, tenth, and eleventh ribs. The apex reaches a point 1 inch from the spine. The anterior basal angle is the most anterior part, but does not present normally beyond the costal margin. The *notch of the spleen* lies above this angle on the anterior margin. The *visceral surface* presents three impressions—*anterior*, *posterior*, and *inferior*. Anteriorly a deep concavity corresponds to the fundus of the stomach, and near the posterior part of this depression is the *hilum* at which the vessels enter. Behind the gastric depression is the renal depression, formed by the anterior surface of the kidney; while lying under these two is the intestinal impression, formed by the splenic flexure of the colon. In the neighbourhood of the spleen *accessory masses* of splenic tissue are not infrequently found (*lienculi*). The spleen is almost enveloped in *peritoneum*, the peritoneum passing from the hilum to the anterior surface of the kidney, forming the *lieno-renal ligament*; and to the fundus of the stomach, forming the *gastro-splenic omentum*. Under the peritoneal covering the spleen possesses a tough *fibrous capsule*, containing both elastic and involuntary muscular fibres. While distensible, this capsule is also contractile, and may account for arrest of hæmorrhage in punctured or gunshot wounds of the spleen. The blood is conveyed by the *splenic artery*, the largest branch of the cœliac axis, which runs along the upper border of the

pancreas; passes between the layers of the lieno-renal ligament; breaks up into several branches, and so enters the hilus after supplying branches to the stomach. The *splenic vein* joins the superior mesenteric behind the head of the pancreas to form the portal vein.

The *nerve-supply* is the splenic plexus, derived from the coeliac of the solar plexus. There are no *lymphatics* in the spleen, but some are present in the capsule. The *normal position* of the spleen is indicated by a line running obliquely downwards and forwards from a point $1\frac{1}{2}$ inches in front of the ninth dorsal spine to a point on the tenth rib at the level of the first lumbar spine, encircled by an oval 3 inches in transverse diameter. Owing to the intervention of the lung between the spleen and chest wall, it is practically impossible to outline its limits. Normally, the spleen does not project beyond the ribs, but, when *enlarged*, the anterior basal angle projects, and then it is generally possible to detect one or more *notches* on the anterior border, which serve to distinguish splenic from other enlargements in the same region.

Pathological enlargement of the spleen is seen in various fevers, and chronically in leucocythæmia, Hodgkin's disease, malaria (*ague cake*), etc. In the latter the organ is extremely easily *ruptured*, fatal hæmorrhage frequently following the accident. In some cases the enlargement is enormous, the spleen occupying the greater part of the abdomen. The spleen may be *punctured* by fractured ribs, but not infrequently the spleen is ruptured, whereas, owing to their elasticity, the ribs escape fracture. As the spleen is very vascular, enormous *hæmorrhage* generally occurs, the abdomen being filled with blood, and death generally resulting. In some cases, however, the ruptured spleen has been *removed*, and the bleeding vessels ligatured, with excellent results. As the splenic artery is an end artery, *infarctions* not infrequently occur in the spleen, from emboli being lodged, and if these are septic, *abscesses* may arise. These are generally multiple and peripheral. A large single abscess of the spleen is rare. Particularly in females, and associated with general displacement of the viscera, the spleen may be found *displaced*, and possessing an elongated pedicle, which permits of considerable movement, the spleen sometimes reaching the pelvis (wandering spleen). In such cases

the spleen may be restored and fixed by sutures (*splenopexy*), or may be removed (*splenectomy*).

LUMBAR REGION.

The lumbar region extends from the level of the twelfth dorsal vertebra and twelfth rib to the base of the sacrum, ilio-lumbar ligament, and iliac crest. Externally it is limited on the posterior aspect by the outer border of the erector spinæ, indicated by a vertical furrow running between it and the flat abdominal muscles, while on the abdominal surface it is limited by the outer border of the quadratus lumborum, the latter muscle, together with the psoas, forming the floor of the space.

The **iliac fossa** is bounded above by the ilio-lumbar ligament, and above and externally by the crest of the ilium, internally by the brim of the true pelvis, and in front by Poupart's ligament. It lodges the iliacus muscle, which, blending with the psoas to form the ilio-psoas, runs down to the small trochanter of the femur. The FASCIAL COVERINGS of these muscles, and particularly of the psoas, are of considerable importance surgically.

Three layers of fascia run outwards from the vertebræ, and fuse, enclosing muscles as they do so, to form the lumbar aponeurosis. The most posterior of these three fasciæ, called the *vertebral aponeurosis*, extends outwards from the spines of the vertebræ to meet the *middle layer*, which arises from the tips of the transverse processes of the lumbar vertebræ, enclosing the erector spinæ between them. The *anterior layer* arises from the junctions of transverse processes and bodies, and extends outwards to meet the middle layer, enclosing the quadratus lumborum, and separating it anteriorly from the psoas (see Fig. 19).

The PSOAS FASCIA, OR SHEATH, forms a fourth layer, which, rising from the front of the bodies of the lumbar vertebra (with arches to permit of the passing of the lumbar arteries), runs outwards and fuses with the anterior layer, shortly before it fuses with the middle and posterior layers to form the lumbar aponeurosis. Above, the psoas sheath commences at the internal arcuate ligament of the diaphragm, being derived from the diaphragmatic portion of the transversalis fascia, and thus the psoas muscle only receives its sheath after perforating the diaphragm.

The LUMBAR APONEUROSIS is a narrow ligamentous band, extending from the last rib to the iliac crest. Besides giving attachments to the internal oblique and transversalis muscles, it is continuous by its anterior edge with the transversalis fascia, and hence it connects the outer border of the psoas sheath with the inner border of the transversalis fascia. It is pierced near the rib by the last intercostal artery and nerve, and near the ilium by the ilio-hypogastric nerve and accompanying artery. The FASCIAE LINING THE ABDOMINAL CAVITY in the lumbar region are the transversalis, lining the antero-lateral portion, the anterior layer of lumbar fascia, and psoas sheath completing the investment. The three layers forming the lumbar aponeurosis are, like it, inserted below into the crest of the ilium, the lower margin of the anterior layer being thickened to form the *ilio-lumbar ligament*, which extends from the transverse process of the last lumbar vertebra to the inner lip of the iliac crest (while its upper margin forms the *external arcuate ligament*). The psoas sheath, however, on reaching the iliac fossa, becomes directly continuous with the ILIAC FASCIA, covering the iliacus muscle, and thus it is necessary to consider these two together in that region. This iliac fascia, then, is attached along the whole iliac crest and ilio-lumbar ligament. Then it extends over the psoas, on the inner border of which it is attached to the sacrum and brim of the true pelvis, and ilio-pectineal eminence, and is continuous with the pelvic fascia. Along Poupart's ligament it fuses with the transversalis fascia, save where the external iliac vessels emerge to form the femoral vessels, the transversalis fascia at this point joining in front of, and the iliac fascia behind, the vessels, to form their sheath (*femoral sheath*). Thus the ilio-psoas muscle and anterior crural nerve enter the thigh through a *compartment* composed of fascia and bone, which is closed, save for the communication with the psoas above, and with the pelvis below and to the inside. Under the iliac fascia the external iliac, by its circumflex iliac branch, anastomoses with the ilio-lumbar branch of the internal iliac.

The INTERNAL SURFACE of the abdominal cavity, then, is lined by a continuous fascial covering, variously named at different parts, the chief portions being the transversalis and iliac fasciæ. On the deep surface of the fascia

lies a layer of EXTRAPERITONEAL TISSUE, which fills in the furrows between the muscles, thus presenting a fairly regular abdominal surface, and in which the kidneys, ureters, renal, colic, and spermatic vessels, and iliac vessels and lymphatic glands are embedded. (The anterior crural nerve and lumbar nerves, on the other hand, are under, or external to, the fascia.) On the inner surface of the extraperitoneal tissue, again, the peritoneum lies.

ABSCESSSES in this region may occur either in the extraperitoneal tissue or under the psoas fascia. *Extraperitoneal* abscesses may arise from appendix, kidney, a parametritis, etc. ; may be of considerable size and widely spread. Such abscesses tend to point above Poupart or to enter the pelvis. Those which occur *under*, or external to, the *transversalis fascia* generally point at the iliac crest or above Poupart ; they rarely extend along the inguinal canal into the scrotum. Sometimes, by following the last intercostal or ilio-hypogastric nerves, they may pierce the lumbar fascia, or may pierce the quadratus lumborum, and then, coming through the external oblique, appear at Petit's triangle. Those which occur *in the psoas sheath* arise generally from tubercular disease of the dorsal or upper lumbar vertebræ (POTT'S DISEASE). Where the disease is in the dorsal region, the tubercular débris is first extruded into the posterior mediastinum in which it gravitates downwards, until arrested by the diaphragm, whence, passing under the internal arcuate ligament in company with the psoas muscle, it enters the abdomen within the psoas sheath. This sheath directs it down the posterior abdominal wall, across the blade of the ilium, under Poupart's ligament, through the special iliac compartment already described, in which position it lies to the outside of the femoral vessels. Then the abscess passes under the vessels, reaches the lesser trochanter, and frequently turns up again and overlaps the vessels from the inside. While this is the typical course of a PSOAS ABSCESS, the pus may sometimes escape from the psoas sheath, as for example by following one of the lumbar arteries between the transverse processes of the lumbar vertebræ, and then, running outwards on the posterior surface of the quadratus lumborum, pierce the origin of the transversalis, and also the internal oblique, and finally present in the **triangle of Petit**—the triangular

interval whose base is formed by the highest point of the crest of the ilium, while the sides are formed by the free border of external oblique anteriorly, and the latissimus dorsi posteriorly. The floor is formed by the internal oblique. (Above the triangle the latissimus dorsi overlaps the external oblique.) Sometimes also the pus may gravitate into the pelvis through the communication with the pelvic fascia. On the other hand, pus from *acetabular disease*, or hip disease where the acetabulum is eroded and perforated, may extend upwards, and so simulate a psoas abscess.

The **KIDNEYS** are about 4 inches long, $2\frac{1}{2}$ inches broad, and $1\frac{1}{2}$ inches thick, the right being shorter and thicker than the left, which, however, is the larger. On the anterior surface of each kidney there is a blunt projection, formed by the pressure of adjoining organs, which in the right kidney forms a transverse ridge, and in the left a blunt summit. The *position of the kidney* may be indicated on the posterior surface by four lines, two horizontal from the spines of the eleventh dorsal and third lumbar, giving the upper and lower limits, and two vertical, one 1 inch, and the other 4 inches from the vertebral spines, indicating the inner and outer limits. The *hilum* corresponds to the level of the first lumbar spine, and is 2 inches from the middle line on the right, and $1\frac{3}{4}$ on the left side. In front the lower limit of the kidneys does not extend below the level of the umbilicus, corresponding generally to the lowest limit of the thoracic framework, and the hilum is about a finger-breadth inside the tip of the ninth costal cartilage. (St. 2.) The right kidney lies $\frac{3}{4}$ inch lower than the left, its lower border being $1\frac{1}{4}$ inches from the iliac crest. The kidneys normally *move with respiration*, and when this movement is excessive, the kidney can frequently be palpated by one hand in front, and the other pressing forwards in the loin when the patient takes a long breath. While the kidney rarely ascends above its normal position, it is frequently found below it. This in some cases may be due to a *congenital defect*, the kidney normally ascending during foetal life from the pelvis into its normal position. In such cases the kidney is generally fixed in the abnormal position, and its vessels are short. Other congenital deformities are horse-shoe kidney, absence of one kidney, or presence of a supernumerary kidney.

A downward displacement of one kidney, and particularly the right, frequently occurs, the condition being known as *movable kidney*. Normally, the kidney is *kept in position* by (1) the pressure of the abdominal wall exerted on it through the viscera, in conjunction with the peculiar shape of its anterior surface already referred to; (2) its vessels; (3) the attachments of the renal fascia, kept tense by the fat of the adipose capsule. If the adipose tissue be diminished, these attachments become slack, and so undue mobility is allowed. In such cases great latitude of movement may be possible, the kidney frequently being found in the pelvis, and gastric dilatation and transient jaundice may be produced by the traction of the kidney upon the duodenum. *Floating kidney* is the term applied to a similar but rare condition where the kidney possesses a *mesonephron*. As a rule, even where the kidney is very movable, its covering is composed of loose fibrous tissue derived from its capsule, and not peritoneum. The condition is most frequently met with in women, being predisposed to by pregnancy, causing relaxation of the abdominal parietes.

The inner borders of the kidneys look inwards and also forwards, and the lower extremities are wider apart, and are directed more forward than the upper extremities. The kidneys lie behind the *peritoneum*, which is only closely related to the outer border, the anterior surface being embedded in the extraperitoneal fat, which in this region is very abundant, constituting the *capsula adiposa* of the kidney. This in turn is surrounded by a fibrous investment, the *fascia renalis*, also composed of extraperitoneal tissue, which splits into two layers to enclose the kidney, fatty envelope, suprarenal capsule, renal vessels, and commencement of the ureter. This fascia is attached above and externally to the diaphragm, and then splits to enclose the kidney, the anterior layer passing in front of the kidney, its vessels, and the aorta, and becoming continuous with that of the opposite side, while the posterior layer passes behind the kidney, and is attached to the front of the spine along the inner border of the psoas. Below the level of the kidney the two layers continue separately in the direction of the iliac fossa, and are gradually lost. This renal fascia sends in numerous trabeculæ, which, traversing the adipose layer, fuse with the proper capsule of the kidney.

The *proper capsule* of the kidney is tough and fibrous, but normally is not very adherent to the kidney substance. It plays an important part in limiting effusions within the kidney substance, may practically form the cyst wall in advanced *hydronephrosis*, and is utilized in the operation of nephrorrhaphy.

Posteriorly, the kidneys are in relation to the diaphragm, internal and external arcuate ligaments, fascia of the psoas and quadratus lumborum and lumbar fascia, the twelfth rib which crosses obliquely at the junction of the upper and middle one-third, and transverse processes of the two upper lumbar vertebræ. *Externally*, the right kidney is in relation to the liver, and the left to the spleen. *In front*, the right kidney is related to the under surface of the liver, ascending and commencement of transverse colon, and second part of duodenum; the left to the fundus of the stomach, descending colon, and pancreas.

The *relationship to the twelfth rib* is of importance, as the reflection of the parietal pleura from diaphragm to chest wall takes place about this level, and sometimes even below it, and maintains this level even when the twelfth rib is rudimentary. It is therefore wise, before commencing a *lumbar operation* on the kidney, to count the ribs and commence the incision fully $\frac{3}{4}$ inch below the lower border of the twelfth rib.

The RENAL ARTERY arises from the aorta at the level of the first lumbar vertebra. The right is larger than the left, and passes under the vena cava. The artery divides into several large branches before entering the kidney. The small vessels within the kidney substance pursue a pretty straight course, and, as they are practically end arteries, *infarctions* not infrequently occur in the kidney substance.

The RENAL VEINS empty into the inferior vena cava, the left being longer and crossing in front of the aorta, while the left spermatic vein opens into it at right angles. The renal veins lie in front of the arteries, which in turn are in front of the ureters.

The NERVES are derived from the renal plexus (from the solar) and accompanying branches of the artery. The segments of the cord involved are from the tenth dorsal to first lumbar, through the small and lesser splanchnics, and

in renal affections pain (*e.g.*, dragging pain in movable kidney) is referred along the sensory nerves derived from these segments.

The expanded PELVIS OF THE KIDNEY, which is situated partly within the lips of the hilum and partly beyond, presents several depressions, or *calyces*, on which the papillæ open. The renal pelvis on the right side is related to the duodenum in front, and vena cava on its inner border; on the left to the body of the pancreas and jejunum in front, and aorta some distance from its inner border.

Infection may reach the kidney by the blood-stream, producing multiple small cortical *abscesses*, or most commonly by the ureter. In the latter case the infection generally extends up from the bladder, producing a *pyelitis*, and by further extension suppurative foci in the kidney substance (so called '*surgical kidney*'). Once the ureter becomes blocked, a *pyonephrosis* occurs. An abscess in the tissue surrounding the kidney (*perinephric abscess*) may arise by extension from the kidney or from suppurative appendicitis, empyema perforating the diaphragm, etc. Such abscesses generally point about Petit's triangle, but, owing to the laxness of the tissues, may spread widely in the extraperitoneal tissues before pointing externally, sometimes descending into the iliac fossa or opening into the colon or rectum. The kidney is frequently affected by tubercle (through the blood-stream). Calculi, particularly uric acid or oxalates, form about the renal pelvis, and, if movable, may cause *renal colic* when attempting to descend the ureter.

Injuries to the kidneys generally result from severe crushes, the kidney being lacerated by pressure against the last rib, or transverse processes and bodies of the two upper lumbar vertebræ. Where the *capsule is ruptured*, a large extravasation of blood and urine may take place into the extraperitoneal tissues. Ruptures of the kidney are more frequently recovered from than similar injuries of the other viscera, owing to their extraperitoneal position. *Hæmaturia* frequently follows injuries to the back, owing to the kidney being crushed between the ilium and lower ribs in acute anterior flexion.

OPERATIONS—*Nephrotomy* (incision into), *Nephrolithotomy* (incision for the removal of stone), *Nephrectomy* (removal),

Nephrorrhaphy (suturing kidney to parietes in normal position).—These operations may be performed through a lumbar incision, commencing below the angle between the last rib and the outer border of the erector spinæ, and extending down and out to about 1 inch above the anterior superior spine. Where necessary, the incision may be extended down and inwards into the inguinal region—still extraperitoneal. The incision involves pretty free section of the muscles and subsequent weakening, and especially in women the space between the last rib and iliac crest is frequently short, making removal of large tumours difficult. Further, it is not possible to inspect the condition of the supposed sound kidney prior to removal of a diseased one, and hence nephrectomy is generally performed through an abdominal incision, the peritoneum, of course, being opened. In either operation the vessels and ureters are ligatured and the organ removed. The possibility of irregular branches of artery or vein entering the kidney away from the hilum should be kept in mind. Occasionally from disease the kidney contracts *adhesions* to surrounding organs—duodenum, colon, vena cava, aorta, etc.—and in order to avoid injury to these important structures it is sometimes necessary to remove the kidney by a *subcapsular operation*, which is rendered easier by the diminished size of the renal vessels in such affections.

In the *abdominal operation* the incision is frequently made in the linea semilunaris, and the peritoneum incised along the outer border of the colon, which is then drawn inwards so as to expose the kidney. *Nephrorrhaphy* (*nephropexy*) is generally performed through the lumbar incision, the proper capsule of the kidney being split along the posterior border, reflected for fully $\frac{1}{2}$ inch along either side, and the reflected capsule then stitched to the transversalis fascia and muscles. The wound is allowed to granulate so as further to fix the kidney by fibrous adhesions.

The **SUPRARENAL CAPSULES** are situated at the upper extremities of the kidneys, and also extend along the inner border, the right being pyramidal and the left crescentic in shape. The right is moulded against the inferior vena cava, and the left is close to the aorta. In *Addison's disease* these capsules, which are closely connected with the solar plexus, are generally affected. Addison's disease is characterized

by a bronzing of the skin, and pigmentation of the skin is also seen in pregnancy, abdominal tuberculosis, some affections of the liver, and carcinoma of the stomach, due probably likewise to some disturbance of the plexus.

The **ureter** commences in the dilated renal pelvis, which is connected to the medullary portion by the calyces or infundibula. Lying at first in the retroperitoneal tissue of the abdomen, it descends to the pelvic brim, which it crosses at the sacro-iliac articulation, to enter the pelvis. About 1 foot long, and possessing a strong muscular wall, the ureter is described in abdominal and pelvic portions. The *abdominal portion* is related in front and to either side to the peritoneum, colic and spermatic vessels, and on the right side to the termination of the ileum, and on the left to jejunum and pelvic colon. On the left side it lies immediately behind the intersigmoid fossa, as it crosses the common iliac artery. Behind, the ureters lie on the psoas sheath and genito-crural nerve, while internally the right ureter is close to the inferior vena cava, and the left to the aorta and inferior mesenteric vessels.

Septic infection frequently travels by the ureter from the bladder to the kidney, while, on the other hand, pus or blood coming from the kidney passes down the ureter to the bladder, where it may be seen, on cystoscopic examination, discharging from the mouth of the ureter, and the side of the affected kidney thus decided with certainty. A ureter catheter is sometimes introduced, with the object of obtaining a specimen of urine from one kidney.

Calculi not infrequently pass down the ureter from the kidney, generally causing severe *renal colic*, with sickness, vomiting, and retraction of the testicle, and sometimes they may become impacted in the ureter, causing hydronephrosis if neglected. In cases of obstruction of the urethra, urine may accumulate in the ureters and pelves, causing distension.

The ureter is not often *wounded* in the abdominal segment, but is in greater danger in the pelvic portion, where it has been wounded through the great sciatic foramen in deep gluteal wounds, while it also lies in the female in close relationship to the uterus, and is liable to damage in removal of the uterus in cases of extensive carcinoma. Where the bladder is also extensively involved, the ureters have sometimes been intentionally cut, and their ends *implanted* into either the

vagina or the rectum. *Rupture* of the ureter has also occurred from external violence.

The **SOLAR PLEXUS** supplies the stomach, small intestine, liver, pancreas, spleen, and kidneys with sensation; controls the blood-supply, and also the calibre of the bowel. The plexus receives branches from the vagus, phrenic (through its hepatic and suprarenal divisions), and also the splanchnic nerves, which arise from the gangliated cord of the sympathetic. *Injuries* to the viscera, supplied by the sympathetic, produce faintness, collapse, and vomiting, the symptoms being more severe in injuries of organs more closely associated with the plexus. Thus injuries about the stomach generally produce profound symptoms; those of the small intestine serious symptoms; while those of the ascending colon, which is supplied by the superior mesenteric plexus, are much less serious, and those of the descending colon and sigmoid, supplied by the inferior mesenteric plexus (and therefore only indirectly associated with the solar), still less so.

The **AORTA** gives off numerous large branches to the intestines, the cœliac axis and superior mesenteric being as large as the carotid. These vessels form arches before finally supplying the bowel, but *embolism* of even a small branch may lead to *gangrene of the bowel*. *Aneurism* of the abdominal aorta occurs most frequently where the cœliac and other large vessels are given off. Several *anastomoses* exist between the visceral branches of the aorta and those of the posterior abdominal parietes in connection with organs which have a large uncovered posterior surface, such as the liver, kidneys, part of the duodenum, pancreas, ascending and descending colon. The vessels anastomosing with these are the lower intercostal, lumbar, ilio-lumbar, circumflex iliac, epigastric, and phrenic, and the blood supplied by this anastomosis has been sufficient to nourish the affected organs after embolism of the cœliac axis and mesenteric vessels (Chiene).

The **INFERIOR VENA CAVA** commences on the right side of the fifth lumbar vertebra at the junction of the iliacs. Lying on the right side of the spine as it ascends, it is in front of the right lumbar, and right renal arteries, which pass behind it, while the spermatic artery lies in front, in addition to small intestine, third part duodenum, pancreas, portal vein, and right lobe of liver. It receives the lower lumbar veins, right

spermatic, suprarenal, and lower phrenic, and both renals (the left of which is the longer, and receives the left spermatic, or ovarian, suprarenal, and lower phrenic prior to entering the cava). While in the notch behind the liver the cava receives the hepatic veins which return the blood brought to the liver by the portal vein and hepatic artery.

The **THORACIC DUCT** has been wounded, and also cut and ligatured without bad results. Its communications with the azygos veins in the posterior mediastinum and lymphatic vessels of the right side may serve to explain this. The duct conveys *carcinoma* at an early period from certain abdominal affections, particularly those about the stomach, and hence, in suspected malignant disease of the stomach, it is always well to inspect the left supraclavicular glands. In many such cases of carcinoma the emaciation is largely due to blocking of the duct with carcinoma.

THE PELVIS

The **PELVIS** is important surgically, not merely on account of its contained organs, but from its mechanical position. The centre of gravity of the adult body is just above the sacro-lumbar angle, and over the midpoint of a line drawn between the heads of the femora. In the erect posture the brim of the true pelvis forms an angle of 60 degrees with the horizon, while the base of the sacrum is $3\frac{3}{4}$ inches above the upper border of the symphysis, and the tip of the coccyx just above its lower border. This obliquity of the pelvis has an effect in modifying shocks transmitted to it, which are further distributed by certain arches.

Thus, when in the erect posture, the arch along which force is transmitted is composed of the sacrum, sacro-iliac joints, acetabula, and intervening bone, while in sitting it is composed of sacrum, sacro-iliac joints, ischial tuberosities, and intervening bone. In these arches the sacrum is compared to a keystone, but, as Cleland has pointed out, the sacrum is really suspended between the innominate bones by its ligaments, and is not really a keystone. Morris describes a counter-arch for each of these mentioned, which, by converting the arch into a ring, 'ties' it, and greatly strengthens it.

Thus the counter-arch in the erect posture is composed of the body and horizontal rami of the pubes, and, in the sitting posture, of the rami of pubes and ischium, the arch being completed, in both cases, by the symphysis, which therefore has to stand a very considerable strain. Thus in rickets the symphysis is frequently pushed forward, and sometimes the anterior arch yields almost entirely, while disease of the symphysis is generally accompanied by pain on standing or sitting. As the sacro-iliac joint and symphysis are surrounded by powerful ligaments, the joints seldom give way, but fracture generally takes place to one side of them. Thus the most common FRACTURE OF THE PELVIS is through the rami of both pubes and ischium, and this is often associated with tearing of the sacro-iliac ligaments or fracture of the bone on either side. Where the pelvis is crushed by laterally applied force (*indirect violence*), the sides of the pelvis tend to be driven together, and thus the posterior sacro-iliac ligaments are torn, whereas when the force is applied antero-posteriorly (*direct violence*), the sides tend to be driven apart, and so the anterior ligaments are torn. Fractures of the pelvis are very apt to cause rupture of the urethra, rectum, or bladder. The three anatomical portions of the pelvis fuse about the seventeenth year. The symphysis has been divided to give more room in labour where the pelvis is contracted (Sigaultean operation), and separation has occurred as the result even of muscular violence. *Sacro-iliac disease*, which is frequently tubercular, but may be rheumatoid, is generally associated with much pain both in standing and sitting, the pain being referred to the sacrum along the upper sacral nerves, the buttock along the gluteal nerve, and the hip or knee-joint along the obturator nerve, and occasionally to the back of the thigh and calf along the lumbo-sacral cord and connection with the great sciatic. (The lumbo-sacral cord and the obturator nerve pass over the front of the articulation.) In his operation for ectopia vesicæ, Trendelenburg divides the sacro-iliac joints in order to get the gaping symphysis to come together. Congenital tumours, dermoids, and teratomata, are sometimes found occupying the *sacro-coccygeal region*, the dermoids frequently arising from remnants of the post-anal gut, which, like the allantois, is an out-growth from the neurenteric canal, and normally entirely

disappears before birth. The sacro-coccygeal region is also the common seat of attachment between attached foetuses. The sacro-coccygeal joint and surrounding parts are frequently the seat of severe pain (*coccygodynia*), which may necessitate removal of the coccyx. The parts are supplied by the posterior divisions of the second, third, and fourth sacral, and anterior and posterior divisions of the fifth sacral, and coccygeal nerves. *Dislocation* may also occur at this joint, or it may be diseased, the coccyx sometimes projecting into the rectum. In old age the coccyx becomes ossified to the sacrum.

The pelvis is divisible into two portions—an upper, the FALSE PELVIS, bounded by the iliac blades and above the level of the ilio-pectineal line, and a lower, the TRUE PELVIS, bounded behind by the sacrum, coccyx, and pelvic portions of the pyriform muscles; laterally by the innominate bone, covered by the obturator internus; in front by the pubic bones and symphysis; above by the ilio-pectineal lines; and below by the pelvic diaphragm, formed by the pyriformis, sacro-sciatic ligament, coccygeus, levator ani, and triangular ligament. Within the pelvis, but below the pelvic diaphragm, are the ischio-rectal fossæ.

The **pelvic cavity** is lined by the PELVIC FASCIA, which is continuous with that of the deep surface of the abdominal wall—namely, the transversalis fascia in front and laterally, and that of the ilio-psoas and quadratus lumborum behind. It consists of parietal and visceral layers, the former running down over the brim of the true pelvis to which it is attached, and then covering the obturator internus and pyriformis, to be inserted below into the rami of the pubes and ischium and tuber ischii. The portion of this parietal layer lining the true pelvis is called the *obturator fascia*. In front it forms the posterior layer of the triangular ligament. At the level of the origin of the levator ani muscles laterally, and in a line from the back of the symphysis to the ischial spine (the *white line*), this parietal pelvic fascia gives off a *visceral* layer, which runs on the abdominal surface of the levator ani to meet its neighbour of the other side, giving off processes to the bladder and rectum in both sexes, and, in addition, to the prostate and vesiculi seminales in the male and the vagina in the female. This visceral layer is frequently called the *recto-vesical fascia*.

The prostate, neck of the bladder, vesiculi seminales and base of the bladder between them, and last $2\frac{1}{2}$ inches of the rectum are excluded by the attachment of the visceral layer of pelvic fascia from the pelvic cavity. The *internal iliac vessels* and branches lie on the pelvic aspect of the pelvic fascia, and thus

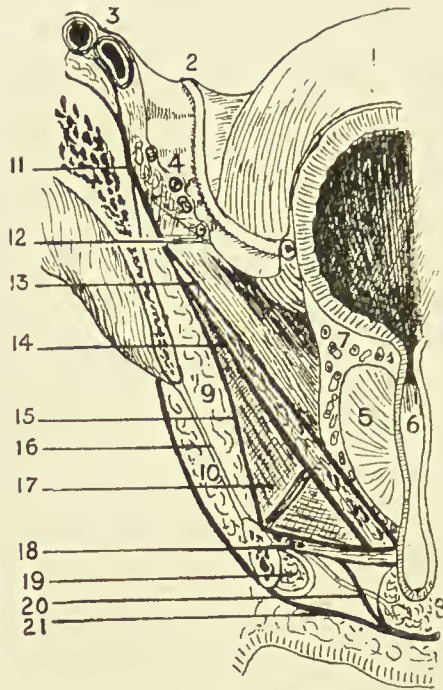


FIG. 29.—ANTERIOR VERTICAL SECTION OF PELVIS FROM FRONT.
(Modified from Testut.)

- | | |
|-------------------------|---|
| 1. Bladder. | 13. Recto-vesical fascia. |
| 2. Vas deferens. | Levator ani muscle between 13 and 14. |
| 3. Iliac vessels. | 14. Anal fascia. |
| 4. Obturator vessels. | 15. Obturator fascia. |
| 5. Prostate. | 16. Obturator membrane. |
| 6. Urethra. | 17. Ischio-rectal fossa. |
| 7. Prostatic plexus. | 18. Two layers of triangular ligament and compressor urethræ and pudic vessels (superficial layer of triangular ligament=deep perineal fascia). |
| 8. Bulb. | 19. Corpus cavernosum. |
| 9. Obturator internus. | 20. Expansion from superficial layer of triangular ligament to invest bulb. |
| 10. Obturator externus. | 21. Deep layer, superficial fascia. |
| 11. Iliac fascia. | |
| 12. White line. | |

their perforating branches are ensheathed by the fascia as they leave the pelvis ; whereas the spinal nerves lie outside the fascia. The *obturator vessels* and nerves form an exception to the rule, passing through a special aperture in the pelvic wall. Separating the parietal pelvic fascia from the peri-

toneum and uncovered pelvic viscera is a *loose layer of fatty tissue*, corresponding to the extraperitoneal fatty tissue of the abdomen, with which it is continuous. This tissue is also continuous with the connective tissue of the hip through the obturator and sacro-sciatic foramina, and in it are the iliac vessels, ureters, lymphatic glands, vasa deferentia, and round ligaments. While this tissue is continuous throughout, it is shut into compartments by septa running in from the level of the sacro-iliac articulation between the bladder and rectum in the male, and uterus and rectum in the female. To inflammatory conditions occurring in this layer, the term *pelvic cellulitis* is properly applied.

The PELVIC PERITONEUM, continuous with that of the abdomen, partially lines the cavity, and possesses generally lax parietal but firm visceral attachments. Owing to its being thrown into folds by underlying structures, the pelvic peritoneum presents *three fossæ*—an anterior, middle, and posterior—which are at different levels, the anterior being the highest, and the posterior the lowest (see Fig. 32).

The ANTERIOR PELVIC FOSSA contains the bladder, and is bounded in front by the symphysis, and behind by the *fold of the ureter*—a peritoneal ridge formed by the underlying PELVIC URETER, which extends from the postero-lateral aspect of the pelvis at the level of the sacro-iliac articulation to the lateral angle of the bladder. A *paravesical fossa* may be seen occupying either side of this fossa when the bladder is empty. The MIDDLE PELVIC FOSSA is narrow, particularly mesially; contains the vasa deferentia and vesiculi seminales in the male, and uterus in the female; and is bounded by the fold of the ureter in front, and by the sacro-genital fold behind. This *sacro-genital fold* projects backwards from the posterior surface of the bladder when empty as a distinct ridge fully $\frac{1}{2}$ inch deep, enclosing the upper extremity of the vesiculi seminales, the vasa deferentia, and some unstriped muscle constituting the *sacro-genital ligament*, between its layers. This ligament curves backwards, and is connected at the back of the rectum with the lower end of the anterior surface of the sacrum. This fold also exists in the female, constituting the *utero-sacral, or fold of Douglas*. The POSTERIOR FOSSA is the lowest, and contains the rectum, which, when empty, as in the case of the bladder, is bounded by a lateral depression on

either side, called the *pararectal fossa*. This posterior fossa is bounded in front by the sacro-genital folds, and behind by the sacrum, etc. The OBTURATOR FOSSA presents on the lateral pelvic wall, being bounded by the external iliac vein in front; the vas deferens, or round ligament, below; and the

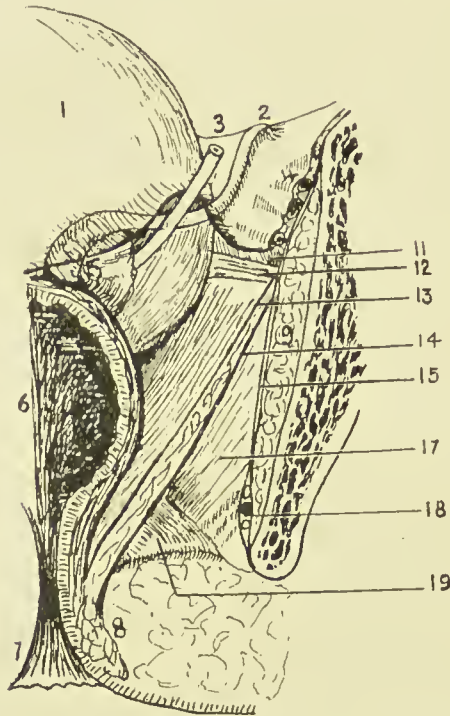


FIG. 30.—POSTERIOR VERTICAL SECTION OF PELVIS FROM BEHIND.

(Modified from Testut.)

- | | |
|------------------------|---|
| 1. Bladder. | 11. Iliac fascia. |
| 2. Vas deferens. | 12. White line. |
| 3. Ureter. | 13. Recto-vesical fascia. |
| 4. Obturator vessels. | Levator ani muscle between 13 and 14. |
| 5. Vesiculæ seminales. | 14. Anal fascia. |
| 6. Rectum. | 15. Obturator fascia. |
| 7. Anus. | 17. Ischio-rectal fossa. |
| 8. Sphincter. | 18. Pudic vessels and nerve in Alcock's canal. |
| 9. Obturator internus. | 19. Posterior extremity of triangular ligament. |

ureter behind. The pelvic attachment of the broad ligament in the female divides this fossa into two parts, of which the posterior is termed the *fossa ovarii*.

In addition to the viscera mentioned, the true pelvis frequently contains coils of small intestine, pelvic colon, and portion of cæcum and tip of the appendix, particularly when

the rectum and bladder are empty. The external iliac vessels produce a peritoneal fold at the posterior part of the pelvic brim, and then, deviating outwards toward the under-surface of Poupart's ligament, they form a triangle, bounded internally by the ilio-pectineal line, and below and in front by Poupart's ligament, which is called the *trigonum femorale*.

The AORTA bifurcates at the level of the fourth lumbar vertebra on its left side, forming the two common iliac arteries.

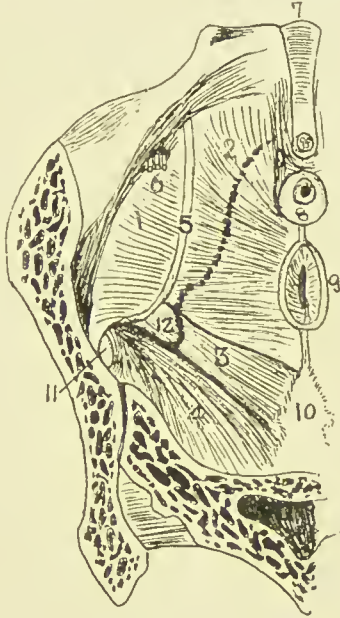


FIG. 31.—VIEW OF PELVIC BASIN FROM ABOVE.

(Modified from Testut.)

- | | | |
|------------------------|-----------------------|-----------------------------------|
| 1. Obturator internus. | 5. White line. | 9. Rectum. |
| 2. Levator ani. | 6. Obturator vessels. | 10. Coccyx. |
| 3. Coccygeus. | 7. Symphysis. | 11. Aperture for gluteal vessels. |
| 4. Piriformis. | 8. Prostate, etc. | 12. Spine of ischium. |

(Dotted line indicates outline of lower border of pelvis.)

These run down and out to the sacro-iliac articulations, where they bifurcate to form the external and internal iliac arteries. The external iliac artery, following the internal border of the psoas muscle, first runs along the pelvic brim, and then, tending outwards, reaches the under-surface of Poupart's ligament, and becomes the femoral. The internal iliac curves down into the pelvis, and divides into anterior and posterior divisions at the upper portion of the great sacro-sciatic notch.

The COMMON ILIAC on both sides is crossed near its termination by the ureter, and is also crossed by the sympathetic fibres running from the aortic to the hypogastric plexus. Occasionally, however, the ureter crosses the upper part of the external iliac artery. The left vessel is also crossed by the inferior mesenteric vessels. The right vessel is about 2 inches, and the left about $1\frac{3}{4}$ inches long. The external iliac is nearly 4 inches long. The *course* of common and external iliac vessels is indicated by a line from a point $\frac{1}{2}$ inch below, and to the left of the umbilicus, to a point on Poupart's ligament, midway between the anterior superior spine and the symphysis pubis. The line should have a slight external convexity, and the upper one-third represents the common iliac vessel.

The EXTERNAL ILIAC artery is invested by both peritoneum and extraperitoneal tissue, the latter (*fascia of Abernethy*) sending in a septum between the artery and vein. The artery is crossed near Poupart's ligament by the genito-crural nerve, spermatic vessels, and deep circumflex iliac vein. The ovarian vessels in the female cross the middle of the artery. *Ligature* of the external iliac vessel might be required for trauma or for aneurism, which at this level generally affects also the femoral artery. The ligature may be performed by opening the abdomen, or by making an incision parallel to, and above, Poupart through the abdominal wall, and then shelling the peritoneum upwards. In the abdominal method the Trendelenburg position should be used, and care is necessary to avoid the vein (lying generally behind and to the inner side), the ureter, and the genito-crural nerve. In the *extraperitoneal method* a curved incision is made, 4 inches long, commencing 1 inch above and internal to the anterior superior spine, and extending downwards and inwards to a point $1\frac{1}{2}$ inches above and external to the centre of Poupart. The superficial structures, muscles, and transversalis fascia are divided, the peritoneum exposed and reflected, until the vessel is exposed on the inner border of the psoas.

The INTERNAL ILIAC is $1\frac{1}{2}$ inches long. Its anterior division gives off (*a*) in the pelvis; vesical and middle hæmorrhoidal, and in the female, uterine and vaginal; (*b*) extrapelvically; obturator, internal pudic, and sciatic branches. The posterior division gives off ilio-lumbar and lateral sacral branches intra-

pelvically, and gluteal extrapelvically. The *obliterated hypogastric artery* constitutes the terminal portion of the internal iliac, which, in the foetus, runs up the abdominal wall to the umbilicus, to pass out with the other structures of the cord.

While for some time after birth the **BLADDER** is an abdominal organ, and spindle-shaped, in the adult it occupies the pelvis, although it rises into the abdomen when distended. The bladder lies between the symphysis in front and the rectum or vagina behind. It rests in a triangular space, formed by two lateral walls, composed of levator ani and internal obturator, covered by pelvic fascia, which converge anteriorly to the pubic symphysis and retropubic fat. Posteriorly and below, the third side is formed by seminal vesicles, vasa deferentia, and recto-vesical layer of pelvic fascia, or, in the female, by anterior vaginal wall and cervix uteri. Thus, the lateral walls and base of the bladder slope inwards and downwards to the *urethral orifice*, which is the lowest and also the most fixed portion of the bladder, being held in position by the pelvic fascia. When the bladder is much distended, the orifice is slightly depressed, while, if the rectum be distended, it is slightly raised. Normally, it lies behind and slightly below the level of the upper margin of the symphysis pubis. The upper surface of the bladder and its peritoneal relations vary according as it is full or empty. The upper surface of the contracted bladder is convex and triangular in outline, the apex lying behind the symphysis, and giving attachment to the urachus, while the postero-lateral angles mark the positions of the ureters.

The PERITONEUM, covering the urachus in front, forms the *anterior false ligament*, the reflection being situated just below the upper border of the symphysis; while laterally, being reflected about the level of the ilio-pectineal lines, it forms the *lateral false ligaments*; and posteriorly, projecting backwards, as already described, in a fold, it forms the *sacro-genital fold*, and then descends into the pelvis, forming the *recto-vesical pouch*, which extends to within an inch of the base of the prostate. When the bladder is distended, the peritoneum, in the position of the anterior false ligament, is raised, exposing, perhaps, a couple of inches of uncovered bladder above the level of the symphysis

(through which the distended bladder may be tapped), and the lateral line of reflection is also raised. Speaking generally,

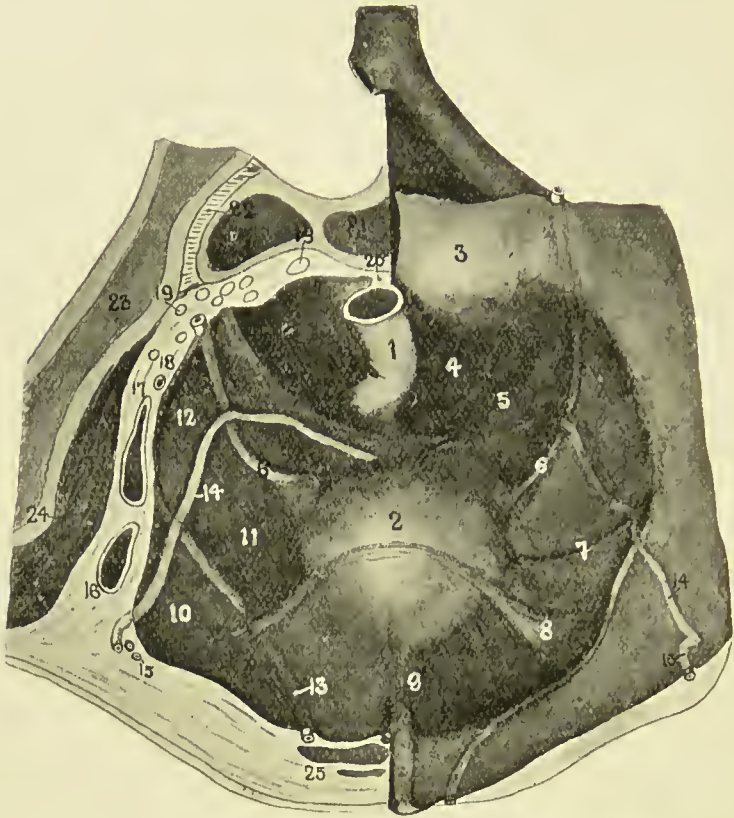


FIG. 32.—DIAGRAM OF MALE PELVIS. VIEWED FROM ABOVE. ON THE RIGHT SIDE THE PERITONEUM HAS BEEN FOLDED OVER, DISPLAYING THE RIDGES AND FOSSÆ, WHILE ON THE LEFT THE PELVIS IS SHOWN CUT IN SECTION.

(Modified from Cunningham.)

1. Rectum.
2. Bladder.
3. Sacral promontory.
4. Pararectal fossa.
5. Sacro- or genito-rectal fold.
6. Ureter.
7. Vesical artery.
8. Plica transversa vesicæ.
9. Urachus.
10. Trigonum femorale.
11. Paravesical fossa.
12. Obturator fossa.
13. Obliterated hypogastric artery.

14. Vas deferens.
15. Deep epigastric vessels.
16. External iliac artery.
17. External iliac vein.
18. Internal iliac artery and obturator nerve.
19. Sacral nerves.
20. End of pelvic mesocolon.
21. Sacrum.
22. Sacro-iliac synchondrosis.
23. Ilium.
24. Iliacus muscle.
25. Rectus muscle, with pyramidalis muscle in front and urachus to inner side.

when the apex of the bladder is 2 inches above the pubic crest, the peritoneum will be raised about $\frac{3}{4}$ inch above it, while, when the apex is midway between the umbilicus and pubes,

the peritoneum may be $1\frac{1}{2}$ to 2 inches above it. Normally, the bladder will hold about a pint, but in great distension, when the organ reaches the level of the umbilicus, or even higher, it may contain 2 or 3 quarts. The sacro-genital fold then disappears, the surplus peritoneum being taken up by the increasing size of the bladder; but the level of the recto-vesical pouch does not appreciably alter, save, perhaps, where the rectum is distended. An equilateral triangle is formed by the prostate as an apex, the vesiculi seminales as two sides, and the recto-vesical fold as base, whose sides are about $1\frac{1}{2}$ inches long (EXTERNAL TRIGONE). The bladder and rectum are adherent over this area, through which, therefore, the bladder may be tapped *per rectum*. The upper surface of the bladder is related in the male to the pelvic colon and small intestine, and in the female to the uterus; the lateral aspect is related to the levator ani, and the internal obturator muscles, parietal pelvic fascia, and vesico-prostatic venous plexus. Below and in front, the pubic bones, symphysis, retropubic fat, vesical layer of pelvic fascia, and anterior vesical veins are in relation; while the base is related to the rectum, with seminal vesicles, vasa deferentia, and recto-vesical fascia intervening in the male, and to the shallow utero-vesical pouch, cervix, and vagina in the female.

The RETROPUBIC FAT and cellular tissue is of importance surgically, as if, in doing a suprapubic cystotomy, this tissue be burrowed into, a pocket is easily formed in which material may collect and sepsis be set up, which, if it spreads, may lead to the death of the patient.

The *muscular coat* of the bladder is composed of a reticulated network of bundles, which become more marked in cases of hypertrophy, producing *fasciculation*. In cases of distension the intervening mucous membrane may yield, producing a *sacculated* bladder. In cases of *hypertrophy* the change is most marked in the anterior wall. The bladder is lined internally with *mucous membrane*, which, particularly when the organ is empty, is thrown into folds by the underlying muscular bundles to which it is but loosely attached by lax submucous tissue.

The INTERNAL TRIGONE forms an equilateral triangle at the base of the bladder, whose sides are about $1\frac{1}{2}$ inches long, and here the mucous membrane is smooth, firmly

attached to the underlying muscle, and slightly raised above that bounding its sides. At the apex of the trigone is the urethral orifice, surrounded by a slightly raised ring of mucous membrane (*annulus urethralis*), while at each of the basal angles of the triangle a ureter opens, having traversed the bladder wall obliquely for $\frac{3}{4}$ inch. The internal and external trigones practically coincide. A fine linear fold, called the *wula vesicæ*, runs from the urethral orifice backwards towards the centre of the base of the triangle, while it is also continued forward through the urethral orifice to the floor of the prostatic urethra, forming the *verumontanum*. This is most marked in cases of enlarged prostate, being situated over the middle lobe. The depression bounding either lateral wall of the triangle is called a *paratrigonal fossa*, while that bounding the base is called the *retro-ureteric fossa*. This latter often becomes large in enlarged prostate, contains a quantity of ammoniacal urine which the patient cannot pass (residual urine), and sometimes a calculus, and is called a *posterior prostatic pouch*.

The *arteries* supplying the bladder are the superior and inferior vesical of the interior iliac, the latter of which is the larger, and supplies the more vascular floor. The *veins* have a plexiform arrangement in the various coats, and join the internal iliac. Those in the region of the trigone frequently become congested, and even varicose in old persons, especially in cases of enlarged prostate. The *lymphatics* run to the glands surrounding the iliac vessels. The motor *nerves* are derived from the eleventh and twelfth dorsal and first lumbar, which pass through the hypogastric, pelvic, and vesical plexuses, and the sensory nerves from the third and fourth sacral, which pass direct to the vesical plexus. The *reflex micturition centre* is situated in the lumbar enlargement, and is normally under control of the brain. In some spinal conditions this control is lost, and the centre acts automatically, emptying the bladder when necessary at regular intervals. When, on the other hand, the centre is destroyed, *absolute incontinence* results. The trigone is richly supplied by the vesical plexus, which also supplies the seminal vesicle, vas deferens, and distal extremity of the ureter. As the skin of scrotum, and penis, and mucous membrane of urethra are also supplied by these segments,

bladder affections frequently cause pain referred to base of glans penis, etc.

The *female bladder* has a smaller capacity than that of the male. There being no prostate, the neck lies nearer the symphysis, and is very distensible, even permitting of a calculus becoming impacted in it. Indeed, *stones* of a diameter of $\frac{3}{4}$ inch have been removed by forceps after dilatation of the urethra. Through the dilated urethra, also, the orifices of the ureters may be seen and examined. The bladder wall and vagina are intimately connected, and *vesico-vaginal fistulæ* frequently occur. The utero-vesical fold of peritoneum extends down only to the junction of body and cervix of the uterus; beyond that point the cervix is loosely adherent to the posterior layer of the bladder, and the vagina intimately so.

Associated with defect in the anterior abdominal wall, the anterior wall of the bladder may be absent, the posterior wall and trigone presenting as a red vascular mass. This condition is called *ectopia vesicæ*, or extroversion of the bladder. *Hernia* of the bladder may occur through the femoral or inguinal canals, and also through the obturator and great sacro-sciatic foramina. *Prolapse* of the bladder backwards into the vagina is called vaginal cystocele, and into the rectum rectal cystocele. *Rupture* of the bladder, caused by blows or falls when the bladder is distended, generally occurs at the upper and posterior surface, which, being covered by peritoneum, causes invasion of the peritoneal cavity. The bladder may, however, be wounded, frequently about the base, and therefore extraperitoneally, by a fractured pelvis, while it has also been wounded through the sciatic notch, thyroid foramen, rectum, abdomen, etc. *Fistulæ* may connect the bladder with the rectum, colon, or vagina (a bi-mucous fistula), or with the suprapubic region, or perineum (muco-cutaneous fistulæ). Where the bladder communicates with the bowel, flatus and even fæcal matter may be passed *per urethram*. *Stones* in the bladder frequently rest upon the vascular and sensitive trigone, causing pain and hæmorrhage, but sometimes they become arrested in one of the pockets of mucous membrane. *Tumours*, such as papilloma or epithelioma, and *ulcerative processes*, such as tubercle, frequently occur in the region of the trigone. Most of these conditions become complicated sooner or later by *cystitis*, or inflammation of the

bladder wall. In order to treat such conditions it is frequently necessary to open the bladder. *Cystotomy* is generally performed suprapubically, a vertical incision being made immediately above the pubes, after the bladder has been distended, so as to raise the peritoneum. The superficial tissues are cut, recti and pyramidales separated, transversalis fascia divided, prevesical fat pushed aside, and the bladder exposed and treated. The bladder may also be reached through the perineum, vagina, or rectum, but the latter route is seldom employed, and is dangerous. Stones are sometimes extracted entire *per urethram* in the female, and in the male by previous crushing (lithotrity) and washing out through a large catheter (litholopaxy).

THE URETHRA.

The FEMALE URETHRA, $1\frac{1}{2}$ inches long, runs downwards and forwards in a slight curve, pierces the triangular ligament, between the layers of which it is surrounded by the compressor urethræ, and ends at the external orifice 1 inch below and behind the clitoris and between the labia minora. The posterior wall is closely associated with the anterior vaginal wall, the peritoneum only dipping in between the postero-superior wall of the bladder itself and the body of the uterus. The canal normally is about $\frac{1}{3}$ inch in diameter, but is very distensible, so that calculi may be passed or extracted *per urethram* in the female. Stones up to $\frac{3}{4}$ inch diameter may be so removed. A small vascular papillomatous tumour, which is painful, may occur about the orifice of the urethra, and is called a *urethral caruncle*.

The URETHRA IN THE MALE is fully 8 inches long, and in addition to the urine, transmits the spermatic fluid from the testicles, and the secretions from the prostate and Cowper's glands. Leaving the narrow orifice of the bladder, it passes through the prostate gland, and then, passing through the triangular ligament, enters the perineum, and penis. It is described as consisting of a prostatic, membranous, and spongy portions; and in its course it describes a *double curve*, first passing down beneath, and then up in front of the pubic arch, and then once more turning down to enter the penile portion. The first curve with the convexity downwards

is fixed, and begins and ends at the level of a horizontal line, drawn antero-posteriorly across the lower border of the symphysis, the summit lying 1 inch below the same point on the symphysis. The second curve commences at the point of attachment of the suspensory ligament, traverses the penis, and is movable.

The PROSTATIC PORTION extending from the floor of the bladder to the prostate apex is the widest portion of the urethra ($\frac{1}{2}$ inch in diameter), is about $1\frac{1}{4}$ inches long, and is almost vertical. Wider at its centre than at either extremity, it begins opposite the centre of the symphysis posteriorly, and extends to a point 1 inch behind and below the subpubic angle. The *verumontanum*, continuous with the *uvula vesicæ* of the bladder, and distally with the *crista urethralis*, which disappears at the membranous portion, forms a ridge on its posterior border, and on its summit presents an opening, leading upwards and backwards for nearly $\frac{1}{2}$ inch, called the *prostatic utricle* (or sinus pocularis), which is the homologue of the uterus and vagina of the female. The *ejaculatory ducts* open on either side of this utricle, while the larger *prostatic ducts* open into grooves, the *prostatic sinuses*, on either side of the verumontanum.

The MEMBRANOUS PORTION is the shortest, measuring about $\frac{3}{4}$ inch; narrowest, except the meatus ($\frac{1}{3}$ inch in diameter); and is also the most fixed, lying between the two layers of the triangular ligament, and surrounded by the fibres of the *compressor urethræ*, which may produce what is called *spasmodic stricture*. It is separated from the subpubic ligament by the dorsal vessels and nerves of the penis, together with loose connective tissue.

The SPONGY PORTION is the longest, over 6 inches, and extends from the anterior layer of the triangular ligament to the meatus. Almost immediately after piercing the triangular ligament, the urethra enters the bulb $\frac{1}{2}$ inch from its posterior extremity, and traverses its dorsal aspect, receiving the orifices of the ducts of *Cowper's glands* on its lower wall. The diameter of the spongy portion is considerable at the bulb, and thereafter is fairly uniform, save near the meatus. It presents numerous small lacunæ and ducts of mucous glands, which open obliquely in the direction of the meatus, particularly on the floor of the canal. The *fossa navicularis*

is a dilatation on the dorsal aspect, situated just beyond the meatus. A small recess, termed the *lacuna magna*, sometimes opens off it. The *external meatus* is the narrowest portion of the entire canal, measuring not more than $\frac{1}{4}$ inch in diameter. As the external meatus is the narrowest part of the urethra, a catheter which will pass that point will pass into the bladder if the canal be normal. The canal generally is only a potential one, and presents as a vertical slit at the meatus, and in the region of the fossa navicularis, and as a horizontal slit at other places.

In *introducing a catheter*, the penis is directed upwards, so as to obliterate the double curve, and, once the catheter has passed the fossa navicularis, its point is directed constantly toward the roof of the canal, as, if it be small, it might otherwise engage in the ducts opening on the floor. The point where difficulty is most likely to be experienced is at the junction of the wide movable penile and narrow fixed membranous portion, and here, if the point be allowed to pass along the floor, which is very dilatable at this point, it will probably not enter the narrow membranous canal, but rupture the urethra, making a *false passage* in the bulbous portion in front of the triangular ligament. To avoid this mistake, the handle of the instrument, which hitherto has been lying on the groin or abdomen of the patient, should now be steadily raised, so as to keep the point on the firmer roof, and usually it then slips in without any application of force.

Stricture from gonorrhœa generally affects the spongy portion, whereas stricture following trauma (as rupture from a fall stride-legs) generally affects the membranous portion. A primary syphilitic sore, occurring just within the urethral orifice, may cause stricture at that part. In cases of stricture, not merely is the canal narrowed, but it frequently is rendered tortuous, rendering catheterization very difficult, and greatly increasing the risk of making false passages. When the urethra is torn, whether by trauma, as in a fall stride-legs, by fractured pelvis, false passage, or ulcerative processes, **EXTRAVASATION OF URINE** is liable to occur. Where the membranous portion is torn, the extravasation takes place *between the layers of the triangular ligament*, by which it is confined, until set free by sloughing, generally of the anterior layer, when it enters the perineum. Where the bulbous

portion is affected, the urine is extravasated *in the perineum* between the anterior layer of the triangular ligament and the deep layer of the superficial fascia (Colles's fascia).

COLLES'S FASCIA is attached posteriorly to the base of the triangular ligament, and laterally to the rami of the pubes and ischium, and thus the urine, as it accumulates, is forced to run forwards. Colles's fascia is *continuous* with the dartos of the scrotum, and superficial fascia of the penis, while, by a funnel-shaped process running in front of the cord, it communicates with the superficial fascia of the abdomen. Thus the extravasated urine first distends the perineum, then the scrotum and penis, and then finds its way on to the front of the abdomen, whence it is prevented reaching the thigh by the attachment of the fascia to Poupart's ligament. The urethral mucous membrane is supplied by the pudic nerve.

MALE ORGANS OF GENERATION.

The **PENIS** is described as consisting of a root and body. The **ROOT** consists of the *bulb of the corpus spongiosum*, which lies in the middle line in front of the anterior layer of the triangular ligament, and of the *corpora cavernosa*, which are attached at either side to the rami of the pubis and ischium. These three structures meet under the pubic arch, where they are fixed by strong connective-tissue bands, and fuse to form the **BODY** of the penis. They are further supported by a fascial *suspensory ligament* from the front of the pubis, and are so arranged that one of the corpora cavernosa occupies either side, while in a sulcus on the deep surface lies the corpus spongiosum, with the urethra embedded in it. Toward the point of the penis, however, the corpus spongiosum ascends, and, spreading out, forms the *glans penis*. The corpora cavernosa are surrounded by a fibrous envelope, the *tunica albuginea*, and are imperfectly separated from one another by the *septum pectiniforme*. They consist, like the corpus spongiosum, of cavernous tissue, and each presents, close to the septum, an artery to the corpus. In gonorrhœal affections the corpus spongiosum may be rendered indistensible, so that in erection of the penis it remains contracted, thus producing curvature of the organ. Superficially the organ is enveloped in a thin *skin*, which, owing to the lax subcutaneous tissue, is very

mobile. Thus it is necessary in performing *circumcision* to see that an excessive amount of skin is not pulled forward and removed. The *subcutaneous tissue*, traversed by the *dorsal vein of the penis*, is very lax, and becomes much swollen when œdematous or when extravasation of urine has occurred.

Under the subcutaneous tissue is the *fascia penis*, which is continuous with the fascia of Colles in the perineum. The *prepuce* is formed of a reduplication of the skin, which covers the glans and neck of the penis. It is attached on the under surface to the glans by the *frænum*. Where the prepuce is long and so narrow that it cannot be retracted from the glans, the condition is known as *phimosis*. Where the prepuce, having been drawn back, forms a constriction round the base of the glans and cannot be returned, the condition is called *paraphimosis*. The lax tissue about the corona enables the Hunterian chancre to develop characteristically, with marked induration; whereas on the glans the submucous tissue is practically absent, and the mucous membrane very adherent.

Certain *congenital defects* may occur in the penis. The cloaca is divided into an anterior urogenital canal, and a posterior rectum, by the coalescence of two lateral folds. The upper portion of the canal receives the ureters and forms the bladder, and the lower portion forms the prostatic and membranous portions, receives the *ducts of Wolff and Müller*, and opens in front of the anus as the *urogenital sinus*. At the apex of this sinus a small genital tubercle appears, and on either side a genital fold, while posteriorly the sinus is separated from the rectum by the perineal septum. In the male the penis is formed from the genital tubercle, which elongates, while a furrow appears on its ventral aspect. This furrow deepens, the lateral margins curve round the groove and coalesce at the median raphe, and thus the spongy urethra is formed. This process of fusion proceeds from behind, forwards. By the coalescence of the genital folds, the scrotum is formed. In the female the tubercle forms the clitoris and the folds the labia majora, while the ducts of Müller coalesce to form the uterus and vagina. *Hypospadias*, where the imperfect urethra opens on the ventral surface of the penis, may be complete, the urethra opening at the base of the penis, or the scrotum may even be cleft (the testicles partially descended or retained), and the urethra open behind it, the parts

thus resembling the female organs (pseudo-hermaphroditism). In less severe cases the urethra may open under the glans or body of the penis. In *epispadias* the penis has either been cleft from above or has become twisted. Usually the organ is badly developed, and the severer forms are frequently associated with *extroversion of the bladder*.

The penis is supplied by branches of the *internal pudic artery*, the blood returning directly or through the *dorsal vein* to the *prostatic plexus*. The *nerves* are derived from the internal pudic and hypogastric plexus, the latter supplying the erectile tissue. The pudic supplies the greater part of the skin, and also the muscles and mucous membrane of the urethra. Thus urethral irritation frequently gives rise to erection of the penis (*e.g.*, gonorrhœal *chordee*), and a similar result may be caused by the collection of smegma under the prepuce, while it is possible that such forms of irritation may also give rise to spasm of the urethral muscles.

The **PROSTATE** has been compared in size and shape to a Spanish chestnut. It is $1\frac{1}{4}$ inches long, $1\frac{1}{2}$ inches broad, and $\frac{3}{4}$ inch in antero-posterior depth. Normally it weighs 6 drams, but may be considered to be enlarged when it weighs an ounce and measures 2 inches from side to side. Its base is firmly attached to the base of the bladder, and its apex, directed downwards and forwards, is related to the posterior layer of the triangular ligament and the compressor urethræ muscle. It is situated about $\frac{3}{4}$ inch below the symphysis pubis, and $1\frac{1}{2}$ to 2 inches from the anus. It is traversed by the urethra, which runs almost vertically through it, with a slight anterior concavity at the junction of its anterior one-third with the posterior two-thirds, and emerges just in front of its apex. The *pre-urethral* segment is mainly composed of smooth muscular tissue, and is separated from the pubis by fatty tissue and its own capsule. The *retro-urethral* segment presents two lateral lobes not separated superficially, and an upper wedge-shaped portion or so-called *middle lobe*, which lies immediately beneath the trigone, and is separated from the underlying lateral lobes by the *ejaculatory ducts*, which, entering the prostate posteriorly, run downwards, forwards, and inwards, to enter the urethra close together on the summit of the verumontanum, which occupies the posterior wall of the prostatic urethra.

The lateral lobes contain a considerable proportion of glandular tissue. The glands are irregularly arranged, are lined by columnar epithelium, and their ducts pierce the floor of the urethra on either side of the verumontanum. The unstriped muscular tissue is best developed in the cortical portion of the gland, and in that surrounding the urethra. Surrounding the prostate, and particularly occupying a deep sulcus between the base of the bladder and the mass of the gland, is a rich venous plexus, the *vesico-prostatic plexus*. These veins are tortuous and well supplied with valves, but in cases of prostatic enlargement they frequently become *dilated and varicosed*, and, indeed, they frequently play a considerable part in rapidly occurring urethral obstruction caused by prostatic enlargement. In addition to its own *proper capsule*, composed of connective tissue and unstriped muscular fibres, the prostate possesses a tough *fibrous capsule*, derived from the recto-vesical layer of pelvic fascia, which encloses both the gland and the venous plexus.

Prostatitis, or inflammation of the prostate, is generally, when acute, due to urethral infection, frequently gonorrhœa, and may give rise to *prostatic abscess*, which may be single or multiple. Such abscesses, if untreated, generally burst into the urethra, sometimes into the rectum, and occasionally into both, causing a *fistula*. They may also discharge into the pelvic cellular tissue and point above Poupart, or even in the perineum, but this is unlikely, as the pubo-prostatic ligaments of the pelvic fascia are dense, and cut off the prostate from the pelvis on the one hand, while the prostatic capsule is continuous with the lower border of the posterior layer of the triangular ligament on the other. Prostatic abscess is acutely painful, owing to this dense encapsulation; and as the gland derives its *nerve-supply* from the lower three dorsal (especially the tenth) and upper three sacral segments, the pain may be referred over a wide area, between the tip of the last rib and soles of the feet. The *lymphatics* pass to glands situated on the pelvic wall between the external and internal iliac vessels. A *thrombo-phlebitis* may be caused by invasion of the prostatic plexus. Prostatic abscesses may be evacuated by a mesial perineal incision between the bulb and the anus through the skin, cellular tissue, *perineal body* (a mass of fibrous and fatty tissue), base of the triangular liga-

ment, compressor urethræ, levator ani, prostatic capsule, and gland substance. Chronic inflammatory conditions of the prostate are generally due to *tubercle*, affecting the vesiculi seminales, testicles, or bladder.

SENILE PROSTATIC HYPERTROPHY, occurring after the age of fifty-three, is the most common affection of the gland, generally due to irregular new gland-like formation. The prostatic urethra is elongated, compressed laterally, and its curvature increased, the outlet of the bladder being raised, and hence micturition is impeded, and the posterior prostatic pouch is liable to form. Frequently also the urethra may become twisted, owing to unilateral enlargement. Owing to the alteration in length and curve of the prostatic urethra, it is frequently necessary to use a *prostatic catheter* in enlarged prostate. A gum-elastic *coude* catheter may also be employed with advantage. In such cases the gland may be *removed* by a suprapubic operation, or through the perineum (prostatectomy), or it may generally be caused to atrophy by division of the vasa deferentia, or by castration. In the former, while the prostatic urethra is of course much damaged in removal of the gland, the external capsule remaining intact prevents the risk of extravasation of urine, while in the latter the perineal wound affords free drainage. The function of the prostate is supposed to be the secretion of a thin milky acid fluid, which acts as a vehicle for the spermatozoa, and stimulates them to activity. While it affords support to the urethra, it probably does not assist micturition.

The **vesiculi seminales**, about 2 inches long, roughly triangular in section, and presenting a tuberculated appearance, are situated at the base of the bladder, to which their anterior surfaces are applied, while their posterior surfaces are moulded on the anterior rectal wall. The upper extremities are wide apart, are partially invested by the peritoneum of the rectovesical pouch, and are separated from contact with the bladder-wall by the termination of the ureters, while the pointed lower extremities lie close together in the transverse fissure at the base of the prostate, where they join the outer aspect of the corresponding vas, from which point the common ejaculatory ducts pass down close together through the prostate, to open on the summit of the verumontanum. The vesiculi seminales are enclosed in a sheath derived from the

recto-vesical fascia. They may be affected by acute or chronic *inflammatory processes*. The former, frequently gonorrhœal, may lead to abscesses, which may burst into the peritoneum, rectum, or perineum. The latter are generally secondary to tubercular epididymitis. The vesiculi seminales may be reached by a curved incision in front of the anus.

The **vas deferens**, some 18 inches long, and extending a distance of about 12 inches, continues the canal of the epi-

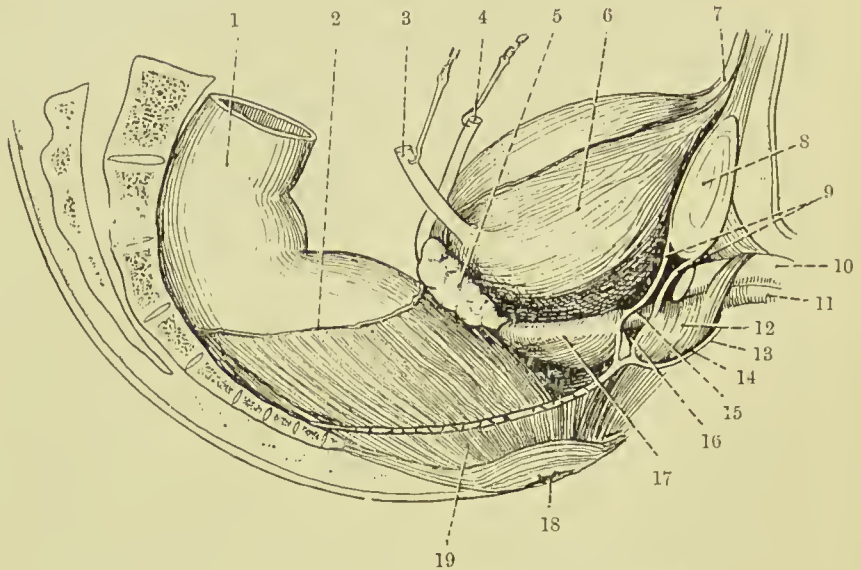


FIG. 33.—THE VISCERA OF THE MALE PELVIS (LATERAL VIEW).
(From Buchanan's "Anatomy.")

- | | |
|------------------------------------|---------------------------------|
| 1. Pelvic colon. | 11. Corpus spongiosum. |
| 2. Line of peritoneal reflection. | 12. Bulb and bulbo-cavernosus. |
| 3. Ureter. | 13. Colles' fascia. |
| 4. Vas deferens. | 14. Perineal pouch. |
| 5. Vesicula seminalis. | 15. Membranous urethra. |
| 6. Bladder. | 16. Cowper's gland. |
| 7. Urachus. | 17. Prostate gland and capsule. |
| 8. Symphysis pubis. | 18. Anus. |
| 9. Triangular ligament of urethra. | 19. Levator ani (cut). |
| 10. Corpus cavernosum. | |

didymis to the *ejaculatory duct*. It may be divided into an abdominal and external portion. From the point where it opens into the ejaculatory ducts, the vas runs upwards along the inner border of the vesiculi seminales, and becomes wider and tortuous and sacculated for a short distance, this portion being called the *ampulla*. At the apex of the vesiculi it passes between the ureter and bladder, and then turns forwards, upwards, and outwards along the lateral pelvic wall, immedi-

ately under the peritoneum, and crosses the vesical vessels, obturator vessels, and nerve, and obliterated hypogastric artery. On reaching the pelvic brim, it crosses the ileopectineal line fully $1\frac{1}{2}$ inches from the pubic spine, and then runs forwards and outwards, turns round the outer side of the deep epigastric artery, and enters the inguinal canal by the internal ring. In the inguinal canal it is joined by the other structures of the spermatic cord, to which it lies posterior, and runs downwards, inwards, and a little forwards to the external ring, after emerging from which it turns downwards over the pubic crest. Then, leaving the other structures of the cord, and becoming thinner and tortuous, it passes down along the inner side of the epididymis, with which it becomes continuous at the globus minor.

The **spermatic cord** consists of the vas deferens and cremaster muscle, artery to the vas, cremasteric and spermatic arteries, pampiniform plexus of veins, genito-crural and sympathetic nerves, and lymphatics. The vas deferens lies at the posterior aspect of the cord, and imparts a firm, cord-like sensation to the examining fingers. It has been ruptured in severe exertion, and is sometimes tied in cases of enlarged prostate.

The **TESTICLE**.—The **epididymis**, composed of a much-convoluted tube some 20 feet long, is applied to the posterior border of the testicle, from which it is separated by an involution of the serous covering, forming a groove called the *digital fossa*. It presents a *body* connecting globular upper and lower extremities, the former and larger being called the *globus major*, and the latter the *globus minor*. The tube begins in the globus major, where it receives the seminal fluid through some twenty minute *vasa efferentia*, which pierce the tunica albuginea to reach it, and ends at the globus minor in the vas deferens. Attached to the globus major, one or more small pedunculated bodies, called *hydatids of Morgagni*, are frequently present, and above the globus major a similar, but larger, body, called the organ of Giraldés, or *paradidymis*, is occasionally met with. These bodies probably give rise to certain forms of *hydrocele* and *spermatocele*. The epididymis is covered by the tunica vaginalis on its exposed parts, except over the greater portion of its posterior border. It is chiefly by this exposed border of epididymis that the

testicle is fixed *in situ*, where it remains even in large hydroceles.

The **testicle** body, about $1\frac{1}{2}$ inches long, 1 inch from before backwards and rather less in thickness, is suspended in the scrotum, with its long axis directed upwards, slightly forwards, and outwards. The left testicle hangs at a lower level than the right, and this is given as one reason for the prevalence of *varicocele* on the left side. The testicle is enveloped in a tough white inelastic coat called the *tunica albuginea*, which sends in septa to its interior, and which is perforated by the vessels and lymphatics at the posterior border, where the tunic and septa meet, forming a fibrous mass called the *mediastinum testis* (corpus Highmori). It is partly owing to the unyielding character of this coat that acute affections of the testicle are generally very painful.

The TUNICA VAGINALIS resembles the peritoneum, from which it is derived, in structure and also in its relationship to the testicle which it encloses. It is a shut sac into which the testicle is invaginated. Hence there is a *visceral layer* enveloping the testicle, dipping into the digital fossa, and covering the epididymis, save at the point of exit of the various structures of the cord, and a *parietal layer* which lines the scrotal sac. In HYDROCELE of the tunica vaginalis the sac may attain a very large size, holding many pints, and when tapping such conditions in order to draw off the fluid, it is important to remember that the testicle lies on the posterior surface, a short distance from the bottom. Distension of the tunica vaginalis with blood is called *hæmatocele*.

The testicle is supplied with blood by the *spermatic artery*, a branch of the aorta, which traverses the cord to reach it, and anastomoses with the artery to the vas. The blood is returned by a series of veins which, issuing on the posterior border of the testis, form a dense plexus called the *pampiniform plexus*. This plexus is of importance surgically, as it frequently becomes varicosed, particularly on the left side, giving rise to the condition known as VARICOCELE. In addition to the fact that the left testicle hangs lower than the right, there are several anatomical reasons for the predominance of left-sided varicocele: On the right side the spermatic vein (which receives the blood from the plexus) is valved, and discharges its blood obliquely into

the inferior vena cava, whereas on the left it is frequently not valved, and discharges its blood at right angles into the renal vein. Further, the left vein is subject to pressure from a distended colon or sigmoid. Some small veins also run up along the vas accompanying its artery. The *lymphatic vessels* of the testicle pass up along the cord to the lumbar lymphatic glands. The *nerve-supply* is derived from the tenth dorsal segment through the aortic and renal plexuses, and communicates on the lower part of the vas with branches from the hypogastric plexus. Thus, kidney and testicle are closely associated in nerve-supply, and the testicle is in direct communication with the solar plexus and semilunar gangliæ, which are associated with the termination of the vagus. Hence, *injury* to the testicle frequently causes collapse and a marked tendency to vomit, while pain is generally felt in the renal region in testicular neuralgia, and conversely the testicle is retracted in passage of renal calculus, etc. The epididymis receives its nerve-supply from the pelvic plexus. The *artery to the vas*—a branch of one of the vesical arteries—accompanies it to the testicle, where it anastomoses with branches of the spermatic artery. The vesiculi seminales are supplied by the inferior vesical artery. Both vasa and vesiculi are supplied by branches of nerve from the hypogastric plexus.

Many of the *affections* to which the testicle is liable resemble in outward appearance an inguinal scrotal hernia. *Hydrocele* of the tunica vaginalis, and of the cord, and varicocele have already been described.

The testicle itself may be affected by (*a*) tubercle, which first affects the epididymis (epididymitis), and is chronic; (*b*) gonorrhœa, which also first affects the epididymis, but is acute (epididymitis); (*c*) syphilis, which first affects the body of the testicle (orchitis); and (*d*) sarcoma, which rapidly involves both body and epididymis, and spreads up the cord. Sarcoma is very malignant, and might almost be described as subacute, the lungs rapidly becoming involved, unless early castration be performed. The testicle may retain its foetal position within the abdomen (*cryptorchismus*), or it may descend to about the position of the external abdominal ring, and resemble an *inguinal bubonocèle*, or hernia, which has not descended into the scrotum. To this form of testicular displacement, as well as that first described, the term *undescended*

testicle may be applied. Sometimes also the testicle may descend, but becomes turned—*inversion of the testicle*—so that it lies in front of the tunica vaginalis, and would therefore be liable to be wounded in the ordinary method of tapping a hydrocele. Where the testicle has not fully descended, attempts may be made to bring it down by operation and fix it in position, and if these attempts do not succeed, it is generally safer to remove it, lest malignant degeneration occur.

In removing the testicle—*castration*—it is generally advisable to cut the vas far up, so as to get beyond the disease, if possible ; to fix the cut end to the abdominal parietes after ligature and disinfection ; and to ligature the other structures of the cord separately.

The **scrotum**, in which the testicles are lodged, consists originally of two lateral folds, one on either side of the urogenital furrow. In the female these folds remain separate, and form the labia majora. In the male they coalesce, the median raphe marking the line of coalescence. The *integument* of the scrotum is thin and delicate, and the subcutaneous tissue is devoid of fat, and contains a layer of unstriped muscle, called the *dartos tunic*, by the contraction of which the scrotum may be thrown into folds. These folds, or *rugæ*, frequently lodge dirt, which, causing irritation, may set up eczema. *Chimney-sweep's cancer*, which occurs on the scrotum, was supposed to be due to soot lodging in these crevices. On the other hand, the skin is very distensible, as is seen in large hydroceles, herniæ, etc., and when thus stretched is fairly *translucent*, enabling the translucency of a contained swelling to be tested by transmitted light. The *subcutaneous tissue* is lax, and is readily affected in œdematous swelling and elephantiasis. The *interior* of the scrotum is divided into two by an incomplete *septum*, derived partly from the dartos tunic. The left compartment hangs lower than the right, and each is lined by separate tunica vaginalis, infundibuliform, cremasteric, and intercolumnar fasciæ. The scrotum is supplied with *blood* by superficial perineal branches of the internal pudic posteriorly, and external pudic branches of the femoral anteriorly. The *nerves* are derived from superficial perineal branches of the internal pudic, perineal branches of small sciatic, and from the ilio-inguinal nerve. The *lymphatics* run to the inguinal glands.

FEMALE ORGANS OF GENERATION.

The **UTERUS** is 3 inches long, 2 inches wide at its broadest part, and its canal, including the cervical portion, is $2\frac{1}{2}$ inches long. It weighs about 1 ounce. It is composed of an upper expanded portion, the *fundus*, which ends at the level of the Fallopian tubes, a *body*, and a *cervix*, the junction of the two latter being occasionally marked externally by an isthmus, while internally there is a marked constriction at this point called the *internal os*. The cervix is about 1 inch long, and is invaginated into the vagina, so that its lower extremity, or *external os*, projects into the lumen of the vagina, and rests against its posterior wall. Thus the cervix is divided into supravaginal and vaginal segments. As the uterus is normally both anteflexed (angle of 120 degrees) and anteverted, it meets the vagina at a considerable angle, and the anterior vaginal wall therefore is shorter than the posterior.

The *peritoneum* covers the entire posterior surface of the uterus, except the vaginal portion of the cervix, and extends down over the posterior vaginal wall for about $\frac{1}{2}$ inch, forming *Douglas's pouch* (recto-vaginal or recto-genital pouch), after which it is reflected on to the rectum. In front it extends down to the junction of the body and cervix, and is then reflected on to the bladder. Laterally, the peritoneum extends out from the uterus in a double layer to the pelvic wall, constituting the broad ligament, while a small fold, called the *sacro-genital fold*, extends on either side from the posterior wall of the cervix to the side of the sacrum. These latter folds contain connective tissue and unstriped muscular fibres, and form lateral boundaries to Douglas's pouch. The uterus possesses a large range of movement, rising and falling according to the condition of the bladder, lying frequently a little to one side of the middle line, especially to the right, while on bimanual examination it may be moved through a considerable area without causing pain. As the cervix is more fixed than the fundus, the organ is frequently *flexed* at the junction of these parts, and this flexion may be pathological and either anterior (anteflexion) or posterior (retroflexion). *Retroversion* of the whole organ may also occur, and likewise *prolapse*, or *procidentia*, where the organ descends through the vagina, which is turned inside out, the bladder frequently being

directed downwards also, while the ureters become dilated in consequence of obstruction.

The CAVITY OF THE UTERUS normally is practically a triangular slit, whose apex is at the *internal os*, and whose basal angles correspond to the uterine ostia of the Fallopian tubes, while the *cervical canal* is spindle-shaped, wider at the centre than at either extremity, its mucous membrane being thrown into folds radiating upwards and outwards from the middle line in front and behind (*arbor vitæ*). Inflammation of the uterus, *metritis*, frequently gives rise to pelvic cellulitis (*parametritis*), large abscesses occurring in the parametrium (*q.v.*), which, if untreated, may burst into the vagina or point above Poupart. The veins also may become affected, causing *thrombosis*, which may extend to the internal and even common iliac veins. In such cases swelling of the whole lower limb (*phlegmasia alba dolens*) occurs, and pyæmia may also be set up. Pelvic peritonitis (*perimetritis*) may be caused by extension of septic matter from the interior of the uterus along the Fallopian tubes.

Carcinoma frequently occurs in the cervix, spreads thence locally, involving the parametrium, ureters, bladder, and rectum, and later by the lymphatics. *Fibro-myoma* of the uterus is very common, and frequently attains a large size. Such tumours are classified according to their position as submucous, interstitial, and subperitoneal. Removal of the uterus may be accomplished through the abdomen (*abdominal hysterectomy*) or through the vagina (*vaginal hysterectomy*). In the former a median vertical abdominal incision is made, the broad ligaments ligatured and cut, the vagina cut through, and the uterus with its appendages removed. Care must be taken to avoid the ureters. In vaginal hysterectomy, the uterus is drawn down, the vagina divided, the bladder reflected, the broad ligaments drawn down and ligatured in detachments, and the uterus finally removed. Care is here especially necessary to avoid the ureters. *Anteriorly*, the uterus is related to the *utero-vesical pouch* of the peritoneum down almost to the cervix, and below this, for fully $\frac{3}{4}$ inch, is loosely attached to the posterior bladder wall by connective tissue; *posteriorly* to the pelvic colon and small intestine, except when, the rectum and bladder being distended, these coils are displaced upwards and the rectum

itself forms the posterior relation. *Laterally*, the uterus is related to the broad ligaments and ureters.

The *uterine artery*, from the anterior division of the internal iliac or one of its larger branches, descends on the lateral pelvic wall in front of the ureter, runs inward in the parametrium, crossing the ureter above the lateral vaginal fornix, and then turns up along the lateral border of the uterus, until, at the level of the ovarian ligament, it divides into its terminal branches. In its upward course the artery is very tortuous, and gives off many branches, which anastomose with those from the opposite side, and with branches from the ovarian artery, while its branch to the ovary anastomoses with the ovarian artery, and that to the round ligament with the deep epigastric artery. The uterus is also supplied by the uterine branch of the *ovarian artery*. The vessels in the uterine wall run transversely to the length of the organ. Ligature of the uterine artery has been done in the hope of arresting the growth of a uterine tumour. The *uterine veins* are thin-walled, and originate in cavernous spaces in the middle coat of the uterus, whence, emerging chiefly about the cervix, they unite with those from the vagina to form the *utero-vaginal plexus*, which surrounds the ureter. Thence the blood is conveyed in two large veins, one on either side of the ureter, which ultimately unite and terminate in the internal iliac. During pregnancy these vessels are greatly increased in size. The *lymphatics* are arranged in three groups, in the mucous membrane, muscular coat, and subperitoneal tissue. They emerge chiefly about the level of the cervix, and join the glands about the bifurcation of the common iliac artery, while a few from the body of the uterus pass up with the ovarian vessels to the lumbar glands arranged along the aorta, and others pass to the inguinal glands along the round ligament. The *nerve-supply* of the uterus is from the second to fourth sacral nerves, while sympathetic fibres reach it from the hypogastric plexus running in the utero-sacral folds.

The **VAGINA** leading from the cervix to the vulva is about 3 inches long, and is partially occluded at its lower extremity in nulliparæ by a fold of mucous membrane called the *hymen*. It is directed downwards and forwards, is slightly curved with the convexity backwards, and is related in front to the bladder and urethra, and to Douglas's pouch and rectum

behind. It will be remembered that the cervix uteri is invaginated into the vagina, and the mucous membrane being reflected from the one to the other forms *vaginal fornices*, or recesses, anterior, posterior, and lateral. In nulliparæ the mucous membrane is thrown into transverse folds—*vaginal rugæ*. These frequently make it difficult to remove pyogenic

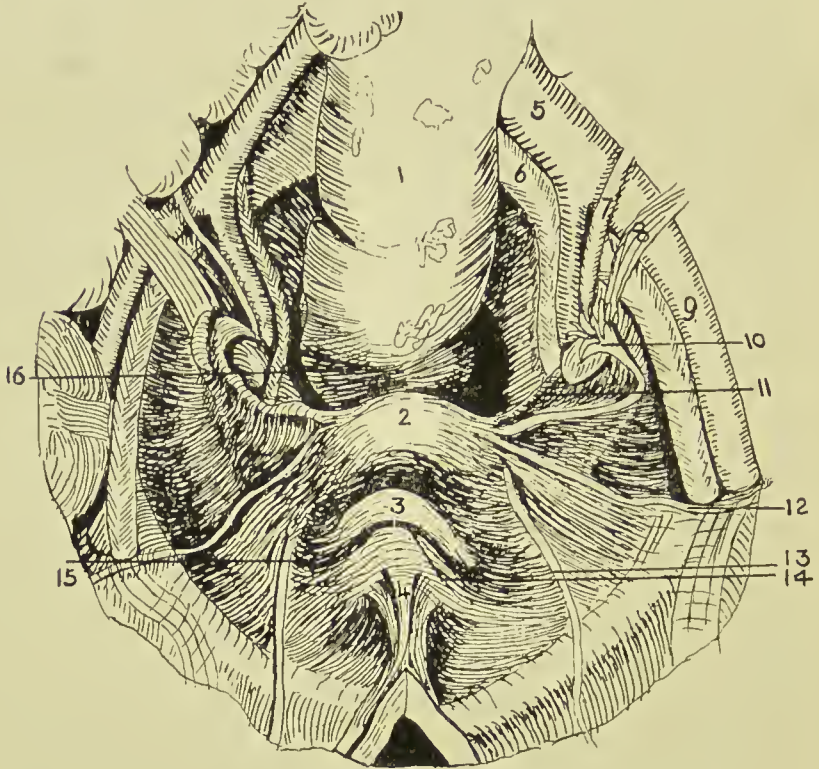


FIG. 34.—VIEW OF FEMALE PELVIC BASIN FROM ABOVE.
(After Testut.)

- | | | |
|-------------------------|-------------------------------------|-------------------------------------|
| 1. Rectum. | 7. Ureter. | 12. Round ligament. |
| 2. Uterus. | 8. Uterine vessels. | 13. Obliterated hypogastric artery. |
| 3. Bladder. | 9. External iliac artery. | 14. Plica transversa vesicae. |
| 4. Urachus. | 10. Fallopian tube and ovary. | 15. Paravesical fossa. |
| 5. Common iliac artery. | 11. Lower margin of broad ligament. | 16. Pararectal fossa. |
| 6. Common iliac vein. | | |

infection (*e.g.*, gonorrhœa), and by direct extension, endometritis may follow vaginitis. Owing to the angularity of the junction of uterus and vagina, the vagina lying almost parallel to the pelvic brim, the *anterior* vaginal wall only measures a little over 2 inches, whereas the *posterior* measures 3 inches. *In front* the vagina is but loosely attached to the trigonal

area of the bladder, but is firmly connected with the urethra. Vaginal cystotomy or urethrotomy is sometimes performed through this anterior wall. *Posteriorly*, it is only separated from the rectal ampulla by a thin layer of connective tissue (recto-vaginal septum), but lower down it is considerably separated from the anal canal by a dense mass of connective and fatty tissue called the *perineal body*. *Laterally*, it is related to the parametrium, vaginal plexus of veins, ureter, and levator ani muscle. Occasionally, by yielding of some portion of the vaginal wall, a protrusion of bladder, rectum or small intestine may occur into the vagina, producing a *vaginal cystocele*, rectocele or enterocele, and vaginal wounds have opened into the peritoneal cavity, allowing the escape of small intestine. The vaginal wall may be evaginated for examination by a finger in the rectum. Vesico-vaginal and recto-vaginal *fistulae* occur not infrequently, owing to the thinness of the vaginal walls. The *vaginal walls* are very vascular and dilatable, as is evidenced at the puerperium and in cases of retained menses. The narrowest part is the vaginal outlet, surrounded by the sphincter vaginæ muscle, and here laceration frequently occurs. A spasmodic contraction of the sphincter muscle—vaginismus—is sometimes met with. The vagina is supplied by branches of the *vesico-vaginal artery* of the anterior division of the internal iliac artery, and *vaginal branches* of the uterine and middle hæmorrhoidal arteries, and branches of the internal pudic. The *veins* form a plexus round the vagina, and drain into the tributaries of the internal iliac. The *lymphatics* from the upper part join the internal iliac group, and those from the lower part join the superficial inguinal glands. The *nerves* are derived from the third and fourth sacral and utero-vaginal and vesical plexuses.

The *Müllerian ducts* of the embryo unite at a very early period at their lower extremities to form the vagina and uterus, while their upper extremities, which open into the peritoneal cavity, form the Fallopian tubes. From imperfect fusion of these ducts a double uterus (*uterus bicornis*) may arise, while, if the condition extend to the vagina, a septum may present, partially dividing the vagina into two compartments.

The **broad ligaments** form a transverse partition of the

pelvic basin, inclined forwards at their uterine, but more vertically at their pelvic extremities, and contain between their layers ovary, ovarian ligament, Fallopian tube, round ligament, uterine, and ovarian vessels, nerves, and lymphatics, parametrium (consisting of muscular and fatty connective tissue), and vestigial remains. Quadrilateral in outline, the inner border is attached to the uterine body, supravaginal cervix, and lateral vaginal fornix; the outer border is attached to the pelvic wall, extending from the external iliac vessels and inner border of the psoas above, to the pelvic floor below, crossing the obturator fossa in its course. The upper border is free, and corresponds to the Fallopian tube in the greater part of its course, and the lower, narrow border is separated from the pelvic floor by connective tissue, containing ureter and uterine veins. The anterior surface, directed downwards and forwards, overlies the bladder; the posterior surface is related to the intestine.

Occupying the upper border of the ligament, the FALLOPIAN TUBE runs upwards and outwards and, arching round, ends in the fimbriated extremity which is attached to the upper pole of the ovary by one long fimbria—the *ovarian fimbria*. The tube is over 4 inches long, and its canal is very narrow, averaging $\frac{1}{4}$ inch in diameter. The portion immediately beyond the uterine wall is called the isthmus, and the remainder the ampulla. It opens at its fimbriated extremity into the peritoneal cavity by a funnel-shaped expansion called the *infundibulum*, $\frac{1}{5}$ inch wide, which lodges the abdominal ostium $\frac{1}{12}$ inch in diameter; and into the uterus at its upper and outer part by a minute orifice $\frac{1}{24}$ inch in diameter. The two openings are called the abdominal and uterine ostia, and thus the tube provides a direct communication between the peritoneal cavity and that of the uterus. The broad ligament surrounding the tube is frequently called the *mesosalpinx*, and both tube and mesosalpinx are frequently folded back over the upper extremity of the ovary, forming a recess, which has been called the *bursa ovarii*. Beyond the fimbriated extremity of the tube, a triangular process of the peritoneum of the upper border of the broad ligament runs up to the external iliac vessels, and encloses the ovarian vessels, nerves, and lymphatics. This process is called the *suspensory ligament of the ovary*.

Salpingitis, or inflammation of the tube, is due to infection travelling to it from the uterus—frequently gonorrhœal. In such cases the abdominal ostium may become sealed by adhesions, and the tube, dilated with pus, presents a sausage-like swelling (*pyosalpinx*). The tube may also become distended with clear fluid (*hydrosalpingitis*) in catarrhal conditions, or with blood (*hæmosalpingitis*). On the other hand, infective matter may escape into the peritoneal cavity, causing a *pelvic peritonitis*. Such peritonitis generally remains localized by many adhesions to surrounding parts. Where the ovum after impregnation becomes fixed in the tube, a *tubal pregnancy* occurs, the tube generally rupturing between the seventh and twelfth week, and frequently causing fatal hæmorrhage. The tortuous condition of the tube and the folds of its mucous membrane may be causes of obstruction to the passage of the ovum.

The **OVARY**, ovoid in shape and about $1\frac{1}{4}$ inches long by $\frac{1}{2}$ inch broad at its widest part, is situated nearly vertically, its upper pole being attached to the pelvic brim by the *suspensory ligament*, while the lower pole is connected to the uterus by the *ligament of the ovary*, which consists of a rounded fibro-muscular band, slightly over 1 inch in length, which is attached to the uterus just below and behind the point of entrance of the Fallopian tube. The outer end of the Fallopian tube arches round the upper pole of the ovary, to which the ovarian fimbria is frequently attached. Instead of lying directly in the plane between the layers of the triangular ligament, the ovary forms a projection on the posterior wall, pushing, of course, the posterior layer of the broad ligament before it as it does so, and thus forming a short mesentery, the *mesovarium*. Thus the ovary is said to possess a posterior free border (covered, however, by altered peritoneum), and an anterior border to which the two layers of the mesovarium are attached, and between the layers of which the ovarian vessels and nerves with some connective tissue and muscular fibres run. The ovary thus projecting from the posterior layer of the broad ligament is frequently accommodated in a depression in the pelvic peritoneum lining the posterior part of the obturator fossa, to which the name '*ovarian fossa*' is given. This fossa lies between the obliterated hypogastric artery in front and ureter and uterine

vessels behind, which thus form relations of the ovary, while above the ovary lie the external iliac vessels, and below, the peritoneum covering the pelvic floor. The ovary may be *palpated* by the fore and middle finger of one hand in the posterior cul-de-sac of vagina pressing up and outwards, and the fingers of the other hand flat above the centre of Poupart pressing downwards. The ovary seldom leaves its normal position, save in uterine displacements, or when affected by tumour. Occasionally, it becomes prolapsed, and may occur in *herniæ*.

Ovarian tumours are most frequently *cystic*, and generally originate from the cortical zone in the region of the Graafian follicles. Such tumours frequently attain an enormous size, and have a pedicle composed of ovarian ligament, Fallopian tube, broad ligament, etc. *Dermoids* occasionally occur, as also *sarcomata*. *Removal of the ovary*, or ovariectomy, is necessitated in such cases, the pedicle, which contains many large vessels, being carefully ligatured. Removal has also been suggested in carcinoma mammae as likely to retard the growth, but has not proved successful.

The *peritoneum* covering the surface of the ovary is altered, being nodular and covered by a layer of columnar cells. The ovary is supplied with blood by the *ovarian artery*—a branch of the aorta—and by the ovarian branch of the *uterine artery*, both of which pass to the ovary along the mesovarium. The *ovarian veins* emerge by the mesovarium, and form a plexus between the layers of the mesosalpinx. The *lymphatics* ascend by the suspensory ligament of the ovary to the lumbar glands, and the *nerves* are derived from the tenth dorsal segment of the cord through the ovarian plexus (a branch of the aortic plexus), and some branches of the uterine plexus.

The HYDATIDS OF MORGAGNI are small pedunculated cystic structures near the infundibulum of the Fallopian tube. One or more in number, they are supposed to represent the upper end of the Wolffian duct. Situated between the layers of the mesosalpinx and in its outer one-third, lying between the Fallopian tube and the ovary, is the *parovarium* (organ of Rosenmüller). This consists of over half a dozen tubes, lined with ciliated epithelium, one of which, running parallel to the Fallopian tube, is called the *duct of Gärtner*, and represents

the Wolffian duct. The remainder are homologous with the male vasa efferentia and epididymis. Also lying between the layers of the mesosalpinx, but internal to the parovarium, is the *paroöphoron*. This consists in infancy of a series of coiled tubes, representing the mesonephros, and is homologous with the paradidymis of the male.

Parovarian cysts may arise from either the parovarium or paroöphoron. They occur between the layers of the broad ligament, and are generally unilocular and filled with clear fluid.

The ROUND LIGAMENT, a fibro-muscular band nearly 6 inches in length, extends from the lateral angle of the uterus in front, and a little below the opening of the Fallopian tube, horizontally outwards between the layers of the broad ligament to the lateral pelvic wall, whence it is directed upwards and forwards to the trigonum femorale, and, curving round the deep epigastric artery, enters the internal abdominal ring. In its pelvic stage it crosses the obturator vessels and nerve, obliterated hypogastric artery, and external iliac vessels, and in the inguinal canal it is accompanied by the ilio-inguinal nerve, a process of transversalis fascia, and sometimes by a process of peritoneum called the *canal of Nuck*. It ends in the subcutaneous tissue and skin of the labium majus. The presence of the canal of Nuck predisposes to congenital inguinal hernia, and occasionally it may become distended with fluid, causing a *hydrocele* of the canal of Nuck. The round ligaments are sometimes *shortened* in order to correct retroversion or flexion of the uterus (Alexander's operation). This is done by exposing them at the external abdominal ring, pulling the anterior portions forwards on both sides, and fixing them to the parietes.

The lower subdivision of the broad ligament, that below the line of attachment of the mesovarium, is called the MESOMETRIUM, and becomes thick as it approaches the pelvic floor. Ultimately the peritoneum of the anterior layer is reflected on to the lateral pelvic wall and bladder, while posteriorly on either side it forms the *sacro-genital fold* (these folds being connected by a ridge on the posterior wall of the cervix, called the *torus uterinus*), and thence gains the lateral and posterior pelvic walls. The extraperitoneal tissue situated on either side of the cervix and upper part of the vagina, and which is continued for a considerable distance between the layers of the broad ligament, and is continuous with the extraperitoneal

tissue lining the lateral pelvic wall, etc., is called the **PARAMETRIUM**. In it run the uterine vessels, nerves, and lymphatics, and the ureter.

The **URETER** runs from the sacro-iliac articulation down and backwards to near the floor of the lateral pelvic wall, whence it enters the broad ligament. This portion is 3 inches long, and lies first in front of, or to the inner side of, the internal iliac vessels; then forms the posterior boundary of the obturator fossa, and lies immediately behind the ovary. The second portion, 2 inches long, traverses the parametrium between the layers of the broad ligament, $\frac{1}{2}$ inch above the lateral vaginal fornix, and separated from the supravaginal cervix by $\frac{3}{4}$ inch. Here it is closely enveloped in the venous plexuses, and is crossed above by the uterine artery. Thence it converges towards its neighbour of the other side, so that it is even nearer the cervix in front than laterally (and may be detected by palpation from the vagina), to enter the bladder at the basal angle of the trigone 1 inch below the level of the external os, and just above the roof of the vagina, its course through the bladder wall being very oblique, and measuring $\frac{3}{4}$ inch in length.

The term **VULVA** is applied to the female external genitals, including the labia majora and minora, clitoris, urethral and vaginal openings. The urethral orifice is immediately in front of that of the vagina, and an inch behind the clitoris, and is surrounded by slightly prominent margins. The vaginal opening is partially closed in the young by the hymen, and when this is imperforate, as it occasionally is, *retention of the menses* occurs. *Bartholin's glands* (equivalent to Cowper's), each about the size of a small bean, are situated low down on the lateral wall of the vagina, and open by slender ducts in the angle between the vagina and labium minus. Cystic dilatation, or even abscess of the duct, may occur. The *labia majora* are similar to the scrotum in nerve and blood supply and pathological tendencies. They may become very œdematous, or present large extravasations of blood, and may be affected by elephantiasis.

The **PERINEUM** is a lozenge-shaped area, nearly 4 inches long and $3\frac{1}{2}$ inches broad at the widest part, which corresponds to the outlet of the pelvis, being bounded in front by the

symphysis ; laterally by the rami of the pubes and ischium, tuber ischii, and great sacro-sciatic ligament ; posteriorly by the coccyx. Above it is separated from the pelvis by the pelvic diaphragm, consisting of the levator ani and coccygei muscles, which are covered on their pelvic aspect by the rectovesical fascia, and on their perineal aspect by the anal fascia. These muscles, originating from a line extending from near the lower border of the symphysis to the ischial spine, slope down and inwards to meet one another in the middle line, leaving, however, passages for urethra and rectum, and, in addition (in the female), for the vagina. As the muscles thus diverge from the pelvic wall, they leave a lateral space on either side, which they, covered by anal fascia, bound on the inner side, and which is bounded externally by the pelvic parietes, covered by obturator fascia, called the *ischio-rectal fossa* (see Figs. 29, 30, and 31). The perineum is subdivided into an anterior *urogenital* and a posterior *rectal triangle* by a transverse line crossing the mid-point of the perineum about 1 inch in front of the anus, and a little in front of the tuber ischii.

The UROGENITAL SPACE forms practically an equilateral triangle, whose sides are about $3\frac{1}{4}$ inches in length, and it is bounded on its deep surface by the triangular ligament. The skin and superficial fascia do not call for special comment, but the deep layer of superficial fascia—Colles's fascia—has an important surgical bearing. Attached laterally to the rami of the pubes and ischium, COLLES'S FASCIA, which is of a membranous structure, dips down posteriorly, and becomes continuous with the base of the triangular ligament, while anteriorly it is continuous with the dartos coat of the scrotum and fascia of the penis, and, continuing up in front of the spermatic cord, becomes continuous with the deep layer of the superficial fascia of the abdomen (Scarpa's fascia). Thus the structures contained in the urogenital triangle are contained in a space which is closed, except in front, by Colles's fascia superficially, and the triangular ligament deeply. When, therefore, on rupture of the urethral bulb which lies in this space, extravasation of urine occurs, the urine is forced to come forward, distending the scrotum and penis, and finding its way up in front of the cord to the front of the abdomen.

As a result of gonorrhœal infection of the urethra, *peri-urethral abscess* is apt to occur in this region, and may burrow ultimately to the surface and discharge. If it also communicates with the urethra, a *perineal urinary fistula* would result. Extravasation may also cause such a fistula. Situated in the middle line of the triangle is the bulb of the corpus spongiosum, enclosing the urethra, and surrounded by the accelerator urinæ muscle, while lying along the rami of the pubes and ischium on either side are the crura of the corpora cavernosa, which converge to meet the corpus spongiosum under the pubic arch, and form the body of the penis. Thus, the urogenital triangle is divided into two smaller triangles, the corpus spongiosum forming the inner side common to both, the crura forming the outer sides of the two triangles, while the transversus perinæi muscles converging to the central point of the perineum from the rami of the ischium form the third sides. The space is traversed from behind forwards by the *superficial perineal vessels and nerves* (from the internal pudic arterial and venous trunks), which enter it by piercing the base of the triangular ligament. The *transverse perineal arteries* (internal pudic) also pierce the triangular ligament, and accompany the muscles of that name, while the *long pudendal nerve* (small sciatic) enters the space through Colles's fascia.

The CENTRAL POINT OF THE PERINEUM lies about a finger-breadth in front of the anus, and at it the antero-posterior accelerator urinæ and sphincter ani, and the lateral transversus perinæi muscles meet. Further, it marks the centre of the base of the triangular ligament, and it is used as a landmark in certain operations, the incisions not being carried beyond it in order to avoid injury to the bulb, which lies just in front of it.

The floor of the triangle is formed by the TRIANGULAR LIGAMENT, which is composed of two layers, enclosing certain structures, the anterior layer being equivalent to the deep perineal fascia, while the deep or posterior layer is derived from the obturator layer of pelvic fascia. Attached laterally to the pubic arch, the layers of the triangular ligament join one another at the base of the triangle, which is about $1\frac{1}{2}$ inches deep. The anterior layer presents a small opening at the apex, under the pubic arch, through

which the dorsal vessels of the penis pass. Between the layers of the triangular ligament is the membranous urethra, surrounded by the compressor urethræ. This lies about 1 inch below the symphysis, and $\frac{3}{4}$ inch above the central point. When ruptured, as by a blow in the perineum, *extravasation* takes place between the layers of the triangular ligament, by which it is limited at first. The anterior layer of the ligament is pierced by the artery to the bulb, close to the urethra, and by the artery to the corpus cavernosum near the subpubic angle. In addition to the membranous urethra and compressor muscle, there are, between the layers of the triangular ligament, the termination of the internal pudic artery, dividing into dorsal artery of penis and artery of the corpus cavernosum, artery to the bulb, Cowper's gland, and the dorsal vein and nerve of the penis. Lying on the deep surface of the deep layer of the triangular ligament is the prostate gland, surrounded by its capsule, derived from rectovesical layer of pelvic fascia, prostatic plexus, etc. In cutting down on the prostate through the perineum, seven layers of alternate fascia and muscle are met with: (1) Superficial fascia; (2) superficial perineal muscles; (3) anterior layer of triangular ligament; (4) compressor urethræ muscle; (5) posterior layer of triangular ligament; (6) levator ani muscle; (7) prostatic capsule.

Perineal lithotomy—to remove a stone from the bladder, which here lies at a depth of 3 inches—is an operation seldom performed. It may be either lateral or median. In the *lateral operation* an incision $2\frac{1}{2}$ inches long is made, commencing just to the left and behind the central point of the perineum, and carried down and outwards into the ischio-rectal fossa, to end at the junction of the outer and middle one-third of a line joining the tuber ischii and the anus. In addition to skin and superficial fascia, the transversus perinei muscle, artery, and nerve, lower edge of external layer of triangular ligament, and external hæmorrhoidal vessel and nerves are cut. The scalpel is now entered through the exposed membranous urethra, and its point engaged in the groove of the staff, while the edge is directed toward the left tuber ischii, and in this position it is pushed along the groove into the bladder. In this incision the membranous and prostatic portions of the urethra, posterior layer of the triangular liga-

ment, compressor urethræ, and anterior fibres of the levator ani, and left lateral lobe of the prostate are divided. In the first incision of this operation the bulb may be wounded if the incision be begun too far forward, or the staff is not drawn sufficiently up under the pubes. The rectum may be cut if the incision is carried too far back or the viscus is distended, and the pudic vessels might be damaged if the incision were carried right to the ramus. In the second incision the prostatic capsule and plexus of veins are necessarily cut; but if the incision be carried too far forward, the visceral layer of the pelvic fascia might be cut, and the pelvic cavity opened; this is more likely to occur in children, where the prostate is rudimentary.

In *median lithotomy* (Cock's operation) the knife is entered in the middle line just in front of the anus, and is directed to enter the median groove on the staff at the apex of the prostate, the membranous urethra being incised in withdrawing the knife, a wound $1\frac{1}{4}$ inches long being made in the median raphe. The finger is now introduced, the parts dilated, and the stone removed. Here the parts divided are skin and superficial fascia, sphincter ani, central point of perineum, base of the triangular ligament, the whole length of the membranous urethra, and compressor urethræ. As this operation is made through the avascular raphe, there is little bleeding, and the pelvic fascia is less likely to be opened by the dilating process; on the other hand, the space obtained is small, the bulb is apt to be wounded (but median wounds of the bulb do not bleed much), and in children the process of separation would be very apt to tear the bladder from the urethra. Similar operations may be performed for removal of the prostate by the perineal route, or for making a simple incision into the bladder to afford free drainage in critical cases of enlarged prostate. The *pudic nerve* supplies sensation to the skin of the perineum and also of the penis, scrotum, and anus, while it also supplies the mucous membrane of the urethra and muscles of the penis. Thus, painful affections of the perineum and anus may cause *priapism*. The *perineal branch of the small sciatic* also supplies sensation to the perineum, and thus in *perineal abscess* pain is frequently referred to the gluteal region and posterior part of the thigh.

In the *female* the urogenital triangle is perforated by the vaginal orifice, the vulva forming practically a cleft

between two halves of a rudimentary scrotum. The deep layer of superficial fascia runs through the labia majora to ascend on to the abdomen. *Rupture* of the perineum occurs frequently in connection with labour, and may extend into the rectum. In such cases the pelvic organs are deprived of considerable support, and may project through the vulva, forming a vesicocele or rectocele.

The ANAL TRIANGLE, occupying the posterior portion of the perineum, contains the rectum and ischio-rectal fossæ. The rectum and anus are situated centrally, being bounded on either side by the ischio-rectal fossæ. Each ISCHIO-RECTAL FOSSA is wedge-shaped, the base being directed downwards, while the apex, $2\frac{1}{2}$ inches from the surface, corresponds to the position of the white line, where the anal and obturator fasciæ join, and is directed upwards and backwards. The triangle is bounded by the levator ani, covered on its inferior surface by the anal fascia, and the external sphincter internally, while it is bounded externally by the obturator externus muscle, covered on its inner surface by the obturator fascia. Anteriorly the fossa is limited by the transversus perinei muscle and base of the triangular ligament, and posteriorly by the margin of the gluteus maximus muscle; but two small extensions occur: an anterior (pubic recess), extending beneath the transversus perinei between the obturator internus and levator ani; and a posterior between the gluteus maximus and great sacro-sciatic ligament and the coccyx to the level of the ischial spine and coccygeus muscle. The fossa is occupied by a quantity of fatty connective tissue continuous with the surrounding subcutaneous fatty tissue, and the two fossæ communicate freely behind the anus with one another. This tissue by yielding permits of fæcal dilatation of the rectum, while in labour the fossæ become almost obliterated by distension of the vagina. As the edge of the gluteus maximus overlaps this pad, it may indirectly assist the levator ani. The *inferior hæmorrhoidal* vessels and nerves pierce the obturator fascia near the posterior part of the space, and pass downwards and inwards toward the rectum. The perineal branch of the *fourth sacral* becomes superficial near the tip of the coccyx, and small branches of the small *sciatic* nerve and sciatic artery curve round the lower border of the gluteus maximus, while the superficial *perineal* vessels and

nerves enter the anterior portion of the space, and immediately leave it again by piercing the triangular ligament.

ALCOCK'S CANAL, situated in the outer wall of the ischio-rectal fossa, is formed by a splitting of the obturator fascia, and contains from above downwards the dorsal nerve of the penis, third part of internal pudic artery with venæ comites, and perineal division of pudic nerve.

The **RECTUM** commences opposite the body of the third sacral vertebra, and, descending in front of the sacrum and coccyx, runs forwards for $1\frac{1}{2}$ inches upon the pelvic floor, formed by the two levatores ani, and then, bending downwards and backwards, it pierces the pelvic floor to terminate at the anus. About 6 inches in length, it has no mesentery and only a partial peritoneal covering, while instead of presenting three muscular bands and general sacculation as the colon does, it presents two wide longitudinal muscular *bands*, the one anterior, the other posterior, slight sacculation occurring laterally between these bands. In addition to the course described above, the rectum presents *lateral curves*, which are maintained by the muscular bands. These curves are generally three in number, an upper and lower with the concavity to the left, while the intermediate one, which is likewise the most prominent, has the concavity to the right. The concavities are marked by furrows externally, and by marked crescentic projections—the *rectal valves*, or valves of Houston—internally. As those valves occasionally obstruct the passage of long instruments, it is well to remember that the main one projecting from the right side is situated about 3 inches above the anus, while the other two, less marked and projecting from the left side, are situated respectively $1\frac{1}{2}$ inches above and below the middle one. The *curving* increases the length of the rectum, and also delays the passage of and supports the bowel contents, and the rectal valves also play an important part in so doing. These valves become most prominent when the bowel is distended, and are excellently seen when, the patient lying inverted, a speculum is introduced through the anus, and the rectum distends with air. When *distended* the rectum occupies the greater portion of the posterior division of the pelvis, obliterating the lateral or pararectal fossæ. About 1 inch in diameter at its upper extremity, it dilates in its lower two-thirds to form the *rectal*

ampulla. At the point of the last sharp curve backwards, the anterior rectal wall sometimes projects forwards and even downwards, forming a small *anterior pouch*. This is most apt to occur in multiparæ.

The relationship of the *peritoneum* to the rectum is of importance in excision of the rectum and similar operations. At its commencement the rectum is covered both in front and laterally by peritoneum, then the lateral portions become uncovered, and, finally, at an average distance of 3 inches from the anus, the peritoneum is reflected from the front of the bowel on to the posterior surface of the bladder and the vesiculi seminales, forming the *recto-vesical peritoneal pouch*. Thus this pouch is generally opened into, when, in excising the rectum, more than the last 3 inches are exposed, but the exact position of the pouch varies between 1 inch and $4\frac{1}{2}$ inches above the anus, and is partly influenced probably by the amount of distension of bladder and rectum. In the female the peritoneum is reflected at the same level on to the upper part of the vagina, cervix, and broad ligaments, forming the fundus of the *pouch of Douglas* (recto-vaginal pouch). The lateral reflections are higher up, about 5 inches from the anus, and form *pararectal fossæ*, when the rectum is empty. These fossæ are generally occupied by small intestine, but, when the rectum is distended, it generally occupies and obliterates these spaces. Below the level of the recto-vesical pouch, the rectum is surrounded by the *rectal fascia*, which is derived from the visceral layer of the pelvic fascia. Here, also, but for the interposition of this fascia, bladder and rectum are in contact with one another over a triangular area about 1 inch long, whose base corresponds to the line of reflection of the peritoneum, and whose apex is situated at the base of the prostate, while the lateral limits are formed by the vesiculi seminales.

Through this triangular area the bladder has been tapped *per rectum*, and the *examining finger, introduced per rectum*, can sometimes detect the presence of a posterior prostatic pouch of the bladder in cases of enlarged prostate, and even perhaps a stone lying in it. The vesiculi seminales can also be examined *per rectum*, and various changes, as, for example, their hardness in certain stages of tubercular disease, noted. Sometimes they may be pressed on by straining at stool, and

thus emptied, causing a so-called 'spermatorrhœa.' In front of the vesiculi seminales, close to the bladder wall, are the ureters, which are not easily felt. The vasa deferentia, however, lying first on the inner borders of the vesiculi seminales, and then lying together for a short distance above the base of the prostate, may be made out. Nearer the anus, and also in front, the prostate gland can be felt, and, when enlarged, it projects markedly into the rectum, giving the patient the feeling that he cannot empty the bowel, and sometimes even leading to partial obstruction. It, too, when enlarged, may be pressed on during defæcation, causing pain if inflamed, and sometimes also producing a so-called 'spermatorrhœa' from the discharge of its secretion by the penis. In the female this portion of the rectum is in relation to the vagina, and advantage may be taken of this in rectal examination to evaginate the lower rectal wall through the anus by the finger introduced into the vagina. At the upper part, the os and cervix uteri may be felt, sometimes projecting markedly into the rectum, and suggesting the presence of tumour. Laterally also, particularly in the child, the lateral pelvic wall over the acetabulum may be explored, and disease of the acetabulum, with extension of tubercular pus to the inner side of the pelvis, detected. Through the posterior rectal wall the coccyx may be felt, and possibly part of the sacrum, and this wall is also in relation to the coccygei and levatores ani muscles, sacro-sciatic ligaments and hæmorrhoidal vessels and lymphatics. Laterally, below the peritoneal reflection, the rectum is in relation to the vasa deferentia and upper extremity of the vesiculi seminales, and receives the middle hæmorrhoidal vessels, enclosed in a layer of connective tissue, derived from the pelvic wall, and called the *lateral ligament* of the rectum. The rectum may also be examined for tumours such as *polypi*, which are frequently situated not very far from the anal orifice, or for *carcinoma*, which is frequently only to be felt by a long finger. An excellent view of the interior of the rectum may be obtained by inverting the patient and stretching the sphincter, the rectum then distending with air.

The last inch or so of the rectum directed downwards and backwards is sometimes spoken of as the *anal canal*. It is surrounded by the internal and external sphincters, which,

assisted by the levatores ani, compress it laterally, thus presenting an antero-posterior slit. It is related in front to the mass of tissue known as the *perineal body*, where several perineal muscles meet; behind to the tissue between the rectum and the coccyx, called the *ano-coccygeal body*; while laterally it is in relation to the fat of the ischio-rectal fossa.

The mucous membrane of this part, becoming continuous with the anal skin at '*Hilton's white line*,' presents a series of slight vertical ridges—*columns of Morgagni*—which become continuous above with the mucous membrane of the rectum proper at the ano-rectal line. At the anal extremity of each of the intervening depressions is a small *anal valve*, opening into a small *rectal sinus* in the submucous tissue. These small valves are sometimes torn by scybalous masses, and are said to give rise to fissure of the anus. The examining finger notes the smooth character of this portion of the mucous membrane and the underlying firm smooth surfaces of the resisting sphincters. Where a *stricture* exists, this is frequently detected only a short distance in, presenting a hard, possibly sharp, resisting ring.

The **anus** is capable of very considerable distension if done gradually, and a small hand has even been introduced for examination of various organs. As, however, the hand rapidly cramps from pressure, it is of little service. The rectum is supplied by the middle sacral and superior, middle, and inferior hæmorrhoidal *arteries*, of which the first two are single, and the others dual vessels. The middle sacral arises from the aorta, and its supply is insignificant. The *superior hæmorrhoidal*, the principal blood-supply, is the continuation of the inferior mesenteric. It supplies numerous branches to the rectum, which may be traced almost to the anus, piercing the muscular coat 3 inches above the anus, beyond which point it supplies chiefly mucous membrane. The *middle hæmorrhoidal* arises from the internal iliac, reaches the rectum about 3 inches above the anus, and anastomoses with both the superior and inferior hæmorrhoidal vessels. The *inferior hæmorrhoidal* rises from the internal pudic of the internal iliac, and supplies chiefly the anal portion. The *veins* of the rectum are arranged in two main plexuses—the *internal hæmorrhoidal*, situated in the submucous coat; and

the *external hæmorrhoidal*, situated in the external coat. The veins constituting the internal hæmorrhoidal plexus commence in a number of small anal veins, radially placed round the anus, and situated in the submucous tissue. They join to form larger and tortuous vessels, which, ascending in the columns of Morgagni, anastomose to form the plexus, and frequently present small dilatations, which may represent starting-points for hæmorrhoids. Ultimately they pierce the muscular coat about the middle of the rectum, and join the superior hæmorrhoidal vein.

Hæmorrhoids consist of a varicosity of the veins of the internal hæmorrhoidal plexus, and are classified as internal when they affect those in the region of the columns of Morgagni and are covered by mucous membrane, and as external when situated beneath the skin at the anal orifice. Internal hæmorrhoids are not infrequently associated with prolapse of the mucous membrane, so that they may even appear externally, and are sometimes constricted by the sphincter, cure taking place by sloughing. Several anatomical causes may be found for hæmorrhoids: (a) upright posture, with veins running vertically in a lax mucous membrane (scybalous masses may press on these vertical veins); (b) the superior hæmorrhoidal, a long vein without valves, communicates with the portal system, and is liable to congestion; it is also liable to be pressed on by loaded rectum. The various *veins* which pass out through the rectal wall unite to form the external hæmorrhoidal plexus, and from this plexus the superior hæmorrhoidals go to join the inferior mesenteric, which joins the portal vein; the middle hæmorrhoidal joins the internal iliac, and the inferior hæmorrhoidal joins the internal pudic of the internal iliac. Thus portal and systemic systems *communicate* on the rectum.

The *lymphatics* pass chiefly to some rectal glands lying in the outer coat of the bowel in the course of the superior hæmorrhoidal vein, and thence to the sacral glands in front of the sacrum. Some of these from the anal region join the cutaneous lymphatics, and so reach the superficial inguinal glands, and a few are said to pass to the internal iliac glands lying on the lateral pelvic wall. The rectum is supplied by the second, third, and fourth sacral *nerves*, together with sympathetic fibres from the mesenteric and hypogastric

plexuses. The anal canal and external sphincter are supplied by the inferior hæmorrhoidal branch of the internal pudic.

The sacral nerves convey motor impulses to the longitudinal muscle fibres and inhibiting impulses to the circular, while the sympathetic does the reverse. While the anal portion of the bowel is very sensitive, the portion above is very insensitive, so that considerable damage may be done without a patient being aware of the fact. In rectal affections pain is sometimes referred to the perineum, penis, and even down the thigh, owing to the pudic and small sciatic nerves arising from the same section of the cord. The fourth sacral nerve supplies both rectum and neck of bladder, and thus *retention of urine* frequently follows operations on the rectum, particularly, it is said, when the sphincter is stretched antero-posteriorly instead of laterally. The *reflex defæcation centre* is in the lumbar region, and may act even when separated from the brain. Destruction of the centre causes incontinence of fæces. Where the pelvic colon, or upper rectum, is greatly distended with fæcal matter, or is affected with carcinoma, the *obturator nerve* is sometimes pressed on, causing the patient to complain of pain in the knee.

In the child the rectum is relatively larger in its upper part, is nearly straight, almost vertical, and is partly abdominal rather than pelvic. At birth, also, the peritoneal covering descends to the base of the prostate, and, as the other connections are loose, *prolapse* is frequently met with. The prolapse in such cases is generally partial, consisting only of mucous membrane. Complete prolapse of the whole bowel wall is not very common, and is generally associated with weakness of the pelvic floor, and severe and repeated straining from some cause such as urethral stricture. In such cases it is well to remember that the herniated portion consists of a double layer of bowel, and that a peritoneal pouch frequently exists between the layers in front, into which a portion of small intestine may descend, causing a sudden increase in the size of the swelling.

In the fœtus the urinary and rectal systems terminate together in the earlier stages in a common space, or *cloaca*. Normally the anterior or urogenital section becomes separated from the posterior or rectal portion. The posterior extremity of the bowel does not open on the surface of the body, but a

depression from the surface, called the *proctodæum*, grows down to meet it, and forms the anal portion of the bowel. At first the protodæum is blind, as is likewise the lower end of the bowel, but finally by absorption of the anal membrane the lumen of the canal is completed. Various *deformities* are seen affecting the lower end of the rectum. The canal may be patent but narrowed, forming a congenital *stricture*. The most common condition is that of *imperforate anus*, where, owing to persistence of the cloacal membrane, a septum exists at the ano-rectal junction. If the proctodæum forms, but the rectum ends unduly high up, the condition is known as *absent rectum*, while the anus may or may not be present. The rectum may open into the bladder, or a cloaca may persist. Where only a septum exists, it may be perforated by the cautery. Where, on the other hand, the lower rectum is absent, an inguinal colotomy is necessary (Littre's operation).

Two forms of rectal stricture have already been mentioned, the one congenital, and the other fibrous, and generally due to syphilis. CARCINOMA, however, constitutes the most important form of rectal stricture, and, indeed, the rectum is the most frequent site of bowel carcinoma. When situated *close to the anus*, it may be removed by making a circular incision round the anus, and then separating a sleeve of bowel, and pulling it down from above. As a rule, however, the tumour is situated some 3 or 4 inches above the anus, in a position where its lower extremity may just be touched by the examining finger. In such cases, after a preliminary colotomy, the affected portion of bowel is removed by *Kraske's operation*, or one of its modifications, in which a median incision is made over the lower portion of the sacrum and coccyx, and extending to about 1 inch from the anus. The tissues on the left side, including the origin of the gluteus maximus, are reflected, as are likewise the attachments of the left sacro-sciatic ligaments, coccygeus and levator ani muscles, to the sacrum and coccyx. The anterior surface of the sacrum is next cleared by the periosteal elevator, the median and lateral sacral arteries and plexus of veins being shelled forward, and then the last two pieces of the sacrum, or at least their left halves, and the whole coccyx, are removed, and the bowel exposed with the hæmorrhoidal vessels. It is not advisable to cut away more than the last two pieces of the

sacrum, as then the third sacral nerve would be injured (Bardenheuer). The sphincters are supplied by the third and fourth sacral nerves, and the levator ani by the third chiefly, while the bladder is supplied by the second, third, and fourth. Thus, if the third and fourth nerves were destroyed, the sphincter would be paralyzed, and the control of the bladder lost, producing *incontinence*. If it is necessary to bring down more bowel from above, this may be done by opening into the peritoneum, which so far has been intact, and pulling down. The diseased portion is removed, cutting wide of the disease both above and below, and the healthy ends united. In this operation the anus with the sphincters is preserved intact. The glands lying in front of the sacrum, and in the iliac regions, may be removed if affected, and the portion of sacrum removed may be replaced after the operation. Where the upper portion of the rectum is affected, it may be reached by a combination of peritoneal and sacral routes.

Fissure and fistula frequently affect the anus. *Fissure* is a narrow crack in the anal skin, extending, perhaps, as far as one of the anal valves, between the columns of Morgagni. It is extremely painful owing to the exposure of one or more nerve terminations, and the constant movements of the rectum with respiration, and of the sphincter. In the more severe cases the sphincter may be overstretched so as temporarily to paralyze it, and the ulcer excised.

Fistula in ano may be produced in much the same manner as the fissure, the mucous membrane about the same site ($\frac{1}{2}$ inch above the anus) being damaged by scybalous masses, etc. Organisms thus gain access to the lax submucous layer, and in it they proliferate, and give rise to pus which passes down in this layer and, therefore, on the bowel side of the sphincter, until it reaches the subcutaneous tissues, which, being more resistant, limit the progress of the pus, which at this point forms an abscess. This abscess may immediately point on the surface, and burst, producing the fistula, or, as not infrequently happens, it first bursts into the ischio-rectal fossa, which is filled with pus prior to the external bursting, forming an *ischio-rectal abscess*. Owing to the length and tortuosity of the track, the condition does not heal, but a persistent discharge is kept up, and frequently

a small mass of granulation tissue, called a 'sentinel pile,' forms at the external orifice. Treatment consists in overstretching the sphincter, and then carefully passing a director along this superficial and tortuous channel, until the inner opening is reached, and slitting it open, removing diseased track, and packing so as to produce healing by granulations from the bottom. Care must be taken in introducing the director not to introduce it into the ischio-rectal fossa, or to force it along an imaginary fistula. If such be done, the fistula will not be laid open, and the sphincter may be cut.

The lower colon and the rectum possess very considerable *absorptive power*, which is utilized in feeding by rectal injections of predigested foods. In cases of shock from loss of blood many ounces of saline solution will generally be rapidly absorbed, and it should be remembered when administering alkaloids by rectum that their action so given is only less powerful than when given hypodermically.

SECTION IV

LOWER EXTREMITY

THE HIP.—This region may be subdivided into gluteal and adductor portions, and region of Scarpa's triangle.

Gluteal Region—**SURFACE ANATOMY.**—The gluteal region is bounded above by the iliac crest, and below by the gluteal fold; internally by the intergluteal sulcus, and externally by a line from the anterior superior spine to the tip of the great trochanter. The anterior superior spine is generally visible as a landmark, and can be easily palpated. The crest of the ilium may be obvious, or may be overhung by flesh, and terminates posteriorly in the posterior superior spine, which is frequently marked by a dimple, and is on a level with the second sacral spine, and just behind the centre of the sacroiliac articulation. The *gluteal fold* does not correspond to the lower border of the gluteus maximus muscle, but lies considerably above it. It extends horizontally outwards, and is most distinct when the thigh is extended, becoming obliterated when it is flexed to a right angle. Thus, in hip disease, where the limb is flexed, loss of the gluteal fold is an early sign, and, later, this symptom becomes more marked from atrophy of the muscles.

The **GREAT TROCHANTER** is an obvious landmark, although in a fat person its position may be indicated by a depression. It is covered by the fascial insertion of the gluteus maximus, and the tendon of the gluteus medius passes over its upper border. It becomes very prominent when the gluteal muscles atrophy, and on abduction of the thigh these muscles are relaxed, and thus the tip of the trochanter is more readily palpated. Normally it should occupy a position midway between the anterior superior spine and the tuber ischii, and

should just touch a line drawn between these two points (NELATON'S LINE) when the thigh is very slightly flexed. As it is frequently of importance in suspected hip affections to test whether the head of the femur is in its position by carefully noting that of the great trochanter, another method has been devised by Bryant (BRYANT'S TRIANGLE). With the patient lying on his back, a vertical line is dropped from the anterior superior spine, and a second line drawn from the same point to the tip of the great trochanter. A third line, at right angles to the vertical line, is now dropped from the trochanteric tip, and this third line, which completes the triangle, is compared in length with its neighbour of the other side. A line drawn from the posterior superior spine to the tip of the trochanter indicates the interspace between the gluteus medius and the pyriformis, and the point of emergence of the *gluteal artery* from the pelvis is at the junction of its inner and middle one-third. A line drawn from the posterior superior spine to a point midway between the tuber ischii and great trochanter crosses the gluteal artery at the junction of its upper and middle one-third, while the junction of its middle and lower one-third indicates the point of emergence of the *great sciatic nerve* from the sacro-sciatic foramen. A line drawn from the posterior superior spine to the outer part of the tuber ischii crosses the posterior inferior spine 2 inches down, and the ischial spine 4 inches down. The pudic artery crosses over the ischial spine in passing from the great to the small sacro-sciatic foramen, and the sciatic artery reaches the gluteal region at the junction of the middle and lower one-third of this line.

The TROCHANTERIC FOSSA is the depression behind the trochanter into which the fingers can be pushed deeply normally, but which is frequently obliterated in extracapsular fracture of the neck. The *tuber ischii* is covered by the gluteus maximus when the limb is extended, but is exposed when the limb is flexed to a right angle, and is then easily palpable.

The SKIN over the gluteal region is thick, and contains numerous sebaceous glands, and is a frequent seat of boils. The SUBCUTANEOUS TISSUE is very fat, and is directly continuous with the fatty tissue which occupies the ischio-rectal fossa, and with a layer lying under the gluteus maximus.

This layer under the gluteus maximus communicates through the sacro-sciatic foramina with the intrapelvic connective tissue, and that of the ischio-rectal fossa and that descending the back of the thigh along the sciatic nerve. The laxity of this tissue favours the formation of large collections of pus or blood, and *lipomata* are frequently found in this region. The FASCIA LATA in this region is strong and tense. Attached above to the outer lip of the iliac crest and to the sacrum and coccyx behind, it splits in front to enclose the tensor fasciæ femoris; and, again, lying on the gluteus medius, splits to enclose the gluteus maximus. Effusions of blood, or *abscesses*, occurring beneath this layer, are much circumscribed, and frequently give rise to much pain. They may travel down the thigh, or even farther, before reaching the surface, or may enter the pelvis through the sciatic foramina; while, conversely, a pelvic abscess may find its way below the gluteus maximus, as may also pus from the hip-joint by perforation of the posterior aspect of the capsule. A thickened band of the fascia—the *ilio-tibial band*—into which the tensor fasciæ femoris is inserted, runs from the iliac crest to the outer tuberosity of the tibia and head of the fibula. A tense portion of this band runs between the iliac crest and the great trochanter, which becomes relaxed in fractures of the neck of the femur.

The GLUTEUS MAXIMUS is the most massive layer of muscle in the body, and is inserted below into the fascia lata overlying the great trochanter, and into the back of the femur. Its lower margin is oblique, and lies well below the gluteal fold. It has been ruptured by muscular violence. The gluteus maximus is separated from the outer surface of the great trochanter, the tuber ischii, and the outer tendinous surface of the vastus externus by BURSÆ. The bursa over the great trochanter is occasionally affected by chronic inflammatory processes, causing the limb to be kept flexed and adducted, and when it bursts it generally gives rise to a sinus difficult to heal on account of the constant movement of the gluteus maximus, while, on the other hand, the disease may spread to the bone.

The GLUTEI medius and minimus are also provided with bursæ over the great trochanter, into which, along with the PYRIFORMIS, OBTURATOR internus and GEMELLI, they are in-

served. The bursa over the ischial tuberosity is frequently enlarged, giving rise to the condition known as *Weaver's or Lighterman's bottom*. It may cause pressure on the perineal branch of the *small sciatic nerve*, giving rise to unilateral neuralgia of the penis and scrotum. Pressure on the same nerve as it crosses in front of the tuber ischii from the use of a hard seat may give rise to similar neuralgia, temporary numbness, or anæsthesia. Small branches of the gluteal and sciatic arteries and nerves pierce the gluteus maximus, while under it lie two groups of vessels and nerves—those which emerge above and below the pyriformis muscle. Those which emerge *above* are the gluteal vessels (posterior division of the internal iliac) and superior gluteal nerve from the sacral plexus, which latter supplies the gluteus medius and minimus, and tensor fasciæ femoris. The artery anastomoses with the deep circumflex iliac of the external iliac, the external circumflex of the profunda femoris, and the sciatic artery. It is generally about the size of the ulnar, but may be larger, and has caused death from hæmorrhage when *wounded*. As a rule, however, the trunk escapes, as it is situated chiefly within the pelvis. The trunk is occasionally the seat of *aneurism*, which, pressing on the lumbo-sacral cord, gives rise to nerve symptoms. *Below the pyriformis* are the sciatic vessels and nerves, and the nerve to the quadratus femoris. In addition, the internal pudic vessels and nerve, and nerve to the obturator internus, emerge from the great sciatic foramen, turn round the ischial spine, and re-enter the pelvis through the lesser sciatic foramen. The *sciatic artery* from the anterior division of the internal iliac supplies the surrounding muscles, anastomoses with the other vessels, and supplies a branch to the great sciatic nerve. The sciatic, internal and external circumflex, and the first perforating vessels form the *crucial anastomosis* about the level of the quadratus lumborum. Very rarely the femoral artery extends down the back of the thigh instead of the front.

The GREAT SCIATIC NERVE, the largest in the body, is a continuation of the sacral plexus (fourth lumbar to third sacral), and lies midway between the tuber ischii and the great trochanter. It is a frequent seat of neuralgia, called here *sciatica*, which may be due to pressure in the pelvis from tumours, engorged pelvic veins, aneurism of branches of the internal

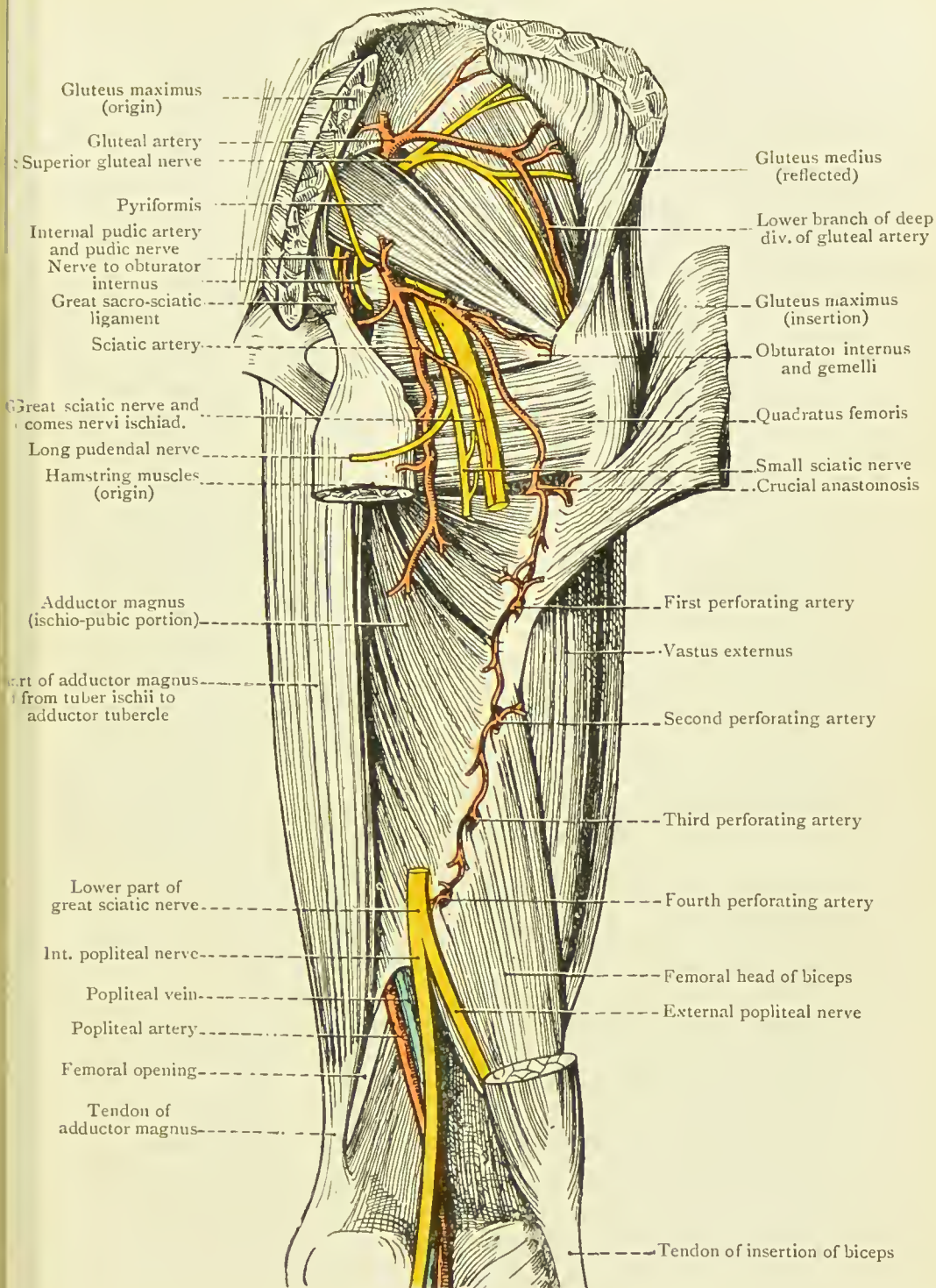


FIG. 35.—THE GLUTEAL REGION AND BACK OF THE THIGH. DEEP DISSECTION. (From Buchanan's "Anatomy.")

iliac, sciatic hernia, fæcal masses in the rectum, etc., while below the gluteus maximus it is comparatively superficial, and may be exposed to cold or injury. It may be *stretched* by flexing the extended limb on the abdomen, or it may be cut down on, picked up at the lower margin of the gluteus maximus, and stretched by hand, the pelvis being raised by it from the table. A weight of 183 pounds is said to break the nerve.

The gluteal region is richly supplied with NERVES, and has well-developed tactile sensation. The nerve-supply is derived from the twelfth dorsal, first lumbar, second and third sacral segments (the latter segments also supplying the sexual organs); through the lateral cutaneous of the twelfth dorsal, twigs from the posterior branches of the lumbar and external cutaneous nerves, iliac branch of the ilio-hypogastric, and branches of the sacral nerves and of the small sciatic. The following muscles lie under the gluteus maximus: the gluteus medius, pyriformis, the obturator internus, with the gemelli on either side; quadratus femoris; hamstrings arising from the tuber ischii; adductor magnus; and vastus externus.

The *great sacro-sciatic ligament* stretches downwards from the posterior inferior iliac spine, sacrum, and coccyx to the tuber ischii, while the *lesser sciatic ligament* stretches downwards and outwards from the side of the sacrum to the ischial spine. The latter converts the great sciatic notch into the *great sacro-sciatic foramen* (which is bounded on its inner side by the great ligament), while the great ligament, assisted by the lesser, converts the lesser notch into the *lesser foramen*.

Wounds of the gluteal region, especially those entering behind the great trochanter, may readily penetrate the pelvis through the sciatic notch, and damage the bladder, ureter, or rectum, giving rise to fistulæ, while the peritoneal cavity may be opened and peritonitis result. The gluteal and sciatic arteries have been *ligatured* from the gluteal region, and might be involved in wounds, while the great sciatic nerve might also be involved.

A *sciatic hernia* occasionally makes its way through the great sciatic foramen, and appears above the pyriformis muscle; rarely through the lesser foramen, appearing below the pyriformis. Such herniæ are more common in women, are generally small, and entirely under the gluteus maximus. When large, however, they may appear under its lower border.

The neck of the sac is usually situated at the fossa ovarica in the angle between the internal iliac artery and its obturator branch.

Treatment should consist in cutting down and out along the ilio-trochanteric line parallel to the fibres of the gluteus maximus, which are separated and retracted. The sac is then carefully defined and freed from adhesions, remembering that most of the vessels and nerves run down and outwards parallel to the fibres of the pyriformis.

Scarpa's Triangle—SURFACE ANATOMY.—Scarpa's triangle is limited above by Poupart's ligament, extending from the anterior superior spine to the spine of the pubis in a slight curve, with the convexity downwards. Owing to the attachment to it of the fascia lata, it is rendered less tense when the thigh is flexed, adducted, and rotated inwards.

Holden's line, extending outwards from the angle between the scrotum and the thigh to midway between the anterior superior spine and tip of the trochanter, is said to be visible when the thigh is flexed, and to act as a guide to the capsule of the hip-joint, across the front of which it runs. The triangle is bounded externally by the sartorius, and internally by the adductor longus. The sartorius may be rendered prominent by raising the limb across the opposite knee. The tendon of the adductor longus arises just below the *spine of the pubis*, and where this landmark cannot very easily be made out in a stout person, the adductor longus tendon, which may be rendered tense by asking the patient to adduct the limb against some resistance, acts as a guide. The pulsations of the femoral artery can generally be seen near the base of the triangle, and occasionally the vein bulges slightly forwards when the patient stands and coughs, thus resembling femoral hernia. Other *conditions resembling femoral hernia* are femoral aneurism, tumours (particularly lipomas, which are sometimes partially reducible through apertures in the fascia lata), psoas abscess, and enlargement of the glands in the groin. The suppurative glandular enlargement, which occurs in soft sore, etc., is spoken of as a *bubo*. The lymphatic glands can frequently be felt.

The position of the *femoral ring* is indicated by taking a point 1 inch from the pubic spine on a line drawn from the spine to the tip of the great trochanter, or by taking a point

$\frac{1}{2}$ inch inside the femoral artery, and close to Poupart's ligament. The position of the *saphenous opening* is sometimes marked by a slight depression on the surface, or it may be indicated by taking a point $1\frac{1}{2}$ inches below, and external to, the pubic spine. In thin persons the *long saphenous vein* can frequently be made out passing to the opening. A *supernumerary mamma* is occasionally found in the groin, and the *testicle*, instead of descending into the scrotum, may descend through the crural canal into Scarpa's triangle, or even turn up like a femoral hernia over Poupart's ligament.

The SKIN over the triangle is thin, loosely attached, and distensible, permitting large herniæ, or tumours, to occupy the space. *Incisions* made parallel to Poupart's ligament come together easily, whereas vertical ones tend to gape. *Burns* frequently produce contraction deformities, resulting in flexion of the hip. The SUPERFICIAL FASCIA contains a considerable amount of fat, and near Poupart's ligament is divisible into two layers. *Lipomas* frequently occur in this region, and may travel, under gravity, some distance down the thigh. Superficial *abscesses* arise from infection of the superficial lymphatic glands from some abrasion of the limb, genitals, anus, or buttock, and generally do not travel under this fascia, but readily point through it close under Poupart's ligament. *Branches of the femoral artery* in this region are the superficial circumflex iliac, epigastric and external pudic, the accompanying *veins* discharging into the long saphenous.

The LONG SAPHENOUS VEIN ascends from the dorsum of the foot, in front of the inner malleolus, along the inside of the leg to the posterior aspect of the internal condyle of the femur, where it is in relation to the long saphenous nerve of the anterior crural. Thence it runs upwards and outwards to the saphenous opening, pierces the cribriform fascia and anterior wall of the femoral sheath, and joins the femoral vein. In its course it receives many branches, of which the chief are the outer and inner superficial femoral, which join it about the apex of Scarpa's triangle.

The LYMPHATIC GLANDS are arranged in superficial and deep sets. The former, about twelve in number, are arranged in two groups—a horizontal close to Poupart's ligament, and a vertical along the long saphenous vein. The *vertical group* receives the superficial lymphatics of the lower limb, of the

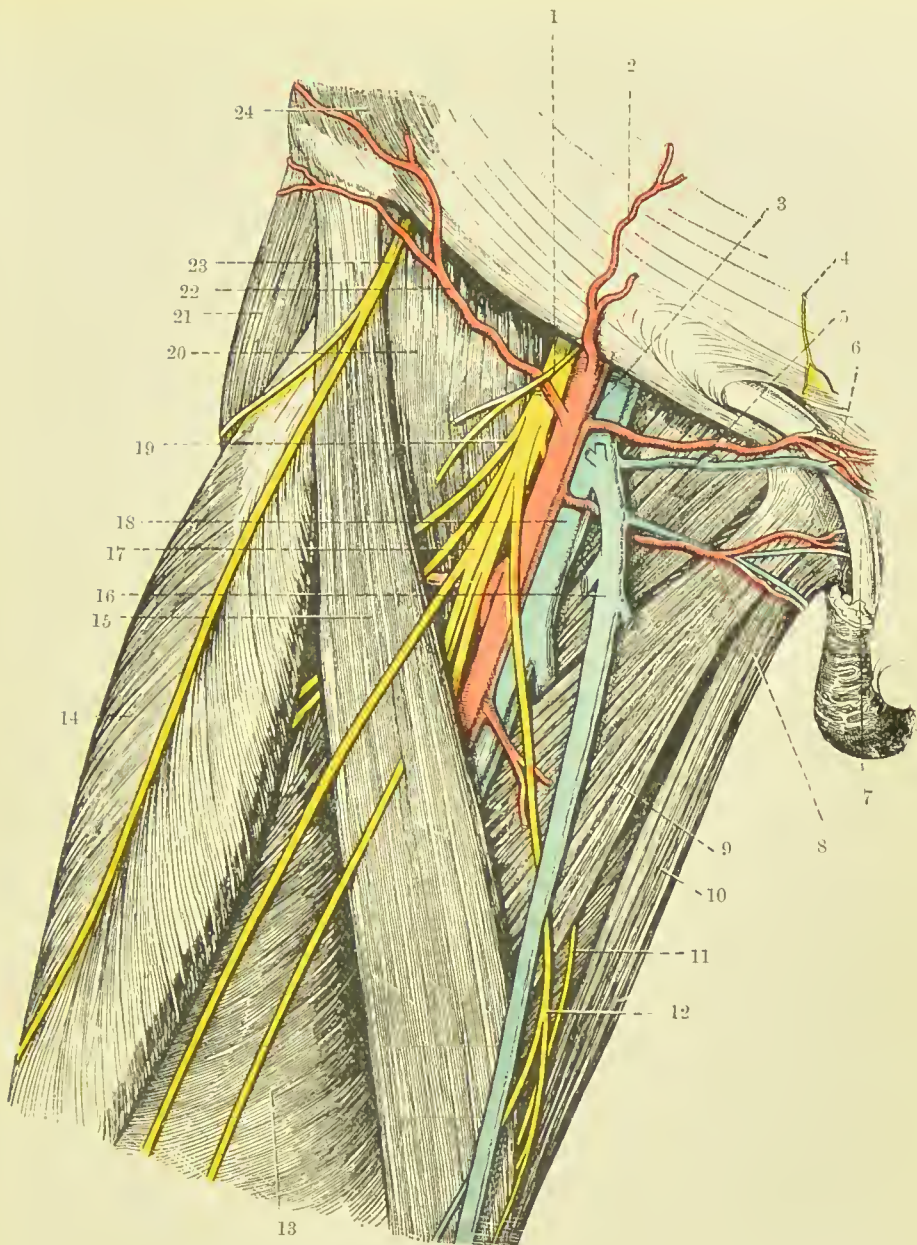


FIG. 36.—THE FRONT OF THE THIGH (SCARPA'S TRIANGLE).
(From Buchanan's "Anatomy.")

- | | |
|--|--|
| 1. Crural branch of genito-crural nerve. | 13. Vastus internus. |
| 2. Superficial epigastric artery. | 14. Rectus femoris. |
| 3. Common femoral artery. | 15. Sartorius. |
| 4. Hypogastric branch of ilio-hypogastric nerve. | 16. Left saphenous vein. |
| 5. Pectineus. | 17. Middle cutaneous nerve. |
| 6. Superior external pudic artery. | 18. Femoral vein. |
| 7. Spermatic cord. | 19. Anterior crural nerve. |
| 8. Inferior external pudic artery. | 20. Iliacus. |
| 9. Adductor longus. | 21. Tensor fasciæ femoris. |
| 10. Gracilis. | 22. Superficial circumflex iliac artery. |
| 11. Cutaneous branch of obturator nerve. | 23. External cutaneous nerve. |
| 12. Internal cutaneous nerve. | 24. Obliquus externus abdominis. |

perineum, and a few from the inner surface of the buttock and from the external genitals. The *horizontal group* receives the lymphatics of the external genitals, the outer surface of the buttock (to the outer glands), inner surface of the buttock (to inner glands), and superficial vessels of lower half of the abdomen (to middle glands). The *deep glands*, some four in number, are situated along the femoral vein near the crural canal, and receive the deep lymphatics of the lower limb, and also most of the efferent vessels from the superficial set. The *efferent vessels* from the deep set pass through the crural canal to the iliac glands, three of which lie immediately above Poupart's ligament. One of these glands is situated in the *crural canal*, lying on the septum crurale. When inflamed, it may cause much pain, and simulate strangulated femoral *hernia*. *Enlargement* of the superficial set may stretch branches of the anterior crural nerve, and give rise to much pain and muscular spasm.

The FASCIA LATA forms a tubular investment for the muscles of the thigh, being attached above to the iliac crest, Poupart's ligament, body, and ramus of the pubis, ramus of the ischium, great sacro-sciatic ligament, side of sacrum and coccyx, and posterior superior spine. The only opening in it is the SAPHENOUS OPENING, formed by splitting and crossing of its upper extremity, and covered by the thin *cribriform fascia*. Of the two portions formed by this split, the *outer iliac portion* covers the sartorius and ilio-psoas, and is inserted into the whole length of Poupart, while the *inner pubic portion* covers the adductor longus and pectineus, and is inserted deeply behind the femoral vessels to the ilio-pectineal line, fusing with the fascia iliaca as it does so. It is not of uniform strength, the thickest portion being the *ilio-tibial band* on the outer side, and it sends in septa between the muscles, of which the most important are the *internal and external intermuscular septa*, the former extending from the lesser trochanter to the adductor tubercle, and the latter lying beneath the great trochanter, and extending to the outer aspect of the knee-joint. This fascia is supposed to exert an influence in causing femoral herniæ and psoas abscesses to *turn upwards* toward the groin, while, on the other hand, it may prevent a psoas abscess from pointing about the small trochanter, and cause it to travel down even to the knee or leg.

Lying between Poupart's ligament and the innominate bone are a number of structures of surgical importance. The SPACE is roughly triangular in shape, bounded above by Poupart's ligament, externally by the anterior edge of the ilium, and internally by the horizontal ramus of the pubis, ilio-pectineal eminence, and upper margin of the acetabulum, and is subdivided into an *outer oval muscular* compartment, and an *inner compartment* roughly triangular, containing the vessels, by the ILIO-PECTINEAL LIGAMENT. This ligament is formed of a band of fascia lata, which extends from the deep surface of Poupart's ligament, just external to the artery, to the ilio-pectineal eminence.

The MUSCULAR COMPARTMENT contains the ilio-psoas muscle, the iliacus portion being the more external, and the anterior crural nerve lying in the groove between the iliac and the psoas portions. Then, internal to the ilio-psoas and in the INNER COMPARTMENT, lie the vessels in their sheath, the artery being external to the vein, while internal to the vein is the crural canal. The vessels, together with the termination of the long saphenous vein, the anterior crural nerve, crural branches of the genito-crural nerve, and the femoral lymphatic vessels and glands, lie embedded in some loose fatty tissue in a prismatic sulcus, formed by the ilio-psoas on the outer, and the adductor longus and pectineus on the inner side.

The FEMORAL SHEATH, composed of fascia transversalis in front and fascia iliaca behind, invests the vessels for a distance of about $1\frac{1}{2}$ inches beyond Poupart's ligament, and is divided by slight septa into *three compartments*, of which the outer contains the artery, the middle the vein, and the internal forms the CRURAL CANAL. The latter contains some fatty tissue, and one or two lymphatic glands and lymphatic vessels.

The FEMORAL ARTERY lies midway between the anterior superior spine and the symphysis, and is very superficial. It is therefore easily *compressed*, immediately under Poupart's ligament against the subjacent pubis and hip capsule, and toward the apex of Scarpa's triangle against the shaft of the femur, which lies rather to its outer side. On the other hand, the vessel is liable to *injury*, which sometimes causes *arterio-venous aneurism*, when both vein and artery are involved, and it has been opened by *ulcerative processes*. The common femoral is not infrequently the seat of *aneurism*, the exposed

position and the relationship to the hip-joint exposing it to injury, while it soon breaks up into two large trunks.

The *line* of the femoral artery in the thigh is from a point midway between the anterior superior spine and the symphysis to the adductor tubercle, when the limb is slightly flexed and rotated outwards. If this line be divided into three equal portions, the first represents so much of the artery as lies in Scarpa's triangle, and the second that which lies in Hunter's canal. The common femoral artery may be *ligatured* just below Poupart's ligament, or the superficial femoral at the apex of the triangle, the bifurcation taking place about $1\frac{1}{2}$ inches below Poupart. The COMMON FEMORAL is not often ligatured, as gangrene from want of blood-supply is apt to be caused. The limb having been adducted and rotated outwards, and the line of the artery noted, a vertical incision, commencing over Poupart's ligament and extending down some 3 inches, is made through skin, fascia, and fascia lata, the femoral sheath exposed, the arterial compartment opened, and the ligature passed from within outwards. Collateral circulation is established through the gluteal, sciatic, and obturator of the internal iliac, and the deep circumflex iliac of the external iliac, with branches of the profunda, and by the internal pudic of the internal iliac, with the superficial and deep external pudic of the common femoral. The PROFUNDA, or deep femoral artery, is given off about $1\frac{1}{2}$ inches below Poupart, and it in turn gives off external and internal circumflex, and perforating branches.

The SUPERFICIAL ARTERY is much more frequently ligatured at the *apex of Scarpa's triangle*, the circulation being maintained by the profunda and its branches. The limb being placed as above, a 3-inch incision is made in the course of the artery, commencing about $2\frac{1}{2}$ inches below Poupart, through skin, fascia, and fascia lata, the long saphenous vein being avoided if near the incision. The sartorius muscle is now drawn outwards, the sheath of the vessels exposed and opened, the internal cutaneous branch of the anterior crural nerve being drawn to one side, and the vessel ligatured. The *vein* is here a posterior relation, and the long *saphenous nerve* and nerve to the vastus internus are external relations. The collateral circulation is maintained by the above-mentioned branches of the iliacs with the profunda branches, and in

addition by branches of the profunda with the popliteal and its branches.

A roughly applied tourniquet may cause *phlebitis* of the femoral vein (and neuralgia of the anterior crural nerve). Phlebitis is said also to have been caused by violent flexion of the thigh. A slight dilatation of the upper part of the femoral vein overlapping the crural canal is not infrequent, and, giving an impulse on coughing, may lead to a diagnosis of *femoral hernia*.

The *long saphenous vein* is sometimes varicosed close up to the saphenous opening, and is not infrequently ligatured a little below this point in severe cases of varicose veins of the leg. It is said that this operation has been followed by thrombosis of the femoral vein, and even of the external iliac vein. The *anterior crural nerve* may be affected by superficial injuries, and sometimes in psoas abscess. The *genito-crural nerve* supplies the cremaster muscle and also the skin of Scarpa's triangle. Irritation of the skin in this region causes retraction of the testicle, especially in children, and this *reflex* is used to test the condition of the second lumbar segment of the cord.

Of the MUSCLES, the ILIO-PSOAS is of particular importance surgically, on account of its sheath directing the course of the pus in psoas abscess, where the spine is the seat of disease (*q.v.*). Being extended over the hip-joint, the muscle is sometimes sprained in violent exercise, while a *bursa*, which lies under the muscle, between it and the thinnest portion of the hip capsule, may become inflamed, necessitating flexion of the hip to relieve it. This bursa may become enlarged in chronic inflammation, and inflammatory processes in it may affect the pelvis. *Contraction* of the ilio-psoas muscle and consequent flexion of the hip may be caused by renal and cæcal irritation, appendicular abscess especially when situated in the pelvis, psoas abscess, inflammation of the bursa, and hip disease.

Rupture of the ADDUCTOR muscles is not infrequent, especially in horsemen— *rider's sprain* consisting of a partial tearing of the muscle close to its pelvic attachment, which is frequently accompanied by a considerable effusion of blood, which may form a hard swelling. *Ossification* sometimes follows such accidents, a bone— *rider's bone*—some 1 to 3 inches in

length, developing in the tendon of the adductor longus or magnus.

The **obturator, or adductor region**, of the thigh lies deeply under the base of Scarpa's triangle, being limited by the hip-joint externally, the pubic arch and the perineum internally, the horizontal ramus of the pubis above, and the tuber ischii below. The OBTURATOR MEMBRANE covers in the foramen, and is covered externally by the obturator externus muscle. In the upper and outer part of the membrane is the aperture constituting the OBTURATOR CANAL, which, $\frac{1}{2}$ to $\frac{3}{4}$ inch in breadth, is directed downwards, forwards, and inwards. It is bounded above by the pubic ramus, below by the membrane and the two obturator muscles. Its pelvic orifice is overlaid by parietal pelvic fascia, extraperitoneal tissue, and by the distended bladder, while its orifice on the thigh opens on the deep surface of the pectineus, slightly internal to the femoral vein. The canal lodges some loose fatty tissue, and is traversed by the *obturator vessels and nerve*, the artery occupying the outer part of the canal, and sending a branch to the hip-joint through the cotyloid notch, and supplying the adductor muscles. The nerve arises from the second, third, and fourth lumbar nerves, divides into two branches in the canal, and sends a branch through the cotyloid notch to the hip-joint, supplies the adductor gracilis and obturator externus, and sends a branch to the knee-joint (geniculate branch). A *hernia* may proceed through the canal, lie beneath the pectineus, and closely simulate a femoral hernia (see Hernia). In addition to the obturator externus and adductor muscles, the gracilis and pectineus form the mass of *muscle* which occupies this region.

The **HIP-JOINT** is an excellent example of a ball-and-socket joint. Ilium, ischium, and pubis all enter into the composition of the **acetabulum**, and are connected by a Y-shaped cartilage, which begins to ossify about the twelfth year, and has disappeared by the sixteenth. Separation, from injury, of the three anatomical portions has occasionally occurred prior to fusion. The articular portion of the acetabulum is roughly horseshoe-shaped, about $\frac{3}{4}$ inch broad, and rests upon the upper thick portion of the bone, which sends a buttress up in front of the great sacro-sciatic notch to the sacro-iliac articulation, and one down from the lower and back

part of the articulation to the tuber ischii. The projecting bony rim of the acetabulum is interrupted below by the *cotyloid notch*, which is bridged by the *transverse ligament*, transmits the articular vessels and nerves, and leads to the *non-articular portion* of the acetabulum, which is extremely thin. The weight of the body, however, does not come upon this thin portion, and ordinarily the head of the femur does not come in contact with it in any position. This area is occupied by some fatty tissue, covered by the synovial mem-

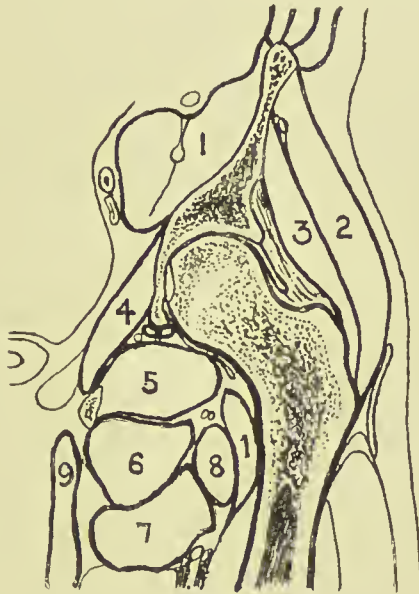


FIG. 37.—OUTLINE DIAGRAM OF LONGITUDINAL SECTION OF HIP.
(After Braune.)

- | | | |
|---|------------------|------------------|
| 1. Ilio-psoas with ant. crural
nerve embedded. | 4. Obturat. int. | 7. Adduct. brev. |
| 2. Glut. med. | 5. Obturat. ext. | 8. Pectineus. |
| 3. Glut. min. | 6. Adduct. mag. | 9. Gracilis. |

brane. It is frequently perforated in *hip disease* in children, prior to soldering of the component parts, the tubercular débris thus entering the pelvis, passing up under the obturator internus and obturator fascia, and appearing finally above Poupart's ligament. It is also possible for the hip-joint to be invaded through this thin area by pelvic abscess.

The depth of the acetabulum is increased by the *cotyloid ligament*, which is attached all round to its rim, like a ring or collar, while its free edge projects inward, encircling and grasp-

ing the head of the femur, and thus providing a practically air-tight joint. The spherical HEAD OF THE FEMUR is marked by the depression for the *ligamentum teres* below and behind the summit, with, beyond it, a smooth flattened area over which the ligament glides. The inner extremity of the ligament is attached to the bone on each side of the cotyloid notch and to the transverse ligament. The head of the femur is separated from the neck by an *epiphysis*, which appears in the first year, and unites to the shaft about the eighteenth year. Sometimes the *articular cartilage* of the head is prolonged over the anterior aspect of the neck, and a facet appears on the anterior portion of the acetabular rim, where a position of flexion is frequently assumed, as in tailors and acrobats.

The NECK OF THE FEMUR forms normally an angle of 125 degrees with the shaft. Its anterior surface lies entirely within the capsule of the joint, but only the inner two-thirds of the posterior surface are intracapsular. The outer one-third of the posterior surface is grooved by the tendon of the obturator externus muscle, which is inserted in a depression at the base of the great trochanter (obturator fossa). The *intracapsular portion* of the neck of the femur is invested by fibrous bands, reflected from the capsule at its insertion, which are called the *cervical ligaments*, and extend up to the junction with the head. These extend especially from (a) the middle of the Y-shaped ligament; (b) from the pectineo-femoral ligament; and (c) from the upper and back part of the neck.

The GREAT TROCHANTER gives attachment to the gluteus minimus by its anterior margin; the obturator internus and pyriformis by its upper margin; the quadratus femoris by its posterior margin, and the gluteus medius by its outer surface, the bursa separating it from the gluteus maximus being situated just below this point. The *epiphysis* of the great trochanter appears about the second year, and joins the shaft about the eighteenth. The great trochanter has occasionally been *separated* as an epiphysis. The tip of the great trochanter lies nearly on a level with the spine of the pubis, and $\frac{3}{4}$ inch below the top of the head of the femur.

The SMALL TROCHANTER gives insertion to the ilio-psoas muscle, and from it three ridges diverge—the posterior inter-

trochanteric ridge, a ridge along the under surface of the neck to the head, and one running vertically downwards to the *linea aspera*. The *epiphysis* of the small trochanter appears about the fourteenth year, and joins the shaft at the eighteenth.

The CAPSULAR LIGAMENT is attached to the rim of the acetabulum, the cotyloid ligament, and the transverse ligament, at its pelvic extremity, while on the femur it is attached in front to the anterior intertrochanteric line, above to the junction of neck and great trochanter, posteriorly to the junction of the middle and outer thirds of the neck, and inferiorly to the lower border of the neck near the small trochanter. This capsular ligament is strengthened by certain limbs, of which the most important is (a) the *Y-shaped ligament* of Bigelow, which is inverted, the tail being inserted into the anterior inferior spine, and the two bands near either extremity of the anterior intertrochanteric line, the thickest part of the ligament being $\frac{1}{4}$ inch thick. Extension is limited by this ligament. The thinnest part of the capsular ligament is inside the inner limb of the Y-shaped ligament, just under the bursa beneath the, ilio-psoas muscle. Sometimes the ligament is wanting here, synovial membrane and bursa being in contact with one another. (b) The *pubo-femoral ligament* from the ilio-pectineal eminence to the lower aspect of the neck limits abduction. (c) The *ischio-femoral ligament* from the lower part of the rim of the acetabulum becomes fused in a portion of the capsule posteriorly, called the *zona orbicularis*. This ligament, with the *ligamentum teres*, limits adduction when the limb is flexed. When the limb is extended, adduction is limited by the ilio-femoral ligament and upper part of the capsule. Rotation outwards and inwards with the limb extended is also limited by the ilio-femoral ligament, while, when the limb is flexed, outward rotation is limited by the ilio-femoral and *teres* ligaments, and inward rotation by the ischio-femoral ligament. Flexion is only limited by contact with the trunk, save when the knee is extended, when the hamstring muscles, sciatic nerve, etc., limit it. Additional stability is given the joint by the muscles which lie in contact with it: the *gluteus minimus* and *rectus femoris* above; *ilio-psoas* in front; *obturator externus* below; and *pyriformis*, *obturator internus* and *gemelli*, and *quadratus femoris* behind;

while cohesion and atmospheric pressure also aid greatly in holding the surfaces in contact.

The **SYNOVIAL MEMBRANE** lines the inner surface of the capsule, from which it is reflected inwards on to the neck along the capsular insertion, being separated from the neck by the cervical ligaments. It is inserted at the head round the margin of the articular cartilage, which ends close to the epiphyseal plate for the head. At its acetabular extremity, where it also is inserted at the margin of the articular cartilage, it is reflected over the cotyloid ligament, overlies the fat in the non-articular part, and covers the ligamentum teres. It sometimes communicates with the bursa lying under the psoas on its anterior aspect.

The *vessels* of the joint are chiefly derived from the internal and external circumflex and obturator arteries.

The *nerve-supply* of the hip-joint is (*a*) from the anterior crural at the front, (*b*) from the obturator at the lower and inner part, and (*c*) from the sacral plexus and sciatic nerve posteriorly. In hip-joint disease pain is frequently referred to the knee, so much so that the condition of the hip is not infrequently overlooked and the knee alone complained of. It is therefore interesting to note that hip and knee have an almost identical nerve-supply, the knee receiving an anterior crural branch in front, an obturator branch posteriorly, and sciatic branches laterally and posteriorly. In so-called '*hysterical hip*,' the patient frequently simulates some forms of hip disease, and it is supposed that the origin of the sciatic nerve from sacral segments of the cord, which also supply the pelvic viscera, may so far account for this.

Fractures of the neck of the femur may be either **INTRACAPSULAR**, or so-called extracapsular. The former generally occurs at the junction of head and neck, as a result of slight indirect violence in elderly persons in whom (*a*) the angle between neck and shaft has diminished from 160 in the child to 125 in the adult, or even less; and (*b*) there is absorption or fatty degeneration of *osseous trabeculæ*, and notably of the *calcar femorale*. These *trabeculæ* run in two series—the first from the lower part of the neck near the small trochanter to the upper part of the head; and the second from below the great trochanter to the lower part of the head, thus forming together a bracket-shaped arrangement to distribute the

weight. The *calcar femorale* runs from near the small trochanter to the under surface of the head. This fracture is rarely impacted, but when it is, the narrow compact neck is driven into the broad cancellous head. The head is supplied with *blood* from the neck, cervical ligaments, and the ligamentum teres, but if the two first sources of blood-supply are cut off, the last is not sufficient to promote osseous union.

An EXTRACAPSULAR FRACTURE of the neck of the femur is anatomically impossible in front, where the capsule is inserted into the intertrochanteric line, but is possible behind. Generally such fractures are extracapsular behind and intracapsular in front, or even, owing to the thickness of the capsule at that part, intracapsular. Such fractures are generally caused by considerable violence, occur usually in males about middle life, and impaction is common, the contracted neck being driven into the upper end of the shaft and trochanter, which may be split by it.

Certain SYMPTOMS are associated with both forms of fracture of the neck of the femur: *Shortening* is due to the glutei, hamstrings, adductors, rectus, etc. *Eversion* is due to the weight of the limb, the centre of gravity of which lies to the outer side; to the action of the ilio-psoas, adductors, pectineus, and small rotators; and to the fracture being generally more extensive posteriorly than in front, owing to the more fragile nature of the bone posteriorly. *Shortening* is evidenced by direct measurement, by the rising of the great trochanter above Nelaton's line, and by relaxation of the fascia lata stretching between the trochanter and the iliac crest. Shortening is generally greater in extra- than in intracapsular fractures. A *fulness* is sometimes produced just under Poupert's ligament, either by effused blood or the broken fragments pushing the capsule forwards.

Dislocation of the hip is generally due to violence, but may rarely be due to muscular action, while it is a frequent sequela of hip disease, and is not infrequently congenital. The only portion of the acetabulum which is shallow, and where the rim is deficient, is below, in the region of the cotyloid notch, and here the capsule also is rather weak. When the limb is markedly abducted, the head of the bone tends to glide out of the socket, and come against this weak portion of acetabulum and capsule; and if the abduction be increased, the great

trochanter hitches on the summit of the acetabulum, acts as a fulcrum, and so enables the head to burst through the capsule toward the thyroid foramen. It is believed that all dislocations of the hip are produced when the limb is in this abducted position, and are primarily downwards; the lower part of the capsule is torn, extending from about the cotyloid notch to near the small trochanter, and thence along the back of the neck; the ligamentum teres is torn, but the Y-shaped ligament remains intact. Four typical forms of dislocation of the hip are described, which, resulting from the original downward displacement, depend largely upon the character of the dislocating force and upon the intact Y-shaped ligament.

The most common dislocation of the hip is that backwards ON TO THE DORSUM, and is produced by a position of flexion and internal rotation of the thigh on the pelvis, assisted perhaps by the glutei, hamstring, and adductor muscles. The head of the bone lies on the dorsum above the tendon of the obturator internus. The limb is shortened; it is flexed, adducted, and rotated inwards, abduction and rotation outwards being impossible; the ilio-psoas is much stretched, and the quadratus femoris, pyriformis, obturator, and gemelli lacerated, even the pectineus and glutei frequently suffering, while the great sciatic nerve may be compressed. The flexion is due to tension upon the Y-shaped ligament and ilio-psoas, the adduction and inversion to the altered position of the head, the Y-shaped ligament remaining intact. The gluteal fold is raised, the depression behind the great trochanter is obliterated, and the head may appear as a fulness of the buttock. Dislocation BACKWARDS on to the ischium is similar in mode of production and symptoms to the former, the flexion and inward rotation at the time of production being more marked, while the head ultimately lies on the ischium near the spine, and below the tendon of the obturator internus. This form is sometimes referred to as dislocation into the sciatic notch; it is doubtful if such a displacement ever occurs.

Dislocation into the OBTURATOR FORAMEN (THYROID) is produced where the head maintains its primary position, or moves slightly forwards. If, on the other hand, extension and external rotation are present, the head may slip forward, and lie on the pubic ramus in front of the ilio-pectineal eminence, producing a dislocation ON TO THE PUBIS. In these

forms the limb is flexed, abducted, and everted. In the obturator form the position is maintained by the ilio-psoas and the Y-shaped ligament; in the pubic form the abduction and eversion is chiefly due to the position of the head of the bone, the Y-shaped ligament remaining intact, while the flexion is due chiefly to tension of the ilio-psoas. In these forms the adductors, gracilis, and pectineus muscles are frequently lacerated, while the ilio-psoas, pyriformis, and glutei muscles are stretched. The obturator nerve may be stretched or torn, and in the pubic form the anterior crural nerve may suffer. In the pubic dislocation there is slight shortening of the limb, while in the obturator there is apparent lengthening due to tilting of the pelvis down on the injured side.

In REDUCING these dislocations, the limb is (1) flexed fully upon the abdomen so as to relax the Y-shaped ligament, and, further, to disengage the head of the bone. This flexion is combined with marked adduction in the first two forms, and with marked abduction in the two latter. In other words, one first increases the deformity in all cases. (2) In order to bring the head of the bone back to the position of the rent in the capsule, the limb is circumducted out in the first two forms, and circumducted in in the two latter. (3) To make the limb re-enter the acetabulum, the limb is extended in all cases. Much depends in all cases in getting the muscles relaxed, and in making the *flexion of the thigh* on the pelvis as full as possible. In addition to the action described above, this movement hitches the upper end of the femur against the pelvis, and so *lifts the head* of the femur on to a level with the acetabulum, which, it will be remarked, presents a raised margin externally as well as internally. It is sometimes useful to remember that the internal condyle faces nearly in the same direction as the head of the bone.

CONGENITAL DISLOCATION of the hip is fairly common, especially in females. While the dislocation is generally of the dorsal type, it *differs* from a traumatic dislocation in certain important particulars: The acetabulum is rudimentary, its surface being covered by fibrous tissue instead of articular cartilage; the ligamentum teres may be absent, or, when present, is wider and longer than normal; the capsule is elongated, and its upper part, which bears the weight of the

limb, is thickened, resembling fibro-cartilage. The head of the femur is smaller than normal and rather pointed, and the neck is short and directed straight forwards, instead of forwards and inwards as it is normally. The head generally lies to the outer side of the anterior inferior spine of the ilium, while the great trochanter is directed backwards, but, in children at least, the head possesses a considerable range of movement in an up-and-down direction, producing a characteristic gait. The limb is generally quite straight and shortened; the great trochanter is situated posterior to instead of in front of the head, and above Nelaton's line, forming a prominence in the gluteal region. As the trunk has a tendency to fall forward, owing to gravity now falling in front of the axis of the bone, the shoulders are thrown back, there is marked lordosis, and the hips are prominent. -

Hip-Joint Disease.—The hip is often affected by tubercle, especially in children, and is less frequently attacked by rheumatoid arthritis. As the joint is deeply placed, evidence of swelling in the joint is not an early symptom, and it is generally late in the disease before the tubercular débris makes an exit externally. Pain also, as already pointed out, is often referred to the knee, the hip-joint being sometimes entirely overlooked. Hip disease, therefore, in the early stages, is, to a considerable extent, diagnosed by the position of the limb, and its limited power of movement, and it should be remembered that it is not always easy at a very early stage to differentiate between hip disease and psoas abscess. When the hip-joint is affected, the patient places the limb in the position of greatest ease, and keeps it there, as far as possible, without movement with reference to the pelvis. When the hip-joint is fixed, the limb may still be moved in various directions by means of the spine, and thus the superficial observer is easily deceived as to the fixity of the joint. Hip disease is generally said to present certain stages, and they are at least convenient as a means of describing the disease.

1. In the *first stage* effusion of fluid has occurred in the joint; all the ligaments are intact, and, in order to accommodate this fluid, the patient fixes the hip-joint in a position of (a) flexion and (b) abduction (also external rotation), which is that of the greatest capacity of the joint. In order to walk he disguises this position by (a) producing a lordosis curve of

the spine, thereby tilting the pelvis downwards, and so obliterating the flexion; (b) producing a scoliosis curve of the spine, thereby tilting the pelvis down on the affected side, and so obliterating the abduction. Thus this patient, while keeping his hip-joint flexed and abducted on the pelvis, walks with a limb which is apparently straight and parallel to its neighbour by means of a lordosis and scoliosis of his spine. Owing, however, to the tilting downwards of the pelvis on the affected side, the limb appears longer than its neighbour, and this, therefore, is referred to as the *stage of apparent lengthening*.

2. The effusion of fluid remaining present, but the ligaments becoming affected, while the adductor muscles become reflexly irritated through the obturator nerve, the hip-joint next assumes a position of (a) flexion and (b) adduction. Here the flexion is corrected as before, while the adduction is corrected by a scoliosis curve of the spine in a direction opposite to the previous one, so that the pelvis is now tilted up on the affected side. Thus the limb again appears straight, but, owing to the tilting of the pelvis, shorter than its neighbour, and so this period is referred to as that of *apparent shortening*.

3. In the late stages of the disease either (a) a *pathological dislocation of the head* on to the dorsum or (b) *destruction of the head* occurs. In both cases there is shortening, and this stage is therefore referred to as that of *actual shortening*. (a) Here the limb becomes fixed in a position of flexion and adduction, which the patient conceals as in (2). (b) Here the limb frequently is straight and perhaps everted, the condition being practically that of pathological fracture of the neck of the femur.

The débris from tubercular hip disease may make its escape in various directions. While it sometimes causes a fulness under the femoral vessels close to Poupart's ligament, it generally escapes from the posterior portion of the joint, and then may work its way forward between the gluteus minimus and the bone and point in front of the great trochanter, or may make its way backwards and point in the gluteal region. When it does escape from the capsule in front, it may enter the sheath of the ilio-psoas, or, if it escapes through the acetabulum, it may work its way up under the obturator and iliac fascia, and so point above Poupart's ligament. In either of these cases it might lead to confusion with real psoas abscess.

Where the disease in the hip-joint has led to extensive destruction of cartilage, *excision of the hip-joint* is performed. This is best done through a single incision in the line of the limb when flexed and adducted, made just above the great trochanter down on to the head of the bone. The capsule is thus only split at one point, the head of the bone removed by a fan-shaped osteotome, the cut neck is rounded off, all débris removed from the acetabulum, and the limb put up in a position of abduction and extension. The abduction fixes the cut neck against the acetabulum, thus facilitating fibrous union between the two surfaces. The operation as performed for disease is easy and quickly done, and excellent results as regards subsequent movement are obtained when an operation is done at a comparatively early stage of the disease.

Amputation at the hip is best performed by a racket incision, which commences about 2 inches above the great trochanter, runs down over it for about 6 inches, and is then made to encircle the limb skin deep. The muscles surrounding the great trochanter are next divided on either side, the hip-joint exposed and opened, the ligamentum teres divided, the head of the bone forced out, and kept out by introducing a pad of gauze into the acetabulum. The muscles are then divided circularly, and the limb removed (Jordan's amputation). *Bleeding is controlled* by the shut fist of an assistant placed over the termination of the abdominal aorta, the assistant standing on a stool and leaning the weight of his body on it through his straight arm (Macewen). The muscles divided are the adductors, hamstrings, quadriceps, sartorius, tensor fasciæ femoris, ilio-psoas, pectineus, glutei, obturator, gemelli, and pyriformis. If the muscles be stitched together after the amputation, a remarkably mobile stump is obtained. The vessels which require ligature are the femoral and profunda, the circumflexes and branches from them and from the sciatic, and the first perforating of the profunda. The nerves divided are the anterior crural, external cutaneous, and obturator branches in front, and the sciatic nerves behind.

4. **THE THIGH**—SURFACE ANATOMY.—Running from the apex of Scarpa's triangle to the internal condyle of the femur is a shallow groove, which lodges the sartorius muscle and corresponds to the position of the femoral artery in Hunter's canal,

and marks the separation between the vastus internus on the outside, and the adductor longus and magnus on the inside. The sartorius also forms the inner margin of a triangle, whose apex is at the anterior superior spine and whose outer border is formed by the tensor fasciæ femoris, the floor being formed by the rectus. As the knee is approached, the rectus in front and vasti on either side become particularly prominent. The position of the external intermuscular septum, which extends in from the fascia lata to the linea aspera of the femur, separating the flexor and extensor muscles, is marked by a slight vertical groove on the outer posterior aspect of the thigh, which extends from the insertion of the gluteus maximus to the outer side of the knee-joint. The skin over this line is rather adherent to the fascia lata, and in front of it the tissues do not yield readily to pressure, owing to the ilio-tibial band. The course of the *long saphenous vein* is indicated by a line running from the saphenous opening to the posterior border of the sartorius at the level of the internal condyle ; that of the *long saphenous nerve* by the line of the artery, the nerve lying at first outside, and then, in Hunter's canal, crossing in front of the femoral sheath to the inside. The course of the *great sciatic nerve* is indicated by a line from a point midway between the great trochanter and tuber ischii to the middle of the popliteal space.

The SKIN of the thigh is thin on the inner, but thicker on the outer aspect of the limb, while, with the exception of the portion over the external intermuscular septum, it is loosely attached, becoming easily separated by injury or in amputation, and permitting extensive subcutaneous extravasations. The FASCIA LATA, with the ilio-tibial band and external intermuscular septum, has already been spoken of. In all it sends in *three septa*, separating the muscles into three distinct groups—anterior, flexor, and adductor. The *extensor* group is supplied by the anterior crural nerve, the *flexor* group by the great sciatic nerve, and the *adductor* group by the obturator nerve. Both external and internal septa extend into the linea aspera. The former, commencing at the insertion of the gluteus maximus beneath the great trochanter, ends at the knee-joint, and separates the extensor from the flexor muscles (vastus externus from short head of biceps), while the latter, less well defined, extends from the small trochanter to the

adductor tubercle, and separates the extensors from the adductors (vastus internus from the adductor longus and magnus). A third ill-defined septum separates the adductors from the flexors. At the knee the fascia extends down in front over the quadriceps and patella, and becomes continuous with the deep fascia of the leg, while posteriorly it covers in the popliteal space, and surrounds the muscles forming its lateral boundaries. The fascia lata offers resistance to all swellings lying under it. It has occasionally been *ruptured* by injury, and the subjacent injured muscle (quadri-

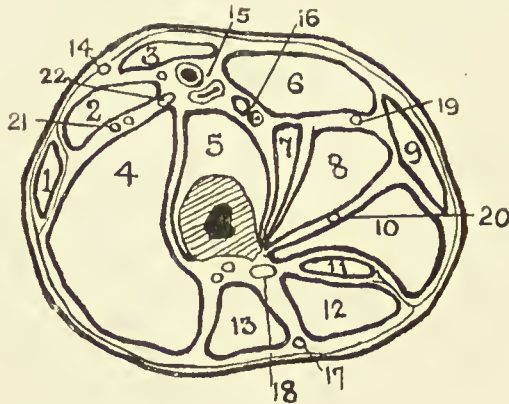


FIG. 38.—OUTLINE DIAGRAM OF TRANSVERSE SECTION OF THIGH AT THE JUNCTION OF UPPER AND MIDDLE THIRDS.

(Modified from Heath.)

- | | | |
|-----------------------------|------------------------|----------------------------------|
| 1. Tensor fasciæ femoriæ. | 9. Adduct. gracilis. | 16. Profunda vessels. |
| 2. Rectus. | 10. Adduct. magnus. | 17. Small sciatic nerve. |
| 3. Sartorius. | 11. Semimemb. | 18. Great sciatic nerve. |
| 4. Vastus externus. | 12. Semitend. | 19. Superficial obturator nerve. |
| 5. Vastus int. and crureus. | 13. Biceps. | 20. Deep obturator nerve. |
| 6. Adduct. long. | 14. Ext. cutan. nerve. | 21. Ext. circumflex vessels. |
| 7. Pectineus. | 15. Femoral vessels. | 22. Ant. crural nerve. |
| 8. Adduct. brev. | | |

iceps, or adductor longus) has formed a hernia through the rent. The *quadriceps tendon* has been ruptured by muscular violence.

Hunter's canal lies on the inner side of the thigh, occupying fully the middle third of the line already given as representing the course of the femoral artery, the upper third of which lies in Scarpa's triangle. It consists of a narrow prismatic space, bounded externally by the vastus internus and internally by the adductors longus and magnus, and roofed in by a strong fibrous expansion running from the vastus to the adductors. It contains the superficial femoral vessels, the vein lying behind

and a little to the outside of the artery, and the long saphenous nerve, which lies in front of the vessels, running obliquely from without inwards.

In LIGATURE OF THE ARTERY, in Hunter's canal, the limb is flexed, abducted, and rotated outwards, and an incision made in the middle one-third of the thigh through the skin, subcutaneous tissue, and deep fascia, the long saphenous vein being drawn to one side if exposed; the sartorius, whose fibres may be recognized running down and inwards (while those of the vastus internus run down and out), is drawn inwards (opposite of its treatment in Scarpa's triangle), and then the aponeurotic roof of the canal is incised, the long saphenous nerve drawn to the side, and the ligature passed from either side. The collateral circulation is the same as in ligature at the apex of Scarpa.

THE FEMUR.—With reference to operations on and fractures of the femur, it should be remembered that the *periosteum* is much thicker in children than in adults, so that displacement is frequently prevented by it in children. The femoral artery lies close to the head of the femur, but from that point to the lower end of Hunter's canal is separated from it by a considerable mass of muscle, while in passing through the opening in the adductor magnus, and thereafter as the popliteal artery, it lies close to the bone. The main *nutrient artery* enters the centre of the shaft at the *linea aspera*, and a second enters 2 or 3 inches lower down. The bone is inclined downwards and inwards from hip to knee, the obliquity being greater in females, and it is slightly curved, with the convexity forwards. In section it is triangular in the middle one-third, and oval in the lower third. While the bone is generally deeply placed among the muscles, particularly in the upper half, it lies entirely in the anterior half of a transverse section at the junction of the middle and lower one-third. In this region also there are no important vessels or nerves on the outer side, and the shaft of the bone is comparatively thin on its outer surface. Hence operations for osteomyelitis, wiring ununited fractures, etc., are generally performed through this outer aspect. The two lower limbs are very frequently of *unequal length*, the left being often the longer by about $\frac{1}{4}$ inch. This difference is generally due to the femur.

Fractures of the shaft of the femur may be due to either

direct or indirect violence, the former most often affecting the lower one-third, the latter the upper one-third, while the two forms are of equal frequency in the middle one-third. As direct violence generally produces a transverse, while indirect produces an oblique fracture, it follows that fractures in the lower one-third are generally transverse, and those in the upper generally oblique, while oblique and transverse occur equally in the middle one-third. The femur is rarely fractured by muscular violence. In oblique fractures the obliquity is from above, downwards and forwards, this obliquity being combined with an inclination inwards in the upper one-third. In both upper and middle one-third where the fracture is oblique, the upper fragment tends to project forwards and a little outwards, being pushed forward by the lower fragment, and pulled by the action of the ilio-psoas. This tilting forward is most marked in the upper one-third. The lower fragment is drawn up behind the upper by the rectus, gracilis, sartorius, tensor fasciæ femoris, hamstrings, and adductors, the latter also producing a slight inclination inwards. The lower fragment is also generally everted by the weight of the limb and external rotators. Fracture in the lower one-third generally occurs about 2 inches above the epiphysis, at the position where compact shaft and cancellous extremity meet. Where this fracture is oblique, and the obliquity favours the displacement, the lower fragment is apt to be tilted backwards by the gastrocnemius, and drawn up by the hamstrings, adductors, and other muscles mentioned above, and as the femoral artery lies close to the bone in this region it is in some danger of being wounded. In such cases the limb is best treated in a flexed position, and this position of flexion is necessary in treating fractures of the upper one-third. Spiral fractures due to torsion forces are met with in the lower end of the femur and of the tibia, and are sometimes spoken of as helicoidal fractures of Leriche. Fractures of the femur in children are frequently transverse, and, the periosteum remaining intact, no sensible displacement may occur. In adults shortening frequently occurs as a result, but in estimating the amount of this the frequent normal difference in the length of the two limbs should be remembered.

Genu valgum, or knock-knee, is a deformity due to rickets, which affects the lower third of the femur, the shaft of

the bone becoming bent with the convexity inwards. In consequence of this curve the epiphyseal line is tilted, the outer extremity being on a higher level than the inner, while the internal condyle appears to be lengthened in a downward direction owing to the tilting. When the patient attempts to stand erect with the legs straight, the head of the tibia rests on the uneven condylar surfaces, and is therefore thrown outwards, so that he stands with the knees touching or even crossing one another, and the feet wide apart. When, on the other hand, he sits, the tibia rests on the more posterior condylar surface, which is not affected by the lateral tilting, and so the deformity disappears. A patient with severe genu valgum makes use of this method of minimizing the deformity. Instead of attempting to walk with straight limbs, which would often be so divergent as to render walking impossible, he flexes both knees and hips, and so diminishes the divergence. In *operating* on genu valgum the bone is cut through by an osteotome, introduced through the soft tissues, at a point a finger's breadth in front of the adductor tubercle (to avoid the anastomotica magna), and a finger's breadth above the *external* condyle (that which is tilted upwards; to avoid the epiphyseal line). A wedge-shaped incision is made through the bone (practically a transverse cut or fracture), the deformity is fully corrected, and the limb put in a splint until united.

GENU VARUM, or bow-leg, is a less definite condition also due to rickets, in which the femur presents a curve with the convexity outwards, which may involve the whole shaft or only part of it. The femoral curve is generally associated with one in the tibia, which is in some cases is principally affected.

AMPUTATION OF THE THIGH is generally performed, where possible, in the lower third. The skin flaps are cut long, are easily raised, and retract markedly. The anterior is generally the longer. The muscles are generally cut by a circular sweep, and retract unequally, the adductors, vasti, and crureus being limited in their retractive power by their attachment to the shaft of the femur. The femoral artery is generally cut in Hunter's canal, while the profunda, considerably reduced in size, lies close to the linea aspera of the femur, behind the tendon of the adductor longus. The other vessels cut are the descending branches of the external circumflex, lower per-

forating, and long saphenous vein. In order to avoid splitting the femoral artery in cutting the flaps in an amputation in the middle third of the femur, it is advised to make them slightly lateral instead of directly antero-posterior. Care should be taken not to include the long saphenous nerve in the ligature of the femoral artery. The great sciatic nerve lies posteriorly amidst the hamstring muscles; it is best pulled down, and cut short, to minimize risk of formation of *stump neuroma*. The other nerves cut are branches of the middle and internal cutaneous and muscular branches of the anterior crural, the anterior branch of the external cutaneous, the obturator,¹ and small sciatic.

THE KNEE—SURFACE ANATOMY.—When the leg is extended it does not lie in the same line as the thigh, but, owing to the obliquity of the latter, forms an angle of about 170 with it. The *patella* is generally easily recognized, particularly when the limb is extended, its inner border being more prominent than the outer. In the extended position it is very mobile, and advantage may be taken of this to displace it sufficiently laterally to permit of examination of the outer edge of the external condyle and inner edge of the internal for evidences of lipping, which occurs in rheumatoid arthritis, etc. On either side of the patella, and between it and the femoral condyle, is a depression, which in stout persons may be obliterated by fat, which in the extended position, with the rectus relaxed, may be united to its neighbour by a shallow depression along the upper margin, the whole forming a horseshoe, called the *peripatellar depression*. Under this depression are situated the lateral and superior pouches of synovial membrane of the joint, and when these are distended from any cause, the depression is replaced by a swelling, roughly horseshoe in shape, which may obliterate the patellar outline. When the knee is flexed, the patella at first is rendered prominent, and then sinks deeply into the intercondyloid notch, where it becomes firmly fixed, protecting the articulation, and assisting the tubercle of the tibia to bear the weight of the body in kneeling. In this flexed position the upper portion of the trochlear surface of the femur can be palpated; the condyles separate from the head of the tibia and become more distinct, and the ligamentum patellæ is rendered tense. On the outer side of the knee the tendon of the biceps may be

felt posteriorly, descending to be inserted into the head of the fibula, which is about a finger's breadth below the articular margin of the tibia, and on a level with the prominent external tuberosity of the tibia. Into this latter is inserted the ilio-tibial band of fascia lata, which becomes very prominent when the knee is actively extended. Immediately in front of the biceps tendon, near its insertion, the upper part of the external lateral ligament of the knee may be felt when the limb is very slightly flexed.

The internal condyle of the femur is much more prominent than the external, and marking its upper limit, and the position of the epiphyseal line, is the *adductor tubercle* into which the tendon of the adductor magnus is inserted. Where any difficulty is experienced in finding the tubercle, the limb should be forcibly adducted, and the finger then run down along the prominent adductor tendon to the tubercle. The sartorius and the tendon of the gracilis, the former anterior, pass behind the internal condyle, and then curve forwards, to be inserted into the upper and inner surface of the shaft of the tibia. As they cross the joint the tendon of the semitendinosus lies close but posterior to them, the interspace being occupied by the long saphenous vein and nerve, and the superficial branch of the anastomotica magna.

The SKIN of the front of the knee is dense, while the SUBCUTANEOUS TISSUE contains but little fat, and being lax permits of considerable movement of the skin when the knee is extended. This *mobility* assists in protecting the joint from various injuries, and is utilized in certain operations on the knee to render the line of incision very oblique by first pulling down the skin prior to incising it. Where the flexed knee is *struck* over the bone by a blunt instrument, a clean-cut wound may result. The front of the knee is supplied with blood by the anastomotic, four articular branches of the popliteal, and anterior tibial recurrent, and with nerves from the third lumbar segment; and the fact that the joint is supplied by branches of the same vessels, and with nerves from the same spinal segment through the obturator nerve, is advanced by some as an argument in favour of the application of blisters to the front of the knee in various joint affections. The superficial lymphatics lie on the inner side, accompanying the long saphenous vein.

BURSÆ OF FRONT OF KNEE.—1. Situated in the subcutaneous tissue over the lower part of the patella and upper part of the ligamentum patellæ is the *prepatellar bursa*, which is the largest subcutaneous bursa in the body. It is frequently subdivided by septa, sometimes into superficial and deep compartments. From its position it is exposed to injury and infection, giving rise to acute bursitis, while a chronic bursitis commonly occurs from pressure of kneeling, the condition here being known as *housemaid's knee*. In the acute form, if untreated, the bursa frequently ruptures, and the septic matter invades the subcutaneous tissues in front of the knee-joint, the subsequent swelling simulating a synovitis of the knee-joint. Both forms are generally painful, particularly the acute, and as the bursa lies in close contact with the patella, the infection has occasionally spread to the bone.

2. There is also a small bursa, situated between the patellar ligament and the head of the tibia. Above the bursa the ligamentum patellæ rests on an *infrapatellar pad of fat*, which separates both it and the bursa from the synovial membrane. Occasionally, however, the bursa communicates with the joint. This bursa is more painful when inflamed, owing to the compression to which it is subjected. The pad of fat projecting from underneath the ligament might occasionally be mistaken for an enlarged bursa.

3. A small bursa occasionally exists in front of the tubercle of the tibia, and is noted especially in those who require to kneel (*prætibial bursa*).

4. Bursæ exist between the internal lateral aspect of the head of the tibia, and (*a*) the sartorius and (*b*) the gracilis and semitendinosus, which have one in common, while (*c*) a bursa separates the tendon of the gracilis from the sartorius. These bursæ, when enlarged, present an oval fluctuant swelling in the position indicated. (*d*) The semimembranosus also lies on a bursa close to its insertion; this, however, is a posterior relation.

5. A bursa exists between the quadriceps tendon and the shaft of the femur, which sometimes communicates with the joint.

The posterior aspect of the knee is occupied by the **popliteal space**—a lozenge-shaped area—which again may be divided into an upper femoral and a lower tibial triangle. The *femoral*

triangle is bounded by the biceps externally, and the semimembranosus and semitendinosus internally (the former lying under, and on the outer or triangular aspect of the latter). The insertions of these muscles embrace the two heads of the gastrocnemius, which form the boundaries of the *tibial triangle*. When examining the popliteal space, the knee should be slightly flexed in order to relax the superficial tissues and muscles, and then the finger may detect the triangular area at the back of the femur (which is often affected in acute osteomyelitis), the vessels, nerve, etc. The SKIN here is less movable than in front, and may become markedly contracted by cicatrices, resulting in flexion of the knee. Contractions forcibly overcome have caused rupture of the skin in this region. The DEEP POPLITEAL FASCIA is a continuation of the fascia lata above, and is continuous with the fascia of the leg below. While it does not possess any bony attachment it presents a firm unyielding barrier to tumours, abscesses, etc., which consequently are generally associated with severe pain. *Abscesses* may attain a large size, containing over a pint of pus, and, unable to escape, generally extend up into the thigh or down into the leg, but may penetrate the popliteal artery or even the joint, while pus may reach the space from the pelvis by following the great sciatic nerve, or from the thigh along the femoral vessels. The popliteal fascia is perforated near the lower part of the popliteal space by the external or *short saphenous vein* which runs up from the outer side of the foot, and a lymphatic gland generally lies near this point under the deep fascia. A varicose condition of the short saphenous vein has been supposed to be due to narrowness of its opening in the deep fascia. The popliteal space is occupied, particularly in the femoral triangle, by fatty tissue in which the vessels, etc., are embedded.

The SCIATIC NERVE is the most superficial of the important structures. It divides at the upper angle of the space into internal (tibial) and external (peroneal) popliteal nerves. The *internal popliteal nerve* runs vertically downwards across the space immediately below the deep fascia, and, as the vessels run obliquely across the space, the nerve lies first to their outer and ultimately to their inner side, while at the level of the intercondyloid notch it lies directly superficial to the vessels. The *external popliteal nerve* runs along the inner

border of the biceps tendon to its insertion, under the deep fascia, and then, entering a groove between the soleus and peroneus longus, curves forward between the peroneus and neck of the fibula, 1 inch below its head.

The POPLITEAL ARTERY enters the space through the tendinous arch of the adductor magnus, and first lies on the outer border of the semimembranosus, but then, inclining outwards, reaches the middle line at the level of the intercondyloid notch, which mesial position it maintains. It is separated by a little fatty tissue from the posterior surface of the femur, and lower down is in close relationship to the posterior ligament of the joint and the fascia covering the popliteus muscle. Below the popliteal space the artery divides into anterior and posterior tibial arteries, while in the space it gives off muscular branches to the hamstrings, and two large ones (inferior sural) to the two heads of the gastrocnemius, and five *articular branches* to the knee-joint.

The two superior articular branches (external and internal) and two inferior articular branches run round to the front of the femur and tibia respectively, where they take part in an anastomosis with the descending branch of the circumflex, the *anastomotica magna*, and with the recurrent branch of the anterior tibial. Together they form three arches, one at the upper border of the patella, and the other two running transversely below the ligamentum patellæ, forming a network surrounding the patella. The fifth, the azygos branch, pierces the posterior ligament, and is distributed to the synovial membrane, crucial ligaments, etc., of the joint. It is accompanied by the geniculate branch of the obturator nerve, and an articular branch of the internal popliteal nerve. The greater part of the popliteal artery is covered by the muscles, about 1 inch in the centre being covered only by superficial tissues. When the limb is extended, the vessel is straight, but it becomes sinuous when the limb is flexed, and its flow of blood is practically stopped on acute flexion. Owing to its deep position the vessel is rarely wounded, but it has been wounded in the lower extremity of the space from the front, the instrument passing through the interosseous space, and it has been ruptured by external violence. Save for the thoracic aorta, this vessel is the one most frequently affected by *aneurism*, due probably to movement (which, when

excessive, may damage the inner and middle coats), to the laxity and small amount of support given by the surrounding tissues, and to the vessel breaking up into large branches just beyond this point. Such aneurisms may attack the bone, and give rise to joint symptoms; may press on the nerves; may impede the venous return from interference with the vein, or may point posteriorly. The vessel is best *ligatured* at the upper and inner portion of the space through an incision some 4 inches long, made parallel to and just behind the tendon of the adductor magnus, the limb being flexed, abducted, and rotated outwards. The sartorius is drawn backwards, the adductor magnus forwards, the semimembranosus backwards, and then the vein is carefully detached from the artery, and the ligature passed. The collateral circulation is abundant through the descending branch of the external circumflex with perforating of deep femoral and anastomotica magna of superficial femoral, and these again with the articular branches of the popliteal and tibial recurrents.

Emboli are particularly apt to lodge at the bifurcation of the popliteal, gangrene of the leg frequently following from blockage of the three main vessels. The *vein* possesses an unusually thick wall, and is intimately associated with the artery, lying first to its outer side, then directly behind, and, finally, to the inner side. The vein generally escapes injury from external violence, although more superficial.

The *lymphatic glands* of the space, some five in number, lie embedded in fatty tissue in close proximity to the vessels, with the exception of one already mentioned, which lies close to the fascia lata and the short saphenous vein. They receive the lymphatic channels from the sole of the foot and back of the leg—those which accompany the short saphenous vein and from the anterior tibial gland. The efferent vessels run to the deep femoral glands within the saphenous opening. Popliteal *abscess* is often due to suppuration of these glands. It also is frequently caused by osteomyelitis of the lower end of the femur, the pus coming to the surface in the region of the triangular area on the posterior surface of the shaft.

Flexion of the knee-joint from disease of the joint may in part be due to contraction of the hamstring muscles from irritation, the muscles being supplied from the fifth lumbar

segment through the great sciatic, which also supplies the joint in part. In some cases, not merely flexion, but subluxation, may be produced from drawing of the tibia backwards. On the other hand, these muscles frequently become permanently contracted in flexion of the knee, and necessitate tenotomy. In *subcutaneous tenotomy of the biceps* there is risk of wounding the external popliteal nerve, and therefore it is frequently better to do an open operation. Contraction of the muscle, or putting it on the stretch by extending the leg, increases its distance from the nerve, while rendering the tendon more superficial, and then the tenotome is introduced between the nerve and the tendon, and the latter cut by bringing the tenotome toward the skin.

There are numerous BURSÆ IN THE POPLITEAL REGION : (1) The largest is situated between the internal condyle and the inner head of the gastrocnemius and semimembranosus. In adult life it frequently communicates with the joint, and may become markedly enlarged, presenting a firm swelling on extension, which may disappear on flexion with steady pressure. Such a swelling may receive transmitted impulse from the femoral artery, and so resemble aneurism, while it frequently interferes with the movements of the joint, necessitating removal. (2) A small bursa, between the outer head of the gastrocnemius and the condyle. (3) One between the popliteus tendon and the external lateral ligament, not communicating with the joint. (4) One between the popliteus tendon and the outer tuberosity of the femur, which communicates with the joint, and frequently also communicates with the tibio-fibular articulation, which thereby may communicate with the knee-joint. (5) One between the biceps tendon and the external lateral ligament, which, when enlarged, may press on the peroneal nerve, and cause pain. (6) A small one between the semimembranosus tendon and the back of the head of the tibia, already mentioned. It does not communicate directly with the joint, but may do so indirectly through communication with (1).

THE KNEE-JOINT, the largest in the body, despite its exposed position is rarely dislocated owing to its great strength. This strength is due chiefly to the muscles, fasciæ, and ligaments, including the internal ones, and to a less degree to the lateral breadth of the articulation. The move-

ment of the knee-joint is not that of a hinge, but consists rather of a gliding of the head of the tibia on the femoral condyles, combined with rotation, outwards in extension and inwards on flexion. In full extension the limb becomes locked, and no rotation is permitted. This position tends to be assumed in standing, the weight of the body falling in front of the centre of the joint, and tending to produce over-extension. In front the quadriceps, containing the patella and ending in the ligamentum patellæ which is attached to the tubercle of the tibia, replaces the capsular ligament. Laterally also tendinous expansions from the vasti reinforce the capsule which extends laterally from either margin of the patella and patellar ligament, but is non-existent above the patella, the synovial membrane being practically in contact with the quadriceps.

The **patella** is developed in the quadriceps tendon, the ossific centre appearing about the third year, and ossification being complete by the fifteenth year. Its anterior surface is very superficial, being covered by skin, superficial and deep fasciæ, and a thin expansion of the quadriceps tendon, which has an important bearing upon fracture of the bone. The anterior surface is slightly convex, and perforated by numerous vascular foramina, the patella being richly supplied with blood from the anastomotica, anterior tibial recurrent, and inferior articular of the popliteal, and hence bleeding freely, as a rule, after fracture.

The upper margin of the bone is thick, the quadriceps being inserted into the anterior two-thirds, while a small portion behind this, which is devoid of cartilage, is covered by synovial membrane. The lateral margins and apex are narrow, the former receiving tendinous insertions from the vasti, while the apex gives insertion to the ligamentum patellæ. The tendinous insertions of the vasti, also termed lateral patellar ligaments, if not ruptured, play an important part in minimizing separation of the fragments when fracture occurs. Save for the small portion on the posterior surface of the apex which is covered by synovial membrane, the whole posterior surface of the patella is covered with articular cartilage, and is unequally divided by a vertical ridge into a small internal and large external portions, each of which is again divided into three by a couple of faint transverse ridges, while a seventh

small vertical area may be present near the inner margin. On section, both vertically and horizontally the patella is roughly triangular, and the vertical triangularity is of importance in the mechanism of fracture.

The *LIGAMENTUM PATELLÆ*, some 2 inches in length, is a continuation of the quadriceps tendon over the front of the patella, and also is attached to the apex of the bone, from

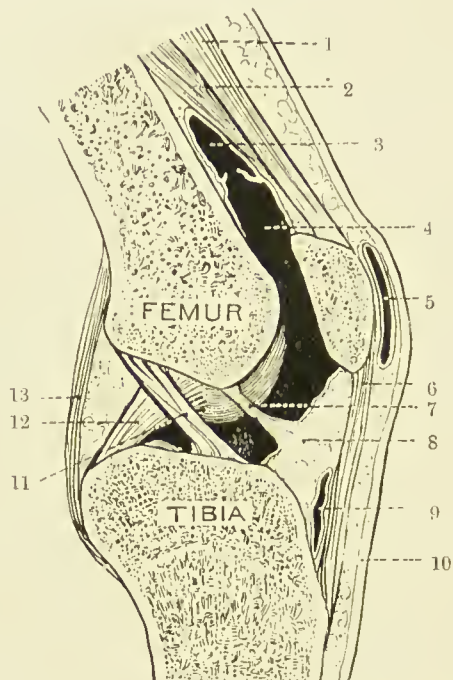


FIG 39.—SAGITTAL SECTION OF THE RIGHT KNEE-JOINT, VIEWED FROM THE OUTER SIDE. (From Buchanan's "Anatomy.")

- | | |
|--|--------------------------------------|
| 1. Crureus. | 7. Ligamentum mucosum. |
| 2. Subcrureus. | 8. Infrapatellar pad of fat. |
| 3. Suprapatellar bursa. | 9. Bursa beneath ligamentum patellæ. |
| 4. Pouch of synovial membrane of knee-joint. | 10. Skin. |
| 5. Prepatellar bursa. | 11. Anterior crucial ligament. |
| 6. Ligamentum patellæ. | 12. Posterior crucial ligament. |
| | 13. Posterior ligament. |

which it inclines downwards and slightly outwards, to be inserted into the lower part of the tubercle of the tibia, from the upper portion of which it is separated by the infrapatellar bursa, a bursa also sometimes existing between it and the skin. While the posterior surface of the patella as a whole is in communication with the joint, a small portion of the apex, together with the upper third of the ligamentum patellæ, is

separated from the joint by a pad of fat. The patella is the bone most frequently broken by muscular action, and the majority of FRACTURES OF THE PATELLA are due to *muscular action*, the fracture in such cases being *transverse*, and about the centre of the bone. The accident frequently occurs when, in trying to prevent a fall backwards, the knee is slightly flexed, and the quadriceps acts violently upon the upper extremity of the patella, while the lower is held by the ligamentum patellæ. As the patella is only resting on the prominent condyles by its transverse axis, it is snapped rather than torn apart. Unless the expansions from the vasti are also torn, the separation of the fragments is slight. Where the fracture is complete, the prepatellar bursa in front is torn, and the articular cartilage posteriorly, so that the joint cavity is opened, and communicates with the subcutaneous bursa. As the patella is a very vascular bone, a *hæmarthrosis* frequently occurs, causing much distension of the joint. Attention has already been directed to the expansion of the quadriceps tendon in front of the bone. As the snapping of the bone takes place, this expansion is stretched, and then also snaps, the torn edges being infolded over the broken ends to which they generally adhere firmly. Thus, although the broken surfaces be brought into apposition, each has a layer of fibrous tissue in front of it, and it is on this account that fibrous instead of osseous union of transverse fractures of the patella so frequently occurs. In these cases it is necessary to cut down and elevate the fibrous tissue from the broken surfaces, which will then unite by bone, even if the fragments be only held by stout catgut. The tendency to separation of the fragments is not nearly so great as used to be supposed, and the fact that hæmarthrosis frequently occurs sufficiently disposes of the other old explanation of fibrous instead of osseous union that the patella was poorly supplied with blood. Where transverse fracture of the patella occurs close to the apex, it is just possible for the joint to escape.

Oblique, or stellate, fractures of the patella may be due to direct violence; but in this connection it should be remembered that when one falls on the knee, the tubercle of the tibia, and not the patella, is the part which comes most readily in contact with the ground.

Of the LATERAL DISLOCATIONS of the patella, that outwards

is the more common, owing to the tendency of the quadriceps when contracted to pull the patella and ligamentum patellæ into a straight line, instead of following the angle formed by the femur and tibia. Normally this tendency is corrected by the prominence of the external condyle. The dislocation generally occurs when the limb is extended, is due to muscular action, and is incomplete. It is occasionally met with in cases of genu valgum. A dislocation of the patella on its edge, the inner edge projecting forwards, may also occur.

Congenital absence of the patella has occurred, and may be associated with a striking deformity, *genu recurvatum*, in which the knees bend backwards, the child standing on the calves of its legs.

Antero-laterally the capsule of the joint is strengthened, in addition to the lateral patellar ligaments, by the ilio-tibial band of fascia lata externally, and the sartorius and semimembranosus internally. Laterally it is strengthened by the *lateral ligaments*, of which the *internal* is flattened, and extends from the tuberosity of the internal condyle to the upper end of the inner border of the tibial shaft, while it is attached between the bones to the inner semilunar cartilage. It is crossed superficially by the tendons of the sartorius, gracilis and semitendinosus, a bursa intervening, while the tendon of the semimembranosus extends beneath its lower and posterior border, and still lower the inferior internal articular vessels pass under it. The *external lateral ligament* is rounded, and extends from the tuberosity of the external condyle to the head of the fibula, just in front of the styloid process. In front of it passes an expansion of the ilio-tibial band; the tendon of the biceps splits to enclose it; and the tendon of the popliteus and inferior external articular vessels pass under it. Posteriorly the capsule is more defined, extending from the upper border of the condyles and intercondylar notch to the head of the tibia. It is reinforced by an *oblique posterior ligament* (ligament of Winslow), derived from the semimembranosus tendon, extending from the inner and lower part of the joint to the outer condyle. The capsule is overlaid by the heads of the gastrocnemius, and is pierced under the inner head by the communication between the gastrocnemius bursa and the joint, and is also perforated by the azygos vessels and popliteus tendon. The internal ligaments consist

of the two *crucial ligaments*, which are attached below, in front of, and behind the tibial spine, the anterior ascending to the posterior and inner aspect of the external condyle, and the posterior to the anterior and external aspect of the internal condyle. Of these ligaments, the anterior resists extension and inward rotation, or forward displacement of the tibia.

The SEMILUNAR FIBRO-CARTILAGES, roughly triangular in section, deepen the articular surfaces on the head of the tibia, the base being turned toward the capsule to which it is attached, while the free apex projects inwards. The lower margin of the base is attached to the head of the tibia by *coronary ligaments*, and the upper and lower surfaces and free edge are covered by synovial membrane. The *external* forms almost a complete circle, being attached in front and behind to the tibial spine, while the *internal*, forming barely a semi-circle, is attached in front of and behind the spine, the two cartilages being connected anteriorly by a transverse ligament. These cartilages, and particularly the internal one, are not infrequently DISLOCATED, or broken through, by injury, especially a twist when the limb is slightly flexed, the movement in rotation being said to take place between the semilunar cartilage and the tibia. It is also said that external rotation favours displacement of the internal cartilage, and *vice versa*. As a result of the accident, the knee frequently becomes locked in a flexed position.

The *synovial membrane* lines the capsule of the joint, and is reflected at its insertions on to the epiphyses of the bones, on which it extends to the margins of the articular cartilages. It covers the semilunar cartilages and the infrapatellar pad of fat, from which latter it extends inwards and upwards to the anterior part of the intercondyloid notch, forming the *ligamentum mucosum*, and also extends inwards, and covers the crucial ligaments. The ligamentum mucosum, and the coverings of the crucial ligaments, together form an incomplete septum along the intercondyloid notch, dividing the joint into two lateral compartments. The so-called *ligamenta alaria* are delicate lateral folds, running from the ligamentum mucosum to the margins of the patella. Superiorly, under the quadriceps, the synovial membrane is not reflected at once on to the epiphysis, but extends up in front of the diaphysis, forming the suprapatellar pouch to a point fully

1 inch above the upper margin of the patella, where it frequently communicates with the subcrural bursa before it is reflected. Thus, in the extended position, a wound in the front of the femur, 2 inches above the upper border of the patella, may involve the joint. In flexion the pouch is drawn slightly downwards. The tendon of the popliteus muscle is in contact with the membrane in its intra-articular portion, and through the bursa between it and the head of the tibia the knee-joint may communicate with the superior tibio-fibular joint.

The **lower extremity of the femur** ossifies from a single centre, which appears before birth, and joins the shaft about

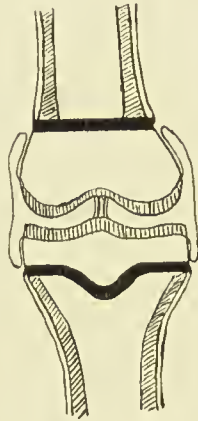


FIG. 40.—DIAGRAM OF KNEE-JOINT OF ADOLESCENT.

Shafts of bones shaded obliquely; epiphyseal plates black; articular cartilages shaded vertically.

Note that periosteum of shaft stops at epiphyseal plate to which it is firmly attached.

Note that synovial membrane commences at edge of articular cartilage and runs up over epiphysis, but is quite distinct and cut off from the periosteum; further, that it covers the crucial ligaments.

the twentieth year. The epiphyseal line is roughly horizontal, and the adductor tubercle forms a convenient guide to its position, the line running just above the tubercle. The plane of the articular surfaces of the *femoral condyles* is also horizontal when the femur is in its normal position, with the shaft extending downwards and slightly inwards. The inner condyle is the narrower, and anteriorly, above the condyles, the articular surfaces coalesce to form the trochlear surface, which is more prominent, and ascends higher, on the outer than on the inner border. Over this trochlear surface the patella

glides. When the limb is extended, the apex of the patella is just on a level with the upper surface of the tibia, and the upper margin of the patella reaches the level of the epiphyseal line. In slight flexion the patella rises slightly in reference to the head of the tibia, but in relation to the femur descends as flexion increases, till in full flexion the articular surface of the patella is opposite the intercondyloid notch. In flexion the bone is wedged against the trochlear surface, so that but little lateral movement is permitted. The lower epiphysis of the femur may be separated, or a T-shaped *fracture* involving the joint may occur, or one or other condyle may be separated.

The **head of the tibia** is also developed from a single centre, appearing shortly before birth, which joins the shaft about the twenty-second year. The epiphyseal line runs roughly horizontally, just below the tuberosities, and including the articular facet for the fibula and depression for insertion of semimembranosus tendon, while in front it dips down to include the tubercle. The head of the tibia is practically divided into two lateral articular surfaces by the spine, and extending from it forwards and backwards are two wedge-shaped rough areas, which give attachment respectively to the anterior and posterior cornua of the semilunar cartilages and the crucial ligaments. The upper third of the tibia is the part of the bone least subject to *fracture*. Either tuberosity may be broken off, or a transverse or oblique fracture of the upper third of the shaft may be associated with a vertical one running up into the joint between the tuberosities.

The **epiphyseal plates** of the long bones deserve attention surgically for several reasons. They are ill-developed in infancy, become very marked during the actively growing period up to seventeen or eighteen, and disappear later. They separate the shaft, or diaphysis, from the extremity, or epiphysis, and, as they are extremely resistant structures, they tend to confine the various affections to the part from which they originate. Thus, *tubercle* and *giant-celled sarcoma* generally affect the epiphyses, and particularly those now under consideration—the lower femoral and upper tibial. The epiphyseal plates form resistant barriers to these diseases, and are frequently successful in limiting them to the epiphyses. *Acute osteomyelitis*, on the other hand, is a pyogenic invasion of the bone-marrow of the shafts, or diaphyses, of long bones,

the infection being conveyed by the blood-stream, which most frequently affects the lower end of the femoral shaft, or upper end of the tibial shaft. The pus formed seeks an exit, and tends to invade the knee-joint, and generally succeeds in doing so in infancy and in adults. In adolescence, however, where the epiphyseal plate forms a barrier, the joint is protected, and the pus is forced to seek exit between the end of the shaft and the epiphysis, or through the Haversian canals of the shaft, causing inflammation of the bone, or *osteitis*, as it does so. Arrived on the outer surface of the shaft of the bone, it lies under the periosteum, another structure of considerable surgical importance.

The **periosteum** is a tough fibrous coat, which lines the diaphyses of long bones, which acts as a limiting membrane to the bone cells, or osteoblasts, keeping them in bounds, and which supplies the bone with blood, particularly in youth and adolescence, in addition to that supplied by the nutrient artery. Between the periosteum and the shaft is a thin layer of loose connective tissue in which numerous osteoblasts generally lie. It should be noted that the periosteum has no power of forming bone, that function belonging to the osteoblasts. In infancy the periosteum is practically continuous with the synovial membrane of the joint, while in adolescence the periosteum dips in, and becomes intimately connected with the edges of the epiphyseal plates.

To revert, then, to the progress of the pus in osteomyelitis. It spreads in the loose areolar tissue between periosteum and shaft, stripping the periosteum, cutting off the periosteal blood-supply, and frequently killing the bone in mass—*necrosis*. It also tends to invade the joint from this position, and is generally successful in infancy, owing to the connection between periosteum and synovial membrane; whereas in adolescence the periosteum, dipping in to fuse with the epiphyseal plate, protects the joint from invasion. Sooner or later the periosteum becomes involved in the pyogenic process—*periostitis*—is softened and perforated, and the pus forms a superficial abscess, which bursts. It will therefore be seen that if osteomyelitis is to be treated successfully it must be done at once, an exit being given to the pus while it is yet in the medulla of the bone, and before it has done much damage, and come to the surface.

The knee-joint is supplied with *blood* by the five articular branches of the popliteal already described, and derives its *nerve*-supply from branches of the nerves to the vasti (anterior crural) in front; from the internal and external popliteal (great sciatic) laterally and behind, and from the geniculate branch of the obturator posteriorly.

Fluid DISTENSION of the knee-joint frequently occurs as a result of *injury*, the distension in *tubercular disease* being more commonly due to masses of granulation tissue within the joint. The suprapatellar pouch becomes markedly distended, while the patella is raised from the trochlear surface on a waterbed (*floating patella*). As in the case of the hip, a position of flexion is that in which the joint accommodates most fluid, and hence a flexion of some 25 degrees is generally met with in cases of distension of the joint from acute or chronic affections, that being the position of maximum capacity. The muscles, supplied by the same nerves as the joint, aid in actively keeping the joint in this position, and *night startings*—a condition characteristic of joint affections where ulceration of cartilage has occurred to some extent—are due to the relaxation and possibly jerking of these muscles on sleep supervening, producing a jarring of the bones on one another, the delicate nerve fibrils which exist in such abundance just under the articular cartilage being crushed. As articular cartilage does not contain sensory nerve filaments, the normal joint does not give rise to acute pain on jarring, unless excessive. The flexed position if persisted in may become permanent, due to contraction of the muscles and ligaments, and also to ankylosis of the joint, while in other cases, where the joint, including the crucial and other ligaments, is disorganized by disease, a subluxation is liable to occur, the head of the tibia being drawn backwards by the contracted hamstring muscles, while slight eversion is also frequently observed, due probably to the action of the biceps.

Knock-knee, being an affection of the lower third of the femur, and not of the joint, is treated under that heading.

The knee-joint is frequently *excised* for tubercular disease, generally through a horseshoe incision from one condyle to the other, above the patella, the skin, fasciæ, quadriceps, and synovial membrane being cut through, and the joint opened. The diseased synovial tissue is removed, the lower portion of

the condyles of the femur and the head of the tibia sawn off, care being taken with regard to the latter not to remove so thick a slice as to imperil the epiphyseal cartilage, and to break rather than cut the last small portion at the back of the tibia, so as to avoid injury to the vessels, the artery lying just behind the posterior ligament. Care must also be taken that the cuts are so made as to leave the limb perfectly straight when the cut surfaces are accurately in apposition. Unlike other joints, the aim in excision of the knee is to secure broad surfaces on both bones, so as to obtain firm osseous ankylosis. While a movable joint can be obtained by excision of the knee, it has been found to be of no practical value, and generally unfit to support the weight of the body.

DISLOCATIONS of the knee-joint are rare, are generally due to great and often direct violence, and, as a rule, the joint is opened, the lateral and crucial ligaments being torn when the dislocation is complete. The tibia may be displaced in any direction, the lateral displacement being perhaps more common and less complete. Of the antero-posterior dislocations, the forward displacement of the tibia is the more common, and in this form the vessels and nerves are said to be more damaged by the femur than by the tibia in the backward form. As a matter of fact, the vessels and nerves are apt to be damaged by the severe injury which causes the dislocation, and as a rule the damage to the joint is such that the tibia may be freely moved in any direction, antero-posteriorly or laterally.

AMPUTATION at the knee-joint may be performed by various methods. In *Smith's* operation two lateral flaps are made, commencing below the tibial tuberosity, and extending downwards for fully 3 inches, that on the inner side being made the larger to accommodate the internal condyle. The flaps consist of skin and cellular tissue alone, and the condyles of the femur are not cut, a disarticulation being performed. *Carden*, *Gritti*, *Lister* and also use skin-flaps, but they remove the condyles. *Carden* makes an anterior horseshoe from one condyle to the other, crossing the centre of the ligamentum patellæ below, and joins the ends of this incision by a posterior transverse one. *Gritti* makes the same incision, but extends it to the lower border of the tibial tuberosity, and he retains the patella which he attaches, after cutting off the cartilaginous surface to the cut surface of the femur. *Lister* makes an

anterior transverse cut at the level of the tibial tuberosity, and joins the ends of the anterior by a posterior, which descends at an angle of 45 degrees to the anterior.

THE LEG—SURFACE ANATOMY.—The tibial crest running in a curved course downwards from the tibial spine forms a prominent landmark, while its internal surface being subcutaneous is easily palpated throughout its entire length. The fibula is situated distinctly behind the tibia in the greater part of its course, and its *head* is easily made out, lying a finger's breadth below the knee, with the biceps tendon inserted into it, and the external popliteal nerve lying to the inner side of the biceps tendon, and again crossing the *neck*, while the lower fourth is subcutaneous, and separates the peroneus tertius in front from the peronei longus and brevis behind. Two lines, drawn respectively from the front and back of the head of the fibula to the anterior and posterior borders of the external malleolus, give the positions of the *anterior and posterior peroneal sulci*, along which intermuscular septa are given off from the deep fascia, which pass to the anterior and external borders of the fibula. Lying between the tibial crest and the anterior peroneal sulcus are the extensor muscles, anterior tibial vessels, and nerves. Between the two peroneal sulci lie the two principal peroneal muscles and the musculo-cutaneous branch of the external popliteal nerve, whose other branch, the anterior tibial, perforates the anterior peroneal septum and extensor longus digitorum muscle to reach the extensor compartment. Between the posterior peroneal sulcus and the inner border of the tibia lie the flexor muscles and posterior tibial vessels and nerve. The long internal and short external saphenous veins can generally be made out, the former, accompanied by the long saphenous nerve, running from the front of the internal malleolus along and internal to the inner border of the tibia, while the latter, accompanied by the external saphenous nerve, runs from behind the outer malleolus along the middle of the calf to the popliteal space. The association of these veins with nerves, as likewise the association of the deep posterior tibial veins with the posterior tibial nerves, is given as a reason for the pain which so frequently accompanies varicose veins. In this connection it may be mentioned that pain referred to the leg may arise from pressure applied to the sciatic trunk or obturator intrapelvically. Thus carci-

noma recti may cause pain referred to the knee and leg. Renal calculus is said also sometimes to cause pain referred to the foot. The tibial vessels are given off at the level of the lower margin of the tubercle of the tibia. The course of the anterior tibial is indicated by a line from a point midway between the external tuberosity of the tibia and head of the fibula to the centre of the front of the ankle; that of the posterior tibial by a line from the centre of the popliteal space to a point midway between the inner malleolus and the prominence of the heel. The posterior tibial is superficial in the lower fourth of the leg, where it lies between the tibia and the tendo Achillis; it gives off the peroneal 3 inches below the knee, which vessel runs along the posterior surface of the fibula to end behind the outer malleolus.

The SKIN of the leg generally is more adherent than that of the thigh, and this is particularly the case over the superficial portions of the shafts of the tibia and fibula. A blow on the skin is apt to cut the integument upon the sharp edge of the tibial crest, and injuries and ulcers occurring in this region may readily expose or even involve the bone, old scars frequently being found adherent to the bone. The *superficial veins* of the leg lie in the subcutaneous tissue, superficial to the deep fascia, while the *deep veins* accompany the arteries under the deep fascia, each artery distal to the popliteal having a couple of *venæ comites*. Both groups, but particularly the superficial, are frequently affected by VARICOSITY, owing probably to their dependent position and vertical direction, and the consequently long column of blood they must support; the possibility of the large abdominal trunks which they ultimately enter being pressed on; and in the case of the superficial veins the comparative want of support from either deep fascia, or, more important, muscular contraction. The wearing of garters, compressing the veins against the firm, deep fascia, may also influence their occurrence. Normally the *circulation in the veins* is carried on by the *vis a tergo* of the heart, the suction action of the chest in inspiration, and muscular action, the intermittent action of the two latter being compensated by the *valves* in the interior of the veins, which prevent any backward flow. Varicosity first shows itself at these valves, frequently in situations where deep and superficial veins communicate, by a series of dilatations.

Following the dilatation, the valves become incompetent, engorgement follows, and the vein stretches and becomes tortuous, while the surrounding skin, suffering from the defective circulation, frequently becomes pigmented, and is prone to ulceration. In some cases the trunk of the internal saphenous (or more rarely the external saphenous) is alone affected, the dilatation extending up to the saphenous opening ; in others the dilatation is general. The DEEP FASCIA of the leg, continuous with that of the thigh, invests the whole limb, save where the bones are subcutaneous, where it is interrupted and attached to the bony margins on either side of the subcutaneous portion. It is also attached to the head of the fibula. It is thicker in front than behind, particularly just below the knee, and it is strengthened below at the annular ligaments. Its peroneal septa have already been described.

In the COMPARTMENT between the tibial crest and the anterior septa are the tibialis anticus and extensor communis digitorum, extensor longus hallucis and peroneus tertius muscles, anterior tibial vessels and nerve, and anterior branch of the peroneal artery. At the upper end of the compartment the two first-named muscles lie together, and are said to be separated from one another by a septum, which is the guide to the underlying vessels. As a matter of fact, the position of the septum has generally to be guessed, and then on separating the muscles the ANTERIOR TIBIAL ARTERY, with its venæ comites, is found lying on the interosseous membrane. Toward its lower extremity the compartment narrows, and the relation of the muscles alters, the extensor hallucis intervening between the border of the tibialis anticus and the extensor digitorum, the *artery* therefore below the middle of the leg being sought on the interosseous membrane or anterior surface of the shaft of the tibia between the tibialis anticus and external hallucis. At the ankle the *artery* is crossed by the tendon of the extensor hallucis, and lies superficially between it and the extensor digitorum. It is continuous with the dorsalis pedis of the foot. Its most important branch is probably the anterior tibial recurrent already mentioned. After ligature of the anterior tibial, the *collateral circulation* is kept up by the external malleolar of the anterior tibial with the peroneals; the internal malleolar of anterior tibial with posterior tibial; and the dorsalis pedis and plantar with peroneals.

The peroneus tertius, arising from the lower third of the fibula on its inner aspect, sends its tendon down on the outer side of that of the extensor digitorum. The branch of the peroneal artery enters the space just above the inferior tibio-fibular joint. The *anterior tibial nerve* lies external to the artery, but may be reached through the same incisions. In the upper third the nerve is a little distance from the artery, but is close to it in the lower two-thirds, and may even overlap it in the middle third.

The PERONEAL COMPARTMENT between the two septa contains the peroneus longus and brevis, the musculo-cutaneous

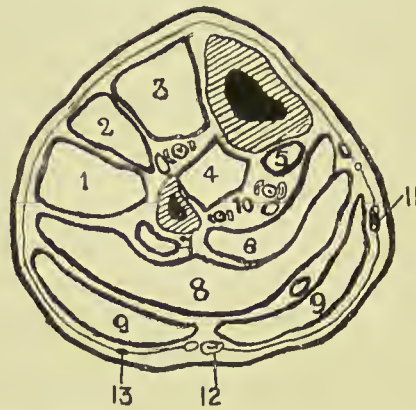


FIG. 41.—OUTLINE DIAGRAM OF TRANSVERSE SECTION OF LEG IN THE UPPER THIRD.

(Modified from Heath.)

- | | |
|--|--|
| 1. Peroneus long. | 7. Flex. long. pollicis. |
| 2. Ext. long. dig. | 9. Gastrocnem. (plantaris tendon above figure on right side). |
| 3. Tibialis anticus. | 10. Peroneal vessels on left. Post. tibial vessels and nerve on right. |
| Ant. tibial vessels and nerve between 3 and 4. | 11. Int. saphenous vein. |
| 4. Tibialis posticus. | 12. Ext. saphenous vein and nerve. |
| 5. Flex. long. dig. | 13. Communicans peronei nerve. |
| 6 and 8. Soleus. | |

nerve, and at its upper end the termination of the external popliteal nerve. Both peronei muscles arise from the outer surface of the fibula, the longus from the upper two-thirds, and the brevis from the middle two-fourths. The musculo-cutaneous nerve of the external popliteal lies on the inner surface of the peronei which it supplies, and between them and the extensor digitorum.

The POSTERIOR COMPARTMENT between the external peroneal septum and the inner border of the tibia is wide above, but

diminishes as it approaches the ankle. It contains a superficial group of muscles, the gastrocnemius, soleus, and plantaris, which are separated from the deep group, consisting of the flexor longus digitorum, flexor longus hallucis, and tibialis posticus by an intermuscular septum running from the fibula to the tibia. The posterior tibial vessels and nerve, and the peroneal vessels, lie in the deep compartment, superficial to the deep muscles. The *gastrocnemius* rapidly narrows, and becomes tendinous about the middle of the leg, the *soleus* remaining fleshy to a lower level. The tendons of the two muscles coalesce to form the TENDO ACHILLIS, which is inserted into the posterior part of the os calcis, and is an important landmark. The long thin tendon of the *plantaris* runs down from without inwards between these two muscles, and is inserted into the os calcis on the inner side of the tendo Achillis.

The tendo Achillis is not infrequently *ruptured* by some unwonted exertion, and the plantaris tendon has been similarly injured, while the gastrocnemius muscle has also been partially torn.

The POSTERIOR TIBIAL ARTERY, accompanied by its venæ comites, lies between the superficial and deep muscles on the under surface of the deep intermuscular septum, just over the tibialis posticus. The *posterior tibial nerve* lies at first to the inside of the artery, but about $1\frac{1}{2}$ inches below the popliteus muscle it crosses behind the artery to the outer side. The vessel is deeply placed in its upper two-thirds, and is best reached about the middle of the leg, through an *incision* on a line from the inner tuberosity of the tibia to a point midway between the internal malleolus and the heel, the patient lying on the back, with the limb everted. The skin and superficial fascia are incised, avoiding the internal saphenous vein and nerve; then the deep fascia is cut through, and the gastrocnemius drawn backwards and the soleus exposed. The soleus is now divided vertically in the line of the incision, until the vessel is reached lying under the deep fascia. This portion of the operation is difficult, the incision being apt to follow the fibres of the soleus, instead of going vertically through them, while a tendinous intersection in the substance of the soleus is apt to be mistaken for the deep aponeurosis. The tibial margin forms a good guide, the incision being deepened at a uniform

distance from it (less than a finger's breadth), until the vessel is reached. *In the lower one-third* the vessel is comparatively superficial, and lies midway between the inner margin of the tibia and the tendo Achillis. To reach it, an incision in the line of the artery is made through the skin, superficial fascia, deep fascia, and deep fascia covering the deep flexors. The artery lies on the flexor longus digitorum.

The *collateral circulation* is by calcaneal branches of external plantar with the peroneals and external malleolar of anterior tibial, plantar arteries with dorsalis pedis, internal malleolar of anterior tibial with posterior tibial, and muscular branches of peroneal and posterior tibial.

Aneurism of the posterior tibial is said to be more apt to cause gangrene of the leg than popliteal aneurism, as it presses upon the anterior tibial recurrent, which plays an important part in collateral circulation.

In the upper portion of the leg the deep posterior muscles are arranged with the tibialis posticus placed centrally, springing from the interosseous membrane and tibia and fibula, while the flexor hallucis, springing from the fibula, lies to the outer side, and the flexor digitorum, springing from the tibia, lies to the inner side. Near the ankle the tendon of the tibialis posticus passes under that of the flexor digitorum, and is thus above, or anterior to, the others. Next to it comes the flexor digitorum tendon, then the artery and its venæ comites, then the nerve, and finally the flexor hallucis lies lowest, or most posterior.

The *peroneal artery*, arising about 1 inch below the end of the popliteal, inclines out to the posterior surface of the fibula, and descends in or beneath the flexor longus hallucis, close to the interosseous membrane. Just above the ankle it divides into anterior and posterior peroneal arteries, of which the *anterior* enters the anterior compartment, through the interosseous membrane, to anastomose with branches of the anterior tibial, and the *posterior* descends posteriorly to anastomose with the anterior malleolar and tarsal vessels. The peroneal also supplies muscular branches, and the nutrient artery to the fibula. While all the vessels of the lower limb are apt to be *injured* in fracture, the peroneal is particularly so, owing to its close relationship to the fibula and its comparative fixation.

BONES OF THE LEG.—It should be remembered that the **tibia** alone articulates with the femur, and therefore bears the whole weight of the body, while the fibula supplements it, particularly in resisting lateral and torsion forces, and assists in forming the ankle-joint by the external malleolus. The tibia is thickest in front, in the region of the crest, and about the centre of the bone. The narrowest part is at the junction of the middle and lower thirds, measuring about 1 inch in transverse diameter, while the average diameter is $1\frac{3}{4}$ inches, and farther, at this point, internally, two columns of spongy matter, one occupying the upper two-thirds, and the other the lower one-third, meet, and thus this point is the weakest, and it is here that fractures of the tibia from indirect violence generally occur.

FRACTURE of the tibia alone is generally due to direct violence, affects the lower one-third most frequently, and when transverse often presents no displacement, the fibula acting as a splint, and occasionally enabling the patient to walk.

The *nutrient foramen* of the tibia is the largest in the body, and enters the posterior surface of the bone in its upper third, whence it is directed downwards in the compact shaft for about 2 inches before entering the medulla. The shaft of the tibia is very frequently affected by acute *osteomyelitis*, which, if it succeeds in plugging the nutrient artery, in addition to stripping the periosteum, may cause death of the shaft from cutting off the blood-supply. In *operating* on the tibia for osteomyelitis the disease is easily attacked through the superficial broad internal aspect. The shaft of the tibia is also a frequent seat of *syphilitic nodes*, a chronic periostitis being set up, which results in the formation of a characteristic spindle-shaped osseous node. In some cases gummatous changes take place, the skin breaks down, and deep ulcers form, while the bone may become softened and bend.

Rickets attacks the tibia and also the fibula at an early stage, various deformities being produced. Perhaps the most common is a curve, with the convexity directed forwards, and inwards or outwards, occurring about the junction of middle and lower third, the malleolus touching the ground in severe cases. A general curving of the tibia, with the convexity

outwards, occurs frequently in *genu varum*, and almost the whole deformity in some of these cases lies in the tibia, and not in the femur. A *cuneiform osteotomy* is generally performed to rectify the more acute tibial curves, a wedge being removed from the convexity of the curve. The lower epiphysis of the tibia, which includes the malleolus and the fibular facet, may be separated by *injury*. It unites with the shaft about the eighteenth year. The malleolus may be broken by violence, and its tip is frequently torn off in Pott's fracture of the fibula.

The shaft of the **fibula** is narrow, but strong, compact, and somewhat elastic, presenting several sharp projecting ridges, which act as flanges, and give the bone in section a shape not altogether unlike that of a girder. As in addition the bone is covered by muscles, it is not often broken alone, despite its exposed position, save in its lower one-fourth. The fracture which occurs in that position is due to indirect violence, is called *Pott's fracture*, and is one of the most frequent and important fractures in the body. As it is associated with dislocation of the ankle, it will be considered under that region. Other fractures of the fibula alone are generally due to direct violence, are transverse, and, the tibia acting as a splint, produce little or no displacement. Where *both bones are broken* by indirect violence, the tibia breaks about the junction of the middle and lower one-third, the line of fracture running obliquely downwards, forwards, and inwards, while the fibula breaks higher up. This fracture is very apt to become *compound*, not only because the crest of the tibia is sharp and very superficial, but because both the lower end of the upper fragment tends to project forwards, and also the upper end of the lower fragment, being tilted by the tendo Achillis pulling the heel backwards and upwards. The weight of the foot also assists in producing this displacement of the lower fragment, and in addition it generally produces slight eversion. The superficial position of the tibia also favours comminution in fractures by direct violence.

A SPIRAL FRACTURE of the tibia, due to torsion, sometimes occurs at the junction of the middle and lower third, running obliquely down and inwards, the upper fragment presenting a V-shaped extremity (Gosselin), while in some cases there is in addition a vertical fracture, extending down through the

lower fragment to the ankle, and the fibula may break at a higher level.

AMPUTATION of the leg used to be performed at a point a hand's breadth beneath the knee-joint (*seat of election*), the stump left by this operation being short, and enabling the patient to walk by kneeling on a pin-leg. Nowadays, speaking generally, the stump should be left as long as possible, the forms of amputation used being adapted to circumstances. Amputation at the seat of election, or middle third, may be performed by long anterior and short posterior flaps, or by a single large external flap, which may be made to contain the anterior tibial artery (*Farabæuf*). Amputation in the middle or lower third may be done by a large posterior flap; and *Teale's* amputation, in which a long anterior flap, four times the length of the posterior, is taken, and then turned over on itself, so that the scar is quite away from the apex of the stump, may be performed in the lower third. It is generally well to bevel the cut end of the tibia so as to remove the sharp tip of the crest, and in amputations at the upper extremity of the leg some recommend the removal of the upper end of the fibula. Owing to the fibula lying behind the plane of the tibia, it is sometimes possible in amputating to run the knife from within outwards behind the tibia, but between it and the fibula, and so get it jammed.

THE ANKLE AND FOOT—SURFACE ANATOMY.—The malleoli form prominent landmarks, the tip of the external malleolus being about $\frac{1}{2}$ inch below and behind that of the internal, while, owing to the greater breadth of the latter, their posterior borders are on a level with one another. In front of the external malleolus and external to the tendon of the peroneus tertius, and between the internal malleolus and tendon of the tibialis anticus, are shallow depressions, which denote the position of the ankle-joint. These depressions are replaced by swellings, when the joint becomes distended. The joint line lies about $\frac{1}{2}$ inch above the tip of the internal malleolus. Less than 1 inch below and in front of the external malleolus lies the peroneal spine of the os calcis, with the peroneus brevis above and the peroneus longus below it, while less than 1 inch below the internal malleolus is the sustentaculum tali of the os calcis, into which the recurrent slip of the tibialis posticus is inserted, while the flexor longus digitorum

and flexor longus hallucis occupy the underlying groove. The tubercle of the scaphoid, which receives the chief insertion of the tibialis posticus, lies about 1 inch in front of the internal malleolus; and over 2 inches in front of the external malleolus is the projecting base of the fifth metatarsal, with the cuboid behind it. The mid-tarsal joint, that between calcaneum and cuboid and between the astragalus and scaphoid, lies internally just behind the tubercle of the scaphoid, and externally just in front of the midpoint between the external malleolus and the base of the fifth metatarsal. When the foot is extended, the astragalus forms a prominence most marked in front of the external malleolus, and below, in front, and a little to the outside of this prominence is a depression, which lodges the outer end of the astragalo-calcaneal ligament, and still farther in front is a slight prominence, due to the anterior tuberosity of the os calcis, which articulates with the cuboid in front. The tendons lying in front of the ankle are best seen when the foot is extended, and consist from within outwards of tibialis anticus, extensor longus hallucis, extensor longus digitorum, and peroneus tertius, while on the outer aspect of the dorsum the belly of the extensor brevis digitorum can be felt.

The *sole of the foot* presents a triangular outline, and only a comparatively small portion of it comes normally in contact with the ground. The parts which touch the ground are the heel, external border of the foot, and ball of the great toe. The foot is arched antero-posteriorly, and also transversely.

The *antero-posterior arch* is formed by bony pillars—os calcis and astragalus posteriorly, and the anterior tarsus and metatarsus anteriorly—and is maintained by the plantar fascia, the plantar and inferior calcaneo-scaphoid ligaments, and tendons of the peronei, tibiales, flexores longus digitorum and hallucis.

The *transverse arch* is formed by the wedge shape of the middle and external cuneiform bones, and second, third, and fourth metatarsals, and is supported by the peroneus longus tendon and short ligaments of the part. In the front of the foot the whole of the first metatarsal and its sesamoid bones can be fairly made out. It articulates behind with the internal cuneiform. The metatarso-phalangeal articulations are about 1 inch behind the webs of the toes. *Posteriorly*

the tendo Achillis forms a prominent landmark. The depression to its outer side lodges the tendons of the peronei longus and brevis, the latter lying anteriorly and more deeply, in contact with the fibula, while that on its inner side is continuous with the groove under the sustentaculum tali, in which are lodged the tibialis posticus (next the tibia), then the flexor longus hallucis, the posterior tibial artery and venæ comites, posterior tibial nerve and flexor longus pollicis. As these latter tendons, with the vessels and nerve, lie well in front of the tendo Achillis, they run little risk of being wounded in a tenotomy of the latter. A bursa separates the lower portion of the tendo Achillis from the os calcis, and when inflamed this bursa may cause swelling and pain suggestive of an affection of the ankle-joint, and may even lead to disease of the os calcis. *Tenotomy* of the tendo Achillis is performed by introducing a blunt-pointed tenotome between the skin and the tendon through a puncture made in the skin, while the foot is kept extended so as to relax the tendon. Then the edge of the tenotome having been turned against the tendon, the foot is forcibly flexed, thereby rendering the tendon tense, and dividing it against the blade, a considerable gap existing subsequently.

The *dorsalis pedis artery* runs from the middle of the ankle-joint to the space between the bases of the first two metatarsals lying to the outer side of the extensor longus hallucis tendon. Starting from a point midway between the tip of the internal malleolus and the heel, the *plantar arteries* run—the internal to the middle of the under surface of the great toe, the external to a point about 1 inch from the base of the fifth metatarsal, whence it turns inwards.

The SKIN over the ankle and dorsum of the foot is thin and freely movable, and is readily damaged from pressure on the subjacent parts. On the sole of the foot the parts which come in contact with the ground are thick and fairly adherent to the dense subcutaneous tissue, while the remainder of the skin of the sole is thin, smooth, and sensitive, and well supplied with sweat-glands. In some respects the skin and subcutaneous tissue of the sole resembles that of the palm; it does not tend to retract when cut; and foreign bodies, such as broken needles, when embedded in it, are frequently difficult to find, while abscesses remain localized, and cause much pain.

The SUBCUTANEOUS TISSUE is lax over the ankle and dorsum, and is frequently the part first affected in dropsy; is abundant and fatty around the tendo Achillis, and thick, dense, and fibrous over the *heel* (where it may be $\frac{3}{4}$ inch thick), and over the parts which come in contact with the ground. This thick pad forms an excellent cushion, and, combined with the elasticity of the arches of the foot, prevents jarring in walking.

The *superficial veins* are most numerous on the dorsum, where they form a plexus, particularly about the internal

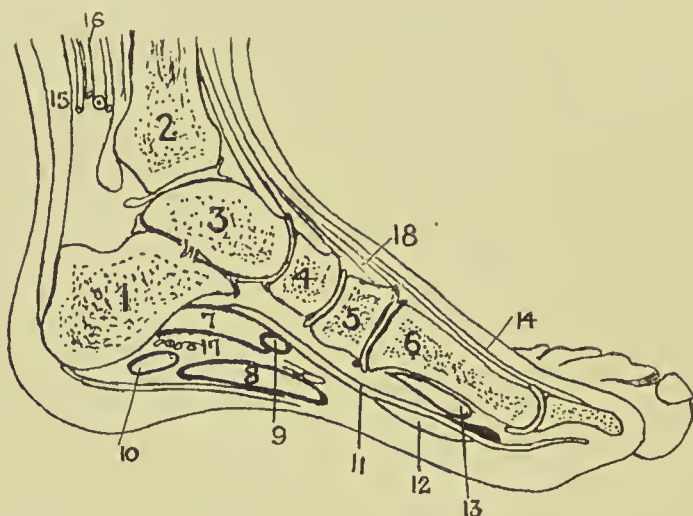


FIG. 42.—OUTLINE DIAGRAM OF LONGITUDINAL SECTION OF FOOT.
(After Braune.)

- | | | |
|----------------------|---------------------------|-------------------------------------|
| 1. Os calcis. | 7. Flex. accessorius. | 13. Flex. brev. hallucis. |
| 2. Tibia. | 8. Flex. brev. dig. | 14. Ext. long. hallucis. |
| 3. Astragalus. | 9. Flex. comun. dig. | 15. Tendo Achillis. |
| 4. Scaphoid. | 10. Adduct. min. dig. | 16. Post. tibial vessels and nerve. |
| 5. Int. cuneiform. | 11. Flex. long. hallucis. | 17. Ext. plantar vessels and nerve. |
| 6. First metatarsal. | 12. Accessorius. | 18. Tibial. antic. |

malleolus, while the parts of the sole which touch the ground are comparatively free from them. Over the instep there are numerous veins, which frequently dilate in varicosity of the limb. On the dorsum the veins form an arch, from the extremities of which the saphenous veins arise.

The *lymphatics* of the foot form a fine plexus, the chief vessels being situated on the dorsum, and particularly on the inner side, whence they ascend near the internal saphenous vein to the inguinal lymphatic glands. A few of the external lymphatics follow the short saphenous vein to the popliteal

glands, but the majority cross the leg, particularly behind and above the knee, to join the inner set, a few crossing in front over the tibia. Thus, *septic wounds* of the inner side of the foot will probably affect the inguinal glands, while those of the outer side may affect either the popliteal or inguinal set. The skin of the foot derives *sensation* from branches of the anterior tibial, two saphenous, external and internal plantar and musculo-cutaneous nerves. Pacinian bodies and end bulbs are found on their terminations, and while tactile sensation is not acute, the sensations of pain, pressure, and temperature are, and tickling is particularly sharply felt. The skin of the dorsum, however, is much less sensitive than that of the sole. Reference has already been made to pain referred to the foot from bowel and other distant affections. *Perforating ulcer* of the foot is believed to be due to a neurosis, is frequently met with in locomotor ataxy, rarely in diabetes, and generally affects the ball of the great toe, and less frequently the heel.

On the dorsum the FASCIA is divided into superficial and deep layers, both of which are poorly developed, and of little importance. The superficial layer is continuous with the anterior annular ligament, and the deep layer covers in the extensor brevis and interossei. The PLANTAR FASCIA, on the other hand, consists of a strong central portion, running forward from the tuberosity of the os calcis, to divide into five slips to the bases of the toes, and two lateral portions, which are much less well developed, and join the dorsal fascia. The portion on the outer side forms a stout band, the *calcaneo-metatarsal ligament* between the tuberosity of the os calcis and the base of the fifth metatarsal. An intermuscular septum passes up on either side of the flexor brevis digitorum, separating it from the abductors of the great and little toes. The plantar fascia helps to support the arch of the foot, and in *talipes cavus*, where the foot is greatly arched, the central band may be strongly contracted, necessitating section before the condition can be remedied. Such *section* is best performed about 1 inch in front of the attachment to the os calcis, where the fascia is narrowed, the scalpel being introduced from the inner side. The density of the plantar fascia tends to prevent the pointing of deep *abscesses* in the sole, although occasionally such an abscess may present through a small aperture in the fascia normally occupied by fat, and then spread subcu-

taneously and point. Generally such abscesses become large, cause considerable destruction of tissue and pain, and finally point on the dorsum or about the ankle. At the ankle the deep fascia is strengthened, and forms the ANNULAR LIGAMENTS—*anterior*, *internal*, and *external*. The *anterior* is in two portions—an upper running between the malleoli, which binds down the tendons of the tibialis anticus and extensors of the toes, the former surrounded by a synovial sheath, and a lower attached externally to the os calcis, and then extending inwards across the dorsum and splitting into two portions, the upper inserted into the internal malleolus, and the lower to the plantar fascia. Under this lower portion are three synovial sheaths—an inner for the tibialis anticus, a middle for the extensor proprius hallucis, and an outer for the extensor communis and peroneus tertius. The *internal* annular ligament extends from the internal malleolus to the tuberosity of the os calcis. Under it pass the tibialis posticus, flexor longus digitorum, and flexor longus hallucis (each enclosed in a separate synovial sheath, that for the tibialis posticus being closely related to the joint), together with the posterior tibial vessels and nerve. The *external* ligament stretches from the external malleolus to the os calcis. Under it pass the peronei longus and brevis in a single synovial sheath. In addition to partial rupture of the ligaments, *sprains* of the ankle are frequently associated with damage to the synovial sheaths, causing long-standing trouble.

Rupture of the tendo Achillis has already been referred to. The *tendons* of the tibialis posticus, and long and short peronei, may also be ruptured by violence, and in some cases their sheaths may also be torn, allowing of displacement of the tendons, which may appear in front of the malleoli. The peroneus longus tendon is said to be more frequently displaced than any other in the body. The tibialis anticus tendon may be *tenotomized* below and in front of the ankle, as it crosses the scaphoid bone, the tenotome being introduced beneath it from without inwards. The tibialis posticus may be similarly treated, either just above the internal malleolus, where it is subcutaneous, or between the internal malleolus and tuberosity of the scaphoid. As these tendons run in sheaths, their section is generally undesirable, the cut ends tending to adhere to the synovial sheath, and movement thereby being much im-

paired. Their section in cases of talipes equino-varus is generally not only useless, but harmful.

The anterior tibial artery is crossed at the ankle by the tendon of the extensor hallucis, and then lies between it

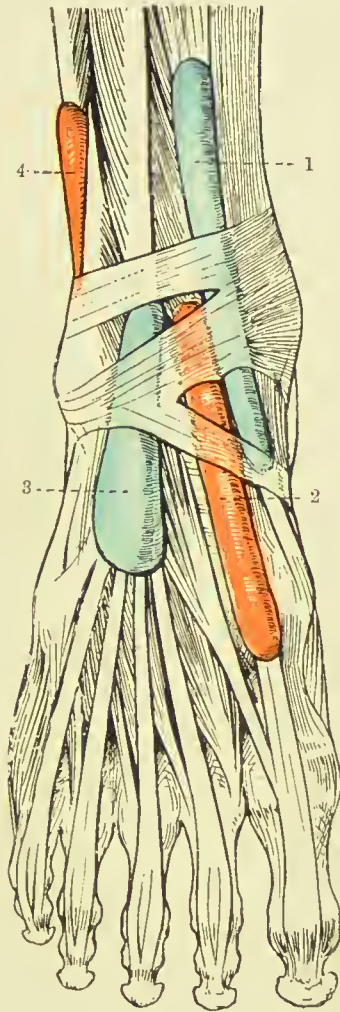


FIG. 43.—THE SYNOVIAL SHEATHS AT THE ANKLE. ANTERIOR VIEW.

(After L. Testut's "Anatomie Humaine.")

- | | |
|--------------------------------|-------------------------------|
| 1. Tibialis anticus. | 3. Extensor longus digitorum. |
| 2. Extensor proprius hallucis. | 4. Peroneus longus et brevis. |

and that of the extensor digitorum, being continued into the foot as the DORSALIS PEDIS. This vessel lies in a *line* from the centre of the front of the ankle to the posterior

extremity of the first interosseous space, being accompanied on its outer side by the anterior tibial nerve and lying between the extensor longus hallucis on its inner side, and the innermost tendon of the extensor digitorum on its outer side. The vessel, lying as it does superficially and close to the bones of the foot, is frequently divided and ruptured in wounds and injuries, and its *ligature* presents little difficulty, save in the cadaver, where a slightly more superficial vein is frequently mistaken for the artery.

The POSTERIOR TIBIAL ARTERY may be ligatured at the ankle through a curved incision a finger's breadth below the

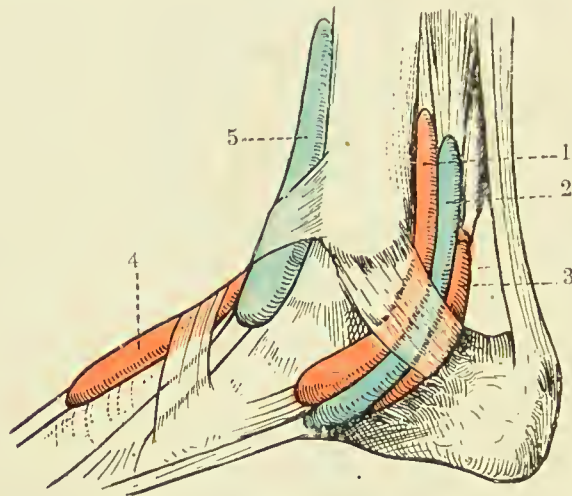


FIG. 44.—THE SYNOVIAL SHEATHS AT THE ANKLE. INTERNAL VIEW.

(After L. Testut's "Anatomie Humaine.")

- | | |
|-----------------------------|-------------------------------|
| 1. Tibialis posticus. | 4. Extensor proprius hallucis |
| 2. Flexor longus digitorum. | 5. Tibialis anticus. |
| 3. Flexor longus hallucis. | |

internal malleolus. At the lower border of the internal annular ligament it divides into internal and external plantar arteries, and sends calcaneal branches to the heel. (The anterior and posterior branches of the peroneal artery descend to the ankle, and anastomose with the branches of the anterior and posterior tibials.) The *internal plantar artery*, the smaller of the two, runs forward between the abductor hallucis and flexor brevis digitorum to the head of the first metatarsal bone, while the *external plantar* runs forwards and outwards between the flexor brevis digitorum and abductor minimi digiti to the

base of the fifth metatarsal, where it turns abruptly inwards to form the *plantar arch*, which crosses the bases of the metatarsals to the outer side of the base of the first metatarsal to anastomose with the *dorsalis pedis*. The *course* of the internal plantar is represented by a line from a point midway between the internal malleolus and prominence of the heel to the middle of the under surface of the great toe; the external runs from the same point to within $\frac{1}{2}$ inch of the base of the fifth metatarsal. *Wounds* of the plantar arch are troublesome, not only because it lies deeply and might necessitate damage to tendons and nerves to reach it, but because of the free anastomoses between the anterior and posterior tibial and peroneal arteries. It has been suggested to reach the vessel from the dorsum by removal of portions of one or more metatarsal bones, but hæmorrhage can often be arrested by pressure on the inner vessels, with firm local pressure and elevation of the limb.

THE ANKLE-JOINT.—The lower ends of the tibia and fibula are firmly bound together by a series of ligaments, while the malleoli project beyond and form a socket into which the upper and external surfaces of the astragalus fit.

The **LIGAMENTS** which hold the bones together are anterior and posterior inferior tibio-fibular ligaments; an interosseous ligament, which is continuous above with the interosseous membrane, and below comes into association with the joint cavity; and a transverse ligament, which stretches posteriorly from the internal malleolus to the inner aspect of the posterior border of the external malleolus. Sometimes there is an actual *joint* between the two bones, lined with articular cartilage, and the synovial membrane of the ankle-joint extends up between the bones. The ligaments of the ankle-joint form a continuous investment of very varying strength. The *anterior ligament* is a weak structure, attached above to the lower border of the tibia and to the malleoli, and below to the neck of the astragalus; and the *posterior ligament*, also weak, extends from the posterior surface of the tibia to the astragalus, and is strengthened by the *transverse* ligament already described. *Effusions* of fluid into the ankle-joint generally show first in front, beneath the extensor tendons, owing to the weakness of the anterior ligament and looseness of the synovial membrane at that point, and if increased cause bulgings of the

posterior ligament, which show as fulness, with fluctuation on either side in front of the tendo Achillis. The *lateral ligaments* are very powerful, particularly the *internal*, which is triangular in shape, the apex being attached above to the internal malleolus, and the base to the scaphoid in front, then the inferior calcaneo-scaphoid ligament and neck of the astragalus, and behind to the sustentaculum tali and inner surface of the astragalus. It is covered by the tendons of the tibialis posticus and flexor longus digitorum. The *external lateral ligament* consists of three fasciculi all arising from the external malleolus, of which the anterior extends to the astragalus, the middle to the os calcis (being covered by the tendons of the peronei), and the posterior to the posterior aspect of the astragalus, being attached to a small tubercle of bone, which is occasionally distinct from the astragalus (*os trigonum*).

The SYNOVIAL MEMBRANE lines the capsule, is lax anteriorly and posteriorly, where it covers pads of fat, and is directly continuous with the inferior tibio-fibular joint, when it exists. The joint is supplied by branches of the anterior tibial and internal saphenous *nerves*, the former associating it with the sacral segments of the cord, and the latter with the lumbar. The ankle-joint only permits of flexion and extension, save in extreme extension, when very slight lateral movement is just possible, owing to the narrow posterior portion of the astragalus coming in contact with the wider anterior portion of the tibio-fibular cavity. Flexion is limited by the posterior ligament and posterior portions of the lateral ligaments, and by contact of the astragalus with the tibia. Extension is limited by the anterior ligament and anterior portions of the lateral ligaments, and by contact of the astragalus with the tibia. Lateral movements of the foot round an antero-posterior axis take place normally between the astragalus and the os calcis, while those round a vertical axis take place at the midtarsal joint. The position of greatest ease of the joint is that of slight extension, although the capacity is not affected by position.

SPRAINS of the ankle frequently occur, a forced movement of the foot producing partial tearing of one or other lateral ligament. Sometimes the ligaments withstand the strain, and a portion of one of the malleoli is torn off by it, the condition being called a *sprain fracture*.

DISLOCATIONS of the ankle are generally associated with fracture, and are due to indirect violence applied to the foot. Sometimes, as a result of injury, one of the malleoli may alone be broken, no dislocation resulting. The ankle may be dislocated laterally, antero-posteriorly, or upwards. The *outward lateral displacement* is by far the most common, and is associated with a fracture of the fibula some 2 or 3 inches from its lower end, the condition being known as **Pott's fracture**. Pott's fracture is caused by a violent eversion of the foot, such as is produced by stepping sidewise from a machine in motion, the internal lateral ligament tearing and the astragalus being rotated, and so brought violently against the external malleolus. * As the ligaments binding the fibula to the tibia remain intact, this portion acts as a fulcrum, and, the malleolus being forcibly everted, the lower end of the shaft of the fibula is forcibly inverted, and finally snaps some 3 inches up. Frequently the tip of the internal malleolus is torn off instead of the internal lateral ligament giving way. After the injury the foot is displaced markedly outwards and everted, and there is also a tendency to backward drooping of the heel when the patient is recumbent. *Dupuytren's fracture* is a somewhat similar condition, which, however, is rare, and only produced by extreme violence. In it, while the fracture of the fibula remains the same, the tibio-fibular articulation gives way, and the everted astragalus is forced up between the two bones, or the lower fragment of the fibula accompanies the astragalus upwards. A *simple dislocation* of the astragalus upwards between the tibia and fibula without fracture, but with laceration of the tibio-fibular ligaments, rarely occurs, generally from a fall on the feet. Complete inward dislocation of the ankle is rare, is generally caused by a severe twist, and is said to be accompanied by fracture of the external malleolus, and often of the internal malleolus, and even of the astragalus. Complete inward dislocation has occurred, however, without fracture of any part. Antero-posterior dislocations of the astragalus are less common, and are caused by violence with the foot fixed as in jumping from a moving vehicle in the line of its motion. Of the two forms, backward dislocation of the astragalus is much the more common, the articular surface of the tibia resting on the scaphoid and cuneiform bones, and all the ligaments suffering, particularly the anterior and

posterior. Here also the fibula may be fractured, and one or both malleoli may be detached.

The Tarsus.—THREE SETS OF JOINTS exist in the tarsus: (1) Between astragalus and os calcis (posterior). (2) (a) Between astragalus and scaphoid, (b) between os calcis and cuboid. These two together constitute the *midtarsal joint*. (3) (a) Between scaphoid and three cuneiforms, (b) between the cuneiforms, (c) between external cuneiform and cuboid.

1. This consists of two parts, entirely separated by the strong astragalo-calcaneal ligament which unites the two bones. The anterior portion is continuous with the joint between the head of the astragalus and the scaphoid. Comparatively weak peripheral ligaments (external, internal, and posterior) also help to unite the two bones, which are further strengthened by the lateral ligaments of the ankle and various tendons. The articulation permits of adduction with slight rotation inwards, and abduction with slight rotation outwards.

2. (a) This articulation is continuous with the last, and is of the ball and socket variety. The lower aspect of the head of the astragalus is supported by the inferior calcaneo-scaphoid ligament, which is a powerful band of triangular shape, running from the sustentaculum tali to the under surface of the scaphoid, and which again is supported on its under surface by the tendon of the tibialis posticus. There is also an external calcaneo-scaphoid and an astragalo-scaphoid ligament, the latter situated on the upper, or dorsal, surface of the articulation. (b) Each bone presents a concavo-convex surface mutually adapted to one another. The joint is supported by an internal calcaneo-cuboid ligament, which springs from the os calcis, together with an external calcaneo-scaphoid ligament, the two diverging in the form of the letter V, to be inserted into the scaphoid and cuboid respectively. There are also external and dorsal calcaneo-cuboid ligaments, while below are situated the inferior calcaneo-cuboid, or plantar, ligaments. The *short plantar ligament* is more deeply placed, and extends from the anterior tubercle on the inferior surface of the os calcis to the proximal part of the under surface of the cuboid. The *long plantar ligament* covers the short, and is separated from it by some fatty tissue. It extends from the posterior tuberosities of the os calcis along its whole inferior surface to the ridge on the under surface of the cuboid,

immediately behind the peroneal groove, some fibres being continued over the groove to the bases of the second, third, and fourth metatarsals. The long plantar is a powerful ligament, and together with the *short plantar* and *inferior calcaneo-scaphoid ligaments* plays an important part in maintaining the arch of the foot. The midtarsal joint permits of flexion and extension and rotation on an antero-posterior axis, the movement in the astragaloid section being freer than that in the calcaneal.

3. These joints are supplied with dorsal, interosseous, and strong plantar ligaments, the latter being reinforced by slips from the tibialis posticus tendon.

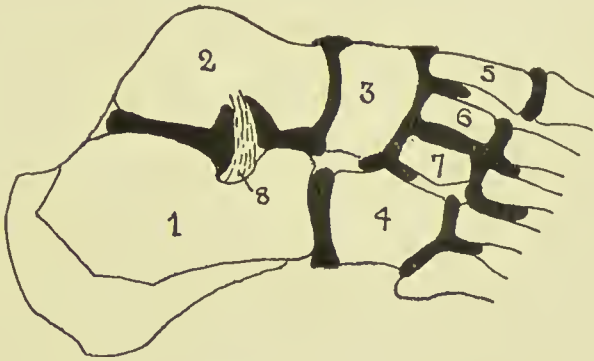


FIG. 45.—DIAGRAM OF THE SIX SYNOVIAL MEMBRANES OF THE FOOT.

- | | |
|----------------|---------------------------|
| 1. Os calcis. | 5. Internal cuneiform. |
| 2. Astragalus. | 6. Middle cuneiform. |
| 3. Scaphoid. | 7. External cuneiform. |
| 4. Cuboid. | 8. Interosseous ligament. |

THE TARSO-METATARSAL ARTICULATIONS.—The first metatarsal articulates with the internal cuneiform by a complete joint, which undergoes an outward subluxation in the condition called *hallux valgus*, the suppurating *bunion*, which frequently forms in this condition, sometimes communicating with and causing disorganization of the joint. The second and third metatarsal bones articulate with the middle and external cuneiform bones respectively, being connected by dorsal and plantar ligaments, the latter reinforced by slips from the tibialis posticus tendon. The second metatarsal, however, is connected to both internal (ligament of Lisfranc) and external cuneiforms by means of interosseous ligaments. The fourth and fifth metatarsals articulate with the cuboid,

being connected by dorsal and plantar ligaments, the latter reinforced by slips from the long plantar ligament. The fourth also is connected to the external cuneiform by an interosseous ligament, and the bases of the third and fourth are also connected by an interosseous ligament. There are SIX SEPARATE JOINT CAVITIES in the tarsus and metatarsus—namely, (1) Posterior calcaneo-astragaloid. (2) Calcaneo-astragaloscaphoid. (3) Calcaneo-cuboid. (4) Anterior tarsal. This is a large articulation, and extends (a) between the scaphoid and three cuneiforms; (b) between each of the cuneiforms, and between the external cuneiform and cuboid; (c) between the bases of the second and third metatarsals, and middle and external cuneiforms respectively; (d) between the contiguous surfaces of the second, third, and fourth metatarsals. (5) Between internal cuneiform and first metatarsal. (6) Between cuboid and fourth and fifth metatarsals.

The **bones of the foot** are frequently affected by *tubercular* disease, the os calcis being most frequently affected, then the base of the first metatarsal, astragalus, cuboid, etc. The disease generally affects the neighbouring joints, and in the case of the scaphoid the large anterior tarsal joint may be involved, and the disease thus become widely diffused. The tendon sheaths also become affected at times, especially the tibial and peroneal. In *operating* it is important to preserve, where possible, the os calcis, which supports the heel, and the head of the first metatarsal, which supports the ball of the toe. The OS CALCIS is frequently affected by tubercular *carionecrosis*, in which a spherical portion of bone is killed in mass (necrosis) by a spreading ulceration (caries), which surrounds and cuts it off. Such disease can frequently be removed without excision of the bone. The os calcis, while frequently *fractured*, is seldom dislocated, and when displaced is generally displaced outwards. It is the most frequently fractured tarsal bone, the fracture occurring from falls on the heel or from muscular action, the tendo Achillis tearing off the posterior portion. Ossification begins in the sixth month of foetation.

The ASTRAGALUS may be *dislocated* forwards, backwards, or laterally, the latter being generally associated with forward movement. Forward dislocation is the most common, is generally complete, frequently compound, and is generally associated with fracture of the tibia, fibula, or astragalus itself.

In all cases the malleoli come nearer the sole, and there is also inversion in the forwards and outwards variety, and eversion in the forwards and inwards variety. *Subastragaloid dislocation* of the foot occurs through the astragalo-scaphoid and astragalo-calcaneal joints, the astragalus retaining its position, and the foot being displaced generally backwards, and either in or outwards. In the former the foot is inverted and curved with the convexity on the outer side, thus resembling talipes varus; in the latter the foot is everted, and the head of the astragalus forms a projection on the inner aspect. The condition is frequently compound, and is generally incomplete as regards the astragalo-calcaneal joint, and complete in the astragalo-scaphoid joint. The astragalo-calcaneal ligaments are torn, and the malleoli are frequently fractured. *Fracture* of the astragalus may result from a fall on the feet, and is frequently associated with fracture of the os calcis, but fracture of the bones of the leg is a more usual consequence. Ossification begins in the astragalus in the seventh month of foetal life. *Dislocations* of the SCAPHOID, CUNEIFORMS, and individual METATARSALS have been reported, but none of the cuboid alone. The *cuboid* begins to ossify at birth, and the scaphoid in the third year. Dislocations of all the metatarsals occur rarely, that upwards being the most common.

Deformities of the foot are generally classed under the heading of talipes, of which there are four principal varieties: talipes varus, talipes valgus, talipes equinus, and talipes calcaneus. The most common form of talipes is a combination of two of these—namely, **talipes equino-varus**—the foot being turned inwards, so that the patient walks on the outer side (talipes varus), while the heel and posterior portion of the foot are drawn up, so that the patient walks on the anterior portion of the foot only (talipes equinus). In addition the foot as a whole is somewhat curled, the sole becoming concave, and the toes being frequently so much turned inwards that in running the child requires to lift one foot over the other. This form is generally congenital, being due to a want of foetal unwinding, and consists primarily of a *deformity of the bones*, the astragalus being principally affected, the muscles and ligaments being sometimes affected secondarily. The neck of the astragalus is lengthened and curved, so that the head, which articulates with the scaphoid, looks inwards instead of

forwards, as it normally does, and while the body of the bone is roughly cubical normally, it becomes wedge-shaped in talipes, the base of the wedge being directed to the outside of the foot, and the apex to the inside. The scaphoid and the os calcis may also become somewhat wedge-shaped, and the former may be so turned round that its tubercle touches the internal malleolus, while the latter is placed almost vertically. The weight of the body rests therefore, not on the heel, but on the cuboid and external surface in front of it, the prominence of the cuboid on the outer side of the foot being generally accentuated by the presence of a bursa. At birth and for some time afterwards the condition can generally be rectified by manipulation alone, the bones being cartilaginous and soft, and tending to unwind. Later, they become hard and unyielding, and other changes occur, the muscles attached to the tendo Achillis becoming atrophied and contracted, the tibiales possibly becoming similarly affected, while the plantar fascia also becomes contracted, and the knees tend to become slightly hyperextended and stiff. In such cases *excision* of the astragalus, combined if necessary with tenotomy of the tendo Achillis, yields good results.

Pure TALIPES VARUS is very uncommon. TALIPES VALGUS is the opposite of talipes varus, the foot being everted and raised, so that the patient walks on the inner margin. A pure valgus is not often met with, the condition being generally associated with flat-foot, which is sometimes meant when the term talipes valgus is used. In the usual type of valgus the foot is flat, the arch being lost, and the head of the astragalus and the scaphoid presenting in the sole. TALIPES EQUINUS and TALIPES CALCANEUS generally are acquired, being due to atrophy and contraction of the muscles of the leg, often secondarily to poliomyelitis. In the former the heel is raised from the ground by contraction of the muscles attached to the tendo Achillis, and the patient walks on the balls of the toes, the foot frequently becoming curved from the transmission of weight and contraction of the plantar fascia, so that heel and toes approach one another (*talipes cavus*). In the latter, which is less common, the anterior part of the foot is drawn up, and the patient walks on the heel, which is generally very prominent, owing to the tilting of the os calcis with projection of its posterior end.

Flat-foot is due to a loss of tone and stretching of the tendons and ligaments of the sole of the foot. In consequence the greater portion of the sole of the foot comes in contact with the ground, the foot tending also to become slightly abducted. In bad cases the osseous arch may sink to such an extent that the head of the astragalus and the tubercle of the scaphoid may present in the sole. The affection is generally painful, the pain being frequently referred to the region of the ankle, and is best treated by attention to the tone of the muscles and ligaments, walking on the balls of the toes, etc. In severe cases a wedge has been removed from the tarsal bones (*tarsectomy*), and the patient thus given a fixed osseous arch.

The TOES are subject to various deformities, especially the great and second toes. *Hallux valgus* has already been mentioned. *Hallux rigidus* consists of a fixed flexion of the metatarso-phalangeal joint. *Hammer toe* is a condition which most frequently affects the second toe, that toe being the longest in a classical foot, and so being pressed upon by badly-fitting boots, or by the great toe in *hallux valgus*. It becomes dorsiflexed at the metatarso-phalangeal joint, flexed at the first interphalangeal joint, and hyperextended at the last interphalangeal joint. A corn frequently develops over the first interphalangeal joint, and another over the tip of the toe, and considerable pain is caused. The tendons and ligaments become contracted in the later stages.

AMPUTATION OF THE FOOT may be performed through the tarso-metatarsal joint (Lisfranc), or through the midtarsal joint (Chopart), or at the ankle (Syme). The latter generally yields the most serviceable stump. In *Lisfranc's amputation* a plantar flap is raised by an incision across the bases of the toes, and extending backwards to the bases of the first and fifth metatarsal bones, all the structures down to the bones being included—namely, skin, subcutaneous tissue, abductor minimi digiti, flexor brevis hallucis and minimi digiti, transversus pedis, and tendons of the flexor longus digitorum and hallucis, tibialis posticus tendinous expansions, plantar vessels and nerves. The dorsal flap has a convexity forwards, and runs from the base of the first to that of the fifth metatarsal, and also includes the structures down to the bone—namely, skin, fascia with superficial veins and musculocutaneous nerve, tendons of the extensor communis and brevis

digitorum, extensor longus hallucis, tibialis anticus, and anterior tibial nerve and dorsalis pedis artery. The articulation between the base of the first metatarsal and the internal cuneiform is then opened, care being taken not to go too far back and open the joint between the internal cuneiform and scaphoid instead. Then the three outer metatarsals are disarticulated from the tarsus. The chief difficulty lies in disarticulating the second metatarsal, the base of which, articulating with the short middle cuneiform, is mortized in between the internal and external cuneiforms. The position of the articulation is sought on the dorsal surface with the point of the knife, the metatarsal being strongly flexed, and once the basal joint is opened the lateral articulations with internal and external cuneiforms are divided, that with the internal cuneiform presenting the strong ligament of Lisfranc. The whole of the metatarsals are now removed, the tendons of the tibialis posticus (expansions) and peroneus longus on the plantar, and peronei brevis and tertius on the dorsal aspect, being cut. The internal cuneiform forms a marked projection, and is difficult to cover unless a very abundant flap has been provided. *Hey*, instead of disarticulating the first metatarsal, saws through the internal cuneiform at the level of the articulation between middle cuneiform and second metatarsal, while *Skey* saws across the base of the second metatarsal instead of disarticulating, and *Cooper* saws across the bases of all the metatarsals, the tendons of the peronei and tibialis anticus being thus left intact, and the large anterior synovial cavity unopened. *Chopart's amputation* is performed by making a short dorsal flap from behind the tubercle of the scaphoid to a finger's breadth behind the base of the fifth metatarsal, reaching anteriorly to the bases of the metatarsals; and a plantar flap, which, commencing and ending at the same points, extends forwards to the centre of the metatarsals, both flaps taking all structures down to the bone, and are as given for Lisfranc, save that the peroneus brevis and peroneus tertius are cut in the dorsal, and flexor accessorius and tibialis posticus are cut in the plantar flaps. Disarticulation is done from within outwards through the astragalo-scaphoid and calcaneo-cuboid joints.

Syme's amputation is performed by taking a point just below and in front of the external malleolus, and a point opposite

to it on the inside. These points are joined by a vertical incision made with the foot strongly dorsiflexed, so as to keep behind the ridge of the posterior tuberosity of the os calcis. The flap is cut down to the bone, and is then dissected up, care being taken to keep close to the bone, and so avoid injury to the vessels. The tendo Achillis may be cut close to its origin or peeled off. The ends of the first incision are now joined across the dorsum, the foot is firmly extended, and disarticulated at the ankle. The malleoli are then sawn off, and the wound closed. The anterior tibial artery is cut in the centre of the anterior incision, the nerve lying to its outer side, and the long saphenous vein to its inner side. The small anterior peroneal artery is also cut on the front of the ankle. The peroneus tertius, extensor hallucis, and tibialis anticus muscles are cut in front. The plantar arteries and nerves are cut on the inner side of the heel flap, and the external saphenous vein and nerve on the outer. The peronei longus and brevis, abductor hallucis, tibialis posticus, flexors longus hallucis, and digitorum are divided in the heel flap. In *Pirogoff's amputation* the posterior portion of the os calcis is cut off instead of being removed, and is attached to the cut surface of the tibia.

The Nerves of the Lower Extremity.

The SPINAL ORIGINS of the nerves supplying the muscles of the lower limb are :—adductors, ilio-psoas, pectineus, sartorius (third lumbar) ; quadriceps extensor cruris (fourth lumbar) ; hamstrings, glutei medius and minimus, tensor fasciæ femoris (fifth lumbar) ; gluteus maximus, short external rotators of hip-joint, peronei, extensors of toes, flexors of ankle (first sacral) ; gastrocnemius, soleus, long flexors of toes, extensors of ankle, muscles of sole (second sacral).

The OBTURATOR NERVE arises from the second to the fourth lumbar nerves in the psoas muscle, from the inner border of which it emerges to pass through the obturator foramen into the thigh, dividing into superficial and deep branches, of which the former supplies the hip-joint through the cotyloid notch, the adductors longus, gracilis, and brevis, the femoral artery in Hunter's canal, and the skin over the lower two-thirds of the inside of the thigh. The deep branch supplies the

obturator externus muscle, the adductors magnus and brevis, and the knee-joint.

Injury of this nerve alone is rare, but may be caused by pressure of the fœtal head or of an obturator hernia. In paralysis, adduction, or crossing, of the limbs is impossible, and outward rotation difficult. Sensation is also affected over the part of the thigh supplied.

The ANTERIOR CRURAL nerve arises from the second to the fourth lumbar nerves in the psoas muscle, from which it emerges on the outer border, to enter the thigh between the psoas and iliacus muscles, which it supplies by passing under Poupart's ligament. In the thigh it supplies the pectineus, sartorius, and quadriceps, articular branches to the hip and knee joints, and middle and internal cutaneous branches to supply the greater portion of the front of the thigh. The long, or internal saphenous, branch accompanies the femoral vessels to the inner side of the knee, where it supplies an articular branch to the knee-joint, and a branch to the patellar plexus, and then supplies the skin of the leg and foot in front, and to the inner side.

The nerve may be injured by fractures, or tumours, of the pelvis, psoas abscess, etc., and when paralyzed the hip cannot be flexed (ilio-psoas), nor the knee extended (quadriceps).

The GREAT SCIATIC nerve arises from the fourth and fifth lumbar, and the first to the third sacral nerves, passes out through the great sciatic foramen, and divides into internal (or tibial) and external (or peroneal) popliteal nerves. The trunk supplies articular branches to the hip and knee joints, muscular branches to the hamstrings and smaller muscles of the hip. The tibial nerve is derived from the anterior trunks of the fourth and fifth lumbar, and first and second, and part of the third sacral, while the peroneal is derived from the posterior trunks of the fourth and fifth lumbar, and first and second sacral.

The *tibial nerve* enters the leg at the lower border of the popliteus muscle, which it supplies, as well as the tibialis posticus, gastrocnemius, soleus, and plantaris, while lower down it supplies the flexor longus digitorum and hallucis. It also supplies the knee-joint, and, together with the peroneal communicating, forms the short saphenous nerve, which supplies the skin of the outer and back parts of the lower third of the

leg, ankle, heel, outer side of foot, and little toe, and gives an articular branch to the ankle. It terminates by dividing into

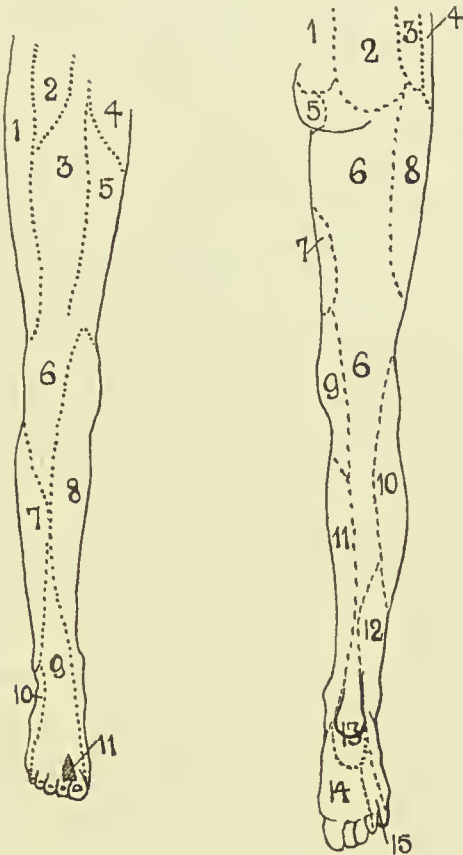


FIG. 46.—NERVE-SUPPLY OF LOWER EXTREMITY.

- | | |
|---|---|
| <ul style="list-style-type: none"> 1. Ext. cutaneous. 2. Genito-crural. 3. Middle cutaneous. 4. Ilio-inguinal. 5. Int. cutaneous. 6. Patellar plexus from long saphenous and ext., middle, and int. cutaneous. 7. Ext. popliteal. 8. Long or int. saphenous. 9. Musculo-cutaneous. 10. Short or ext. saphenous. 11. Ant. tibial. | <ul style="list-style-type: none"> 1. Post. sacral. 2. Post. lumbar. 3. Ilio-hypogastric. 4. Last thoracic. 5. Perforat. cutan. of fourth sacral. 6. Small sciatic. 7. Obturator. 8. Ext. cutaneous. 9. Int. cutaneous. 10. Ext. popliteal. 11. Long saphenous. 12. Short saphenous. 13. Int. calcaneal of post. tibial. 14. Int. plantar of post. tibial. 15. Ext. plantar of post. tibial. |
|---|---|

internal and external *plantar* nerves, the former of which is the larger, and is homologous with the median nerve in the hand, while the latter is homologous with the ulnar (*q.v.*).

In paralysis of this nerve the toes cannot be flexed, nor the ankle extended (long flexors of hallux and toes, *tibialis posticus*, *gastrocnemius*, and *soleus*). Adduction and inversion of the foot are impaired (*tibialis posticus*), as is likewise sensation over the area supplied.

The *peroneal nerve* passes over the outer head of the *gastrocnemius* to the back of the fibular head. At this part it gives off a sural branch, which supplies the skin over the upper two-thirds of the leg posteriorly, and a communicating branch to form the external saphenous nerve with the tibial communicating. The recurrent tibial branch supplies the *tibialis anticus*, and tibio-fibular articulation, and knee-joint. The terminal branches are the anterior tibial and musculo-cutaneous, the former supplying the *tibialis anticus*, long extensors of the hallux and toes, *extensor brevis digitorum*, the three dorsal interossei muscles, the ankle, and other adjacent joints, and the skin over the adjoining sides of the great and second toes.

The musculo-cutaneous nerve supplies the *peronei longus* and *brevis*, and the skin over the lower third of the leg, *dorsum* of the foot, and toes.

In paralysis of the nerve the foot droops, and can neither be flexed nor abducted (extensors of hallux and toes, and *peronei*), and adduction is imperfect (*tibialis anticus*). It also becomes flattened from paralysis of the *peroneus longus*. Sensation is impaired over the affected area.

SECTION V

UPPER EXTREMITY

REGION OF THE SHOULDER—SURFACE ANATOMY.—This region may be divided into clavi pectoral, deltoid, and scapular portions. The CLAVI PECTORAL REGION is bounded by the clavicle above, the sternum internally, lower border of the pectoralis major below, and the groove between the pectoralis and deltoid externally. The *skin* is thin and freely movable, while the *subcutaneous tissue*, particularly in the female, is generally abundant. The clavicle forms a prominent landmark, the acromial end being generally the least prominent portion, while, when the acromio-clavicular ligaments are relaxed, it may be very prominent, simulating subluxation. While the axis of the clavicle is normally directed outwards and upwards, so that the sterno-clavicular articulation is in line with the head of the humerus, it may in weakly persons incline downwards at the outer end. The *deltoid tubercle* is a small bony projection, situated about the centre of the outer curve, on the anterior border, which, if well developed, might be mistaken for an exostosis. A *bursa* frequently develops over the outer part of the clavicle in those who carry weights on the shoulder, and *lipomas* are sometimes met with in the same region. The *infraclavicular fossa* lies under the outer third of the clavicle, which bounds it above, and is directed downwards and outwards between the pectoralis major and deltoid. It overlies the upper part of the axilla, lodges the cephalic vein and a branch of the acromio-thoracic artery, and the axillary artery may be felt and compressed against the second rib by deep pressure in it. It is obliterated in subcoracoid dislocations of the humerus, some fractures of the clavicle, axillary swellings, and by superficial œdema. The *coracoid process* lies just to its outer side, covered by some fibres of the

deltoid. When the arm hangs at the side with the palm directed forwards, the bicipital groove also looks forward, and lies midway between the acromial and coracoid processes. In this position also the acromion, external condyle, and styloid process of radius all lie in the same line. The lower border of the pectoralis major constitutes the *anterior fold of the axilla*. The line of the *axillary artery*, when the arm is raised from the side, runs from the centre of the clavicle to the inner side of the coraco-brachialis. The upper border of the pectoralis minor is indicated by a line from the costo-chondral junction of the third rib to the coracoid. The point of intersection of these two lines indicates the position of the *acromio-thoracic artery*. A line from the costo-chondral junction of the fifth rib to the coracoid indicates the lower border of the pectoralis minor, and the *long thoracic artery* which runs along that border.

The DELTOID REGION corresponds to the deltoid muscle, being limited above by the outer third of the anterior border of the clavicle, tip and outer border of the acromion, and lower border of the spine of scapula. It extends almost to the centre of the humerus. The *skin* in this region is rather thick and coarse, and is bound to the fascia of the underlying muscles by fascial septa. The rounded contour of the shoulder depends on both the deltoid muscle and the tuberosities of the humerus. If the muscle be atrophied or the head of the bone displaced, the acromion process, which normally does not form a projection, stands out prominently, and the tip of the fingers may even be inserted beneath it. The junction of the acromion with the inferior border of the scapular spine is marked by the *acromial angle*, which is often the best marked portion of the acromion, and is used in taking various measurements. It is useful to remember in examining for dislocation that the internal condyle of the humerus indicates the direction of the articular surface of the head. The most prominent portion of the shoulder in front is formed by the great tuberosity. The coracoid process lies just to the outer side of the infraclavicular fossa, and is overlapped by the anterior border of the deltoid muscle. The posterior circumflex artery and circumflex nerve cross the humerus horizontally a finger's breadth above the centre of the vertical length of the deltoid.

The SCAPULAR REGION corresponds to the bone, which extends from the second to the seventh rib, and is divided by the spine into supra- and infraspinous regions. The *skin* in this region is thick, and closely adherent to the dense subcutaneous tissue, and is frequently the seat of *boils* and *carbuncles*. The *scapular spine* forms a prominent landmark, and its inner extremity is opposite the spine of the third dorsal vertebra. The vertebral border and spine of the scapula are easily palpated, while the anterior border is covered by the infraspinatus and teres muscles. The anterior surface of the scapula gives origin to the *subscapularis*, which forms the greater part of the posterior axillary wall. The *latissimus dorsi* forms the posterior fold of the axilla, and lies at a lower level than the pectoralis major, which forms the anterior fold, and lies at the level of the fifth rib.

The Clavi-pectoral Region.—The *shoulder girdle* is formed by the clavicle and scapula, the clavicle alone being articulated to the trunk at the sterno-clavicular articulation. A few cases of *avulsion* of the entire upper limb have been recorded, the only joint involved being the small sterno-clavicular one. The *skin* over the clavicle is freely movable, and hence frequently escapes wounding and penetration from fracture, while injury is frequently accompanied by severe pain from implication of the *supraclavicular nerves*, which may also rarely be caught in callus after fracture, and so cause persistent pain. On the other hand, pain over the clavicle may be caused by disease of the upper cervical spine, the pain being referred along the supraclavicular branches of the third and fourth cervical nerves. In addition to the skin, fascia, and superficial nerves, the anterior surface of the clavicle is covered by platysma fibres, and occasionally is crossed by the *cephalic vein*, or a branch from it to the external jugular. The *innominate vein* lies *behind* the sternal end of the clavicle, and also the bifurcation of the *innominate artery* on the right, and the *common carotid* on the left. These structures are separated from the bone by the sterno-hyoid and thyroid muscles. The *subclavian vessels* (with the vein most internal) and cords of the *brachial plexus* lie behind the inner or greater curve of the clavicle, from which they are separated by the subclavius muscle and axillary sheath. Owing to its position and the

weakness of its wall, the *vein* is most readily pressed on by tumour or fracture, the subclavius muscle, however, saving it in many instances. In addition to the structures mentioned, the suprascapular and internal mammary arteries, the external jugular veins, the phrenic and posterior thoracic nerve (to serratus magnus), omo-hyoid and scalene muscles, and apex of lung lie behind the clavicle.

The surfaces of both clavicle and sternum are covered with fibro-cartilage at the STERNO-CLAVICULAR ARTICULATION, and a disc of fibro-cartilage intervenes, which is attached above to the clavicle, and below to the sternum, and generally divides the joint into two distinct synovial compartments.

The capsular ligament is attached both to the clavicle and sternum, and the margin of the plate of fibro-cartilage, and is well defined anteriorly and posteriorly.

A strong ligamentous band—the *interclavicular ligament*—extends from the upper border of the articular facet of one clavicle to the other, over the sternal notch, into which many fibres are inserted; and the *rhomboid ligament* consists of fibres directed upwards and outwards from the first costal cartilage to the under surface of the clavicle. To these two latter accessory ligaments the strength of the articulation is mainly due. The joint permits of limited movement in nearly all directions, and, when diseased, abduction of the arm is particularly painful, as the joint surfaces are then brought most nearly into apposition. Forward movement is checked by the posterior ligament, assisted by the anterior; backward movement by the anterior, assisted by the posterior and the rhomboid; upward by the rhomboid, interclavicular, and interarticular cartilage.

Dislocation of the sternal end of the clavicle is not common, that forwards being the most frequent, and followed by those backwards and upwards, the latter being very uncommon. In the forward variety the head of the bone lies in front of the manubrium, and carries the sterno-mastoid forwards. In the backward dislocation the rhomboid ligament is torn in addition to the capsule, and the head lies between the manubrium and the sterno-hyoid and thyroid muscles, sometimes pressing on the trachea or œsophagus, causing dyspnœa or dysphagia, or on the subclavian artery or innominate vein. In the upward variety the head lies on the manubrium between the sterno-

mastoid and sterno-hyoid muscles. The dislocations are generally easily reduced, but difficult to retain in position. This joint is said to be more frequently involved in *pyæmia* than any other. The pus generally presents anteriorly, though it may burst posteriorly, and so enter the mediastinum, and the condition is not followed by anchylosis, owing to the character of the joint and the constant movement. Not merely does the clavicle supply the only articulation between the upper limb and the trunk, it also plays an important part in regulating the position of the shoulder in relation to the chest-wall, and gives attachment to important muscles both of the neck and of the upper extremity. Before discussing its regulating power, it will be necessary to consider the connections between the clavicle and scapula. These consist of two sets — acromio-clavicular articulation and coraco-clavicular ligaments.

The ACROMIO-CLAVICULAR JOINT is directed from before backwards, and slopes from above, down, and inwards, the outer end of the clavicle projecting to a varying extent above the upper surface of the acromion upon which it rests. An incomplete interarticular cartilage generally exists, and there is a capsular ligament best developed above and below.

The CORACO-CLAVICULAR ATTACHMENT consists of two ligaments, the *conoid* and *trapezoid*, which extend from the posterior portion of the upper surface of the coracoid process to the conoid tubercle and trapezoid ridge respectively on the under surface of the clavicle. A synovial bursa frequently exists between these two ligaments. These ligaments chiefly limit the movement of the outer end of the clavicle, which is fixed to and must move with the scapula. When the scapula moves, it carries with it the clavicle, which in turn moves on the sterno-clavicular joint. But for the clavicle, the scapula, in gliding round the chest-wall under the action of the serratus magnus and other muscles, would tend to lie close to that wall, and thus, when the scapula came forward on the chest, its glenoid cavity, instead of being at right angles to the long axis of the arm, would be directed forwards and inwards, so that if the arm were used to strike a blow, the head of the humerus would rest on the posterior part of the capsule, instead of in the glenoid cavity, and thus dislocation would probably occur. This tendency for the scapula to rotate on coming forwards is

prevented by the clavicle, and as it does so the acromioclavicular joint comes into play, and the angle between the scapula and clavicle diminishes. Owing to the shape of this joint, *dislocation*, when it occurs, is generally upwards and frequently partial. A few cases of downward dislocation are recorded. The displacements are easily reduced, but difficult to retain in position.

The **clavicle**, owing to its superficial and exposed position, its reception of all shocks communicated to the upper extremity, its slenderness and early ossification, is more frequently *fractured* than any other bone, the fracture most frequently occurring at the junction of the middle and outer thirds. The fracture occurs here, as this is the most slender part of the bone; the fixed outer third meets the more movable inner two-thirds, and the two curves meet at this point. The fracture is generally due to indirect violence, is oblique, and runs from above, downwards, and inwards, the inner fragment maintaining its normal position, or having its outer end slightly raised by the clavicular portion of the sterno-mastoid. The outer fragment is (*a*) depressed by the weight of the limb, aided by the pectorals and latissimus dorsi; (*b*) drawn inwards by the same muscles, assisted by the trapezius, rhomboids, levator anguli scapulae, and subclavius; (*c*) rotated on a vertical axis, so that the broken end looks inwards and backwards, by the serratus magnus acting on the scapula, assisted by the pectorals.

The rotation is generally difficult to remedy, and shortening frequently results. A recumbent position, with a narrow pillow between the shoulders, helps in reducing the deformity. Fracture due to *direct violence* may occur at any part of the bone, and is generally transverse. When about the middle third, the displacement is as above; when *between the conoid and trapezoid ligaments*, there is no displacement; when *external to these ligaments*, the inner end of the outer fragment is raised by the trapezius, while the outer end is drawn forwards by the serratus magnus and pectorals. In fracture at the *inner extremity*, the inner end of the outer fragment is displaced down and inwards, simulating dislocation. The clavicle has been fractured by *muscular violence*, generally in the middle third, probably due to the action of the deltoid and clavicular portion of the pectoralis major. It is the most frequent seat

of *greenstick fracture*, owing to its early ossification (the entire shaft being bony at birth), and thick but lax periosteum, half the cases of fractured clavicle occurring before five years of age. The cords of the brachial plexus, the subclavian artery and vein, the acromio-thoracic artery and internal jugular vein, and even the lung may be injured in fractures of the clavicle. The biceps, brachialis anticus, and supinator longus are supplied by the upper cord of the plexus, and may be paralyzed by a blow on the shoulder (which may subsequently fracture the clavicle), or may be affected by the carrying of heavy weights on the shoulder.

The Scapular Region.—The posterior scapular muscles are contained within fairly definite compartments, composed of deep fascia, which are attached round their origins to the bone, and accompany them to near their insertions. The sheath of the infraspinatus and teres minor muscles is more dense than that of the supraspinatus. These fascial sheaths tend to limit hæmorrhagic and purulent effusions, and direct them forward toward the muscular insertions, and they also fix tumours growing from the fascia, and thus make them resemble tumours springing from the bone. The inferior angle of the scapula is crossed by the latissimus dorsi, and gives insertion to a slip of the muscle. When the angle slips out from under the latissimus, as it does in some injuries, especially when the muscular slip is torn, the angle of the scapula projects, and the upper limb is somewhat weakened. On the other hand, especially after carrying heavy weights on the shoulder, the posterior thoracic, or external respiratory nerve (of Bell) may be injured, causing *paralysis* of the serratus magnus. When this occurs, the vertebral border and inferior angle of the scapula project markedly from the posterior chest-wall (*luxation*). Projection of the angle of the scapula is also generally marked in lateral curvature of the spine, the scapula on the side of the convexity of the curve being affected. As already noted, the carrying of heavy weights on the shoulder may also lead to paralysis of the biceps, brachialis anticus, and supinator longus. Owing to its position between thick muscular pads, resting on the elastic chest, and its mobility, *fracture*, particularly of the body of the scapula, is not common. The part of the bone most frequently fractured is the acromion. The *acromion* possesses two or three centres

of ossification, ossification beginning about puberty, and junction with the rest of the bone about twenty-three; but sometimes only a fibrous union occurs between process and spine. In such cases of fracture displacement is slight, owing to the dense periosteum and fibrous aponeurosis of the muscles. Occasionally the fracture may involve the acromio-clavicular joint. The *coracoid* is rarely broken in dislocations of the head of the humerus inwards, and still less frequently by trauma or muscular violence. It may also be separated as an epiphysis up to the seventeenth year. Displacement is generally slight, being limited by the coraco-clavicular ligament, but may be considerable.

Fracture of the surgical neck of the scapula occurs rarely. The line of fracture is from the suprascapular notch to the upper part of the axillary border, nearly parallel to the glenoid cavity, and including the coracoid process. Displacement is generally slight, owing to the coraco-clavicular and acromio-clavicular ligaments; but if these be torn, then the whole arm will be displaced downwards, the condition resembling a subglenoid dislocation, from which it may be distinguished by the ease with which reduction is obtained, but which is not maintained; by the fact that the coracoid moves with the humerus; by crepitus, etc. Fractures of the body of the bone generally affect the blade below the spine, little displacement occurring.

The scapula is not infrequently the seat of tumours, which generally grow from the neck, spine, or inferior angle. *Sarcoma* is generally of the periosteal type, and may necessitate removal of the whole bone, and sometimes of the arm as well, particularly if the joint be involved. The removal is done by making an elliptical incision, beginning over the clavicle, and ending over the angle of the scapula. The artery is tied before the vein, so as to empty the limb of blood, and the supra-, sub-, posterior, and dorsal scapular vessels and acromial branches of the acromio-thoracic artery require ligature.

The Deltoid Region.—The *SKIN* in this region is thick, and possesses a considerable subcutaneous tissue, in which *lipomata* not infrequently develop, and which occasionally shift their position under gravity to perhaps the front of the chest. The *deltoid muscle* in its sheath covers in the whole region. Under

the deltoid is a quantity of loose connective tissue, which may occasionally be membranous, and exert an effect in limiting abscesses of the joint. In this loose tissue are one or more *bursæ*, which separate the muscles from the underlying structures. The *coracoid process* gives attachment by its inner border to the pectoralis minor, and by its apex to the coracobrachialis and short head of the biceps. It gives attachment to the coraco-clavicular ligaments (conoid and trapezoid) by its upper surface, and by its outer border to the *coraco-acromial ligament*, which is a flat band, triangular in outline, uniting the acromion and coracoid, and thus completing the *coraco-acromial arch*. This arch overhangs and completes the shoulder-joint, from which it is separated by the *subacromial bursa*, which lies between the arch and the capsule with tendons of the capsular muscles. This bursa is frequently the seat of disease, rendering abduction movements painful. When it suppurates, the pus may burst into the loose subdeltoid areolar tissue, and simulate disease of the shoulder-joint. As the fascia covering in the deltoid and infraspinati muscles posteriorly is dense, the pus generally presents anteriorly. It may be torn by twists of the arm, and sometimes communicates with the joint in old people.

THE SHOULDER-JOINT.—While of the ball-and-socket variety, the shoulder-joint relies chiefly upon muscular support, and thus, while great latitude of movement is permitted, it also is prone to dislocation. The coraco-acromial arch, with its concavity directed downwards, greatly strengthens the articulation against upward and backward or forward displacements. While normally the head of the humerus is only separated from the arch by the bursa, it may in cases of *paralysis* of the deltoid and scapular muscles fall away from it, permitting of the insertion of the finger between arch and head. The joint is also supported by the short scapular muscles and the long head of the biceps. In *rupture* of the latter the head of the humerus may be pulled up and forwards close to the coraco-acromial arch. Atmospheric pressure and cohesion also assist in keeping the parts in apposition. Movement is permitted in all directions, save direct adduction, but extension backwards is limited by the head coming in contact with the coracoid. The movements generally are rendered more free by the mobility of the scapula.

The *glenoid cavity* is shallow and pyriform, the apex being directed upwards. The lowest part of the margin is the strongest, and it is more prominent on the inner than on the outer side, thus strengthening the weakest part of the articulation, the lower and inner, through which part dislocations generally occur. When the arm hangs at the side, two-thirds of the humeral head are not in contact with the glenoid. The glenoid is covered by hyaline cartilage, and surrounded peripherally by a ring of fibro-cartilage, the *glenoid ligament*, which deepens

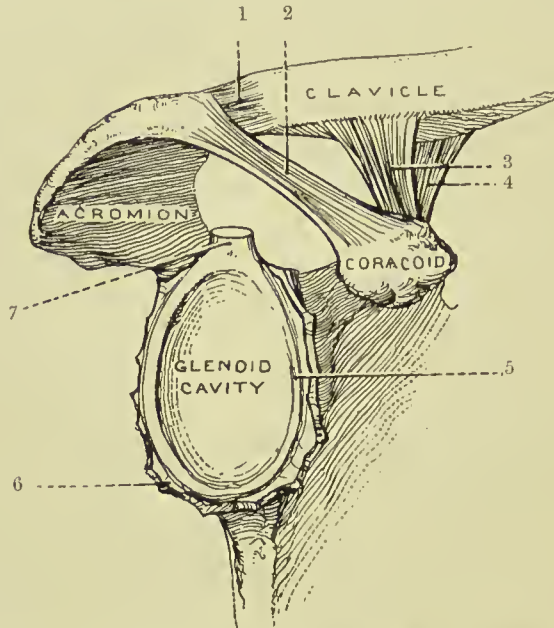


FIG. 47.—THE RIGHT GLENOID CAVITY, AND THE ADJACENT LIGAMENTS.
(From Buchanan's "Anatomy.")

- | | |
|---|-----------------------------|
| 1. Capsule of acromio-clavicular joint. | 5. Glenoid ligament. |
| 2. Coraco-acromial ligament. | 6. Capsular ligament (cut). |
| 3. Trapezoid ligament. | 7. Long head of biceps. |
| 4. Conoid ligament. | |

the cavity. The supra- and infraspinati and teres minor muscles are inserted into the great tuberosity of the humerus, and their tendons practically fuse with the capsular ligament. A projection of synovial membrane under the infraspinatus is rare. The subscapularis, which is inserted into the lesser tuberosity, is separated from the capsule, which is deficient at this point, by a bursa—subscapular—which may communicate with the joint. Apart from these muscles the capsule is lax.

The *capsule* is inserted above into the rim of the glenoid fossa

and to the glenoid ligament, while below it is inserted into the anatomical neck of the humerus in front and externally, but a little distal to the neck behind and internally. It is strengthened by some accessory ligaments, the *coraco-humeral* running from the root of the coracoid to the great tuberosity, and superior, middle, and inferior *gleno-humeral* running from the glenoid margin above and in front to the lesser tuberosity and neck of the humerus below. The long head of the biceps acts as an accessory ligament, being inserted above into a small depression at the upper part of the glenoid fossa and to the glenoid ligament, and then, crossing the head to the inner side of the summit, descends in the bicipital groove. It is invested in a fold of synovial membrane, which forms a prolongation lining the bicipital groove as far as the insertion of the pectoralis major (the *intertubercular bursa*), and the groove is converted into a canal at its upper part by a series of ligamentous fibres, the *transverse humeral ligament*.

The shoulder is the most common seat of **dislocations**. By a *false luxation* is meant a displacement of the head, which remains within the capsule (as might occur in paralysis of the muscles), while in true dislocations the head leaves the capsule through a tear in the latter, which in the shoulder is said always to occur primarily at the lower and inner aspect, the head assuming the subglenoid position. Such displacements are caused by direct violence forcing the head downwards, or by indirect violence when the limb is abducted. Generally the head does not remain in the subglenoid position, but is drawn forwards and inwards by the pectoralis major, so as to rest under the coracoid. A subspinous dislocation is supposed to be due to the dislocating force acting from in front, and so driving the head backwards. In all dislocations of the shoulder there is flattening of the deltoid, owing to removal of the subjacent head, so that a *straight-edge* touching the external condyle and lying along the axis of the upper arm when at the side will also touch the acromion process. Normally the straight-edge lies nearly a finger's breadth from the acromion. As the deltoid is also stretched, there is a tendency to abduction of the arm from the side, and this is most marked in the subglenoid variety, while stretching of the biceps causes flexion and slight supination of the forearm. In the normal condition the patient can *touch the sound shoulder* with the fingers of

the affected limb, while the internal condyle of the humerus touches the crest of the ilium ; while in dislocation, owing to the head lying much closer to the thoracic wall than normally and the stretching of the muscles, the lower end of the humerus generally cannot be brought close into the side, and the necessary rotation is not permitted. The head having left the glenoid cavity, there is an increase in the vertical circumference of the shoulder ; but this is of little value as a test, since many swellings of the shoulder produce a similar result. The vessels and nerves may be pressed on, especially in the subglenoid or subcoracoid varieties, producing œdema, pain, and loss of power, and even in rare cases gangrene. The circumflex nerve is also occasionally damaged.

Much the most common form of dislocation is the SUBCORACOID, the head lying directly below the coracoid process, in front, internal to, and a little below, its normal position. The posterior part of the articular surface rests on the neck of the scapula, the anatomical neck rests on the anterior lip of the glenoid fossa, and the posterior part of the great tuberosity is opposite the glenoid cavity. The subscapularis muscle going to the lesser tuberosity is stretched over the humeral head, and may be partly torn, while the supra- and infraspinati and teres minor are stretched or torn, or the great tuberosity may be separated. The long head of the biceps is deflected down and inwards, and may even be torn from its groove, while the short head of the biceps and the coraco-brachialis are rendered very tense, and lie in front of the head, instead of to the inner side. Frequently the head is rotated markedly inwards, constituting an *intracoracoid* dislocation, the biceps tendon being markedly deflected, and the head producing only a slightly marked prominence. While there is actual lengthening present, the abduction produced frequently presents an apparent shortening, when a measurement is taken from the acromion to the external condyle. Rarely the head is carried farther inwards and upwards towards the clavicle, in extreme cases constituting a *subclavicular* dislocation.

The SUBGLENOID comes next to the subcoracoid dislocation in order of frequency. Here the head lies below and a little in front of and internal to its normal position, lying between the subscapularis above, and the long head of the triceps

below, the latter arresting its downward movement. The articular head rests on the flattened portion of the axillary border of the scapula, which gives origin to the triceps, just below the glenoid. The subscapularis and spinati muscles are stretched or torn, but the teres muscles generally escape. The deltoid is much stretched, and produces the marked abduction of the limb, while the coraco-brachialis and biceps are stretched, but not generally injured. Lengthening is present, but is often masked by abduction.

SUBSPINOUS DISLOCATION.—In the true subspinous dislocation the head rests on the dorsum scapulæ under the spine, the infraspinatus and teres minor muscles being pushed before it, while the subscapularis is drawn across the glenoid, and is frequently torn. The supraspinatus, biceps, and pectoralis major are rendered tense, the latter producing inward rotation and forward adduction of the humerus, while the teres major and latissimus dorsi are relaxed. The circumflex nerve is frequently torn. A modified subspinous or *subacromial* displacement is said to be more common, the head resting on the posterior surface of the neck of the scapula.

In reducing dislocations of the shoulder, especially those of old standing, the axillary artery is not infrequently damaged, the vein and nerves generally escaping. The glenoid cavity is capable of very considerable *distension*, the humerus being separated from the glenoid by nearly $\frac{1}{2}$ inch in extreme cases, and thus giving rise to lengthening, while slight extension (arm carried back) and rotation inwards take place, possibly in part due to the action of the latissimus dorsi. When the joint is distended, the diverticula also become affected, a swelling sometimes appearing between the pectoralis major and the deltoid, from distension of the intertubercular bursa, overlaid by the unyielding biceps tendon; and when rupture occurs it is frequently through one of the diverticula that it takes place, most often through the intertubercular one. Here the pus presents in front, generally below the pectoralis major tendon. When it escapes through the subscapular bursa, it tends to spread between the muscle and vertebral surface of the scapula, and point at the lower and back part of the axilla.

EXCISION of the shoulder is frequently performed for tubercular disease, or even rheumatoid arthritis, a false

joint, with practically perfect movement, generally resulting. A vertical incision is made over the head of the bone midway between the coracoid and the acromion, the humerus being fully rotated outwards, so as to remove the long head of the biceps from injury. This incision goes through the superficial tissues, deltoid, and capsule of the joint, and the head is then cut off with a fan-shaped osteotome, and the wound stitched up. In some cases of *myeloid sarcoma* of the upper end of the humerus an amputation of the head of the bone through the surgical neck is performed, a fairly useful limb resulting.

AMPUTATION at the shoulder may be performed by making a racket-shaped incision to include a deltoid flap, from the outer side of the coracoid down to the lower border of the pectoralis major, then outwards across the limb through the lower portion of the deltoid to the posterior axillary fold, the limb being abducted and rotated outwards. As the first part of this incision is practically that for excision, it enables the conditions of the parts about the joint to be examined before proceeding to amputate, in cases of doubt. The racket is now completed across the superficial tissues on the inner side of the limb. The deltoid flap containing the posterior circumflex vessels and circumflex nerve is now raised, the capsular muscles, capsule, and biceps tendon divided, and the head disarticulated. The triceps, latissimus dorsi, and teres major are next cut, and the limb being drawn from the side, the axillary vessels may be ligatured, and then along with the nerves, cephalic vein, humeral branch of the acromiothoracic artery, some fibres of the deltoid and biceps and coraco-brachialis, divided by a transverse incision.

THE AXILLA (Fig. 50) is a roughly funnel-shaped passage between the neck and the arm, whose apex is directed upwards and inwards, which is bounded in front by the clavicle and subclavius muscle, and behind by the first rib and first digitation of the serratus magnus, and whose base corresponds to the hollow of the armpit. The SKIN over the region presents numerous hairs and sebaceous and sudoriferous glands, in connection with which small abscesses frequently arise. Its *anterior* wall is composed of the pectoral muscles, the *pectoralis major* enveloped in the thin, deep pectoral fascia, and its lower border extending between the fifth rib and the middle of the

anterior border of the deltoid. Between the upper border of the pectoralis major and the deltoid is a narrow groove, which contains the cephalic vein, humeral branch of the acromio-thoracic artery, and one or two infraclavicular glands. The *pectoralis minor* forms with the costo-coracoid membrane a second, deeper layer.

The *costo-coracoid membrane* extends from the clavicle and subclavius muscle above, between the chest-wall internally

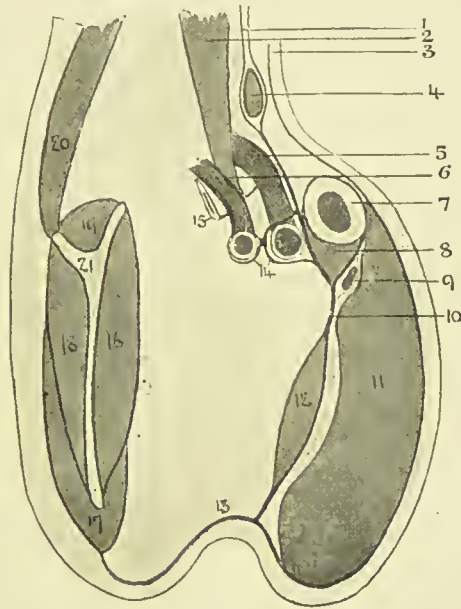


FIG. 48.—COSTO-CORACOID MEMBRANE.

- | | | |
|---|--|----------------------|
| 1. Pretracheal layer, deep cervical fascia. | 7. Clavicle. | 14. Axillary sheath. |
| 2. Scalenus anticus. | 8. Subclavius. | 15. First rib. |
| 3. Investing layer, deep cervical fascia. | 9. Cephalic vein. | 16. Subscapularis. |
| 4. Omo hyoid. | 10. Costo-coracoid membrane (clavi-pectoral fascia). | 17. Teres major. |
| 5. Axillary vein. | 11. Pectoralis major. | 18. Infraspinatus. |
| 6. Axillary artery. | 12. Pectoralis minor. | 19. Supraspinatus. |
| | 13. Axillary fascia. | 20. Trapezius. |
| | | 21. Scapula. |

and coracoid process externally, to the *axillary fascia*, stretching between the anterior and posterior axillary folds, below, where it fuses with subcutaneous tissues. On its way it splits to enclose the pectoralis minor, and it acts as a *suspensory ligament*, drawing up the skin of the axilla. It is separated by loose cellular tissue from the fascia covering the pectoralis major, and in this tissue lie branches of the acromio-thoracic vessels, anterior thoracic nerves, and a lym-

phatic gland belonging to the infraclavicular group. The portion above the pectoralis minor is perforated by the cephalic vein, branches of the acromio-thoracic vessels, and external anterior thoracic nerve. From its deep surface it sends off an expansion to the axillary vessels.

The *posterior wall* is formed from above downwards by the subscapularis, latissimus dorsi, and teres major muscles, and the *inner costal wall* is bounded by the five upper ribs, intercostal spaces, and serratus magnus, on whose surface lies the posterior thoracic nerve. The *base* of the passage or hollow of the armpit is covered by skin, subcutaneous tissues, and *axillary fascia*, the latter rather ill-defined, and fusing in front with the pectoral fascia; behind with that covering the latissimus dorsi and teres major; internally with the fascia of the serratus, and externally with the deep fascia of the arm. The axilla is occupied by loose fatty connective tissue, in which large collections of pus or blood may accumulate, and lodges the axillary vessels, brachial plexus, and lymphatic glands.

The AXILLARY ARTERY extends from the outer border of the first rib to the lower border of the teres major muscle, and is divided into three parts—above, behind, and below the pectoralis minor. Its course, and that of the brachial, is represented by a line drawn from a point $\frac{1}{2}$ inch inside the centre of the clavicle, to the centre of the bend of the elbow with the upper limb at right angles to the trunk. It is accompanied by the axillary vein, lymphatic glands, and cords of the brachial plexus, the vessels being enclosed in the axillary sheath derived from the deep cervical fascia. The *first part* lies on the first intercostal space and serratus magnus muscle, beneath the clavicular portion of the pectoralis major and the costo-coracoid membrane, and is crossed by the cephalic vein from without inwards. The axillary *vein* lies on its inner anterior aspect, and the cords of the brachial plexus behind and to the outer side. One branch, the *superior thoracic*, is given off, which anastomoses with the supra-scapular, acromio-thoracic, and internal mammary arteries.

Ligature of the first part is performed through a slightly curved incision, made below the clavicle from inside the coracoid to the sterno-clavicular articulation, skin, subcutaneous tissue, platysma, and pectoralis major being divided.

(This portion of the pectoralis major sometimes consists of two planes, with an intervening cellular interval.) The pectoralis minor is now pulled down, the costo-coracoid membrane defined and divided close to the coracoid process; the vein is drawn in, the sheath of the vessel opened, and the needle passed from within outwards. If the vein overlaps the artery, the arm should be drawn down to the side. In dividing the costo-coracoid membrane, care must be taken not to cut the branches of the acromio-thoracic artery and external and internal anterior thoracic nerves. Anastomosis is as in the third part.

The *second part* is the shortest, and is surrounded by the cords of the brachial plexus lying in the positions indicated by their names—inner, outer, and posterior. The *acromio-thoracic* and *long thoracic* branches are given off near the upper and lower borders of the pectoralis minor respectively. The latter is also called the *external mammary*, and supplies the outer and deeper parts of the gland and the pectoralis muscles. Its *vein* is stated to be a canalized vein, one whose walls are rigid and do not collapse when cut, rendering it liable to suck in air on inspiration.

The *third part* lies partly under the pectoralis major and partly superficially, and lies on the latissimus dorsi and teres major, while the capsule of the shoulder-joint and coraco-brachialis lie externally. It is surrounded by branches of the brachial plexus, the inner head of the median lying in front, the internal cutaneous and ulnar to the inner side, median and musculo-cutaneous to the outer, and musculo-spiral and circumflex posteriorly. The lesser internal cutaneous nerve lies to the inner side of the vein. The chief branches given off are the *subscapular*, which arises at the lower border of the subscapularis muscle, and runs down and back along the posterior fold of the axilla with the long subscapular nerve; the *anterior circumflex*, which passes out across the surgical neck of the humerus below the biceps and coraco-brachialis; the *posterior circumflex*, which passes with the circumflex nerve backwards through the *quadrilateral space*, bounded by the subscapularis above, teres major below, long head of the triceps internally, and surgical neck of the humerus externally, to supply the deltoid, shoulder-joint, and humerus.

Ligature of the third part is performed through an incision along the line of the vessel (at the junction of the middle and anterior thirds of the axilla), which should not extend beyond the lower border of the *teres major*. The superficial tissues are divided, *coraco-brachialis* retracted outwards with musculo-cutaneous nerve; the median nerve is also drawn out, the vein and internal cutaneous nerve drawn in, and the vessel ligatured between the subscapular and circumflex branches. Anastomosis is between the branches of the axillary and those of the thyroid axis. A muscular slip from the *latissimus dorsi* to the *pectoralis major*, *coraco-brachialis* or *biceps* sometimes exists, crossing the third part of the vessels obliquely, which might be mistaken for the *coraco-brachialis*. The axillary artery is frequently affected by *aneurism*, owing to its nearness to the heart, its abrupt curve, and the communication of movements to it from the arm, by which it may be injured. Such aneurisms frequently grow rapidly, and may press on the cords of the brachial plexus and on the axillary vein.

The AXILLARY VEIN is formed by the junction of the basilic with the *venæ comites* of the brachial artery. This junction frequently occurs at the lower border of the *subscapularis* muscle, rendering the vein shorter than the artery. Sometimes *venæ comites* may continue close up to the clavicle, many cross branches existing. As the *costo-coracoid* membrane is adherent to the vein above, maintaining it in a patent condition, it bleeds very freely when cut, and is also liable to suck in air on inspiration. The vein is more often wounded than the artery, but the latter is more liable to injury from traction on the upper limb. The relation of the vein to the first part of the artery varies according to the position of the limb, being inside and a little in front when the limb hangs by the side, and almost entirely in front when the arm is at right angles to the trunk. The glands of the deep axillary group are situated along its antero-internal aspect, and are closely associated with it, rendering their removal in cases of advanced carcinoma difficult, and sometimes necessitating removal of a portion of the vein itself. The lesser internal cutaneous nerve lies along its inner side at the lower part of the space, and it receives the cephalic vein a short distance below the clavicle.

The BRACHIAL PLEXUS is derived from the fifth to the eighth cervical and first dorsal nerves, and emerges between the scalenus anticus in front and the scalenus medius and posticus behind. The fifth and sixth cervicals unite, as do the eighth cervical and first dorsal, forming thus three cords; and these again divide each into two at the level of the entrance of the axilla. The outer cord is formed of the anterior divisions of the fifth, sixth, and seventh cervicals; the inner of the anterior divisions of the eighth cervical, and nearly all of the first dorsal; and the posterior of the posterior divisions of all the cervical nerves involved. The *outer cord* gives off the external anterior thoracic, musculo-cutaneous, and outer head of the median; the *inner* gives off the inner head of the median, ulnar, internal cutaneous, lesser internal cutaneous, and internal anterior thoracic; the *posterior* gives off the circumflex, subscapular, and musculo-spiral. The median is the nerve most frequently damaged by *wounds* of the axilla, and the musculo-spiral the least. In severe traction the connection with the spinal cord is the part most likely to give way.

The LYMPHATIC GLANDS are classified in four groups: (1) Anterior pectoral group (5 or 6), lying behind the anterior axillary fold, on the serratus magnus. These drain the pectoral region, outer two-thirds of the mammary gland the antero-lateral chest, and abdominal wall. (2) Central group (10 to 15), lying under the axillary fascia, and draining the upper limb. (3) Posterior subscapular group (5 or 6), lying along the posterior axillary fold, with the subscapular artery and long subscapular nerve. (4) Deep group (6 to 10), lying along the axillary vessels, and draining the upper limb, and communicating with the glands of the neck and mediastinum, and other axillary glands. The infraclavicular glands, consisting of a few between the pectoralis major and the deltoid, between the pectoralis major and minor, and along the acromiothoracic artery, drain the outer side of the arm, shoulder, and part of the breast. The axillary glands are regularly affected secondarily in *carcinoma* of the breast, and occasionally give rise to a tumour much exceeding in size that from which it originated. They may also become enlarged from *tubercular* and *syphilitic* affections, and from *sepsis*, while they

are also occasionally the seat of *lymphadenoma* and *lymphosarcoma*.

Axillary *abscesses* may arise from a penetrating wound or from lymphadenitis. When the abscess is superficial to the costo-coracoid membrane, it is generally small, and points either in the infraclavicular fossa or about the anterior axillary fold. An abscess under the pectoralis minor or costo-coracoid membrane generally arises from gland infection, or disease of the shoulder-joint or rib. It cannot pass forwards, owing to the pectoralis minor and costo-coracoid membrane; backwards, owing to the insertion of the serratus magnus to scapula; inwards, owing to the chest-wall; outwards, owing to the arm; downwards, owing to the axillary fascia; and therefore, after pressing on the axillary fascia, and rendering it convex externally, instead of concave, it tends to pass up into the neck, and possibly to the mediastinum. Sometimes the pus may travel down the arm along the vessels. In *opening* axillary abscesses the incision should be made midway between the anterior and posterior axillary folds, so as to avoid the long thoracic and subscapular vessels, and at the thoracic rather than the humeral side, so as to avoid the large vessels. The external mammary artery, however, might possibly be wounded by this incision.

THE ARM—SURFACE ANATOMY.—The region of the arm extends from the axilla to the elbow. The contour varies according to the muscular development, being cylindrical where the development is poor, but flattened from side to side where the muscles are well developed, and displaying the prominent mass of the biceps in front. On either side of the biceps is a *sulcus*, that on the *inner* being the more marked, and extending from the front of the elbow to the posterior axillary fold. It indicates generally the course of the basilic vein and axillary vessels, and separates the biceps and coracobrachialis from the triceps above, and the biceps from the pronator radii teres below. The *external sulcus* extends from the bend of the elbow to the insertion of the deltoid, indicates so much of the course of the cephalic vein, and separates biceps and brachialis anticus from triceps above, and biceps from the supinator longus and radial extensors below. The *insertion of the deltoid* marks the centre of the humeral shaft where the cylindrical upper joins the lower prismatic portion,

and the nutrient artery enters the bone. About this level the superior profunda artery and musculo-spiral nerve cross the back of the bone, and the coraco-brachialis is inserted and the brachialis anticus takes origin. The *course of the brachial artery*, and also of the *median nerve*, is shown by a line drawn from the junction of the anterior and middle third of the outlet of the axilla to the centre of the bend of the elbow, when the limb is extended and supinated. The same line indicates the course of the *ulnar nerve* in the upper third, after which it runs down and backwards with the inferior profunda artery to the posterior aspect of the internal condyle. The artery is superficial, can be easily felt and compressed by pressure (out and backwards in upper two-thirds and backwards in lower one-third) against the humerus, and when atheromatous, is frequently visible pursuing a tortuous course just under the superficial tissues. The *musculo-spiral nerve* follows the line of the artery for a short distance, and then descends obliquely outwards across the back of the arm to the external bicipital sulcus, which it reaches about 1 inch below the insertion of the deltoid, and follows to near the external condyle.

The SKIN of the arm is thin, smooth, and very mobile in front and on the inner side, but thicker and more adherent on the outer and posterior aspects. The skin of the front of the arm is used in Tagliacozzi's plastic operation for restoration of the nose. The looseness of the skin allows of its being easily drawn up by hand in circular amputation, and large flaps may be torn up in various injuries.

The loose fatty SUBCUTANEOUS TISSUE is directly continuous with that of the axilla and forearm, and thus inflammatory infections easily spread from one region to the other. In this tissue lie the *superficial veins* (cephalic on the outer and basilic on inner side), small arterial twigs, superficial lymphatics, and *supracondyloid lymphatic gland* (the latter about 2 inches above the elbow and immediately behind the internal bicipital sulcus), and superficial nerves—intercosto-humeral, lesser internal cutaneous, branches of the musculo-spiral and internal cutaneous.

The DEEP FASCIA is continuous with that of the axilla and forearm, and forms a complete investing sheath, which is thin in front but thick behind, especially over the lower part

of the triceps. It sends in outer and inner *intermuscular septa* to the supracondyloid ridges of the humerus, thus dividing the arm into anterior and posterior compartments, of which the *anterior* contains all the muscles except the triceps, the brachial vessels, basilic vein, median, internal cutaneous, and musculo-cutaneous nerves. The *posterior compartment* contains the triceps, while the superior profunda artery and musculo-spiral nerve, the inferior profunda artery and ulnar nerve, and the anastomotica magna are common to both compartments. While various effusions tend to be limited by these compartments, they may pass from one compartment to the other by following these perforating structures.

The BICEPS MUSCLE is occasionally ruptured, the long head frequently giving way, the muscle then causing a prominent swelling in the middle of the arm when contracted, while the arm is weakened. In such cases the humeral head tends to be displaced upwards toward the coraco-acromial arch. Sometimes the tendon of the long head is displaced, generally inwards, from its groove, the head of the bone again tending to be drawn up. In some cases of *rheumatoid arthritis* the intracapsular portion of the tendon has been destroyed by friction, the lower portion acquiring an attachment to the bicipital groove. While the biceps muscle is free, the brachialis anticus is attached to the bone, and hence in amputating the former retracts more markedly than the latter. Where the muscles are well developed the biceps may considerably overlap the brachial artery.

The BRACHIAL ARTERY extends from the lower border of the teres major to the bend of the elbow. At first it lies to the inner side, but ultimately lies in front of the humerus. It is superficial save near its termination, where it dips under the bicipital fascia, between the supinator longus and pronator radii teres. Along with the venæ comites and median nerve, it is surrounded by loose connective tissue, in which lie the *deep lymphatics* of the limb. Externally the vessel is in relation to the coraco-brachialis above and biceps below, while it lies from above downwards on the long and internal heads of the triceps, coraco-brachialis insertion, and brachialis anticus. In its upper part it is surrounded by nerves, the median lying in front and external, the ulnar and internal cutaneous internally, and musculo-spiral behind. The

median nerve remains in close relationship, but crosses in front of the artery at the middle of the arm to the inner side. The *ulnar nerve* leaves the artery in the middle third of the arm, and piercing the internal intermuscular septum along with the inferior profunda, descends in the triceps to the interval between olecranon and internal condyle posteriorly. The *internal cutaneous nerve* also accompanies the artery in the upper third, and then, piercing the brachial aponeurosis, divides into superficial, anterior, and posterior branches. The *musculo-spiral* nerve soon leaves the artery, and inclines back and outwards behind the humerus in the musculo-spiral groove, along with the superior profunda artery. At the outer border of the humerus it pierces the external intermuscular septum, and descends in the anterior compartment between the brachialis anticus and extensor carpi radialis longior. The close relationship of the brachial vessel to various nerves, and particularly the median, explains the *pain* frequently caused by the application of tourniquets. The musculo-spiral nerve is frequently damaged by contusion and fracture, the latter damaging the nerve either at the time of injury or by subsequent callus. It is frequently *paralyzed by pressure*, as in sleeping with the arm over the back of a chair, and in *crutch paralysis*, the ulnar suffering next most frequently.

The artery is accompanied by *venæ comites*, the inner being generally the larger, connected by numerous branches, crossing the vessel both in front and behind. At the elbow the vessel is crossed by the *median basilic vein*, the bicipital fascia intervening. In the lower part of the arm the *basilic* lies above the artery, separated from it by the deep fascia, while in the upper part of the arm the basilic vein pierces the deep fascia, and lies internal to the artery. The chief branches of the artery are the two *profunda arteries* already described, the former arising about $1\frac{1}{2}$ inches behind the commencement of the artery, and the latter about the middle of the arm; the *nutrient branch*, given off about the centre of the arm, but sometimes from the superior profunda; the *anastomotica magna*, given off 2 inches above the elbow, which runs in across the brachialis anticus behind the median nerve, and bifurcates into the anterior and posterior branches. There are also numerous small *muscular* branches.

The vessel is not often *wounded*, owing to its protected position.

Abnormalities are of sufficient frequency to require attention. Most frequently, when abnormal, the brachial artery divides in the upper third of the arm, the two vessels then running together to the elbow, where they become radial and ulnar, or one may divide into radial and ulnar, and the other form a common interosseous. Frequently one of the two brachial arteries (the *vas aberrans*) lies superficial to the median nerve, and lower down may pass, along with the nerve, under a process of bone arising from the inner side of the humerus, 2 inches above the epicondyle, called the *supracondyloid process*.

LIGATURE OF THE BRACHIAL artery may be required for injury to the vessel itself, or its larger branches in the forearm or hand, and is most frequently performed in the *middle* of the upper arm. An incision $2\frac{1}{2}$ inches long is made in the line of the artery, the limb being held abducted, and not supported underneath, as the triceps is then apt to be pushed forward and simulate the biceps. Skin, superficial and deep fascia are cut through, the biceps and coraco-brachialis and median nerve are drawn outwards, the ulnar nerve and basilic vein, if seen, kept to the inside, and the vessel ligatured. A large inferior profunda has been mistaken for the main vessel, and the median nerve lying on the vessel and receiving communicated pulsation from it might similarly be mistaken. Ligature in the *upper third* is similar, the basilic vein, ulnar and internal cutaneous nerves being displaced inwards, and the coraco-brachialis and median nerve outwards. Ligature at the *bend of the elbow* is done through an oblique incision along the inner border of the biceps tendon, the superficial tissues being divided, the median basilic vein drawn inwards, the bicipital fascia divided as far as is necessary, and the artery thus isolated and ligatured. The median nerve here lies to the inside, at the junction of the inner and middle third; the biceps tendon lies outside the artery, which lies at the centre of the elbow; and the musculo-spiral nerve lies outside it, at the junction of the outer and middle third. There is a free *anastomosis at the elbow* between the profunda vessels and *anastomotica magna* above, and the anterior and posterior ulnar recurrents, radial recurrent, and interosseous recurrent

below. Where ligature is performed above the profunda vessels, the *anastomosis* occurs between the circumflex vessels above and the ascending branches of the superior profunda below.

The **HUMERUS** is cylindrical above its centre, then prismatic, and finally flattened antero-posteriorly, presenting marked lateral supracondyloid ridges, which give attachment to the intermuscular septa. The principal *nutrient foramen* is situated on the inner side, about the centre of the shaft, and is directed downwards for about 2 inches before opening into the medullary cavity. Sometimes, however, the foramen is situated posteriorly in the musculo-spiral groove, the nutrient vessel then coming off the superior profunda. A rough elevation at the middle of the outer side indicates the position of the insertion of the deltoid (*deltoid tubercle*), and the *musculo-spiral groove* is evident on the posterior aspect. As already pointed out, the internal condyle indicates the direction of the articular facet of the head, and the external condyle is in the same straight line as the great tuberosity. These points are of importance in relation to dislocation, fractures, and excisions. Above the insertion of the deltoid most of the muscles surrounding the humerus do not possess osseous insertions, and thus retract readily when cut, whereas below that point the triceps and brachialis anticus do not retract much when cut, owing to their osseous attachments. The upper end of the humerus presents the hemispherical head, shallow anatomical neck, the two tuberosities, and the surgical neck. The *surgical neck* is that portion which lies below the tuberosities, but above the insertions of the latissimus dorsi and teres major muscles.

The *circumflex nerve and posterior circumflex artery* emerge from between the two teres muscles, and wind horizontally round the bone at the surgical neck. The nerve supplies the joint, the deltoid and teres minor muscles, and the skin over the lower two-thirds of the shoulder and upper part of the triceps, thus securing agreement between the moving force and the parts moved. This distribution of the circumflex nerve is an illustration of *Hilton's Law*:—A nerve trunk, supplying a given joint, also supplies the muscles moving that joint, and the integument covering their insertions. The nerve may be damaged by injury to the shoulder, and more frequently by fracture of the surgical neck or disloca-

tion, particularly backwards, or by tumours of the upper end of the humerus. It may also be affected by neuritis from affections of the shoulder-joint. In all these cases paralysis of the deltoid is apt to result.

Fractures of the Humerus.—Those which occur at the UPPER END may be classified as (a) anatomical neck; (b) through the tubercles; (c) separation of the upper epiphysis; (d) surgical neck.

(a) *Anatomical Neck.*—This is a rare form of fracture. As the capsule extends beyond the anatomical neck below, this fracture is partly intracapsular. If entirely separated, the head dies; but if it is impacted into the broad upper end of the shaft, or the reflected fibres from the capsule remain intact, it may live. The deltoid may be slightly flattened, and the upper end of the lower fragment projected slightly forwards and inwards.

(b) *Fractures through the tubercles* frequently cause but little displacement, owing to the broad bone surfaces and the muscular insertions through which the fracture passes. There are *three epiphyses* for the upper end of the humerus—one for the head, and one for each tuberosity, which fuse together about the fifth and join the shaft about the twenty-first year.

(c) *Separation of the upper epiphysis* occurs just about the position of fracture through the surgical neck. Displacement is generally slight owing to the broad surfaces, the upper end of the lower fragment perhaps forming a slight projection below the coracoid process. Marked shortening is apt to follow this fracture, as the humerus grows chiefly from this upper epiphysis.

(d) *Surgical Neck.*—Fracture in this situation is fairly common, and impaction may occur, the lower being driven into the upper fragment. While there may be a tendency for the upper fragment to be abducted and rotated outwards by the spinati and teres minor muscles, and for the upper end of the lower fragment to be drawn upwards by the deltoid, biceps, coraco-brachialis, and triceps, and inwards and forwards by the great pectoral, there is often little or no displacement.

The shaft ossifies from a single centre, and is partially ossified at birth. FRACTURES OF THE SHAFT may be classified according as they occur above or below the insertion of the

deltoid. They are generally due to direct violence, and displacement depends more upon the fracturing force than on muscular action. In fracture *above the insertion of the deltoid* the lower end of the upper fragment is drawn in by the pectoralis major, teres major, and latissimus dorsi, while the upper end of the lower fragment is drawn up by the biceps, coraco-brachialis, and triceps, assisted by the deltoid, which also throws it outwards. In fracture *below the insertion of the deltoid* the tendency to displacement from muscular action is less than in that above the deltoid insertion. The lower end of the upper fragment is carried outwards by the deltoid, and the upper end of the lower fragment upwards by the biceps and triceps. Fracture by *muscular action* occurs generally below the insertion of the deltoid. These fractures of the shaft are stated to be very frequently followed by non-union, but this is probably due to the use of faulty apparatus, which does not fix the shoulder and elbow joints, and to dipping of muscular tissue between the broken ends. The most common *complication* of fracture of the shaft is drop-wrist, due to *injury* to the *musculo-spiral nerve*, either at the time of the accident or subsequently from involvement in callus.

FRACTURES OF THE LOWER END OF THE HUMERUS.—

(a) Transverse supracondyloid; (b) T-shaped fracture; (c) fractures of condyles; (d) separation of lower epiphysis. All of these fractures occur more frequently in young subjects.

(a) The *transverse supracondyloid* explains itself. It is generally oblique from above and behind, downwards and forwards, and results generally from a blow on the elbow; the lower fragment, with the bones of the forearm, is displaced backwards and upwards, the triceps, biceps, and brachialis anticus assisting.

(b) In the *T-shaped fracture* there is, in addition to the transverse fracture described in (a), a vertical limb, which runs down between the condyles into the joint. It also is generally produced by falling on the elbow, which is flexed.

(c) In *fractures of the condyles* the line of fracture generally lies above the epicondyle and outside the joint, and then enters the articulation about the trochlear surface. In fracture of the *internal condyle* displacement upwards, backwards, and inwards may occur, the ulna going with the condyle. Displacement in fracture of the *external condyle*

is generally slight. The *epicondyles* may be chipped off, the internal suffering more frequently, as it exists as a distinct epiphysis until about the eighth year. Displacement is generally slight, but the ulnar nerve may be damaged by fracture of the internal epicondyle.

(d) The lower end of the humerus presents (a) an epiphysis for capitellum and outer half of trochlea. (b) One for remainder of the trochlea. (c) One for the external condyle. These unite to form the *lower epiphysis*, which forms an irregular line running between the two condyles, and unites to the shaft about the seventeenth year. The internal epicondyle has a separate epiphysis, and does not join the shaft until about the eighteenth year. The epiphysis is almost entirely within the capsule, and there is consequently in *separation* generally only slight backward displacement. As the humerus grows chiefly from the upper epiphysis, this accident is not commonly followed by much shortening, and, indeed, marked shortening does not even follow excision of the elbow with complete removal of this epiphysis, unless performed at an early age.

It is a general rule that the epiphysis toward which the *nutrient artery* is directed unites first, and also that in the foetal position, with both upper and lower extremities flexed, all the nutrient vessels point downwards. Hence, in the humerus the nutrient vessel is directed downwards, and the lower epiphysis unites first. The nutrient vessel divides into ascending and descending branches on reaching the medulla, which rapidly break up into a fine capillary anastomosis. The bone also receives blood-supply from numerous vessels entering the foramina at the extremities of the bone and from the periosteum, and all of these systems anastomose.

Acute osteomyelitis is discussed in connection with affections of the lower limb. It occasionally affects the humerus. Chronic microbic infection of long bones may be either due to *tubercle* or *syphilis*. The former generally attacks the epiphyses, causing ulceration or caries of bone, rarely invades the diaphysis, and regularly affects the joint, giving rise to tubercular synovitis, ulceration, and shedding of cartilage, sinus formation, ankylosis, etc. *Syphilis* affects bone in many ways, a chronic osteitis and periostitis, with formation of nodes on the surface of the shaft, being one of the most

common (occurs generally in tibia). The humerus may also be affected by *sarcoma*, either myeloid, spindle- or round-celled. The former type generally occurs within the ends of long bones (head of humerus), while the latter, which is much more malignant, generally begins on the surface of the shaft, probably in the periosteum. While the myeloid sarcoma may be sometimes successfully removed by a local operation, the periosteal type demands disarticulation at the shoulder.

Amputation through the arm is generally performed by a modified circular method, two short antero-posterior flaps

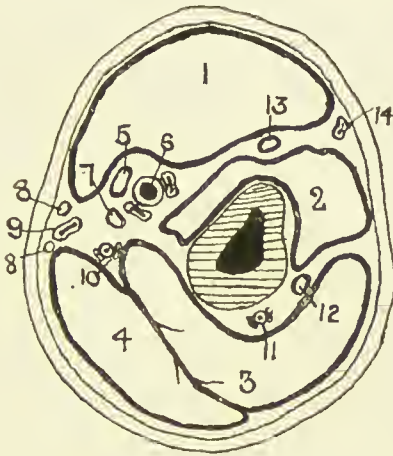


FIG. 49.—OUTLINE DIAGRAM OF TRANSVERSE SECTION OF UPPER ARM IN THE MIDDLE THIRD.

(Modified from Heath.)

- | | | |
|------------------------|-------------------------------|--------------------------------|
| 1. Biceps. | 6. Brachial vessels. | 11. Superior profunda vessels. |
| 2. Brachialis anticus. | 7. Ulnar nerve. | 12. Musculo-spiral nerve. |
| 3. Triceps. | 8. Internal cutaneous nerves. | 13. Musculo-cutaneous nerve. |
| 4. Triceps. | 9. Basilic vein. | 14. Cephalic vein. |
| 5. Median nerve. | 10. Inferior profunda vessels | |

of skin and cellular tissue ($2\frac{1}{2}$ inches long) being raised and retracted, the muscles then cut circularly, and also retracted, and then the bone cut as high up as possible. As the biceps retracts markedly, it is generally best to cut it first about the level of the skin incision, and then cut the other muscles higher up. If the amputation be about the middle of the arm, the nutrient artery may give a little trouble. In arranging the flaps the arm should be well rotated outwards, and then in the anterior segment are the biceps and brachialis anticus, with the musculo-cutaneous nerve between

them, and a small portion of the triceps; the brachial vessels, median and ulnar nerves, and inferior profunda artery. The basilic vein and internal cutaneous nerve are found about the inner border, and the cephalic vein about the outer border of the skin flap. In the posterior segment are the triceps, superior profunda artery, and musculo-spiral nerve.

THE ELBOW—SURFACE ANATOMY.—The lower end of the biceps muscle and its tendon form a tapering mass in the

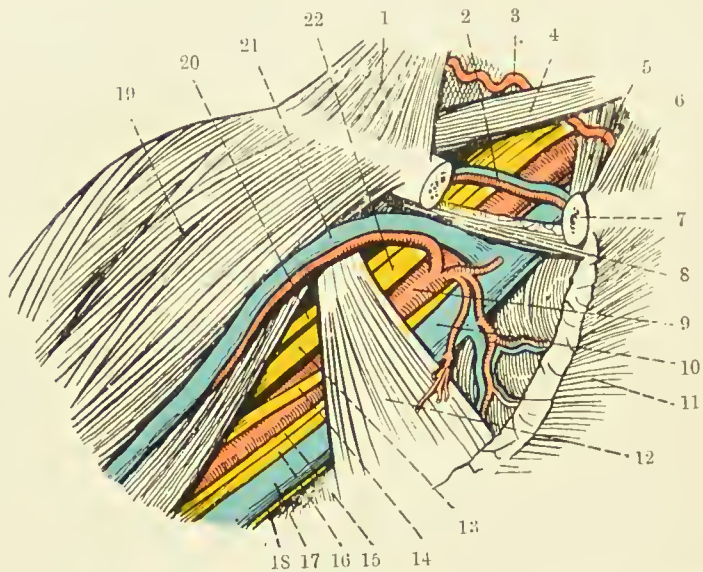


FIG. 50.—THE AXILLARY SPACE, AFTER REFLECTION OF THE PECTORALIS MAJOR; AND THE SUBCLAVIAN TRIANGLE.

(From Buchanan's "Anatomy.")

- | | |
|----------------------------------|---------------------------------|
| 1. Trapezius. | 12. Pectoralis minor. |
| 2. Suprascapular vessels. | 13. Outer head of median nerve. |
| 3. Transverse cervical artery. | 14. Inner head of median nerve. |
| 4. Posterior belly of omo-hyoid. | 15. Internal cutaneous nerve. |
| 5. Scalenus anticus. | 16. Ulnar nerve. |
| 6. Sterno-cleido-mastoid. | 17. Axillary vein. |
| 7. Clavicle in section. | 18. Nerve of Wrisberg. |
| 8. Subclavius. | 19. Deltoid. |
| 9. Axillary artery. | 20. Musculo-cutaneous nerve. |
| 10. Axillary vein. | 21. Cephalic vein. |
| 11. Pectoralis major (cut). | 22. Brachial plexus. |

centre of the elbow, and is separated by an angular-shaped hollow from a mass on the outer side, consisting of supinator longus and extensor muscles, and from a mass on the inner, consisting of pronator radii teres and flexor muscles. The diverging limbs of the angle run into the outer and inner bicipital sulci, and its apex corresponds to the point where the biceps tendon dips down to its insertion. In this position,

but external to the biceps tendon, the *median vein* of the forearm is joined by the deep median vein, and then divides into median basilic, which crosses the biceps tendon to occupy the inner sulcus, and median cephalic, which occupies the outer sulcus. The median basilic is joined by the posterior ulnar vein above the internal condyle, to form the *basilic vein*, and the median cephalic is joined by the radial vein at the level of the external condyle, to form the *cephalic vein*. More deeply placed in the inner groove are the brachial vessels and median nerve, while in the outer groove, deeply placed, are the terminations of the musculo-spiral nerve and superior profunda artery. The outer border of the biceps tendon is generally easily palpated, but the inner border is somewhat obscured by the bicipital fascia. The fold of the elbow, convex below, extends between the two condyles, a little above the joint line. The condyles form good landmarks, the internal being more prominent and less rounded than the outer, and their prominence is frequently taken advantage of in applying traction from the elbow. The olecranon is also well marked, lying nearer the internal than the external condyle. A depression between internal condyle and olecranon lodges the *ulnar nerve*, which may frequently be felt, and the posterior ulnar recurrent artery. To the outer side of the olecranon and below the external condyle is a depression, best marked when the limb is extended, in which the head of the radius may be felt, and which marks the separation of anconeus from radial extensors of the carpus and supinator longus. A line joining the two condyles is at right angles to the axis of the humerus. In extension the tip of the olecranon may lie a little above this line, but in flexion is below it, normally forming when flexed to a right angle an *equilateral triangle* with the condyles of the humerus. The line of the elbow-joint as a whole is equivalent to about two-thirds of, and is not parallel to, the intercondylar line; for while the radio-humeral joint is parallel, and is situated $\frac{3}{4}$ inch below the external condyle, the ulnar-humeral joint slopes downwards and inwards, and is fully 1 inch below the internal condyle at its inner extremity. Hence in extension the forearm is at a slight angle with the upper arm, the apex directed inwards.

The SKIN IN FRONT OF THE ELBOW is thin and mobile,

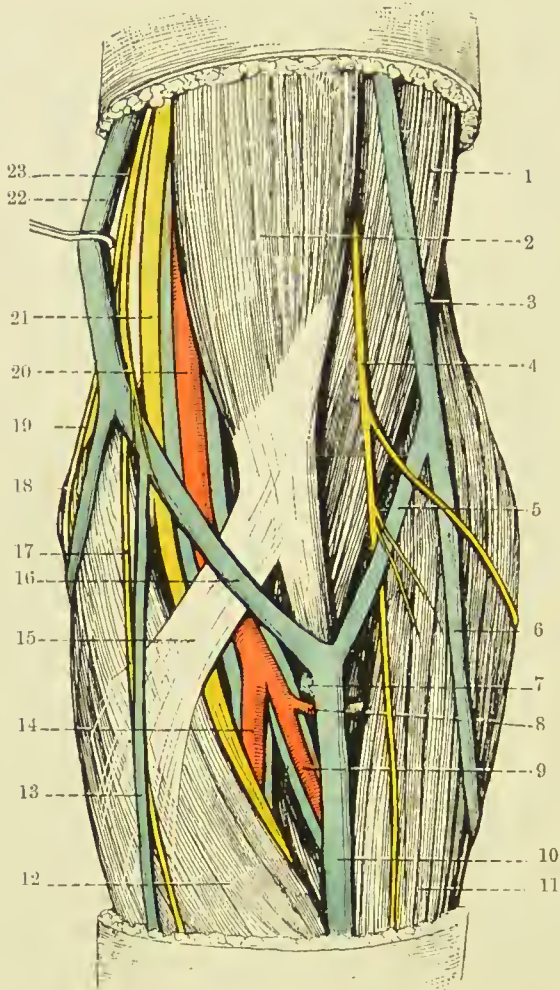


FIG. 51.—SUPERFICIAL DISSECTION OF THE FRONT OF THE LEFT ELBOW.
(From Buchanan's "Anatomy.")

- | | |
|------------------------------------|---|
| 1. Brachialis anticus. | 14. Ulnar artery and venæ comites. |
| 2. Biceps. | 15. Bicipital fascia. |
| 3. Cephalic vein. | 16. Median basilic vein. |
| 4. Musculo-cutaneous nerve. | 17. Anterior branch of internal cutaneous nerve. |
| 5. Median cephalic vein. | 18. Posterior ulnar vein. |
| 6. Radial vein. | 19. Posterior branch of internal cutaneous nerve. |
| 7. Deep median vein. | 20. Brachial artery and venæ comites. |
| 8. Radial recurrent artery. | 21. Median nerve. |
| 9. Radial artery and venæ comites. | 22. Basilic vein. |
| 10. Median vein. | 23. Internal cutaneous nerve. |
| 11. Brachio-radialis. | |
| 12. Pronator radii teres. | |
| 13. Anterior ulnar vein. | |

frequently possessing little subcutaneous fat, the superficial veins being visible through it. They may be rendered more prominent by moderate constriction of the arm. Their

arrangement, forming a capital **M** by the median dividing into median basilic and cephalic, which are joined respectively by ulnar and radial, has already been described, but the arrangement is not constant. The median basilic is the most constant and least movable of these veins, and, further, having received the blood of the deep median, is the largest, while it has also thick walls, and was therefore generally selected for *venesection* (or phlebotomy). It crosses the biceps tendon and bicipital fascia, and is thus separated from the brachial vessels and median nerve. Notwithstanding the separation, the artery used occasionally to be wounded in venesection, an *arterio-venous aneurism* resulting; and as the superficial lymphatics accompany the veins, acute lymphangitis was also not uncommon. The *lymphatic gland* lying above the internal condyle, which receives lymph from the inner side of the forearm and inner fingers, is the lowest in the upper extremity, and has already been mentioned. Injury to nerves was sometimes occasioned in venesection, the internal cutaneous, when involved, causing a neuralgia, while inclusion of filaments of the musculo-cutaneous (lying over the median cephalic) in the scar has led to reflex irritation, and contraction of the biceps and brachialis anticus, which are supplied by the same spinal segment, a flexed arm resulting. The *ante-cubital fossa* is the triangular depression in front of the elbow. Under the deep fascia lie, centrally, the biceps tendon, with the brachial artery, accompanied by its *venæ comites*, to its inner side. (The *bicipital fascia*, which covers the artery, is a strongly developed portion of the deep fascia, extending from the biceps tendon to the inner side of the arm.) To the inner side of the artery, at the junction of the inner and middle third of the elbow, lies the median nerve. Both artery and nerve are surrounded by loose fatty tissue, continuous above with that underlying the biceps, and below with that between the superficial and deep muscles of the forearm. On the outer side of the biceps tendon, at the junction of the outer and middle third of the elbow, lies the musculo-spiral nerve, dividing into radial and posterior interosseous branches, and the radial recurrent artery, anastomosing with the termination of the superior profunda. The brachial artery may be compressed by forced flexion of the elbow-joint, and aneurisms in this position have been treated by such flexion. In extreme

extension also the vessel becomes flattened and compressed, and it has been ruptured by forcible extension applied to a flexed and injured elbow.

The SKIN OVER THE BACK OF THE ELBOW is thicker than in front, and slightly corrugated, or even scaly. It possesses great freedom of movement, and presents a *bursa* over the posterior aspect of the olecranon, which is frequently affected by bursitis from pressure, constituting *student's or miner's elbow*. Subcutaneous bursting of the bursa may set up diffuse cellulitis. The *ulnar nerve* is frequently injured at the elbow on account of its exposed position, but it is

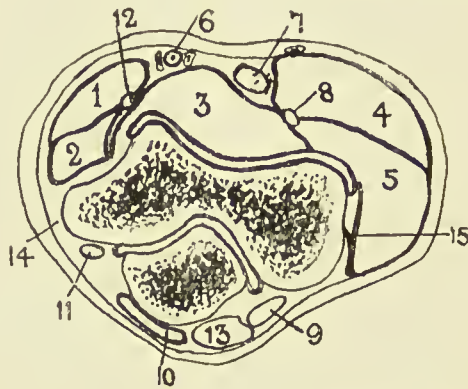


FIG. 52.—OUTLINE DIAGRAM OF TRANSVERSE SECTION OF ELBOW.
(After Braune.)

- | | | |
|--------------------------|----------------------|---------------------|
| 1. Pronator teres. | 6. Brachial vessels. | 11. Ulnar nerve. |
| 2. Flex. carpi rad. | 7. Biceps tendon. | 12. Median nerve. |
| 3. Brach. ant. | 8. Radial nerve. | 13. Triceps tendon. |
| 4. Supinator longus. | 9. Anconeus. | 14. Int. lat. ligt. |
| 5. Ext. carpi rad. long. | 10. Bursa. | 15. Ext. lat. ligt. |

occasionally covered by an accessory muscle, the *epitrochleo-anconeus*. Sometimes the nerve passes in front of the internal condyle.

The **ELBOW-JOINT** is a perfect example of a hinge, and depends for its strength chiefly upon the coaptation of the bony surfaces.

The LOWER END OF THE HUMERUS, flattened from side to side and curved with the convexity forwards, presents at the junction of the shaft and articular extremity, and above the trochlea, two fossæ—one, the anterior and smaller, named the *coronoid*; the other posterior and larger, the *olecranon fossa*. These fossæ contain a small quantity of fatty tissue, separated

from the bone by sacs of the synovial membrane, and receive the extremities of coronoid and olecranon processes in full flexion and extension respectively. The bone separating these fossæ is extremely thin, and is sometimes perforated. The articular surface proper consists of *capitellum* externally and *trochlea* internally. The former, limited to the anterior aspect of the bone, is almost hemispherical, is covered by articular cartilage, and presents above a shallow depression, the *radial fossa*, which receives the rim of the radial head in full flexion. The latter is separated from the capitellum by a shallow groove, and presents a surface marked by a deep rounded depression, which winds spirally round the lower end of the humerus from behind, down, forwards, and inwards. Further, its plane is not at right angles to the shaft, but slopes down and inwards.

The UPPER END OF THE RADIUS articulates with the capitellum by a concave depression on the head, contact being greatest in semiflexion and least on extension. The head as a whole is circular in outline, and articulates with the lesser sigmoid notch of the ulna, to which it is held by the *orbicular ligament*. The head is connected to the shaft by the slightly constricted neck.

The UPPER END OF THE ULNA articulates with the humerus by the great sigmoid cavity, to which its surface is adapted, presenting a median longitudinal rounded crest, which divides the surface into an inner portion slightly concave transversely, and an outer slightly convex transversely. The *sigmoid cavity* as a whole is roughly hemispherical, and has been likened to the Greek letter ω , owing to its frequently presenting a slight transverse ridge at the junction of the olecranon process above with the coronoid process below. The *olecranon process* is widest above, but constricted below, while the *coronoid process* presents on its outer surface the lesser sigmoid cavity by which it articulates with the radial head. The *ligaments of the elbow-joint*, consisting of anterior, posterior, and lateral, form a complete capsule for the joint. The anterior ligament is thin, and is attached to the humerus in a curved line, including the coronoid and radial fossæ, and extending thence toward the condyles, while below it is attached to the anterior margin of the coronoid process, the orbicular ligament, and the neck of the radius. It

provides origin for some fibres of the brachialis anticus. The posterior ligament is the weakest, attached above to the humerus, enclosing the olecranon fossa, and below to the superior and external aspects of the olecranon, the orbicular ligament, and neck of the radius. The subanconeus portion of the triceps is attached to it. The internal lateral ligament is the strongest, and is triangular in outline, the apex being attached to the antero-inferior aspect of the internal condyle, while the base is attached anteriorly to the inner border of the coronoid, and posteriorly to the inner border of the olecranon, and to the bony ridge between these points. The external lateral ligament extends from the external condyle to the orbicular ligament and neck of the radius. Accumulations of *fluid* in the elbow-joint show most readily through the weak anterior and posterior ligaments. Flexion of the joint is chiefly prevented by contact of the soft parts, while overextension is prevented at first by the muscles and ligaments, and not by osseous contact, and in overextension, and particularly in lateral movements, the internal lateral ligament generally suffers most.

The **superior radio-ulnar joint**, together with the inferior, permits of the movements of pronation and supination. It consists of the articulation between the lesser sigmoid cavity of the ulna and radial head, together with the ORBICULAR LIGAMENT. The latter is attached anteriorly and posteriorly to the lesser sigmoid cavity, forms four-fifths of a circle, and is cupped superiorly for the neck of the radius. A common SYNOVIAL MEMBRANE lines both elbow and superior radio-ulnar articulations. Superiorly the membrane dips into both olecranon and coronoid fossæ, and inferiorly it surrounds the upper part of the neck of the radius. The elbow-joint is a frequent seat of *tubercular disease*, swelling frequently first appearing round the margins of the olecranon, and pointing sometimes ultimately in the same region. The limb tends to become semiflexed, as this is its position of greatest capacity, while the musculo-spiral and musculo-cutaneous nerves, which supply both the joint itself and some muscles controlling its movements, may tend by reflex irritation to produce muscular rigidity. The ulnar nerve may be pressed on and produce pain, referred to the little finger and inner side of ring finger. Although the whole head of the radius is sur-

rounded by the same synovial membrane, it generally escapes infection at least until a late stage. Practically the whole lower humeral epiphysis is within the joint, but only a portion of the upper epiphysis of the ulna.

In such cases, **excision of the elbow** is performed through a vertical posterior incision, extending above and over the olecranon. The incision is made down to the bone, the soft parts are shelled to either side by a periosteal elevator, the

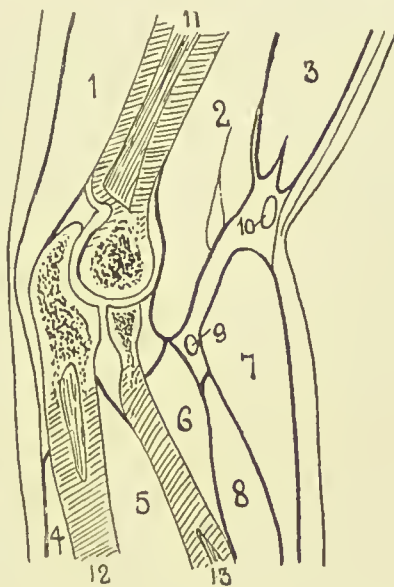


FIG. 53.—LONGITUDINAL SECTION OF ELBOW.

(After Braune.)

- | | | |
|------------------------|--------------------------|---------------------------|
| 1. Triceps. | 6. Sup. brev. | 10. Median cephalic vein. |
| 2. Brach. ant. | 7. Sup. longus. | 11. Humerus. |
| 3. Biceps. | 8. Ext. carp. rad. long. | 12. Ulna. |
| 4. Ext. carp. uln. | 9. Radial nerve. | 13. Radius. |
| 5. Flex. profund. dig. | | |

olecranon is cut off at its base, and the joint freely opened, examined, and the diseased parts removed. The head of the radius can generally be left intact, but it is desirable to remove the whole lower epiphysis of the humerus, cutting through the line of the coronoid and olecranon fossæ. In this way no external soft parts are cut, the muscles retain their attachment to the triceps aponeurosis, which has only been split, and excellent movement is obtained, pronation and supination, flexion and extension, being generally perfect.

Fractures of the lower end of the humerus have already been dealt with (see p. 401).

The OLECRANON PROCESS is generally *fractured* by direct violence, the fracture occurring through the constricted neck. As a rule, displacement is slight, owing to the dense triceps aponeurosis, but the joint is often involved from fracture, extending through the articular cartilage. In such cases it is generally best to cut down and wire the fragments. A small *epiphysis* at the apex of the olecranon, which joins the body about the seventeenth year, has occasionally been separated, considerable displacement resulting. *Fracture of the coronoid* is very rare. *Fracture of the radial head* is rare, save in severe injury, and is generally associated with dislocation. The *upper epiphysis of the radius* joins the shaft at seventeen, and is very rarely separated, being within the orbicular ligament.

Dislocations of the Elbow.—The most common form of dislocation at the elbow is one of BOTH BONES BACKWARDS. The bones generally go together, owing to the firm connection between them. They tend to be displaced back or forwards rather than laterally, owing to the weakness of the capsule, slight muscular support antero-posteriorly, and to the narrowness of the articular surface in that direction, while a forward displacement is rendered almost impossible by the large curved olecranon, the coronoid process rendering much less resistance to a backward displacement. The *cause* is generally a fall on the hand with the arm fully extended, the force producing first a hyperextension, which brings the olecranon into contact with the humerus, so as to act as a fulcrum, and lever the coronoid process away from the humerus. The upward acting force then comes into play, pushing the two bones up behind the humerus. Dislocation may also be produced by wrenching inwards of the forearm with the elbow semiflexed. The internal lateral ligament is torn, and the coronoid turned down under the articular surface of the humerus. When the dislocation is complete, the coronoid is opposite to, but not in, the olecranon fossæ; the head of the radius lies behind the outer condyle; the anterior and lateral ligaments are torn; the brachialis anticus much stretched and generally torn; the anconeus rendered very tense, as are likewise the ulnar and median nerves; and the biceps is markedly stretched over

the lower end of the humerus. In such cases the tip of the olecranon lies above the intercondylar line, notwithstanding the flexion of the limb, which generally coexists, while the head of the radius can generally be detected posteriorly behind the external condyle, and the rounded extremity of the humerus felt anteriorly. Even in the not infrequent *incomplete dislocation* of both bones backwards, the relationship of the olecranon to the condyles is a good guide to the condition.

LATERAL DISPLACEMENTS OF BOTH BONES are much less common, are generally incomplete, and are more frequently outwards than inwards, owing to the marked projection downwards of the humeral articular surface on the inner side. A slight lateral deviation frequently accompanies the backward displacement. Dislocation of *both bones forwards* is very rare. When a *single bone is dislocated*, it is generally the RADIUS which is affected, owing to its slight connection to the humerus, its greater mobility, and its greater connection with the hand. It is most often DISPLACED FORWARD by jerks of the forearm, the anterior ligament of the elbow-joint and the orbicular ligament giving way. The radial head then lies in front of the external condyle, producing an abnormal fulness, and flexion and supination are both interfered with.

A SPRAIN OF THE ELBOW, or 'pulled elbow,' is a somewhat similar condition frequently met with in young children, where, owing to a sudden jerk of the arm, the radius is pulled out of the orbicular socket. The limb then lies in a position of slight flexion and pronation, and supination is impossible. The radius may also be displaced backwards or outwards. When the ULNA is dislocated alone, it is always *backwards*. The condition is very rare.

THE FOREARM—SURFACE ANATOMY.—The forearm, when well developed, is oval in section in the upper third, but slightly flattened anteriorly, and more convex posteriorly. In the middle third it is more nearly circular, while near the wrist it becomes flattened antero-posteriorly. In women and children, however, the limb is rounded. The *course of the radial artery* is represented by a line from the middle of the bend of the elbow to the styloid process of the radius. Where the limb is well developed, a shallow sulcus follows this course, which indicates the separation between the radial extensors

and supinator longus on the outer side, and the flexors and pronator radii teres on the inner. The *radial pulse* is easily felt at the lower part of this sulcus, the vessel lying on the radius between the styloid process and the tendon of the flexor carpi radialis. The *course of the ulnar artery* in its lower third is represented by a line from the internal condyle to the radial side of the pisiform. The upper third curves up and outwards to meet the radial at the middle of the bend of the elbow.

The posterior surface is narrower than the anterior, and is limited internally by the *ridge of the ulna*, which is subcutaneous from the olecranon to the styloid, and externally by the radius, which is superficial in its lower half, but is obscured by muscles in the upper half. A sulcus, however, frequently exists, which indicates the position of the radius, and separates the supinator longus and radial extensors from the extensor communis digitorum. The extensor muscles of the thumb form a slight projection as they cross the lower end of the radius.

The SKIN on the front of the forearm is thin, delicate, and sufficiently transparent to exhibit the underlying veins, while on the posterior aspect it is thicker and covered with short hairs. The SUBCUTANEOUS TISSUE is continuous with that of the arm, contains a varying amount of fat, and is traversed by the superficial veins, lymphatics, and sensory nerves. The chief VEINS are the radial, median, and anterior and posterior ulnar, and the LYMPHATIC VESSELS accompany them. The *internal cutaneous NERVE* supplies the ulnar border both in front and behind; the *musculo-cutaneous* supplies the radial border both anteriorly and posteriorly, but is assisted posteriorly by a branch of the *musculo-spiral*. The DEEP FASCIA is directly continuous with that of the arm and hand, and forms a complete investment for the limb. In front it receives the bicipital fascia, and behind is reinforced by the triceps aponeurosis. It is attached above to the olecranon process and condyles of the humerus; at the wrist it is continuous with the anterior and posterior annular ligaments; and by its deep surface it gives attachment to several muscles, and sends in intermuscular septa, which are attached to the bones.

The MUSCLES consist of anterior, antero-external, and posterior groups. The *anterior group* arises from the internal con-

dyle, and consists of a superficial and a deep set. The superficial muscles, from without inwards, are the pronator radii teres, flexor carpi radialis, palmaris longus, flexor sublimis digitorum, and flexor carpi ulnaris. The deep set consists of the flexor profundus digitorum, flexor longus pollicis, and pronator quadratus (which rises from the lower quarter of the anterior surface of the ulna). These muscles are supplied by the *median* and its anterior interosseous branch, except the flexor carpi ulnaris and inner half of the flexor profundus digitorum. The *antero-external set* arise from the external condyle and supracondylar ridge, and include the supinator longus, the long and short radial extensors of the carpus, and supinator brevis. The two former are supplied by the *musculo-spiral*, and the two latter by its posterior interosseous branch. The *posterior muscles* consist of superficial and deep sets. The former comprise the extensor communis digitorum, extensor minimi digiti, extensor carpi ulnaris, and anconeus; the latter the extensor ossis metacarpi pollicis, extensores brevis and longus pollicis, and extensor indicis. All these muscles are supplied by the posterior interosseous branch of the *musculo-spiral*, except the anconeus, which is supplied by a special branch of the musculo-spiral.

The **MEDIAN NERVE** passes between the two heads of the pronator teres, and compression between these may explain occasional cramp of the flexor muscles after violent exercise. It then runs down the centre of the limb between the superficial and deep muscles. The **ULNAR NERVE** enters the limb between the two heads of the flexor carpi ulnaris, and runs directly from the internal condyle of the humerus to the radial side of the pisiform bone.

The **ULNAR ARTERY** is the larger of the brachial terminal branches. Its line has already been given. It lies at first deeply under the superficial muscles on the flexor profundus, and is crossed by the median nerve, the deep head of the pronator teres intervening. It is accompanied by venæ comites, and continues to lie on the flexor profundus, but becomes more superficial, the flexor sublimis lying to its outer, and the flexor carpi ulnaris and ulnar nerve to its inner side. It gives off anterior and posterior ulnar recurrents to the anastomosis at the elbow, the common interosseous, and the anterior and posterior ulnar carpals.

The *common interosseous* arises close to the origin of the ulnar, and divides into *anterior* and *posterior interosseous* arteries, the former, accompanied by *venæ comites* and the *anterior interosseous nerve* (median), lying in front of the interosseous membrane, between the *flexor profundus* and *flexor longus pollicis*, and supplying the *nutrient vessels* to ulna and radius. At the upper border of the *pronator quadratus* it passes to the posterior surface, and joins the anastomosis at the wrist. The *posterior interosseous* passes to the posterior surface, between the upper border of the interosseous membrane and the oblique ligament, and soon runs between the superficial and deep muscles, to finally anastomose with the anterior interosseous. It gives off the *interosseous recurrent* to the elbow anastomosis.

The course of the **RADIAL ARTERY** has also been given. The *supinator longus* lies to its outer side, and at first overlaps it; the *pronator teres* above and the *flexor carpi radialis* below lie to its inner side. It is accompanied by *venæ comites*, and the *radial nerve* lies to its outer side in the middle of the forearm. It gives off the *radial recurrent*, *anterior radial carpal*, and *superficial volar*. The *anastomosis* between the vessels in the forearm is very free, necessitating ligature of both ends of a divided vessel.

The *ulnar* may be **LIGATURED** by a 2-inch incision in line of the artery at the junction of the upper and middle third of the forearm, the interval between the *flexor carpi ulnaris* and *flexor sublimis* sought, and the vessel exposed. At the wrist a small vertical incision in the line of the artery, commencing 1 inch above the wrist, is made through superficial tissues, the interval between *flexor carpi ulnaris* and *flexor sublimis* sought, and the vessel ligatured. The *radial* is more easily ligatured at any part of its course, owing to its more superficial position. An incision is made in the line of the artery, the *supinator longus* separated from the *pronator radii teres* above, or the *flexor carpi radialis* below, and the vessel exposed and ligatured. Both *radial* and *ulnar* arteries occasionally lie immediately beneath the skin.

The **radius and ulna** lie nearer the posterior than anterior surface of the forearm, particularly in the upper third. Here, also, the muscles lie chiefly in front and on either side, whereas lower down the muscles lie chiefly in front and behind.

In compound fractures, therefore, the tendency is for the fragments to project on the posterior surface. While the ulna is wide above, and forms the chief constituent of the elbow-joint, the radius is wide below, and has a similar relation to the wrist. In the centre of the arm they are of about equal size. The INTEROSSEOUS MEMBRANE extends from 1 inch below the tuberosity of the radius to the inferior radio-ulnar articulation. Its fibres run generally down and

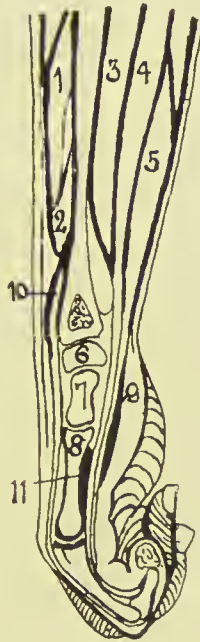


FIG. 54.—LONGITUDINAL SECTION OF FOREARM AND HAND.

(After Braune.)

- | | | |
|------------------------------|-----------------------|-----------------------|
| 1. Ext. oss. metacarp. poll. | 5. Flex. sublim. dig. | 9. Ant. annular ligt. |
| 2. Ext. prim. internal poll. | 6. Semilunar. | 10. Ext. comm. dig. |
| 3. Flex. long. poll. | 7. Os. magnum. | 11. Adduct. poll. |
| 4. Flex. profund. dig. | 8. Third metacarp. | |

inwards, and it is thicker below than above. It helps to communicate shocks received by the hand to the ulna, and thus prevent upward displacement of the radius. The *oblique ligament* connects the bones above the interosseous membrane, running from the outer border of the coronoid of the ulna down and out to the lower part of the bicipital tuberosity of the radius. It prevents the radius being driven away from the humerus. The *posterior interosseous artery*

passes between the oblique ligament and the interosseous membrane. The bones lie parallel to one another when the limb is midway between pronation and supination, and the entire interosseous membrane is then slack. In full pronation the interosseous space is narrowest, and it is widest in full supination, when it forms an irregular ellipse.

The INFERIOR RADIO-ULNAR JOINT consists of (a) an articulation between the head of the ulna and the sigmoid facet on the lower end of the radius, and (b) the articulation between the head of the ulna and the *triangular fibro-cartilage of the*

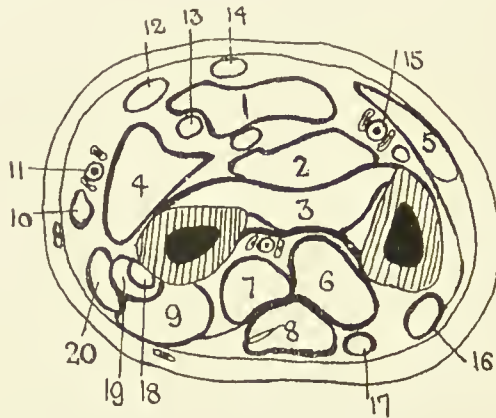


FIG. 55.—OUTLINE DIAGRAM OF TRANSVERSE SECTION OF FOREARM IN LOWER THIRD.

(After Braune.)

- | | | |
|-----------------------|----------------------|------------------------------|
| 1. Flex. sublimis | 8. Ext. comm. dig. | 15. Ulnar vessels and nerve. |
| 2. Flex. profund. | 9. Ext. brev. poll. | 16. Ext. carpi ulnaris. |
| 3. Pronat. quad. | 10. Sup. longus. | 17. Ext. min. dig. |
| 4. Flex. long. poll. | 11. Radial vessels. | 18. Ext. carpi rad. brev. |
| 5. Flex. carpi ulnar. | 12. Flex. carpi rad. | 19. Ext. carpi rad. long. |
| 6. Ext. indicis. | 13. Median nerve. | 20. Abductor pollicis. |
| 7. Ext. long. poll. | 14. Palmaris long. | |

wrist. The fibro-cartilage is attached by its base to the inferior border of the radius, and by its apex to the depression at the base of the styloid of the ulna. It binds the bones together, and separates the inferior radio-ulnar joint from the wrist. The inferior radio-ulnar joint presents weak anterior and posterior ligaments, which extend from either side of the radial sigmoid notch to the ulna and triangular fibro-cartilage. The *synovial membrane* is loose, and lines both the articulation between radius and ulna and the interspace between the lower end of the ulna and the triangular fibro-cartilage. Pronation

and supination movements take place round an axis from the head of the radius through the end of the ulna, to the fourth metacarpal. Pronation is limited by the lower two-thirds of the interosseous membrane, part of the posterior ligament of the wrist, and apposition of the bones. Supination is limited by the lower third of the interosseous membrane, the internal lateral ligament of the wrist, and contact of the posterior edge of the sigmoid cavity of the radius with the tendon of the extensor carpi ulnaris. Supination is the more powerful movement of the two.

Fractures of the Radius and Ulna.—BOTH BONES are most frequently fractured, generally as a result of direct violence, both bones breaking about the same level, in the middle or lower third. Displacement depends chiefly on the fracturing force, and may be in almost any direction. The upper fragments tend to be flexed by the biceps and brachialis anticus, and to be drawn together by the pronator radii teres, while the lower are drawn together by the pronator quadratus, and pulled up by the long flexor and extensor muscles. Both pronators tend generally to slightly pronate the radius. If the tendency to drawing together of the fragments be not corrected, cross union may result, and pronation and supination movements be lost. The use of interosseous pads for correction, however, is dangerous, and is apt to cause pain from pressure on the median nerve, and swelling, or even gangrene, from pressure on the vessels. Fracture of the radius alone is generally caused by indirect violence, as from falls on the hand; that of the ulna alone by direct violence, as when the arm is raised to defend a blow. When the RADIUS is broken *above the insertion of the pronator radii teres*, the upper fragment is fully supinated by the supinator brevis, and flexed by the biceps, which further assists the supination. The lower fragment is drawn toward the ulna, and pronated by the two pronators. As the upper fragment is small, the limb is generally best placed in flexion and full supination in treating this fracture. When the fracture occurs *below the insertion of the pronator radii teres*, the upper fragment takes up a position midway between pronation and supination, the pronators and supinators counteracting one another; is flexed by the biceps, and drawn toward the ulna by the pronator radii teres. The lower fragment is drawn toward the

ulna, and pronated by the pronator quadratus, while the supinator longus, attached to the styloid of the ulna, further tilts the upper end of the lower fragment toward the radius. Fracture of the ULNA alone generally occurs in the lower segment of the bone, and displacement is generally slight.

The LOWER END OF THE RADIUS is a favourite seat of *myeloid sarcoma*, which is sometimes treated, owing to its comparatively slight malignancy, by *removal* of the lower portion of the bone. This is perhaps best done through an incision along the radial sulcus. The lower end of the radius is the most massive part of the bone, is quadrilateral, and curved forwards. The carpal articular surface is triangular in outline, and is inclined down and forwards. Its outer portion articulates with the scaphoid, and the inner with the semi-lunar.

Colles' fracture occurs within $\frac{3}{4}$ inch of the lower articular surface, where the narrow compact shaft meets the wide and cancellous extremity. It is caused by indirect violence, generally from falls on the outstretched palm, and the displacement is caused by the fracturing force. Probably at the moment of impaction the forearm forms with the ground an angle of less than 60 degrees, and hence the force is borne by the lower end of the radius alone, which is broken off and driven backwards. Not merely is the lower fragment (*a*) displaced backwards; it is also (*b*) rotated backwards, so that the articular surface looks backwards as well as downwards. This is due to the prominence of the posterior edge of the bone receiving an undue share of the shock. (*c*) Further, the lower fragment is rotated, so that it looks down and outwards, instead of down and inwards, owing to the prominence of the radial margin of the bone receiving a great portion of the shock from the thumb, while the triangular fibro-cartilage holds the ulnar border of the fragment in position. Thus the styloid of the radius comes to be on a level with, or even higher than, that of the ulna, and the hand is thrown markedly to the radial side. Partial *impaction* generally occurs, the upper fragment being driven into the lower, which may be splintered, and the internal lateral ligament of the wrist is frequently torn, while in some cases the ulnar styloid may be broken off. When the angle of impact is over 60 degrees, the force generally travels up the bones of the forearm, and

either a sprain of the wrist or dislocation of the elbow occurs. In one or two cases, where the patient fell on the back of the hand, the position of the fragments has been reversed. Some hold that the displacement is due to muscular action—supinator longus, extensors of thumb and radial extensors—while some French authorities state that it is due to tearing of the bone by strain on the wrist ligaments. The *epiphysis* of the lower end of the radius, which includes the ulnar facet and insertion of the supinator longus, joins the shaft about the twentieth year, and is occasionally separated.

Amputation through the forearm should be performed as near the wrist as possible. In the lower part a circular, and in the upper part a modified circular, amputation, with equal antero-posterior skin-flaps, is best. After retracting the skin-flaps, the muscles, vessels, etc., are divided circularly, the interosseous membrane cut, and the bones sawn across at the same level after reflection of the periosteum. The periosteal flaps are then drawn over the cut ends, the radial, ulnar, and anterior interosseous vessels ligatured, and the wound stitched.

THE WRIST AND HAND—SURFACE ANATOMY.—Like the lower portion of the forearm, the wrist is compressed antero-posteriorly, and presents for examination anterior and posterior surfaces. The *styloid processes* of radius and ulna form prominent landmarks, separating these surfaces from one another, the styloid of the radius lying anterior to and $\frac{1}{2}$ inch below that of the ulna. Three furrows can frequently be observed on the anterior skin surface, the superior corresponding to the level of the styloid of the ulna, the middle to the wrist-joint, and the inferior to the midcarpal joint and the upper border of the anterior annular ligament. From without inwards the following structures are met with at the *front of the wrist*: First, the radial artery, which is accompanied by its venæ comites, and by the superficial volar when that vessel is given off high up ('double pulse'); then the tendon of the flexor carpi radialis, inserted into the bases of the second and third metacarpals, followed by the median nerve, which cannot be distinguished, and the tendon of the palmaris longus, which is absent in 10 per cent. of cases, and which, when present, is best rendered prominent by extending the fingers and flexing the wrist, and either closely approxi-

mating or widely separating the thenar and hypothenar eminences. The flexor sublimis digitorum lies immediately beneath the palmaris longus. Next comes the ulnar artery, with its venæ comites ; then the ulnar nerve, which grooves the radial side of the pisiform bone ; and then the flexor carpi ulnaris, which is inserted into the pisiform bone, and is rendered prominent by forcibly flexing the little finger into the palm, and slightly flexing the wrist.

On the dorsal aspect, commencing externally beyond the radial artery, there are two tendons close together, the first being the extensor ossis, and the second the extensor primi internodii pollicis, separated by a slit-like interval. About $\frac{1}{2}$ inch farther round lies the tendon of the extensor secundi internodii pollicis (extensor longus pollicis). These tendons are rendered prominent by abducting and extending the thumb. Between the two first and the third of these tendons lies a shallow triangular depression—the TABATIÈRE ANATOMIQUE—which is crossed superficially by the dorsal vein of the thumb (cephalic) and branches of the radial nerve, and deeply by the radial artery running from the wrist to the posterior extremity of the first interosseous space. The *floor of the area* is formed by the scaphoid, trapezium, and base of the first metacarpal bone, and the tendons of the extensor carpi radialis longior and brevior cross the base of the triangle, to be inserted into the bases of the second and third metacarpal bones respectively. If the tendon of the extensor longus pollicis be followed up to the radius, a small bony tubercle is met, marking the outer border of its osseous groove. Here the tendon marks the centre of the posterior surface of the radius, and roughly the interval between the scaphoid and semilunar bones. Beyond the tendon of the extensor longus pollicis comes that of the extensor communis digitorum. Further to the ulnar border lies the tendon of the extensor minimi digiti, which can be felt ; then comes the head of the ulna, which is prominent when the hand is pronated ; and, lastly, there is the tendon of the extensor carpi ulnaris, which is inserted into the base of the fifth metacarpal. The *styloid process* of the ulna becomes most distinct on supination, lying to the ulnar side of the external carpi ulnaris tendon. Its tip corresponds to the line of the wrist-joint.

The PALMAR SURFACE OF THE HAND is roughly quadrilateral

in outline and concave centrally, where the skin is adherent to the palmar fascia. This central depression is surrounded by the thenar and hypothenar eminences. At the upper extremity of the thenar eminence is a bony prominence, due to the tubercle of the scaphoid and ridge of the trapezium, while at the upper extremity of the hypothenar eminence is another bony prominence, due to the pisiform bone, with the unciform hook below it. The *anterior annular ligament* takes attachment from these points. The *opponens* and *abductor pollicis* take origin from the ridge of the trapezium, and the *flexor carpi ulnaris* is inserted into the pisiform and hook of the unciform. The *abductor minimi digiti* arises from the pisiform.

Three of the *creases traversing the palm* are of importance: The superior, starting from a point about 1 inch above the base of the index-finger, curves up and inwards, and demarcates the thenar eminence. The middle, starting from the same point, crosses the palm obliquely, to end over the hypothenar eminence, and indicates roughly the position of the *superficial palmar arch*, whose summit almost touches it in the line of the third metacarpal. The *deep palmar arch* is about $\frac{1}{2}$ inch nearer the wrist. The third furrow commences $\frac{3}{4}$ inch above the base of the little finger, and runs across toward the radial border of the palm, indicating the upper limit of the synovial flexor tendon sheaths of the three outer fingers. The *metacarpo-phalangeal joints* lie below this crease, and $\frac{3}{4}$ inch above the webs of the fingers, and about the same level the *palmar fascia* divides into four slips for the four fingers. Between these slips and opposite the webs of the fingers three small elevations, corresponding to the fatty tissue between the fascial slips, may be seen, particularly when the first phalanges are extended and the other two are flexed. The transverse creases corresponding to the metacarpo-phalangeal joints lie $\frac{3}{4}$ inch below the joints. Those at the first interphalangeal joints are exactly opposite the joints, while those at the second interphalangeal joints are a little above the joints.

The superficial PALMAR ARCH may be represented by a curved line running from the pisiform down to the middle crease opposite the third metacarpal, and then up to the tubercle of the scaphoid; while the deep arch may be represented by a

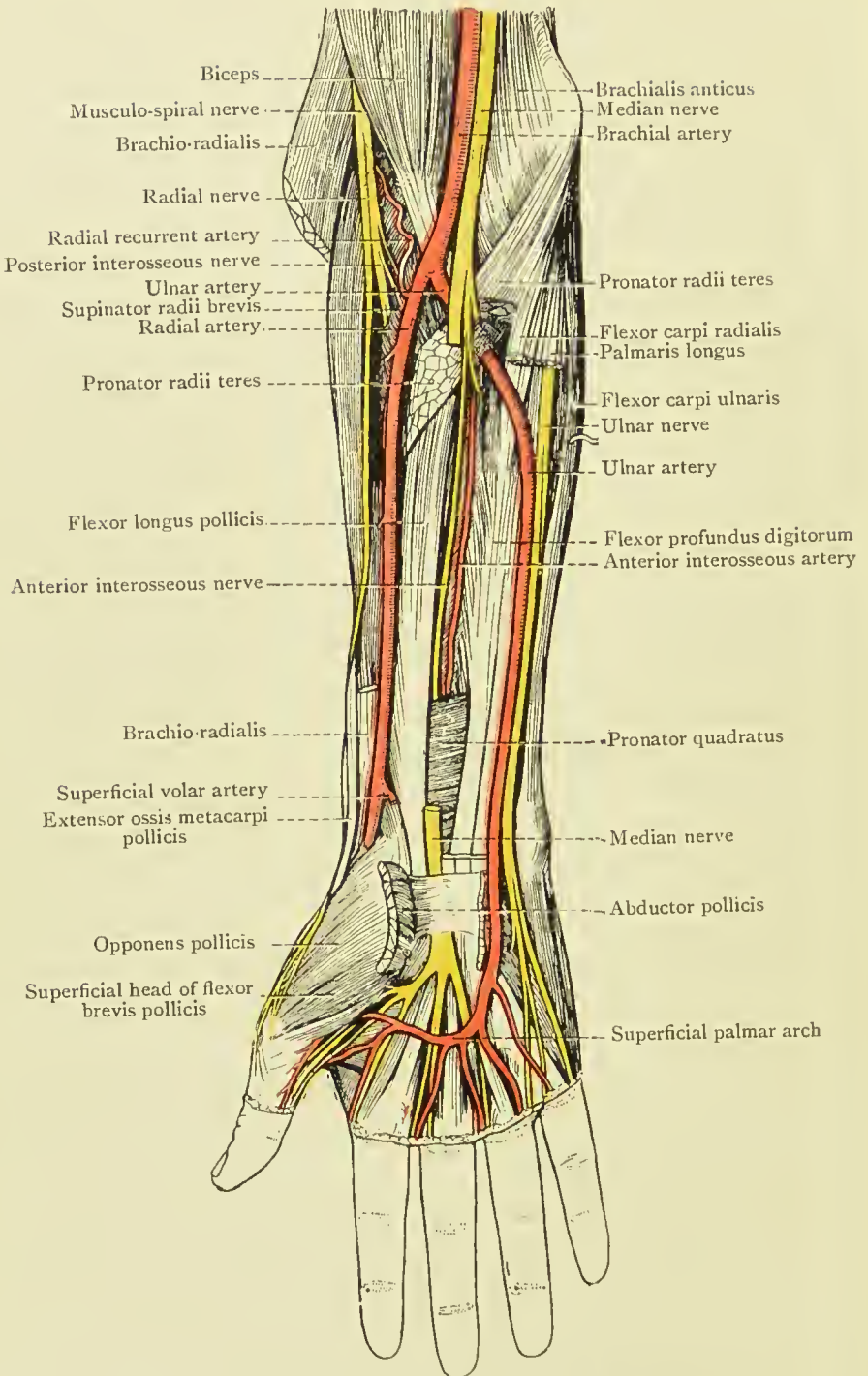


FIG. 56.—DEEP DISSECTION OF FRONT OF RIGHT FOREARM,
 AND SUPERFICIAL DISSECTION OF PALM.
 (From Buchanan's "Anatomy.")

line from the base of the fifth to that of the second metacarpal, its centre corresponding to the apex of the hollow of the palm. The *digital arteries* bifurcate about $\frac{1}{2}$ inch above the webs of the fingers.

On the DORSAL ASPECT OF THE HAND the tendons can generally be easily made out, particularly when the fingers are hyperextended. The *first dorsal interosseous muscle* is chiefly responsible for the eminence which appears when the two first metacarpal bones are firmly approximated. The prominence of the knuckles at the metacarpo-phalangeal and interphalangeal joints is formed by the heads of the proximal bones, and, therefore, when seeking to open these joints when flexed, the knife should be entered distal to the prominence.

The SKIN OVER THE BACK OF THE WRIST AND HAND is firmer than that of the palm, and freely movable. It is provided with numerous hairs and sweat-glands, and permits of the superficial veins being seen through it. *Boils and furuncles* not infrequently appear on this surface in connection with the hair or glands, but do not occur on the palm.

The SUBCUTANEOUS TISSUES are very lax, permitting great cedematous swelling and accumulations of blood or pus. The VENOUS PLEXUS forms a network on the backs of the fingers, which collects to form a *venous arch* on the back of the hand, with the convexity pointing downwards, and which leads to the radial vein on the outer side, while on the inner side it is joined by a vein from the little finger, which runs in the fourth intermetacarpal space (*vena salvatella*) to form the ulnar veins. All the larger veins of the hand are on the dorsal aspect, and most of the blood of the hand returns dorsally. The LYMPHATICS are large, and widely distributed over the dorsum. The NAILS grow about $\frac{1}{32}$ inch per week, and are frequently marked by transverse grooves in illness or from injury. They are also said to be altered in shape by some diseases, and they share in *clubbing of the finger-tips*, which occurs in certain chest affections, becoming markedly curved (Hippocratic hand). The *matrix* of the nail receives a large branch from each digital nerve, and is extremely sensitive to injury or inflammatory processes. Such inflammatory conditions affecting the matrix are referred to as *onychia* (or paronychia, when the surrounding parts are affected), and may lead to deformity or destruction of the nail, a new nail forming if the matrix survives.

THE SKIN OF THE FRONT OF THE WRIST AND HAND varies much in character. On the front of the wrist it is thin and comparatively movable, but is connected with the deep fascia. The superficial VEINS are visible through it, and the *median vein* of the forearm generally takes origin about this position. The skin over the *thenar eminence* is also thin, much thicker over the *hypothenar eminence*, and very thick over the *palm*, where, in addition, it is firmly bound down to the palmar fascia by numerous fibrous septa. The *cuticle* is thick, and both on palm and fingers presents numerous fine ridges, on which open large numbers of *sweat-glands* (2,800 per square inch on the palm). The *papillæ* of the fingers are richly supplied with *Pacinian corpuscles*, the sensation of touch being more active on the palmar aspect of the terminal phalanx of the index-finger than on any other part of the body, except the tip of the tongue. The dorsum, on the other hand, is much less sensitive, while the skin of the middle of the forearm and of the shoulders is very insensitive. There are no hairs, sebaceous glands, nor large superficial veins, and few lymphatics on the palmar aspect.

THE SUBCUTANEOUS TISSUE is dense and scanty, the fat being arranged in lobules between the fibrous septa. It is continuous with that of the forearm and fingers, and with the fatty tissue in the central compartment of the palm, between the slips of the palmar fascia. It is also continuous laterally with that on the dorsum. Over the proximal and middle phalanges it is connected with the fibrous sheaths of the flexor tendons, while on the distal extremity of the terminal phalanges it forms the *pulp of the finger*, which is intersected by numerous trabeculæ passing from the skin to the periosteum of the bone (*cutaneous phalangeal ligaments* of Cleland). These trabeculæ are of importance in suppurative affections of the terminal phalanges, as they tend to direct the process downwards from the surface to the periosteum, whereby a simple *whitlow* may give rise to a subperiosteal abscess, or paronychia, with partial *necrosis of the bone*, the epiphyseal end, to which the flexor profundus is attached, generally surviving (the epiphysis unites about the twentieth year).

THE PALMAR FASCIA is strong and unyielding, is comparatively free from vessels and nerves, and hence renders the

overlying skin suitable for withstanding pressure and friction. The intimate connection between skin and fascia also prevents gaping of wounds and accumulations of œdema or blood; indeed, when inflammation does occur in this region, it generally produces much pain from tension of the parts. The palmar fascia consists of a *stout central palmar portion*, and *two lateral expansions* to the thenar and hypothenar eminences, by which these latter are enclosed. The *central portion* is connected superficially with the skin by numerous septa, but its deep surface, lying over the flexor tendons, is smooth. Commencing above where it is continuous with the anterior annular ligament and palmaris longus muscle, it widens out as it approaches the fingers, and divides opposite the heads of the four inner metacarpal bones into four slips, which pass to the roots of the respective fingers. These again divide, and pass to the sheaths of the flexor tendons, transverse metacarpal ligaments, and skin. This fascia is so dense that suppurative processes can hardly come forward through it, but are generally forced down along the fingers, or up into the forearm, or even back on to the dorsum of the hand.

DUPUYTREN'S CONTRACTION of the palmar fascia most frequently affects the slips to the ring and little fingers, producing flexion of these fingers and wrinkling of the overlying skin when an attempt is made to straighten the fingers. The CENTRAL COMPARTMENT OF THE PALM is bounded superficially by the palmar fascia, deeply by the aponeurosis of the interossei muscles, and laterally, both at the thenar and hypothenar eminences, by the fusion of these two layers. Superiorly it narrows, and is continuous with the wrist under the anterior annular ligament, and inferiorly it widens out, being continued along the fingers by the flexor tendon sheaths, while between the fingers it communicates with the subcutaneous tissue of the palm. It contains the superficial and deep tendons in their synovial sheaths, and the lumbricales muscles, the superficial palmar arch and its branches, and the median nerve and its terminal branches. Under the central compartment is a DEEP COMPARTMENT, lying between the aponeurosis of the interossei muscles and the bones, which contains the interossei muscles, the deep palmar arch, and the deep division of the ulnar nerve.

The ANTERIOR ANNULAR LIGAMENT is attached to the

tubercle of the scaphoid and ridge of the trapezium externally, and internally to the pisiform and hook of the unciform. Above it is continuous with the fascia of the forearm, and below with the palmar fascia. It forms a tunnel with the carpal bones for the passage of the flexor tendons and median nerve to the central compartment of the hand, and gives attachment to the short muscles of the thumb and little finger. The tendon of the palmaris longus expands in front of it, and it is crossed externally by the superficial volar branch of the radial, and on the inside by the ulnar artery and nerve.

The *flexors sublimis and profundus digitorum* have a COMMON SYNOVIAL SHEATH (great palmar bursa), which, commencing fully an inch above the annular ligament, extends down under it for about the same distance, and then sends short prolongations extending to the centre of the metacarpal bones along the index, middle, and ring finger tendons. Beyond this these tendons have separate sheaths in the fingers, which begin at the necks of the metacarpal bones, fully $\frac{1}{4}$ inch above the terminations of the others, and extend to the bases of the terminal phalanges. The sheath to the little finger, on the other hand, generally goes direct to the base of the terminal phalanx, while the long flexor of the thumb has a separate sheath of its own, which commences in the forearm $\frac{1}{4}$ inch below the common sheath, and extends to the base of the terminal phalanx. Thus, a SEPTIC WOUND of the *little finger* is apt to produce a suppuration of the common synovial sheath, which might extend into the forearm, and cause impairment of movement of all the fingers. A septic wound of the *thumb* might also produce a lesion, extending up the forearm, but would only probably involve the thumb. A septic lesion of the *index*, middle, or ring fingers would probably produce a local condition, as these fingers have each a separate distal synovial sheath, which only extends up to the neck of the corresponding metacarpal bone, and does not communicate with the common sheath. Abscesses in these sheaths are sometimes referred to as *thecal*. INCISIONS for relief of abscesses may be made deeply in the middle line of the terminal phalanges; and distal to the palmar arch, over the metacarpal of the index and ring fingers particularly, without danger of cutting vessels. The sheath of the common flexor tendon

is not infrequently affected by chronic *tubercular synovitis*, extending both into the palm and up into the forearm, necessitating its free removal.

The tendons of the FLEXOR PROFUNDUS are inserted into the base of the terminal phalanges, having perforated the tendons of the FLEXOR SUBLIMIS, which are inserted into the sides of the middle phalanges. The tendons and their sheaths are

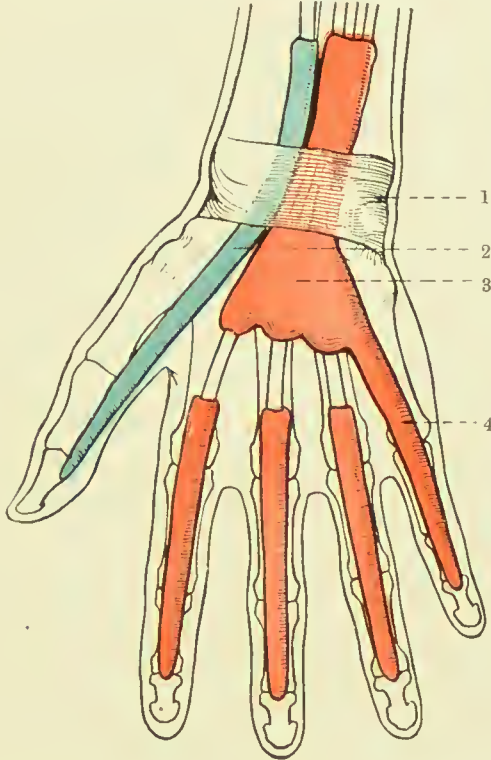


FIG. 57.—THE GREAT PALMAR BURSA, AND THE SYNOVIAL SHEATHS OF THE FLEXOR TENDONS.

(From Buchanan's "Anatomy.")

- | | |
|-------------------------------|--------------------------------------|
| 1. Anterior annular ligament. | 3. Great palmar bursa. |
| 2. Synovial sheath of thumb. | 4. Synovial sheath of little finger. |

enclosed in strong FIBROUS THECÆ, which are best developed over the shafts of the two proximal phalanges of each finger, but which are thin over the joints, pus finding its way here into the sheaths. These sheaths gape when cut, unless care be taken to close them, and may permit access of septic matter. The tendons lying within the synovial sheaths are not free, but are attached to them by practically 'mesenteric' folds, which carry the nutrient vessels to the tendons. Within

the digital sheaths these folds are replaced by the *ligamenta longa and brevia*, which are situated near the insertions of the tendons. *Rupture* of the synovial sheaths may destroy the nutrient vessels of a portion of tendon, and is generally followed by effusion. As the synovial sheaths communicate freely with the surrounding lymphatics, septic absorption takes place rapidly from them.

The LUMBRICALES arise from the outer edges of the tendons of the deep flexor, and are inserted into the fibrous expansion of the extensor tendons of the four fingers. A growth on the tendon or tendon sheath may limit the movement of a finger, preventing extension, and contractions of the finger may also result from contraction of the sheath, adhesion of the tendon to the sheath, or contraction of the muscles.

The ULNAR ARTERY, on reaching the palm, divides into superficial and deep branches, the former, with the superficial volar of the radial, forming the SUPERFICIAL ARCH, which lies in the central compartment of the hand, and gives off four digital branches, one to the ulnar border of the little finger, and the other three dividing $\frac{1}{4}$ inch above the webs to supply each side of two adjacent fingers. The DEEP BRANCH of the ulnar sinks between the abductor and short flexor of the little finger to form the DEEP ARCH with the termination of the radial.

The RADIAL ARTERY passes from the front of the wrist below the styloid process, outwards over the external lateral ligament of the wrist, and under the extensores ossis and primi internodii pollicis, to enter the tabatière, whence it passes between the heads of the first dorsal interosseous muscle to reach the palm. It gives off a posterior radial carpal to form the *posterior carpal arch* with the posterior ulnar carpal (from which arise the second and third dorsal interosseous arteries), the first dorsal interosseous artery, the dorsalis indicis, and dorsalis pollicis. As the artery is in close contact with the carpo-metacarpal joint, it is apt to be wounded in amputation of the thumb or excision of the first metacarpal. In the palm the artery forms the deep palmar arch with the deep branch of the ulnar, and gives off the arteria princeps pollicis, the radialis indicis, three palmar interossei, two or three recurrent branches to the anterior carpal arch, and three posterior perforating branches to the dorsal interosseous. The deep arch lies in the deep compartment under the flexor tendons

and interosseous aponeurosis, its lower border corresponding to the upper border of the superficial. The ANASTOMOSIS between the various vessels of the hand is so free that when a vessel is cut it is generally necessary to ligature both ends. It is often difficult to do this where the wound is of the punctured variety; and where the deep palmar arch has been wounded, it has been suggested to reach it from the dorsal aspect of the hand by resecting the proximal portion of the third metacarpal bone. The *anterior and posterior carpal arches* communicate with one another, with the interosseous vessels, and with the deep palmar arch; while the two *palmar arches*, besides being in direct communication, anastomose through the digital branches of the superficial arch, and the palmar interosseous of the deep arch, which form a rich plexus in the pulp of the fingers. Pressure applied to the palm for arrest of hæmorrhage may, nevertheless, lead to gangrene. The LYMPHATICS of the fingers are numerous and large, and lymphangitis frequently follows septic wounds.

The POSTERIOR ANNULAR LIGAMENT lies higher than the anterior, and runs obliquely from without inwards. It consists of a thickening of the deep fascia, and is attached externally to the radius and internally to the cuneiform and pisiform bones and palmar fascia. It sends in processes to the underlying bones by which six compartments are formed for (1) *extensores ossis and primi internodii pollicis*; (2) *extensores carpi radialis longus and brevior*; (3) *extensor longus pollicis*; (4) *extensor indicis and communis digitorum*; (5) *extensor minimi digiti*; (6) *extensor carpi ulnaris*. These tendons lie on the posterior ligament of the wrist-joint, which is very thin, and frequently permits small protrusions of synovial membrane from the wrist-joint. The synovial tendon sheaths commence slightly above the annular ligament, while inferiorly they are variously described either extending as shown in Fig. 58, or as follows: Below, all the sheaths extend to the insertions of the tendons, except (1), which extends to the first carpo-metacarpal joint, and (4) and (5), which extend to the middle of the metacarpus. As these sheaths are injured in Colles' fracture, fixation of the fingers is apt to occur (unless prevented by passive movement) from adhesions between tendons and sheaths. *Ganglion* is a cystic protrusion of the tendon sheaths of the back of the

hand or of the carpus which may be treated by subcutaneous rupture or small incision.

The **WRIST-JOINT** consists of the articulation between radius and triangular fibro-cartilage above, and scaphoid, semilunar, and cuneiform bones below, the upper or radial surface being concave from side to side and from before

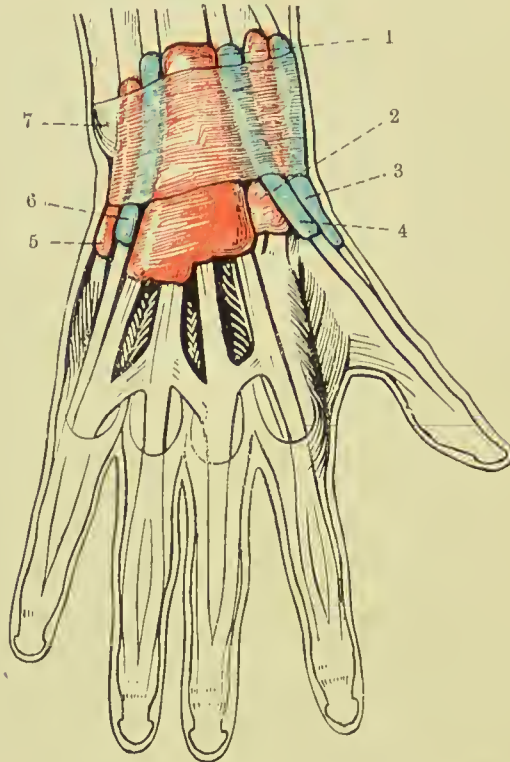


FIG. 58.—THE SYNOVIAL SHEATHS OF THE EXTENSOR TENDONS.

(After L. Testut's "Anatomie Humaine.")

- | | |
|---------------------------------|--------------------------------|
| 1. Extensor communis digitorum. | 5. Extensor carpi ulnaris. |
| 2. Radial carpal extensors. | 6. Extensor minimi digiti. |
| 3. Extensor brevis pollicis. | 7. Posterior annular ligament. |
| 4. Extensor longus pollicis. | |

backwards, the apex of the curve lying $\frac{1}{2}$ inch above a line joining the two styloid processes. It is surrounded by a CAPSULAR LIGAMENT, which is described as consisting of a strong anterior ligament, extending from the lower end of the radius, triangular fibro-cartilage, and ulnar styloid to the first and second rows of carpal bones; a weak posterior ligament, extending from the same points posteriorly to the first row

of carpal bones ; an external ligament, extending from the radial styloid to the tuberosity of the scaphoid ; and an internal, extending from the ulnar styloid to the pisiform and cuneiform bones and annular ligament.

The **midcarpal articulation** roughly conforms in outline to the wrist-joint, and possesses a capsular ligament and an extensive synovial cavity. In it the scaphoid, semilunar, and cuneiform articulate with the trapezium, trapezoid, os magnum, and unciform. There are FIVE ARTICULAR SYNOVIAL SACS connected with the carpus : (I) Radio-

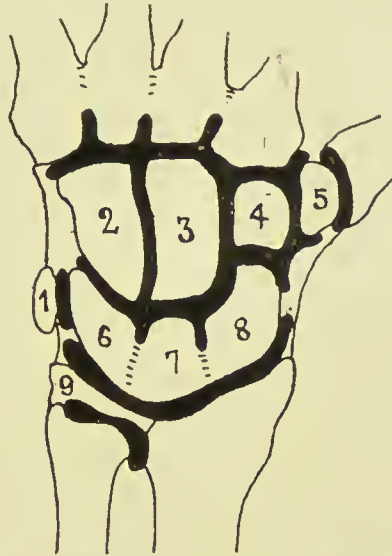


FIG. 59.—DIAGRAM OF THE FIVE SYNOVIAL MEMBRANES OF THE HAND.

- | | | |
|---------------|---------------|--------------------------------|
| 1. Pisiform. | 4. Trapezoid. | 7. Semilunar. |
| 2. Unciform. | 5. Trapezium. | 8. Scaphoid. |
| 3. Os magnum. | 6. Cuneiform. | 9. Triangular fibro-cartilage. |

carpal or wrist ; (2) midcarpal, which extends between all the bones and also to the carpo-metacarpal joints of the index and middle fingers ; (3) between the unciform and ring and little fingers—(2) and (3) are sometimes continuous, (4) between the trapezium and metacarpal of the thumb ; (5) between the pisiform and cuneiform. As just stated, the metacarpal bone of the thumb possesses a separate articulation, while these of the first two fingers always, and the last two fingers sometimes, communicate with the midcarpal joint. The wrist depends for its strength chiefly upon the strong tendons surrounding it, and is protected to an extent

by the numerous joints of the hand, which lessen shocks communicated to it, and which also prevent leverage of the joint from the distal side. It is stated that DISLOCATION of the wrist is extremely rare, but it should be borne in mind, when estimating its frequency, that it is often easily reduced, a slight pull, of the hand sufficing in some cases. The dislocation of the wrist *backwards* is much more common, probably owing to falls on the outstretched hand being the common mode of production. The hand is generally adducted to the ulnar side, whereas in Colles's fracture it is thrown to the radial side. The *movements* permitted at the wrist-joint are flexion, extension, abduction, and adduction, and, by a combination of these, circumduction. The midcarpal joint also participates to an extent in these movements. Forced extension, as in falls on the palm, is a more frequent source of injury to the wrist than forced flexion. In forced flexion of the hand the head of the *os magnum* has occasionally been displaced backwards, so as to project on the dorsum of the wrist, the ligaments being torn. The condition may simulate ganglion of the wrist. The carpus is frequently affected by *tubercular disease*, which, owing to the extensive synovial sheath, rapidly spreads to the various bones of the carpus, and not infrequently to the carpo-metacarpal joints. The ligaments of the joint and overlying tendon sheaths also become affected, and a fusiform swelling, more prominent posteriorly than anteriorly, is produced, while the hand generally remains straight. In the later stages the forearm and fingers become wasted and powerless, while sinuses form, generally posteriorly.

EXCISION OF THE WRIST may be performed in various ways, and while it is a difficult operation on the normal cadaver, it is comparatively easy in the diseased condition. A vertical incision, some 3 to 4 inches long, is made over the wrist in the line of the common extensor tendon to the index finger, that tendon being thrown to the ulnar side prior to making the incision by flexing the three inner fingers, and extending the index, when it is drawn aside by the band connecting it to the tendon of the middle finger. The incision is extended on to the lower end of the radius. The tendons of the extensor secundii internodii pollicis and extensores carpi radialis longior and brevior are drawn to the radial, and the extensor tendons

of the fingers drawn to the ulnar side, the joint is flexed, and the first row of bones is exposed and shelled out with the periosteal elevator, and then the carpo-metacarpal joints are opened, and the second or lower row of bones removed. Wherever possible the trapezium, hook of the unciform, and pisiform are left intact, as are also the lower end of the radius and ulna, the ends of the metacarpal bones, and also the tendons in their sheaths. Excellent results are obtained, even the more delicate movements of the fingers, such as apposition of the thumb and forefinger, being retained. *Amputation at the wrist* for extensive crushing or tubercular disease

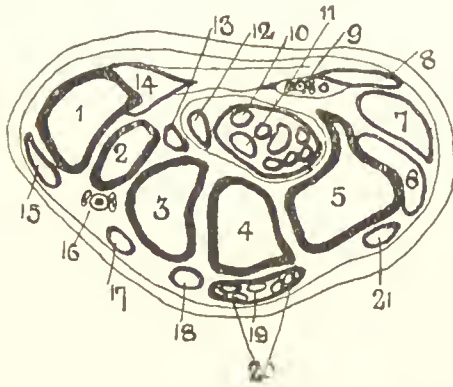


FIG. 60.—TRANSVERSE SECTION OF WRIST.

(Bellamy after Henle [Morris].)

- | | | |
|------------------------|--------------------------------|-----------------------------|
| 1. First metacarp. | 8. Palmaris brev. | 15. Ext. prim. inter. poll. |
| 2. Trapezium. | 9. Ulnar vessels and nerve. | 16. Radial vessels. |
| 3. Trapezoid. | 10. Median nerve. | 17. Ext. carp. rad. long. |
| 4. Os magnum. | 11. Flex. sublim. and profund. | 18. Ext. carp. rad. brev. |
| 5. Unciform. | 12. Flex. long. poll. | 19. Ext. indicis. |
| 6. Ext. carpi ulnar. | 13. Flex. carp. rad. | 20. Ext. comm. dig. |
| 7. Hypothenar muscles. | 14. Thenar muscles. | 21. Ext. min. dig. |

of the carpus is rarely performed. An elliptical incision planned to give a good palmar flap, beginning at the carpo-metacarpal joint of the thumb, arching across the palm to the extent of 2 inches below the wrist, and then turning up again to the pisiform, is made on the palmar surface, and is completed dorsally by an incision, with its concavity toward the fingers, and extending $\frac{1}{2}$ inch above the wrist. This incision is made through the skin and superficial tissues, and includes the superficial branches of the radial and ulnar nerves. The tendons are then cut, commencing at the radial side, and the joint is also opened at that side, so as to avoid

injury to the triangular fibro-cartilage of the wrist. Dorsally the tendons of the two radial extensors and extensores ossis metacarpi and primi internodii pollicis, together with extensores indicis, communis, minimi digiti, and carpi ulnaris, radial nerve, dorsal branch of the ulnar nerve, and radial artery are cut; while in the palmar wound the tendons of the flexor sublimis, profundus, longus pollicis, carpi radialis, ulnar artery, superficial volar, ulnar and median nerves, and parts of the short muscles of the thumb and little finger are cut.

THE THUMB AND FINGERS. — The carpo-metacarpal joints of the index, middle, and ring fingers permit of little movement, whereas that of the thumb possesses free movement, and that of the little finger a much less degree. The distal heads of the four inner metacarpal bones are bound together by the *transverse metacarpal ligament*. Flexion of the two distal phalanges, without flexing the first, is performed with the aid of the extensor tendon, which first fixes the proximal phalanx. In *extensor paralysis*, therefore, this movement is not possible. The power of flexion of the distal phalanx alone is not generally possessed, but sometimes from injury, where the extensor tendon has been ruptured from its attachment to the terminal phalanx, that phalanx becomes flexed and fixed, the condition being known as *mallet finger*. The middle finger, owing to its greater length, is most exposed to *shocks* received by the fingers, and is well adapted to resist these, as its metacarpal bone rests on the os magnum, which again communicates with the semilunar, and so with the strongest portion of the radius. Fractures of the metacarpal bones are common, the first being most frequently and the third least often affected. Fracture at the base of the first metacarpal is called Bennett's fracture ('stave of the thumb'). *Avulsion* of one or more fingers may be caused by machinery tears or bites of certain animals. In such cases not only the fingers, but also the tendons, may be dragged out from the forearm. Where only a single tendon comes away, it is generally that of the flexor profundus, but all the tendons may be so torn. As the *palmar*, or *glenoid*, *ligaments* in front of the fingers are more firmly attached to the distal than the proximal bones, they are carried with the distal bones, when *dislocated*, backwards, and cause considerable difficulty when reduction is attempted. The palmar

ligament consists of a *plate of fibro-cartilage* firmly attached to the base of the phalanx on its palmar aspect, and but loosely attached to the proximal bone. The two *sesamoid bones of the thumb* are developed in the metacarpo-phalangeal plate, and a *single sesamoid bone* is frequently developed in the metacarpo-phalangeal plate of the index finger on its radial side. In the case of the thumb the outer bone gives attachment to the abductor and outer head of the flexor brevis, while the inner gives attachment to the adductor and inner head of the flexor brevis.

A BACKWARD DISLOCATION OF THE THUMB (Hey's) at the metacarpo-phalangeal joint is not uncommon, being caused generally by forcible hyperextension, and presents considerable difficulty in reduction. This difficulty has been variously attributed to the backward displacement of the plate of fibro-cartilage forming the palmar ligament, which has just been mentioned as causing difficulty in the fingers, and which carries with it the short muscles attached to the sesamoid bones ; to entanglement of the long flexor tendon ; locking of the metacarpal bone between the lateral ligaments, or heads of the flexor brevis, etc. To *reduce the dislocation* it is advised to extend the phalanx till at right angles to the metacarpal bone, and while in this position, to carry the base of the phalanx over the metacarpal head, and then to flex the phalanx suddenly. *Subcutaneous section* of the palmar ligament from the extensor aspect is said to permit of easy reduction. *Amputation of the thumb* with its metacarpal bone is best done through a vertical incision over the subcutaneous radial border of the metacarpal bone. The metacarpal bone is excised subperiosteally, and the finger removed by an elliptical incision at the lower end of the vertical one. *Amputation of the fingers* is frequently performed at the *metacarpo-phalangeal* or interphalangeal joints. In the former position a racket incision is generally best, taking care to keep the racket distal to the web of the finger, while the handle of the racket extends upon the dorsal surface over the joint. In the case of the index and little fingers the handle of the racket should be kept toward the centre of the hand, so that the scar will not present on the pressure surface. Further, it is not wise to remove the head of the underlying metacarpal bone, as it weakens the hand greatly. At the

interphalangeal joints the knife is entered dorsally just distal to the flexed knuckle ; then, having opened the joint, the edge is directed distally, and a long palmar flap is cut from the anterior surface of the phalanx. The bases of the distal phalanges should be saved where possible, as they carry the insertions of the flexor profundus tendons. If the lower half of the middle phalanx can be preserved, the insertions of the flexor sublimis to it would be saved. Where tendons are cut within their sheaths, as at the first interphalangeal joint, they generally retract markedly, leaving the phalanx without power, and the gaping sheath also makes spread of sepsis probable. It is well, therefore, to stitch the end of the divided tendon to the sheath, and close the mouths of the latter. Removal of fingers should be done sparingly, particularly in the case of the thumb, index, and little fingers.

The Nerves of the Upper Extremity.

The SPINAL ORIGINS of the nerves supplying the muscles of the upper limb are : adductors and abductors of shoulder (circumflex, supra- and subscapulars), fifth and sixth cervical ; flexors of elbow (musculo-cutaneous), fifth, sixth, and seventh cervical ; extensors of elbow (musculo-spiral), sixth, seventh, and eighth cervical ; flexors of wrist and hand (median group), sixth and seventh cervical ; flexors of wrist and hand (ulnar group), seventh and eighth cervical, first dorsal ; extensors of wrist and hand, and supinators (musculo-spiral and posterior interosseous), sixth, seventh, and eighth cervical.

The *median nerve* supplies the flexor sublimis digitorum (and part of the flexor profundus by the anterior interosseous), the abductor, opponens, and half of the flexor brevis pollicis (superficial), and first and second lumbricals.

The *ulnar nerve* supplies part of the flexor profundus digitorum, and all the small muscles of the hand not supplied by the median.

The *anterior interosseous* of the median supplies the flexor longus pollicis, pronator quadratus, and part of the flexor profundus.

As to SENSATION : The palmar aspect of the thumb and two and a half outer fingers is supplied by the median, the remaining one and a half by the ulnar.

Dorsally, the thumb is supplied by the radial, as well as the first phalanges of the index, middle, and radial side of the ring finger. The second and third phalanges of the index, middle, and half of the ring fingers are supplied by the median. The ulnar side of the ring and the whole of the little finger are supplied by the ulnar.

The MUSCULO-SPIRAL nerve arises from the fifth to the eighth cervical nerves. It gives off internal and upper and lower external cutaneous branches in the upper arm; supplies the triceps and anconeus from the musculo-spiral groove, and the brachialis anticus, supinator longus, and extensor carpi radialis longior after piercing the external intermuscular septum. Its posterior interosseous branch in the forearm supplies the extensor carpi radialis brevior, supinator brevis, extensors of the fingers and thumb, and extensor carpi ulnaris muscle, while the radial branch is purely sensory.

The nerve is frequently injured in fractures of the humerus, owing to its close relationship to the bone, and by undue pressure on the arm or on the axilla (as in crutch paralysis). When paralysis of the nerve occurs the extensors of the limb are affected, causing *drop-wrist*, and the supinators are likewise affected, while the flexors suffer from want of co-operation. Where the lesion occurs below the middle of the forearm, the triceps escapes. Sensation may be quite unaffected.

The MEDIAN NERVE arises from the sixth to the eighth cervical and first dorsal. In the forearm it lies between the superficial and deep muscles, and gives off muscular branches to the pronator radii teres, flexor carpi radialis, flexor sublimis digitorum, and palmaris longus, while the anterior interosseous branch supplies the outer half of the flexor profundus, flexor longus pollicis, and pronator quadratus. At the wrist it lies between the flexor carpi radialis and flexor sublimis, gives off the palmar cutaneous above the annular ligament, under which it passes to enter the palm, where it divides into its terminal branches, after supplying the abductor, opponens, and superficial head of the flexor brevis pollicis. The inner and outer terminal branches supply the two first lumbricals, and sensation to the palmar aspect of the thumb, index, middle, and half of the ring finger, and to the dorsal aspect of the terminal phalanx of the thumb, and of the two

terminal phalanges of the index, middle, and half of the ring finger.

In the palm the median nerve lies under the superficial palmar arch, but in the fingers its branches are superficial to the digital arteries.

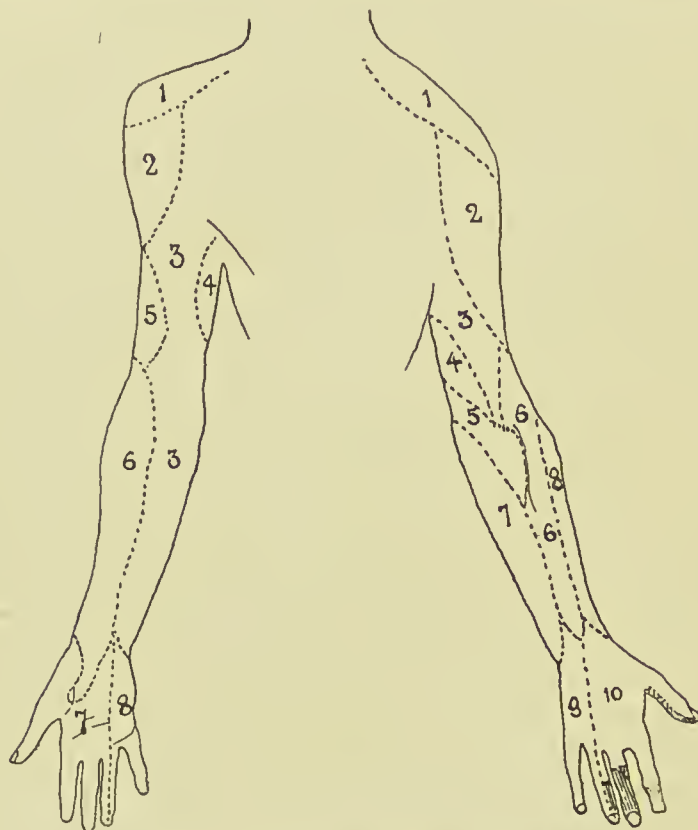


FIG. 61.—CUTANEOUS NERVES OF ARM.

Front.

1. Supra-acromial.
2. Circumflex.
3. Int. cutan.
4. Int. cutan. of musculo-spiral and intercosto-humeral.
5. Ext. cutan. of musculo-spiral.
6. Musculo-cutan.
7. Median.
8. Ulnar.

Back.

1. Supra-acromial.
 2. Circumflex.
 3. Int. cutan. of musculo-spiral.
 4. Intercosto-humeral.
 5. Lesser int. cutaneous (Wrisberg).
 6. Ext. cutan. of musculo-spiral.
 7. Internal cutan.
 8. Musculo-cutan.
 9. Ulnar.
 10. Radial.
- Parts shaded : Median.

Paralysis of the nerve is most often produced by wounds of the forearm or wrist, and produces inability to completely pronate the forearm, and, when flexion of the wrist is attempted, produces ulnar adduction. The thumb is extended

and adducted, and flexion and apposition are impossible, while wasting of the thenar eminence is marked. Flexion of the terminal phalanges of the index and middle fingers (supplied by the outer portion of the flexor profundus) is impossible, as is likewise flexion of all the second phalanges (supplied by sublimis and profundus together). Flexion of the first phalanges, with, at the same time, extension of the two distal phalanges, is possible, from the action of the interossei and two outer lumbricales, while the flexor brevis minimi digiti will also act. Sensation may be completely lost in the parts supplied, or may be almost unaffected.

The ULNAR NERVE arises from the eighth cervical and the first dorsal. It gives off articular filaments to the elbow-joint, and enters the forearm between the heads of the flexor carpi ulnaris, giving off thereafter motor branches to the flexor carpi ulnaris and inner half of the flexor profundus digitorum. Below the centre of the forearm it gives off a palmar cutaneous branch, which supplies the hypothenar eminence and central area of the palm, and a dorsal cutaneous branch, which communicates with the radial, and supplies the dorsum of the hand on its ulnar side, and also the dorsum of the little finger, and of the ulnar border of the ring finger. The trunk enters the palm by crossing the annular ligament superficially, and divides into superficial and deep branches, the former supplying the palmaris brevis, and the hypothenar skin and skin of the little finger, and ulnar border of the ring finger on both palmar and dorsal aspects. The deep branch supplies all the interossei, two inner lumbricales, and all the outer short muscles of the hand, except the abductor, opponens, and half of the flexor brevis of the thumb.

The ulnar nerve is most often damaged about the elbow, but may also be wounded about the wrist. In paralysis of the nerve, flexion of the wrist is accompanied by radial deviation. The thumb cannot be adducted, and the little finger is almost completely paralyzed, the hypothenar eminence atrophying. The ring finger cannot be flexed at the metacarpophalangeal joint, nor extended at the interphalangeal joints, owing to paralysis of the interossei and inner lumbricales, while the index and ring fingers, partly supplied by the two outer lumbricales, are less markedly affected.

In the later stages a *claw-hand* is developed from the un-

restrained action of the flexors and extensors, producing overextension of the first and flexion of the second and third phalanges.

As in the other nerves described, loss of sensation is often partial, owing probably to the overlapping of the sensory areas supplied by the various nerves.

ERB'S BRACHIAL PARALYSIS is one which affects the deltoid, biceps, brachialis anticus, supinator longus, and sometimes the supra- and infraspinati and supinator brevis. It is due to injury to, pressure upon, or disease of either (a) the motor columns of the cord supplying particularly the fifth and sixth cervical roots, or (b) that part of the brachial plexus where the motor tracts for the involved muscles have not yet divided into the different nerve trunks.

Erb's point, which lies fully $\frac{1}{2}$ inch anterior to the border of the trapezius on a line from the sterno-clavicular articulation to the seventh cervical spine, is that selected for stimulation of the affected muscles.

A somewhat similar condition is met with in infancy, due probably to traction on the cords of the brachial plexus, from pulling on the head of the child during delivery and exerting great pressure on the supraclavicular fossa. The arm is rotated markedly inwards, the ulnar border of the hand presenting anteriorly, the position resembling that found in subspinous dislocation of the shoulder. This condition may persist to adult life and cause much limitation of movement of the affected limb.

INDEX

The number given first indicates the principal reference.

- ABDOMEN, 177
boundaries of, 177
fasciæ of, 239
inframesocolic compartment
of, 202
integuments of, 177
muscles of, 179
nerves of, 183
palpation of, 183
parietes of, 177
superficial divisions of, 177
supramesocolic compartment
of, 202, 205
surface anatomy of, 177
transverse furrows of, 178
vessels of, 248
- Abdominal : aneurism, 248
aorta, 248
ascites, 177, 231
incisions, 178, 179
rings, 189, 191
viscera, 203-247
wall, abscess of, 182, 200
anastomosis in, 179, 185
blows on, 183
extravasation of urine
into, 178
lymphatics of, 179
nerves of, 183
reflex nervous mechan-
ism of, 183
vessels of, 178, 185
- Aberrant obturator artery, 193
Abnormalities of brachial artery,
398
- Abscess, abdominal, 182, 200
acetabular, 242, 321
alveolar, 95
appendicular, 221
axillary, 394
cerebral, 20, 34
cerebellar, 51
extradural, 17, 50
extraperitoneal, 241
- Abscess, gluteal, 301
hepatic, 223
Hilton's mode of evacuating,
91
iliac, 241
intracerebral, 51
ischio-rectal, 297
mammary, 160
mastoid, 49
mediastinal, 161
orbital, 61
palmar, 5
parotid, 91
perineal, 286
perinephric, 245
periurethral, 286
popliteal, 331
post-pharyngeal, 90
prevertebral, 117
prostatic, 268
psoas, 241, 141
renal, 245
retropharyngeal, 141, 207
retroperitoneal, 241
subphrenic, 213, 221
temporal, 9
temporo-sphenoidal, 21, 51
thecal, 428
tropical, 233
zygomatic, 97
- Accessory sinuses of nose, 80
anterior group, 82
posterior group, 81
thyroids, 131
- Accommodation, 66, 72
- Acetabulum, 312
abscess arising from, 242
fractures of, 312
- Achillis, tendo, 349
- Acne of face, 85
rosacea, 74
- Acromion process, 381
fracture of, 381
angle of, 376

- Acromio-clavicular articulation,
379
dislocation of, 380
- Addison's disease, 246
- Adductor region, 312
tubercle, 329
- Adenoids, 110
- Aditus ad antrum, 48
- Adrenals, 246
- Agger nasi, 76
- Ague cake, 238
- Air in veins, 135
embolism, 135
- Alæ nasi, 74
- Alcock's canal, 290
- Alexander's operation, 283
- Allantois, 186
- Amazia, 160
- Amnion, 186, 187
- Ampulla of milk ducts, 156
of Vater, 235
gall-stones in, 235
rectal, 290
- Amputation (see under Arm, Leg,
etc., and name of inventor)
neuroma, 328
- Amygdaloid nuclei, 23
- Anæsthesia, pupil in, 73
tongue in, 105
- Anal canal, 292
congenital defects of,
296
development of, 295
digital examination of,
291
lymphatics of, 294
mucous membrane of,
293
nerves of, 294
relations of, 291
triangle, 289
valves, 293
vessels, 293
white line, 293
- Anastomosis (see under Ligature
of Arteries)
artificial portal systemic, 231
crucial, 302
parietal and visceral, 248
patellar, 332
- Aneurism, aortic, 167
arterio-venous, 54, 407
axillary, 392
carotid, 133
cerebral, 29
cirroid, 7
femoral, 309
gluteal, 302
- Aneurism, innominate, 138
popliteal, 332
posterior tibial, 350
subclavian, 139
treatment of, 167
- Angina, Ludwig's, 102, 122
- Angular curvature of spine, 141
- Angulus sternalis, 151
- Ankle, 353
fasciæ of, 358
joint, 361
amputation at, 370
dislocation of, 363
effusion into, 361
fractures about, 363
ligaments of, 361
nerves of, 362
sprain, 358, 362
sprain fractures at, 362
synovial membrane of,
362
surface anatomy of the, 353
tendons of, 358
- Ankyloblepharon, 57
- Annular ligaments of ankle, 358
of wrist, 423, 427, 431
- Ano-coccygeal body, 293
- Annulus urethralis, 260
- Antecubital fossa, 407
- Anterior chamber of eyeball, 69
fontanelle, 11
fossa of skull, 12
palatine canal, 106
synechiæ, 65
- Antrum, duodenal, 211
mastoid, 48
of Highmore, 83
pylori, 205
- Anus, 293
artificial, 226
development of, 295
distension of, 293
epithelioma of, 296
fissure of, 297
fistula of, 297
imperforate, 296
- Aorta, abdominal, 248
compression of, 322
aneurism of, 167, 248
arch of, 166
ascending, 166
descending, 166
isthmus of, 166
sinuses of, 166
spindle of, 166
thoracic, 166
- Aortic valve of heart, 164
- Apex of lung in neck, 113

- Aponeuroses. See Fasciæ
- Apoplexy, cerebral, 29
pulmonary, 173
- Appendices epiploicæ, 226
- Appendicitis, 220
abscess following, 221
operative treatment for, 221
peritonitis following, 220
- Appendix vermiformis, 218
- Aqueduct of Fallopius, 53
of Sylvius, 24
- Aqueous humour, 69
- Arachnoid, cerebral, 17
spinal, 144
- Arches of foot, 354
of palate, 107
of palm (arterial), 423
- Arcus senilis, 65
- Area, motor, 20
Rolandic, 20
- Argyll-Robertson pupil, 72
- Arm, 394
amputation of, 403
fascia of, 395
integuments of, 395
lymphatics of, 396
nerves of, 398
surface anatomy of, 394
vessels of, 395
- Arterio-venous aneurism, 309
- Artery, aberrant obturator, 193
acromio-thoracic, 376, 391
anastomotica magna, 397
anterior tibial, 347
aorta, 164, 248
axillary, 390, 376
brachial, 396, 395
bronchial, 173
carotid, 132, 377
central, of retina, 68, 71
cerebral, 29
ciliary, 71
circumflex, arm, 391, 399
iliac, 185
cœliac axis, 205
coronary, 205
cremasteric, 271
cystic, 232
dental, inferior, 94
dorsalis pedis, 359, 355
epigastric, deep, 185
superficial, 306
external carotid, 134
external iliac, 256
external mammary, 391
facial, 5, 85, 122
femoral, 309
gluteal, 302
- Artery, hæmorrhoidal, 293
hepatic, 231
hyaloid, 71
iliac, 256
inferior dental, 94
innominate, 138, 377
intercostal, 154
internal carotid, 134
iliac, 256
mammary, 155
interosseous, 416
lingual, 103, 121, 122
lenticulo-striate, 29
mammary, internal, 139
mesenteric, inferior, 226
superior, 216
middle cerebral, 29
colic, 226
meningeal, 26, 4, 13
obliterated hypogastric, 186,
257
obturator, 193
occipital, 6
ophthalmic, 71
ovarian, 277
peroneal, 350
plantar, 360, 355
popliteal, 332
posterior interosseous, 417
tibial, 349
profunda brachialis, 397
femoris, 309
pulmonary, 164
radial, 416, 413, 430
ranine, 103
renal, 244
sciatic, 302
spermatic, 272
splenic, 236, 237
subclavian, 136, 377
subscapular, 391
superior intercostal, 139
thoracic, 390
temporal, superficial, 6
thoracic aorta, 166
arteries, 391, 376
thyroid, inferior and superior,
129, 130
axis, 139
tibial, anterior, 347, 359
posterior, 349, 360
ulnar, 414-416, 430
umbilical, 186
uterine, 277
vas deferens, 273
vertebral, 139
Willis, circle of, 28
- Aryteno-epiglottic folds, 124

- Ascites, 177, 231
 Asterion, 3
 Astigmatism, 64
 Astragalus, 366
 dislocations of, 363, 366
 fractures of, 367
 in congenital talipes, 367
 Asymmetry of head, 1
 Atheromatous cyst, 5
 Atrium of nose, 76
 Attic of tympanum, 45
 Auditory meatus, external, 43
 Auerbach's plexus, 217
 Auricle, supernumerary, 42
 Auricular point, 3
 Avulsion of scalp, 6
 of upper limb, 377
 Axes of rotation of eyeball, 60
 Axilla, 388
 boundaries of, 388
 contents of, 390
 folds of, 376, 388, 390
 surface anatomy of, 388
 suspensory ligament of, 389
 tumours of, 393
 wounds of, 393
 Axillary abscess, 394
 aneurism, 392
 fascia, 389
 lymphatic glands, 393
 affections of, 393
 nerves, 393
 vein, 392

 Band, ilio-tibial, 301, 307
 Bartholin's duct, 102
 glands, 284
 Basal ganglia, 23
 Base of skull, 12
 fossæ of, 12
 fracture of, 14
 Bell's paralysis, 39
 Bennett's fracture, 436
 Bezold's aperture, 53
 Biceps muscle, rupture of, 383
 Bicipital fascia, 407
 sulci, 394
 Bile-duct, 233
 common, 234, 233
 obstruction of, 234, 235
 operations on, 235
 Biliary colic, 235
 Black eye, distinction from frac-
 ture of orbital plate, 55
 Bladder, 257
 coats of, 259
 development of, 186
 distension of, 259
 Bladder, extroversion of, 261, 267
 fasciculated, 259
 female, 261
 fistulæ of, 261
 hernia of, 261
 hypertrophy of, 259
 inflammation of, 261
 ligaments of, 257
 lymphatics of, 260
 nerves of, 260
 of child, 257
 orifice of, 257
 prolapse of, 261
 prostatic pouch of, 260
 puncture of, 259
 relations of, 259
 rupture of, 261
 sacculatation of, 259
 stone in, 261
 trigones of, 259
 tumours of, 261
 ulcers of, 261
 vessels of, 260
 wounds of, 261
 Blepharitis, 55
 Blepharo-chalasis, 56
 spasm, 56, 65
 Blind spot, 68
 Bones, blood-supply of, 342
 epipteric, 11
 interparietal, 34
 of cranial vault, 9
 of forearm, 416
 of leg, 351
 surgical affections of, 341,
 326
 turbinal, 77
 Wormian, 11
 Bougie, œsophageal, 176
 Bowman's glands, 76
 Brachial artery, abnormalities of,
 398
 plexus, 392, 377
 Brachycephalic skulls, 1
 Brain, 19
 abscess of, 20, 34
 basal ganglia, 23
 centres of, 20
 concussion, 33
 convolutions, 20
 fissures, 20
 membranes, 16
 motor centres, 20
 pulsation of, 25
 relations to surface, 19
 tumours of, 25, 34
 vessels of, 29
 Branchial arches, 137

- Branchial clefts, 137
 cysts, 137
 fistulæ, 137
 recesses, 137
 Breast, 156. See Mamma
 Bregma, 2
 Broad ligaments, 280
 contents of, 280
 relations of, 280
 Broca's lobe, 20
 Bronchi, 168
 foreign bodies in, 168
 Bronchocele. See Goitre
 Bruch, membrane of, 67
 Brunner's glands in burns, 211
 Bryant's mode of dividing palate
 muscles, 108
 triangle, 300
 Bubo, 305
 Bubonocele, 191
 Buccal cavity, 101
 pad of Bichat, 85
 portion of pharynx, 110
 Bulb of corpus spongiosum, 265
 Bulbar paralysis, 41
 Bulla ethmoidalis, 78, 82
 frontalis, 82
 Bunion, 365
 Burdach, columns of, 32
 Burn, ulcer after, 211
 Bursa, elbow, 408
 great palmar, 428
 trochanter, 301
 intertubercular, 385
 ischial tuberosity, 302
 knee, 330
 ovary, 280
 patellar, 330
 popliteal, 334
 subacromial, 383
 subscapular, 384
 thyro-hyoid, 123
 Buttock. See Gluteal region
 Cæcal folds and fossæ, 219
 hernia, 218
 Cæcum, 217
 abnormal positions of, 218
 adult type of, 218
 development of, 218
 foreign bodies in, 218
 hernia of, 218
 infantile type of, 218
 inflammation of, 220
 in intestinal obstruction, 218
 nerves of, 220
 peritoneum of, 218
 sacculatation of, 218
 Cæcum, ulceration of, 218
 vessels of, 219
 volvulus of, 218
 Calcaneo-astragaloid-joint, 364
 cuboid joint, 364
 Calcaneum, 366
 Calcar femorale, 317
 Canal, Alcock's, 290
 crural, 193
 facial, 46
 Hunter's, 324
 hyaloid, 71
 inferior dental, 92
 inguinal, 188
 lachrymal, 59
 of Nuck, 282, 198
 of Petit, 71
 of Schlemm, 64, 72
 of Stilling, 71
 of Wirsung, 236
 palatine, 106
 semicircular, 54
 Canaliculi, lachrymal, 59
 Cancer en cuirasse, 159
 Cancrum oris, 85
 Canine fossa, 85, 92
 Canthi, 56
 Capitellum, 409
 Capsule, external, of brain, 22
 internal, of brain, 22
 of Glisson, 228
 of hip-joint, 315
 of kidney, 243
 of knee-joint, 335, 338
 of lens, 70
 of parotid gland, 116
 of prostate, 268
 of shoulder-joint, 384
 of submaxillary gland, 116
 of Tenon, 62
 Caput Medusæ, 179
 Carden's amputation, 344
 Cardiac area, superficial, 163
 orifice of stomach, 203
 Cario-necrosis, 366
 Carnochan's operation, 88
 Carotid aneurism, 133
 artery, 132
 anastomoses of, 133, 134
 ligature of, 133, 134
 lymphatics, 132
 region of neck, 132
 sheath, 132
 tubercle, 133
 Carpal arches, 430, 431
 bursa, great, 428
 Carpus, articulation of, 433
 disease of, 434

- Cartilages, lateral, of nose, 74
 septal, of nose, 75
 tarsal, 54
 Y-shaped, of acetabulum, 312
 Caruncle, lachrymal, 56, 57
 urethral, 262
 Castration, 274
 Cataract, congenital, 70
 senile, 70
 traumatic, 70
 Catheter, coudé, 269
 Eustachian, 78
 male, 264
 prostatic, 269
 Cauda equina, 143
 Caudate lobe of liver, 229
 nucleus, 23
 Cavernous sinus, 27, 61
 Cavum Meckelii, 36
 Centres, defæcation, 295
 micturition, 260
 of brain, 19
 of cord, 146
 of medulla, 32
 Cephalhæmatoma, 8
 Cerebellar abscess, 22
 localization, 22
 tracts, 31, 33
 tumour, 22
 Cerebellum, 30, 4, 22
 peduncles of, 30
 Cerebral abscess, 25, 20, 34
 aneurism, 29
 circulation, 26, 28
 convolutions, 20
 crura, 30
 embolism, 29
 hæmorrhage, 29
 localization, 4, 19
 membranes, 16
 sinuses, 26
 tumour, 25, 34
 vessels, 29
 Ceruminous glands, 43
 Cervical abscess, 116
 cord, 32
 enlargement, 143
 fascia, 114
 fistulæ, 137
 glands, 122, 132, 137
 nerves, 117
 ribs, 137
 sympathetic, 133
 tumours, 130, 137
 Cervico-pericardiac fascia, 161
 Cervix uteri, 275
 Chalazion, 57
 Chambers of eyeball, 69
 Charcot, aneurism of, 29
 Chassaignac's tubercle, 133
 Check ligaments, 62
 Cheek, 85
 Chemosis, 57
 Chest, deformities of, 150
 female, 150
 surface anatomy of, 150
 variations in shape of, 150
 want of symmetry of, 150
 wounds of, 165
 Chimney-sweep's cancer, 274
 Choanæ, 75
 Cholecystectomy, 235
 Cholecystenterostomy, 235
 Cholecystostomy, 234
 Cholecystotomy, 234
 Choledochotomy, 235
 Cholesteatoma, 54
 Chopart's amputation, 370
 Chordee, 267
 Chorio-capillaris, 67
 Choroid plexuses, 18
 Chorioid, 67
 rupture of, 67
 tumour of, 67
 Chorioidal fissure, 66
 Chyle cysts, 217
 Ciliary arteries, 71
 body, 66
 muscle, 66
 nerves, 72
 processes, 66
 Circle of Willis, 28
 Circular sinus, 27
 Circulus iridis, 71
 Circumcision, 266
 Circumvallate papillæ of tongue,
 103
 Cirroid aneurism, 7
 Cisterna magna, 18
 pontis, 18
 Clarke's column, 33
 Claustium, 22, 23
 Clavicle, 380
 articulations of, 378, 379
 dislocations of, 378, 380
 fractures of, 380
 movements of, 379
 ossification of, 381
 periosteum of, 381
 Clavi-pectoral region, 377, 375
 Claw-hand, 441
 Cleft, median, of lower lip, 101
 of upper lip, 101
 palate, 107
 recesses (branchial), 137
 Clergyman's sore-throat, 124

- Clitoris, 284
 Cloaca, 295
 Clubbing of finger-tips, 425
 Club-foot. See Talipes
 Coccygodynia, 251
 Coccyx, 251
 Cochlea, 54
 Cock's operation, 288
 Cœliac axis, 248
 Colitis, 220
 Colles's fascia, 285, 178, 265
 fracture, 420
 Coloboma facialis, 88, 101
 of iris, 66
 of lower eyelid, 88, 57
 of upper eyelid, 57
 Colon, ascending, 222
 descending, 224
 hepatic flexure of, 223
 hernia of, 223
 iliac, 224
 lymphatics, 226
 nerve-supply, 226
 operations on, 225
 pelvic, 224
 peritoneum of, 224
 positiou of, 222
 ptosis of, 223
 splenic flexure of, 223
 transverse, 223
 volvulus of, 225
 Colotomy, inguinal, 225
 lumbar, 225
 Column of Clarke, 33
 of Goll and Burdach, 32
 vertebral, 139
 Columns of Morgagni, 293
 Compression of brain, 34
 of cord, 146
 Concussion of brain, 33
 of cord, 145
 Conditions resembling femoral
 hernia, 305
 inguinal hernia, 197, 272,
 273
 Condyles of femur, 340
 Congenital dislocation of hip, 319
 exomphalos, 187
 fistula, 137
 hernia, 197
 hydrocele, 197
 malformations of anus and
 rectum, 295
 of bladder, 261
 of penis, 266
 of pinna, 42
 talipes, 367
 tumour of sterno-mastoid, 119
 Conjoined tendon, 180, 188
 Conjunctiva, 57
 fornices of, 57
 nerves of, 58
 vessels of, 58
 Conjunctivitis, 58
 Conus medullaris, 143
 Constipation, 224
 Contre-coup, fracture by, 11
 Convolutions of brain, 20
 Cooper's amputation, 370
 Coraco-acromial arch, 383
 -clavicular attachment, 379
 Coracoid process, 383, 375
 fracture of, 382
 Cord, spermatic, 271
 hydrocele of, 197
 spinal, 143, 32
 injuries of, 145-146
 umbilical, 185
 vocal, 125
 Corectopia, 66
 Cornea, 64
 herpes of, 65
 inflammation of (keratitis), 65
 lymphatic canals of, 64
 nerves of, 65
 ulceration of, 65
 wounds of, 65
 Coronal suture, 2
 Coronoid fossa, 408
 process, 409
 fracture of, 412
 Corpora cavernosa, 265
 geniculata, 23
 quadrigemina, 23
 striata, 23
 Corpus callosum, 24
 Highmori, 272
 spongiosum, 26
 striatum, 23
 Costal cartilages, 153
 fracture of, 153
 Costo-coracoid membrane, 389
 Cotyloid notch, 313
 Course of tracts in cord, 33
 Cowper's glands, 263
 Cranial bones, 9
 fossæ, 12
 meningocele, 3
 necrosis, 9
 nerves, 35
 points, 2
 sutures, 11
 vault, 9
 Craniotabes, 9
 Cranium, 5
 Cribriform fascia, 193, 308

- Cricoid cartilage, 112
 Crico-thyroid membrane, 126
 Crista urethralis, 263
 Crucial anastomosis, 302
 ligaments of knee, 339
 Crural canal, 193, 309
 nerve, 311, 372
 septum, 193
 Crus cerebri, 30
 Crusta, 30
 Crutch paralysis, 397, 439
 Cryptorchismus, 273
 Cuboid bone, 367
 Cuneiform bones, dislocation, 367
 Curves of spines, 140
 Cut throat, 123
 Cyclitis, 67
 Cynanche tonsillaris, 109
 Cyst, atheromatous, 5
 chyle, 217
 dermoid, 73, 102
 hydatid, 174
 mesenteric, 217
 of breast, 160
 of neck, 137
 of urachus, 186
 ovarian, 282
 pancreatic, 236
 tarsal, 55
 Cystic duct, calculus impacted in,
 234
 mucous membrane of,
 234
 hygroma of neck, 137
 Cystitis, 261
 Cystocele, 261
 Cystotomy, 262

 Dacryocystitis, 59
 Dartos, 274
 Darwin's tubercle, 42
 Dangerous area of eye, 67
 of scalp, 5
 Defæcation centre, 295
 Deltoid, bursæ, 383
 insertion, 394
 muscle, 382
 paralysis of, 383
 region, 382, 376
 tubercle, 375, 399
 Dental caries, reflex effects of,
 94
 Dentition, 94
 Dermoids, cervical, 102
 ovarian, 282
 sacral, 250
 thyro-glossal, 102
 Dextro-cardia, 165

 Diagnosis, anatomical causes of
 mistakes in, 194, 202, 214, 273
 Digastric triangle, 121
 Diploë, 10
 veins of, 10
 Diplopia, 89
 Direct inguinal hernia, 190
 Dislocation. See Joints involved
 Dolichocephalic skulls, 1
 Dorsal enlargement of cord, 143
 Dorsum ilii, dislocation of head of
 femur on to, 318
 Double chin, 114
 pulse, 421
 Douglas, pouch of, 275, 291
 semilunar fold of, 180
 Drop-wrist, 439
 Duchenne's paralysis, 41
 Duct, Bartholin's, 102
 bile, 233
 cystic, 234
 ejaculatory, 263
 hepatic, 233
 lactiferous, 156
 Müllerian, 279, 266
 nasal, 59, 78
 naso-frontal, 78
 of Gaertner, 282
 of Rivini, 102
 of Santorini, 236
 pancreatic, 236
 parotid, 91
 Stenson's, 91
 thoracic, 249
 thyro-glossal, 102
 vitello-intestinal, 186
 Wharton's, 102
 Wirsung's, 236
 Wolffian, 266
 Ductus venosus, 230
 Duodeno-jejunal flexure, 211
 junction, 211
 Duodenum, 210
 antrum of, 211
 flexures of, 211
 fossa of, 213
 hæmorrhage from, 213
 papilla of, 211, 234
 peritoneum of, 211
 pouch of, 213
 relations of, 211
 rupture of, 213
 strictures of, 213
 suspensory muscle of, 211
 ulcer of, 211
 vessels of, 213
 Dupuytren's contraction, 427
 fracture, 363

- Dura mater, 16
 inflammation of (pachy-
 meningitis), 19
 of brain, 16
 of cord, 144
 vessels of, 26
 Dysphagia, 175
 Ear, 42
 bleeding from, 15
 cough, 40, 43
 frost-bite of, 42
 hæmatoma of, 42
 internal, 54
 middle, 45
 nerves of, 43, 44, 53
 pinna, 42
 polypi of, 43
 serous discharge from, 16
 sneezing, 43
 tophi in, 42
 tumours, 44
 vomiting, 43
 yawning, 43
 Ectopia, cæcal, 218
 cordis, 152, 165
 intestinal, 187
 testis, 273
 vesicæ, 261
 Ectropion, 55
 Ejaculatory ducts, 263, 267, 270
 Elbow, bursæ, 408
 dislocations of, 412
 excision of, 411
 fractures of, 412
 gland of, 407
 integuments of, 405, 408
 joint, 408
 disease of, 410
 ligaments of, 409
 region of, 404
 sprains of, 413
 surface anatomy of, 404
 synovial membrane of, 410
 veins of, 405
 Elephantiasis, 274
 Embolism, air, 135
 cerebral, 29
 of central artery of retina, 68
 Eminence, parietal, 4
 Emissary veins of skull, 10
 Emmetropia, 64
 Emphysema, 171
 Empyema, 171
 Encephalocèle, 19
 Encysted hernia, 197
 hydrocele of cord, 197
 Endognathion, 107
 Endothoracic fascia, 154
 Enterectomy, 216
 Enterorrhaphy, 216
 Enterotomy, 216
 Enteroptosis, 214
 Entropion, 55
 Epicanthus, 57
 Epicondyle, fractures of, 402
 Epididymis, 271
 globus major of, 271
 globus minor of, 271
 Epididymitis, 273
 Epigastrium, 177
 Epiglottis, 103, 124
 Epilepsy, 34
 Epiphora, 56
 Epiphyseal plates of long bones,
 341
 Epiphysis, acromial, 381
 coracoid, 382
 femoral, 340
 humeral, 400, 402
 olecranal, 412
 rule regarding union to shaft,
 402
 tibial, 341
 Epiplocele, 202
 Epipteric bone, 11
 Epispadias, 267
 Epistaxis, 77
 Epitympanic recess, 45
 Erb's brachial paralysis, 442
 Erb's point, 442
 Erectile body, 76
 Eruption of teeth, 94
 Estlander's operation, 172
 Ethmoidal bulla, 82
 cells, 81
 anterior group, 82
 posterior group, 81
 Eustachian catheter, 78
 tube, 47, 109
 isthmus of, 47
 mouth of, 48
 Excision. See Particular joint
 Exognathion, 107
 Exomphalos, 187
 Exophthalmic goitre, 130
 Extensor paralysis of hand, 436
 External abdominal ring, 191, 189
 auditory meatus, 43
 abscess of, 43
 bony segment of, 43
 cartilaginous segment of,
 43
 exostosis of, 44
 in infant, 43
 nerves of, 43

- External auditory meatus, polypi
 of, mistakes regarding,
 43
 skin of, 43
 semicircular canal, 48
 trigone of bladder, 259
- Extracapsular fracture of femur,
 317
- Extradural abscess, 17
 hæmorrhage, 17
- Extraperitoneal abscess, 241
 tissue, 182, 421
- Extravasation of urine, 264, 287
 between layers of tri-
 angular ligament, 264
 into perineum, 265
- Extroversion of bladder, 267
- Eyeball, 62
 anterior chamber of, 69
 coats of, 64
 dangerous area of, 67
 excision of, 67
 lens, 69
 movements of, 60
 muscles of, 60
 nerves of, 72, 60
 posterior chamber of, 69
 rupture of, 64
 vessels of, 71
 vitreous, 70
- Eyebrows, 54
- Eyelashes, 55
- Eyelids, 54
 canthi of, 56
 cartilages of, 54
 coloboma of, 57, 88
 cysts of, 55
 lymphatics of, 56
 muscles of, 55
 nerves of, 55
 œdema of, 55
 septum orbitale of, 57
 vessels of, 56
- Face, 85
 development of, 88
 lymphatics of, 86
 nerves of, 86
 skin of, 85
 surgical affections of, 86
 vessels of, 85
- Facial canal, 46, 53
 neuralgia, 37, 87
 paralysis, 38, 86, 101
- Fæcal fistula, 186
- Fainting, 161, 206
- Fallopian tube, 280
 ampulla of, 280
- Fallopian tube, fimbriæ of, 280
 inflammation of, 281
 infundibulum of, 280
 isthmus of, 280
 mesosalpinx of, 280
 ostia, 280
 pregnancy in, 281
 rupture of, 281
- Fallopian tube, aqueduct of, 53
- False cords, 125
 passages, 264
- Falx cerebri, 17
- Farabœuf's amputation, 353
- Fascia, abdominal, 240
 axillary, 389, 390
 bicipital, 407
 bucco-pharyngeal, 110
 cervical, 114
 cervico-pericardiac, 161
 cremasteric, 182
 cribriform, 194, 308
 endothoracic, 154, 168
 iliac, 240, 191
 infundibuliform, 189
 intercolumnar, 191
 lata, 193, 308
 lumbar, 239
 obturator, 251
 of Abernethy, 256
 of arm, 395
 of Colles, 285, 178, 265
 of Scarpa, 285
 of thigh, 307
 palmar, 426
 parotid, 89
 pectoral, 156
 pelvic, 251
 perineal, 285
 plantar, 357
 popliteal, 331
 pretracheal, 116, 135
 prevertebral, 116
 psoas, 239
 rectal, 291
 recto-vesical, 251
 renal, 243
 temporal, 9
 transversalis, 182, 189, 191
 triangular, 191
 vertebral, 239
- Fauces, isthmus of, 106
 pillars of, 106
- Female generative organs, 275
- Femoral artery, 309
 aneurism of, 308
 ligature of, 309
 canal, 193, 308
 hernia, 191

- Femoral hernia, bladder in, 194
 conditions resembling,
 305, 308, 311
 contrasted with inguinal,
 191, 194
 course of, 193
 radical cure of, 199
 strangulation of, 198
 taxis in, 194
 lymphatic glands, 306
 phlebitis, 310
 ring, 305
 sheath, 309, 191
 trigone, 255
 vessels, 309
- Femur, 325, 314
 adductor tubercle of, 329
 condyles of, 340
 dislocations of, 317
 fractures of, 315, 325, 341
 great trochanter of, 313
 head of, 314
 lower extremity of, 340
 neck of, 314
 nutrient vessels of, 325
 osteomyelitis of, 341
 periosteum of, 325
 shaft of, 325
 variations in length of, 325
- Fenestra ovalis, 46
 rotunda, 46
- Ferguson's mode of dividing palate
 muscles, 108
- Fibro-cartilage, semilunar, of knee,
 339
 triangular, of wrist, 418
- Fibula, 352
 fractures of, 352
- Filiform papillæ of tongue, 102
- Filtering angle of eyeball, 69
- Filum terminale, 143
- Fimbriæ of Fallopian tube, 280
- Finger, 436
 abscess of, 428
 amputation of, 437
 avulsion of, 436
 contraction of, 430
 fractures of, 436
 lymphatics of, 431
 mallet, 436
 nerve-supply of, 438
 pulp of, 426
 synovial sheaths of flexor
 tendons of, 428
 thecæ of tendons of, 429
 wounds of, 428
- Fissure for ductus venosus, 228,
 229
- Fissure for obliterated umbilical
 vein, 229
 Glaserian, 92
 longitudinal, of brain, 4
 longitudinal, of liver, 229
 of anus, 297
 of brain, 20
 of liver, 228
 of lung, 172
 of Rolando, 4, 20
 of Santorini, 43
 of Sylvius, 4, 20
 portal, 229
 pterygo-maxillary, 97
 sphenoidal, 97
 spheno-maxillary, 97
 umbilical, of liver, 229
- Fistula, branchial, 137
 fæcal, 186, 268
 in ano, 297
 perineal, 286
 salivary, 91
 umbilical, 186, 187
 urinary, 286, 186
 vesico-vaginal, 261
- Flat-foot, 369
- Floating kidney, 243
 patella, 343
- Fold, aryteno-epiglottic, 124
 gluteal, 299
 of Douglas, 180
 of ureter, 253
 sacro-genital, 253, 257, 275,
 283
 salpingo-pharyngeal, 109
 utero-sacral, 253
- Fontana, spaces of, 64
- Fontanelles, 11
 sagittal, 4
- Foot, 353
 abscess, 355, 357
 amputation, 369
 arches, 354
 bones of, 366
 deformities of, 367
 dislocations of, 367
 fasciæ, 357
 flat, 369
 fractures, 366
 integuments, 355
 joints, 364
 lymphatics, 356
 nerves, 357
 surface anatomy of, 353
 vessels of, 356
 wounds of, 357, 361
- Foramen cæcum of medulla, 32
 of tongue, 103

- Foramen inferior dental, 92
 infra-orbital, 4
 jugular, 39
 mastoid, 10
 mental, 5
 of Key and Retzius, 31
 of Majendie, 31, 24
 of Monro, 24
 of Winslow, 201
 parietal, 10
 sacro-sciatic, 304
 sphenopalatine, 99
 spinosum, 13
 supra-orbital, 54
- Forearm, 413
 amputation of, 421
 bones, 416
 dislocations, 412
 fractures, 419
 integuments of, 414
 luxations, 413
 lymphatics, 414
 muscles, 414
 nerves, 414
 surface anatomy of, 413
 vessels, 414
- Foreign bodies in air-passages, 168
 in ear, 43
 in œsophagus, 132
- Formatio reticularis, 33
- Fornix of conjunctiva, 57
 of vagina, 278
- Fossa, antecubital, 407
 anterior of skull, 12
 fracture of, 15, 12
 canine, 85, 92
 coronoid, 408
 cranial, 12
 digital, of testicle, 271
 duodenal, 213
 glenoid, 92
 ileo-cæcal, 219
 ileo-colic, 219
 iliac, 239
 infraclavicular, 375
 inguinal, 190
 intersigmoid, 225
 ischio-rectal, 289, 285
 middle, of skull, 12
 nasal, 75
 navicularis, 263
 obturator, 254, 312
 olecranon, 408
 of Rosenmüller, 110
 ovarii, 281, 254
 pararectal, 254, 291
 paratrigoal, 260
 paravesical, 253
- Fossa, patellaris, 69
 pelvic, 253
 posterior, of skull, 14
 pterygo-maxillary, 96
 pyriform, 110
 radial, 409
 retrocolic, 219
 retro-ureteric, 260
 sphenomaxillary, 99
 supraclavicular, 114
 supraclavicular minor, 113
 supratosillar, 108
 trochanteric, 300
 zygomatic, 96
- Fourth ventricle, 31, 24
- Fovea centralis retinae, 69
- Fracture. See Various bones
 by contre-coup, 11
 dislocation of vertebrae, 142
- Frenulum linguæ, 103
 penis, 266
- Frenum epiglottidis, 103
- Frontal lobes of cerebrum, 20
 sinus, 82, 10
 empyema of, 83
 fracture of, 83
- Fronto-nasal duct, 83, 78
 process, 80
- Fundus of gall-bladder, 233
 of stomach, 204
 of uterus, 275
- Fungiform papillæ of tongue, 103
- Funicular process of peritoneum, 196
 hernia into, 197
 hydrocele, 197
- Gaertner, duct of, 282
- Galactocoele, 160
- Gall-bladder, 233
 distension of, 234
 fundus of, 233
 nerves of, 235
 operations on, 234
 surface anatomy of, 233
 ulceration of, 234
- Gall-stones, intestinal obstruction
 caused by, 234
- Ganglion at wrist, 431
 Gasserian, 13, 36
 lenticular, 36
 Meckel's, 87, 36
 otic, 36
- Gangrene, bowel, 248
- Gasserian ganglion, removal of:
 Hartley Krause, 99
 Macewen, 13
 Rose, 99

- Gastrectasis, atonic, 206
 stenotic, 206
 Gastrectomy, 208
 Gastric dilatation associated with
 movable kidney, 243
 Gastric ulcer, 203
 Gastro-jejunosomy, 209
 Gastro-colic omentum, 201, 200
 -hepatic omentum, 201, 203,
 230
 -splenic omentum, 204, 237
 Gastrostomy, 207
 Gastrotomy, 208
 Generative organs, development
 of, 266, 279
 female, 275
 male, 265
 Genu valgum, 326
 varum, 327, 352
 osteotomy for, 327, 352
 recurvatum, 338
 Giraldès, organ of, 271
 Girdle, shoulder, 377
 Glabella, 3
 Gladiolus, 151
 Glands of Montgomery, 157
 Glandulæ concatenatæ, 137
 Glans penis, 265
 Glaserian fissure, 92
 Glaucoma, 64, 69
 Glaucomatous cup, 64, 68
 Glenoid cavity, scapula, 384
 fossa, lower jaw, 92
 Glisson's capsule, 228
 Globular process, 101
 Glossitis, 104
 Glosso-epiglottidean folds, 102
 Glottis, œdema of, 124
 respiratoria, 125
 vocalis, 125
 Gluteal abscess, 301
 aneurism, 302
 bursæ, 301, 302
 fascia, 301
 fold, 299
 integuments, 300
 region, 299
 nerves of, 304
 surface anatomy of, 299
 vessels of, 302
 wounds of, 304
 Goitre, 130
 Goll, columns of, 32
 Gosselin's fracture, 352
 Gower's comma tract, 33
 Great omentum, 200
 sacro-sciatic foramen, 304
 transverse sinus, 163
 Great trochanter, 299, 314
 Grey matter of cord, 33
 Gritti's amputation, 344
 Gubernaculum testis, 195
 Gudden's commissure, 35
 Gums, 101
 Hæmarthrosis of knee, 337
 Hæmatocele, 272
 Hæmatoma of scalp, 8
 of pinna, 42
 Hæmoptysis, 173
 Hæmorrhage, cerebral, 29
 extradural, 26
 from frenum linguæ, 103
 from tongue, 103
 from tonsil, 108
 in laminectomy, 149
 in lithotomy, 288
 into chorioid, 67
 into internal capsule, 23
 into vitreous, 71
 meningeal, 17, 18
 subconjunctival, 57
 Hæmorrhoids, 294, 231
 Hæmosalpingitis, 281
 Hæmothorax, 173
 Hallux rigidus, 369
 valgus, 365
 Hammer toe, 369
 Hamular process, 107
 Hand, 421
 amputation of, 435
 creases of, 423
 fasciæ of, 426
 lymphatics of, 425
 skin of, 425, 426
 surface anatomy of, 421
 synovial sheaths of, 428
 synovitis of, 429
 vessels of, 425
 wounds of, 428
 Hanging, 146
 Hard palate, 106
 Hare-lip, 88, 101, 106
 median, 101
 Head (Section I.), affections of, 1
 asymmetry of, 1
 Heart, 164
 displacements of, 165
 valves of, 164
 wounds of, 165
 Heel, integument of, 356
 Helicoidal fractures of Leriche,
 326
 Hemianopsia, 35
 Hemiplegia, 23
 Hepatectomy, 232

- Hepatic artery, 231
 duct, 233
 flexure of colon, 223
 veins, 232
- Hepato-ptosis, 227
- Hepatotomy, 228
- Hermaphroditism, pseudo, 267
- Hernia, cæcal, 218
 complete, 191
 conditions resembling femoral, 305
 conditions resembling inguinal, 197, 272, 273
 congenital, 197
 coverings of, 190, 193
 diagnosis, mistakes in, 194, 202, 307
 diaphragmatic, 199
 direct, 190
 encysted infantile, 197
 femoral, 191
 infantile, 197
 inguinal, 187
 into funicular process, 197
 intraparietal, 182
 labial, 191
 Littre's, 198
 lumbar, 199
 mesenteric, 214
 oblique, 190
 obturator, 194
 of bladder, 261
 of lung, 170
 of muscle, 324
 of pancreas, 237
 omental, 202
 parts concerned in inguinal, viewed from behind, 187
et seq.
 perineal, 199
 pudendal, 199
 radical cure of femoral, 199
 of inguinal, 198
 rare forms of, 199
 retroperitoneal, 213
 Richter's, 198
 sciatic, 199, 304
 scrotal, 191
 strangulated, 198
 relief of, 198
 taxis, 194
 umbilical, 186
 vaginal, 279
 ventral, 178, 221
- Herniotomy, 193, 195
- Herophili torcular, 26
- Herpes zoster, 155, 167
- Hesselbach's triangle, 189
- Hey's amputation, 370
 dislocation, 437
- Hiatus semilunaris, 78
- Highmore, antrum of, 83
 empyema of, 84
- Hilton's law, 399
 method of opening abscesses, 91
 white line, 293
- Hilum of kidney, 242
 lung, 173
 spleen, 237
- Hip, 299
 amputation at, 322
 dislocations of, 317, 321
 disease, 320, 313
 excision of, 322
 fractures of, 316
 hysterical, 316
 joint, 312
 movements of, 315
 nerve-supply, 316
 region, 299
 surface anatomy of, 299
 synovial membrane of, 316
 vessels of, 316
- Hippocratic hand, 425
- Hodgkin's disease, spleen in, 238
- Holden's line of thigh, 305
 of face, 37
- Hordeolum, 55
- Horseshoe kidney, 242
- Hourglass stomach, 207
- Housemaid's knee, 330
- Houston's valves of rectum, 290
- Humerus, 399
 anatomical neck of, 399, 400
 development of, 400
 dislocations of, 385
 epiphyses of, 400
 fractures of, 400
 lower extremity of, 408, 402
 musculo-spiral groove of, 399
 nutrient artery of, 397, 402
 foramen of, 399
 shaft of, 400
 surgical affections of, 402
 neck of, 399
- Humour, aqueous, 69
 vitreous, 70
- Hunter's canal, 323
- Hutchinson teeth, 96
- Hyaloid artery, 71
 canal, 71
 membrane, 70
- Hydatid cyst, 233
 of Morgagni, 271, 282
- Hydrencephalocoele, 19

- Hydrocele, 271, 272
 bilocular, 197
 congenital, 197
 encysted of cord, 197
 infantile, 197
 of canal of Nuck, 283
 of neck, 137
 Hydrocephalus, 25
 Hydronephrosis, 244
 Hydrosalpingitis, 281
 Hygroma of neck, 137
 Hymen, 277
 Hyoid bone, 122, 112
 fracture of, 122
 Hypermetropia, 64
 Hypertrophy of bladder, 259
 of prostate, 269
 Hypochondriac region of abdomen, 177
 Hypogastric region, 177
 Hypopyon, 64
 Hypospadias, 266
 Hypothenar eminence, 426
 Hysterectomy, 276
 Hysterical hip, 316

 Ileo-cæcal fossa, 219
 intussusception, 222
 valve, 221
 Ileo-colic fossa, 219
 intussusception, 222
 Ileum, 214
 Iliac abscess, 241
 colon, 224
 fascia, 240, 191
 fossa, 239
 region, 177
 spines, 299
 vessels, 256
 Ilio-pectineal line, 188
 tibial band, 301, 308
 Imperforate anus, 296
 Incontinence of fæces, 295
 urine, 297
 Incisor, supernumerary, 107
 Inequality in length of limbs, 325
 Infantile hernia, 197
 hydrocele, 197
 Inferior maxilla, 92
 deformities of, 92
 dislocations of, 93
 excision of, 94
 fracture of, 92
 subluxation of, 93
 Infraclavicular fossa, 375
 hyoid region, 123
 mesocolic compartment of abdomen, 202, 212

 Infra-orbital foramen, 4
 patellar bursa, 330
 pad of fat, 330
 Infundibuliform fascia, 189
 Infundibulum of Fallopiian tube, 280
 of nose, 78
 Inguinal canal, 187
 colotomy, 225
 fossæ, 190
 hernia, 190
 affections resembling, 197, 272, 273, 305
 radical cure of, 198
 lymphatics, 306
 region, 187
 viewed from behind, 188
 Inion, 3
 Intercolumnar fascia, 191
 Intercostal membranes, 154
 muscles, 154
 nerves, 155, 154
 neuralgia, 155
 spaces, 153
 vessels, 154
 Intermuscular septa of arm, 396
 of thigh, 323
 Internal abdominal ring, 189
 capsule, 22
 ear, 54
 strangulation of intestine, 217
 table of skull, 9
 Interosseous membrane of arm, 417
 of leg, 437

 Interparietal bone, 4
 Intersigmoid fossa, 225
 Intervertebral disc, 141
 Intestinal obstruction, 214, 217, 218
 Intestine, development of, 186, 218
 large, 217
 characteristics of, 226
 functions of, 226
 lymphatics of, 226
 nerves of, 226
 operations on, 225
 stricture of, 226
 vessels of, 226
 small, arrangement of, in abdomen, 215
 determination of upper end of loop of, 214
 diseases of, 215
 diverticula of, 217
 identification of, 215
 length of, 214
 lymphatics of, 216
 nerves of, 217

- Intestine, small, operations on, 216
 strangulation of, 214
 stricture of, 215
 ulcers of, 215
 vessels of, 216
 wounds of, 216
- Intra-capsular fracture of femur, 316
 ligaments of eye, 62
- coracoid dislocation of shoulder, 386
- cranial pressure, 25
 sinuses, 14
- mammary abscess, 160
- ocular tension, 69
- pelvic cellulitis, 281
- Intussusception, 222, 217
 ileo-cæcal, 222
 ileo-colic, 222
- Inversion of testicle, 274
- Iridectomy, 66
- Irideremia, 66
- Irido-cyclitis, 67
- Iris, 65
 coloboma of, 66
 injuries of, 66
- Iritis, 67
- Ischio-rectal abscess, 297
 fossa, 289, 285
- Island of Reil, 22
- Isthmus of Fallopiian tube, 280
 of fauces, 106
 of thyroid, 130
- Iter ad antrum, 48
 relation of external semi-circular canal to, 48
 relation of facial canal to, 48
 relation of temporo-sphenoidal lobe to, 48
- Iter chordæ anterioris, 45
 posterioris, 45
- Jacksonian epilepsy, 34
- Jacob's ulcer. See Rodent ulcer
- Jaundice associated with movable kidney, 243
- Jaw, lower, 92
 upper, 88
- Jejunum, 214
- Joints. See Various articulations
- Jordan's amputation, 322
- Jugular vein, internal, 135
 air in, 135
 thrombosis of, 135
 wounds of, 135
- Keratitis, 65
- Keratoconus, 64
- Kidney, 242
 abnormalities of, 242
 abscess of, 245
 adipose capsule of, 243
 calculi, 245
 calyces, 245
 capsule, proper, of, 244
 fibrous capsule of, 243
 floating, 243
 hilum of, 242
 horseshoe, 242
 infection, mode of, 245
 injuries of, 245
 movable, 243
 nerve-supply of, 244
 operations on, 246
 pelvis of, 245
 position of, 242
 relations of, 244
 to twelfth rib, 244
 supernumerary, 242
 supporting mechanism, 243
 surgical, 245
 tuberculosis of, 245
 vessels of, 244
- Knee, 328
 bursæ about, 330
 fractures about, 337, 341
 housemaid's, 330
 fibro-cartilages of, 339
 integuments of, 329
 joint, amputation through, 344
 capsule of, 335, 338
 disease of, 343
 dislocations of, 344
 excision of, 343
 flexion of, 333
 nerves of, 343
 subluxation of, 343
 synovial membrane of, 339
 vessels of, 343
 nerves of, 329
 surface anatomy of, 328
 vessels of, 329
 of sigmoid sinus, 50
- Knock-knee, 326
- Kocher's operation on nose, 80
- Kraske's operation, 296
- Kyphosis, 140
- Labia majora, 284
- Labial hernia, 191
- Labio-glossal paralysis, 41
- Labyrinth of ear, 54

- Lachrymal abscess, 59
 apparatus, 58
 canal, 59
 canaliculi, 59
 caruncle, 56
 gland, 58
 nerve of, 58
 puncta, 59
 sac, 59
- Lacteals, 216
- Lactiferous ducts, 156
- Lacuna magna, 264
- Lacus lachrymalis, 56
- Lagophthalmos, 56
- Lambda, 2
- Lambdoidal suture, 2
- Lamina, basalis, 67
 chorio-capillaris, 67
 fusca, 67
- Laminectomy, 149
- Large intestine. See Cæcum,
 Colon, Rectum
- Laryngeal glands, 124
 pharynx, 110
 saccule, 125
- Laryngitis, 124
- Laryngoscopy, 126
- Laryngotomy, 126, 112
- Larynx, 123
 excision of, 127
 foreign matter in, 125, 126
 fracture of, 126
 lymphatics of, 125
 mucous membrane of, 124
 nerves of, 124
 new growths of, 124
 relations of, 124
 vessels of, 125
 ventricle of, 125
 vestibule of, 125
- Lateral curvature of spine. See
 Scoliosis
- lithotomy, 287
- sinuses, 27, 4
- ventricles, 24
 tapping of, 25
- Leg, 345
 amputation of, 353
 bones of, 351
 fasciæ of, 347
 fractures of, 351, 352
 integuments of, 346
 lymphatics of, 356
 muscles of, 347, 350
 nerves of, 371
 rickets of, 351
 surface anatomy of, 345
 varicose veins of, 346
- Leg, vessels of, 346
- Lens, 69
 capsule of, 70
 equator of, 70
 poles of, 70
 suspensory ligament of, 66,
 70, 71
- Lenticular nucleus, 22, 23
- Leptomeningitis, 19
- Leriche, helicoidal fracture of,
 326
- Lesser curvature of stomach, 203
 peritoneal sac, 201
 trochanter, 314
- Leucoplakia of tongue, 103
- Leukæmic enlargement of spleen,
 238
- Lieberkühn's glands, 215
- Lienculi, 237
- Ligament. See various regions
 annular, of ankle, 358
 of wrist, 423, 427,
 431
- Bigelow's, 315
- bladder, 257
- broad, 279
- calcaneo-metatarsal, 357
- calcaneo-scaphoid, 365
- capsular of hip, 315
- cervical of femur, 314
- check, 62
- conoid, 380, 383
- coraco-acromial, 383
- coraco-clavicular, 383
- coraco-humeral, 385
- coronary, liver, 230
- cotyloid, 313
- crucial, of knee, 339
- cutaneous phalangeal, of Cle-
 land, 426
- falciform, 193, 228
- Gimbernat's, 188
- glenoid, 384, 436
- gleno-humeral, 385
- hepato-colic, 223
- ilio-femoral, 315
- ilio-lumbar, 240
- ilio-pectineal, 309
- interclavicular, 378
- intracapsular, 62
- ischio-femoral, 315
- lateral, of rectum, 292
- lienorenal, 237
- Lisfranc's, 365, 370
- oblique, 417
- of ovary, 281
- orbicular, 410, 409
- of Treitz, 211

- Ligament of Winslow, 338
 peritoneal, 200
 phreno-colic, 224
 plantar, 364
 Poupart's, 180
 pterygo-maxillary, 93, 101
 pterygo-spinous, 96
 pubo-femoral, of hip, 315
 rectal, 292
 rhomboid, 378
 round, of liver, 230, 186
 of uterus, 283
 sacro-genital, 253
 sacro-sciatic, 304
 spheno-maxillary, 93
 spinal, 142
 stylo-maxillary, 90, 93
 suspensory, of breast, 156
 of Cooper, 156
 of lens, 66, 70, 71
 of Lockwood, 62
 of ovary, 280, 281
 of penis, 265
 of tarsi, 56
 thyro-arytenoid, 125
 transverse, of ankle, 361
 of hip, 313
 of humerus, 385
 of knee, 339
 of metacarpus, 436
 trapezoid, 379
 triangular, 286
 Y-shaped hip, 315
- Ligamenta alaria, 339
 brevia, 430
- Ligamentum latum pulmonis, 169
 mucosum, 339
 nuchæ, 114
 patellæ, 336
 pectinatum iridis, 64
 teres, 314
- Lighterman's bottom, 302
- Line, Holden's, of face, 37
 of thigh, 305
 ilio-pectineal, 188
 Nélaton's, 300
 of pleural reflection, 169
 white, of anus, 293
 of pelvis, 251
- Linea alba, 178
 aspera of femur, 325
 semilunaris, 179
- Lineæ albicantes, 177
 transversæ, 178, 179
- Lingual tonsil, 103
 triangle, 122
- Lipoma nasi, 74
- Lips, 100
- Lips, lymphatics of, 100
 nerves of, 100
 surgical affections of, 100
 vessels of, 100
- Lisfranc's amputation, 369
- Lister's amputation of knee, 344
- Litholapaxy, 262
- Lithotomy, perineal, 287
 suprapubic, 262
- Lithotrity, 262
- Littre's hernia, 198
 operation, 296
- Liver, 227
 abscess of, 232
 capsule of, 228
 caudate lobe of, 229
 channels of infection of, 232
 fixation of, 230
 hydatids of, 233
 injuries to, 232
 in pyæmia, 232
 ligaments of, 230
 lymphatics of, 232
 nerves of, 232
 nutmeg, 231
 operations on, 232
 peritoneum of, 228
 ptosis of, 231
 quadratic lobe of, 228
 relations of, 228
 Riedel's lobe of, 228
 Spigelian lobe of, 228
 surface anatomy of, 228
 relations of, 227
 tight-lacing, effects of, on, 228
 tumours of, 232
 uncovered area of, 228
 vessels of, 231
- Lobes of brain, 20
 of liver, 228
- Localization, cerebral, 20
- Lockjaw, or trismus, 93
- Long bones, surgical affections of, 341
- Longitudinal fissure, 4
 sinus, 26, 4
- Lordosis, 141
- Lower jaw, 92
 articulation of, 93
 condyle of, 92
 congenital defects of, 92
 dislocation of, 93
 excision of, 94
 fractures of, 92
 nerves of, 94
 subluxation of, 93
 surgical affections of, 93
 vessels of, 94

- Lower limb, length of, 325
 Ludwig's angina, 102, 122
 Lumbago, 141
 Lumbar abscess, 241
 aponeurosis, 239
 caries, 141
 colotomy, 225
 fasciæ, 239
 hernia, 199
 puncture, 144
 region, 239, 177
 spine, 141, 142
 injuries to, 142
 Lungs, 172
 abscess of, 173
 apex of, 172
 bleeding from, 173
 cavities in, 174
 collapse of, 170
 elasticity of, 170
 emboli of, 173, 174
 extent of, in root of neck, 113
 fissures of, 172
 hernia of, 170
 hilum of, 173
 incisura of, 172
 lobes of, 172
 nerves of, 173
 relations of, to chest wall, 172
 root of, 173
 rupture of, 173
 surgery of, 173, 174
 tumours of, 173
 vessels of, 173
 wounds of, 172, 173
 Lupus, 85
 Luschka's tonsil, 110
 Lymphatics. See Various regions
 Macrocheilia, 100
 Macroglossia, 104
 Macrostoma, 88, 101
 Macrotia, 42
 Macula lutea, 69
 Magendie, foramen of, 31, 24
 Malar bone, fracture of, 89
 Malignant pustule, 85
 Malleoli, fracture of, 341
 Mallet finger, 436
 Mamma, 156
 abnormalities of, 160
 abscess of, 160, 156
 areola of, 157
 capsule of, 156
 carcinoma of, 157 *et seq.*
 development of, 156
 examination of, 160
 incision of, 156
 Mamma, inflammation of, 160
 lymphatics of, 157
 nerves of, 160
 nipple, 156
 relations of, 156
 sarcoma of, 159
 skin of, 157
 supernumerary, 306
 suspensory ligaments of, 156
 tumours of, 159
 vessels of, 157
 Manubrium, 151
 Mastitis, 160
 Mastoid abscess, 49
 aditus, 48
 antrum, 48
 cells, 48
 cholesteatoma, 54
 lining of, 48
 process, 53
 pus, modes of escape from, 53
 relation of facial canal to, 53
 of sinus to, 50
 suprameatal triangle, 52
 surgery of, 52
 tegmen of, 48
 vein, 10, 28
 Mastoidectomy, 52
 Mastoiditis, 49
 sequelæ, 50
 cerebellar abscess, 51
 cerebral abscess, 51
 facial paralysis, 52
 meningitis, 51
 sigmoid sinus throm-
 bosis, 51
 Masto-squamosal suture, 53
 Maxilla. See Inferior and Super-
 rior
 McBurney's point, 221
 Meatal point, 3
 Meatus auditorius, 43
 of nose, 78
 urinarius, 264
 Meckel's diverticulum, 186, 217
 ganglion, 87, 36
 Median hare-lip, 101
 lithotomy, 288
 Mediastinal abscess, 161
 aneurism, 161
 lymphatic glands, 155
 pleura, 169
 tumours, 161
 Mediastinum, 160
 testis, 272
 Mediocarpal joint, 433
 Mediotarsal joint, 364
 Medulla oblongata, 31

- Megacephalic skull, 1
 Meibomian glands, 54
 Meissner's plexus, 217
 Membrana flaccida, 45
 tympani, 44
 Membrane, costo-coracoid, 389
 crico-thyroid, 126
 interosseous, of forearm, 417
 of leg, 347
 obturator, 312
 of brain, 16
 of Bruch, 67
 of cord, 144
 of Descemet, 64
 Schneiderian, 76
 Shrapnell's, 45
 thyro-hyoid, 123
 tympanic, 44
 Membranous urethra, 263
 Ménière's disease, 54
 Meningeal hæmorrhage, 13, 17, 18
 vessels, 26
 Meningitis, cerebral, 19
 spinal, 144
 Meningocele, cranial, 3, 19, 76
 spinal, 145
 Meningo-encephalocele, 19
 Meningo-myelocoele, 145
 Mental foramen, 5
 Mesencephalon, 30
 Mesenteric glands, 217
 hernia, 214
 Mesentery, 213, 195, 201
 apertures in, 214
 attachment of, 213
 cysts of, 217
 diseases of, 217
 length of, 214
 prolapse of, 214
 Mesoappendix, 219
 Mesocolon, transverse, 201, 224
 Mesognathion, 107
 Mesometrium, 283
 Mesonephron, 243
 Mesosalpinx, 280
 Mesovarium, 281
 Metacarpal bones, fracture of, 436
 Metacarpo-phalangeal joints, dis-
 location of, 436
 Metatarsal bones, 367
 Metatarso-phalangeal joints, dis-
 location of, 436
 Metatarsus, amputation of, 369
 Metritis, 276
 Microcephalic skull, 1
 Microstoma, 88, 101
 Microtia, 42
 Micturition centre, 260
 Middle ear, 45
 fossa of skull, 12
 meningeal artery, trephining
 for, 26
 Midcarpal joint, 433
 Midtarsal joint, 364
 amputation through, 370
 Miliary aneurism of Charcot, 29
 Milk-ducts, 156
 Miner's elbow, 408
 Mitral valve, 165
 Monro, foramen of, 24
 Montgomery's glands, 157
 Morbus coxæ, 320
 Morgagni, columns of, 293
 hydatid, of, 271, 282
 Motor centres of cortex, 20
 speech centre, 20
 tracts in cord, 33
 Mouth, 100
 vestibule of, 100
 Movable kidney, 243
 Mucocoele, 82
 Mucous colitis, 220
 polypus of nose, 77
 Mule's operation, 67
 Müller, ducts of, 279, 266
 muscle of, 61
 Mumps, 91
 Muscæ volitantes, 71
 Muscle (see Various regions) :
 adductors, 311, 323
 back of neck, 119
 biceps, 396
 ciliary, 66
 compressor urethræ, 263
 constrictors of pharynx, 110,
 122
 cremaster, 182
 deltoid, 382
 digastric, 120
 epitrochleo-anconeus, 408
 flexor carpi ulnaris, 422
 gemelli, 301
 glutei, 301
 hyo-glossus, 121, 122
 ilio-psoas, 311
 intercostal, 154
 interossei, 425
 latissimus dorsi, 377, 381
 lumbriales, 430
 mylo-hyoid, 120, 122
 obturator, 301
 occipito-frontalis, 5
 ocular, 59
 of Treitz, 211
 omo-hyoid, 120
 orbitalis, of Müller, 61

- Muscle, palatal, 107
 palmaris longus, 421
 pectoralis major, 388
 minor, 389
 plantaris, 349
 platysma myoides, 114
 prevertebral, 119
 pterygoid, 98
 pyriformis, 301
 pyramidalis, 180
 quadriceps extensor, 324
 rectus abdominis, 179
 scalene, 119
- Musculo-spiral groove, 399
 nerve, injury to, 401
- Myelocele, 145
 Myoma uteri, 276
 Myopia, 64
 Myxœdema, 131
- Nails, 425
- Nares, anterior, 75
 plugging, 79
 operations on, 80
 posterior, 75
- Nasal asthma, 80
 bones, 75
 fracture of, 75
 douche, 76
 duct, 78, 59
 exploration of, 80
 fossa, 75
 mucous membrane, 76
 olfactory portion, 76
 respiratory portion, 76
 roof of, 75
 lymphatics, 76
 obstruction, 80
 operations, 80
 polypus, 77, 80
 septum, 75
 perforation of, 75
 tumours, 77
- Nasion, 3
 Naso-pharynx, 109
 Neck, 112
 abscess of, 116
 aneurism of, 138, 139
 cysts of, 137
 development of, 137
 fasciæ of, 114
 fistulæ of, 137
 hydrocele of, 137
 integuments of, 114
 lung in, 113, 136
 lymphatics of, 132, 133
 middle line of, 112
 muscles of, 117
 Nélaton's line, 300
 Necrosis, of bones of vault, 9
 of long bones, 342
 Nephrectomy, 245
 Nephrolithotomy, 245
 Nephropexy, 246
 Nephrorrhaphy, 246
 Nephrotomy, 245
 Nerve-stretching, 304
 Nerve. See Various regions
 alderman's, 39
 anterior crural, 311, 372
 tibial, 348
 Arnold's, 39
 auditory, 39
 auricular, of vagus, 39
 auriculo-temporal, 36
 Bell's, 381
 cervical sympathetic, 133
 chorda tympani, 38, 45
 ciliary, 72
 circumflex, 399
 cranial, 35
 descendens noni, 132
 eighth, 39
 external respiratory, of Bell,
 381
 eleventh, 41
 facial, 38, 53, 86
 fifth, 36, 60, 87
 first, 35
 fourth, 35, 60
 genito-crural, 311
 glosso-pharyngeal, 39
 great auricular, 118
 petrosal, 38
 sciatic, 323, 372
 gustatory, 36, 101
 hypoglossal, 41, 104
 inferior dental, 37, 38, 52, 98
 maxillary, 36
 infra-orbital, 37
 intercostal, 155
 internal cutaneous, 397, 414
 Jacobson's, 47
 laryngeal, recurrent, 40, 125
 lingual, 99, 37, 101
 long saphenous, 309, 323
 median, 439, 397, 415
 mental, 37
 musculo-cutaneous, 348, 414
 musculo-spiral, 439, 397, 414
 ninth, 39

- Nerve, obturator, 312, 371
 olfactory, 35
 ophthalmic, 36, 72
 optic, 35
 palatine, 106
 peroneal, 374
 phrenic, 167
 plantar, 373
 pneumogastric, 39, 175, 206
 popliteal, 331
 posterior thoracic, 381
 tibial, 349
 pudic, 288
 recurrent laryngeal, 40
 respiratory, of Bell, 381
 sciatic, great, 331, 302
 small, 302
 seventh, 38
 sixth, 38, 60
 small occipital, 117
 spinal accessory, 41, 113
 superficial cervical, 118
 superior maxillary, 36
 supraclavicular, 377
 supra-orbital, 37
 sympathetic, 61, 72, 133
 tenth, 39
 third, 60, 35, 72
 tibial, 372
 trigeminal, 36
 twelfth, 41, 104
 ulnar, 441, 397, 415
 vagus, 39, 132
 Vidian, 81
- Nerve, artificial anastomosis,
 39
 points of exit from vertebral
 canal, 147
 supply of lower limb, 371
 supply of upper limb, 438
- Neuralgia, trigeminal, 37
- Night-startings, 343
- Nipple, 160
 supernumerary, 160
- Nose, affections of, 74
 accessory sinuses of, 80
 alæ of, 74
 atrium of, 76
 bleeding from, 77
 cartilaginous portion, 74,
 75
 foreign bodies in, 80
 lymphatics of, 76, 77
 meati of, 78
 nerves of, 74, 80
 outer wall of, 76
 skin of, 74
 ulceration of, 74
- Nose, vessels of, 77, 74
 vestibule of, 76
 wounds of, 74
- Notch, cotyloid, 313
 of Rivini, 45
- Nuck, canal of, 198, 283
 hernia into, 198, 283
 hydrocele of, 283
- Nuclei of medulla, 32
- Nutmeg liver, 231
- Oblique inguinal hernia, 190
 muscles of abdomen, 181
 of orbit, 60
- Obturator canal, 312, 194
 fascia, 251
 fossa, 254, 312
 hernia, 312
 herniotomy, 195
 membrane, 312
 or thyroid dislocation, 318
 region, 312
 vessels of, 312
- Occipital lobes of brain, 21
 protuberance, 3
 sutures, 3
 triangle, 136
- Occipito-frontalis aponeurosis, 5
- Ocular apparatus, 54
- Œdema of eyelids, 55
 of glottis, 124
 of scrotum, 274
- Œsophageal bougie, 176
 groove of liver, 228
 plexus, 175
- Œsophagectomy, 132
- Œsophagostomy, 132
- Œsophagotomy, 132
- Œsophagus, cervical segment of,
 131
 foreign bodies in, 132
 operations on, 132
 relations of, 131, 174
 stricture of, 132, 174
 thoracic segment of, 174
- Olecranon, bursa over, 408
 fossa, 408
 process, 409
 fracture of, 412
 relation of, to condyles, 405
- Olive of medulla, 32
- Omental hernia, 202
 sac, 202
- Omentum, functions of, 202, 203
 in hernia, 202
 gastro-splenic, 204, 237
 great or gastro-colic, 200,
 201

- Omentum, lesser or gastro-hepatic,
201, 203, 230
- Onychia, 425
- Ophthalmia, sympathetic, 67
- Optic atrophy, 68
 commis sure, 35
 disc, 68
 nerve, 35
 neuritis, 68
 thalamus, 23
- Ora serrata, 68
- Orbicular ciliaris, 66
- Orbit, abscess of, 61
 aneurism of, 61
 fracture of, 73
 movements of, 60
 muscles of, 60
 nerves of, 60
 paralysis of, 61
 tumours of, 61
 vessels of, 61
 wounds of, 54, 73
- Orbital cavity, 73
 tumours of, 73
 wounds of, 73
- Orchitis, 273
- Organ of Giral d ès, 271
 of Rosenmüller, 282
- Os calcis, 366
 disease of, 366
 dislocation of, 366
 fracture of, 366
- epactal, 3
 innominate, 249
 magnum, 434
 trigonum tarsi, 362
 triquetrum, 11
- Ossicles, 53
- Osteomyelitis of long bones, 341
- Ostia of accessory sinuses, 78
- Othæmatoma, 42
- Otitis media, 47
- Ovarian cyst, 282
 fimbria, 280
- Ovariotomy, 282
- Ovary, 281
 bursa of, 280
 fossa of, 281
 hernia of, 282
 ligament of, 280
 lymphatics of, 282
 mesovarium of, 281
 nerves of, 282
 palpation of, 282
 peritoneum covering, 282
 prolapse of, 282
 relations of, 282
 suspensory ligament of, 281
- Ovary, tumours of, 282
 vessels of, 282
- Ozæna, 76
- Pacchionian bodies, 6, 10
- Pachymeningitis, 19
- Pacinian corpuscles, 357, 426
- Pain referred, 155, 184, 206, 221,
 224, 233, 235, 245, 260, 268,
 273, 288, 295, 302, 316, 320,
 345, 357
- Palate, 106
 arch of, 106, 107
 cleft, 107
 hard, 106
 muco-periosteum of, 106
 muscles of, 107
 nerves of, 107
 soft, 106
 vessels of, 107
- Palatal crest, 106
- Palatine canals, 106
- Palm, abscess of, 427
 central compartment of, 427
 creases of, 423
 deep compartment of, 427
 skin of, 426
 synovial sheaths of, 428
- Palmar arches, 430
 fascia, 426
 Dupuytren's contraction
 of, 427
 vessels, 423
- Pampiniform plexus, 272
- Pancreas, 235
 access to, 236
 cyst of, 236
 ducts of, 236
 functions of, 236
 hernia of, 237
 lesser, 235
 lymphatics of, 236
 nerves of, 236
 relations of, 235
 surgery of, 236
 tuber omentale of, 236
 uncinate process of, 235
 vessels of, 236
- Pancreatic diabetes, operation
 for, 237
- Pancreatitis, suppuration follow-
 ing, 236
- Panniculus adiposus abdominis,
 178
- Pannus, 65
- Papilla of duodenum, 211, 234
- Papillæ of tongue, 102, 103
- Paracentesis pericardii, 164

- Paracentesis thoracis, 153
 tympani, 45
 ventricles of brain, 25
 Paradidymis, 271
 Parallel fissure, 21
 Paralysis. See Various nerves and regions
 bulbar, 41
 Duchenne's, 41
 Erb's brachial, 442
 Parametritis, 276
 Parametrium, 284
 Paraphimosis, 266
 Pararectal fossa, 254, 291
 Parathyroid bodies, 131
 Para-umbilical veins, 179
 Paravesical fossa, 253
 Parietal and visceral anastomosis
 in abdominal wall, 248
 eminence, 4
 fissures, 21
 foramen, 10
 lobes of brain, 21
 Paronychia, 425
 Paroöphoron, 283
 Parotid abscess, 90
 opening of, 91
 capsule, 116
 cyst, 92
 duct, 91
 fascia, 89
 fistula, 91
 gland, 89
 processes of, 90
 inflammation of, 91
 nerve-supply of, 91
 recess, 89
 region, 89
 structures within the gland, 90
 tumour, 91
 wounds, 91
 Parovarium, 282
 cysts of, 283
 Parrot's nodes, 2
 Pars ciliaris retinae, 68
 iridica retinae, 68
 Patella, 335
 absence of, 338
 blood-supply of, 335
 development of, 335
 dislocations, 337
 floating, 343
 fractures, 337
 ossification of, 335
 surface anatomy of, 335
 Patellar fossa, 69, 70
 ligament, 336
 plexus, 332
 Pelvic arch, 249
 bones, 250
 cavity, 251
 cellulitis, 253, 276
 diaphragm, 151
 fascia, 251
 fatty tissue, 253
 fossæ, 253
 peritoneum, 253
 peritonitis, 276, 281
 symphysis, 250
 viscera, 253
 Pelvis, 249
 false, 251
 floor of, 151
 fracture of, 250
 of kidney, 245
 true, 251
 vessels of, 256
 viscera of, 253
 Penis, body of, 265
 glans, 265
 malformations of, 266
 nerves of, 267
 root of, 265
 suspensory ligament of, 265
 vessels of, 267
 Perforating ulcer of duodenum,
 211
 of foot, 357
 of stomach, 207, 203
 Pericardium, effusion into, 163
 fibrous, 161
 paracentesis of, 163
 relations of, 161
 to chest-wall, 163
 serous, 162
 surgery of, 163
 Pericardotomy, 164
 Pericranium, 8, 5, 9
 Perimetritis, 276
 Perineal abscess, 286, 288
 body, 268, 279, 293
 fistula, 286
 hernia, 199, 202
 lithotomy, 287
 Perinephric abscess, 245
 Perineum, 284
 anal triangle of, 289
 boundaries of, 285
 central point of, 286
 fasciæ of, 285
 female, 288
 nerves of, 286
 rectal triangle of, 285
 rupture of, 289
 uro-genital triangle of, 285
 vessels of, 286, 289

- Periosteum of long bones, 342
 function of, 342
 Peripatellar depression, 328
 Peritoneal cavity, 201
 ligaments, 200
 Peritoneum, 200, 195
 duodenal fossa of, 213
 greater sac of, 200
 inguinal sac of, 190
 intersigmoid, 225
 ligaments of, 200
 pararectal, 254, 291
 paravesical, 253
 lesser sac of, 201
 mesentery of, 201
 pelvic fossæ of, 253
 omenta of, 200 *et seq.*
 sacs of, 200
 Peritonitis, 214, 220
 bands from, 214
 deformans, 214, 217
 pelvic, 276, 281
 pyogenic, 220
 tubercular, 214
 Peroneal compartment, 348
 sulci, 345
 Pes anserinus, 38
 cavus, 368
 Petit's canal, 71
 triangle, 241, 180
 Petrosal sinus, 14, 27
 Petro-squamosal suture, 46
 Peyer's patches, 215
 Phantom tumour, 179
 Pharyngeal aponeurosis, 110
 muscles, 110
 tonsil, 110
 Pharyngo-laryngeal recess, 124
 Pharyngotomy, 111
 Pharynx, 109
 abscess of, 111
 foreign bodies in, 110
 inflammation of, 110
 lateral recesses of, 110
 lymphatic glands, 111
 mucous membrane of, 110
 pyriform fossa of, 110
 relations of, 111
 supratonsillar fossa of, 108
 tumours of, 111
 Phimosis, 266
 Phlebitis, femoral, 311
 Phlebotomy, 407
 Phlegmasia alba dolens, 276
 Phthisis bulbi, 67
 Pia-arachnoid, 17
 Pia mater, 18
 choroid plexuses of, 18
 Pia mater, of cord, 145
 Pigeon breast, 151
 Piles, 294
 sentinel, 289
 Pillars of external ring, 191
 of fauces, 106
 Pineal body, 23
 Pinna, 42
 congenital defects of, 42
 injuries to, 42
 vessels of, 42
 Pirogoff's amputation, 371
 Plantar arch, 361
 fascia, 357
 ligaments, 357, 364
 nerves, 373
 vessels, 360
 Plantaris tendon, rupture of, 349
 Pleura, 168
 cohesion of, 170
 in neck, 136
 lowest level of, 169
 reflections of, 169
 relations of, 168
 surgery of, 171
 wounds of, 170
 Pleural cavity, effusion into, 171
 paracentesis of, 171
 sinuses, 168
 Plexus gulæ, 175
 vesico-prostatic, 268
 Plica semilunaris, 57
 sublingualis, 102
 Plugging nares, 79
 Pneumatocele, 54
 Pneumonectomy, 174
 Pneumothorax, 170
 Pneumotomy, 174
 Point, auricular or meatal, 3
 Erb's, 442
 McBurney's, 221
 pre-auricular, 3
 Politzer's method of inflating
 middle ear, 48
 Pollock's method of dividing
 palate muscles, 108
 Polycoria, 66
 Polypus of nose, 77
 Polymazia, 160
 Polythelia, 160
 Pons Varolii, 31
 lesion in, 38
 Popliteal abscess, 331, 333
 aneurism, 332
 bursæ, 334
 embolism, 333
 fascia, 331
 glands, 333

- Popliteal nerves, 331
 space, 330
 triangles of, 330
 vessels, 332, 333
 Portal and systemic venous systems, 231
 artificial communications, 231
 normal connecting channels, 231, 294
 circulation, 231
 obstruction, 231
 vein, 231
 Position of cardiac valves, 165
 Post-nasal adenoids, 110
 Post-pharyngeal abscess, 90
 Posterior chamber of eyeball, 69
 fossa of skull, 14
 palatine canal, 106
 prostatic pouch, 260
 region of neck, 114
 triangle of neck, 135, 114
 Pott's disease of spine, 141, 151, 241
 fracture, 363, 352
 puffy tumour, 17
 Pouch, duodenal, 213
 of Douglas, 275, 291
 of Prussak, 45
 post-prostatic, 260
 recto-genital, 275
 recto-vaginal, 273
 recto-vesical, 257
 Poupart's ligament, 180
 Pre-auricular point, 3
 Precentral convolution of brain, 20
 Pre-interparietal bone, 3
 Prepatellar bursa, 330
 Prepuce, 266
 Presbyopia, 70
 Precentral convolution of brain, 20
 Premaxilla, 107
 Pretibial bursa, 330
 Pretracheal fascia, 116, 135
 Prevertebral abscess, 117
 fascia, 116
 Processus cochleariformis, 47
 vaginalis, 196
 Priapism, 288
 Procidencia uteri, 275
 Proctodæum, 296
 Prolapsus ani, 295
 uteri, 275
 Promontory of cochlea, 46
 Pronation, movement of, 419
 Proptosis, 56
 Prostate, 267
 function of, 269
 hypertrophy of, 269
 Prostate lymphatics, 268
 middle lobe of, 267
 nerves, 268
 size of, 267
 Prostatectomy, 269
 Prostatic abscess, 268
 capsules, 268
 catheter, 269
 ducts, 263
 plexus of veins, 268
 pouch, 260
 sinus, 263
 urethra, 263, 267
 utricle, 263
 veins, 268
 Prostatitis, 268
 Prussak, pouch of, 45
 Psoas, abscess, 241
 sheath, 241
 Pterion, 3
 Pterygium, 58
 Pterygo-maxillary fissure, 97
 fossa, 96
 Ptosis of upper eyelid, 56
 of abdominal viscera, 207,
 214, 227, 238
 Pubic dislocation of hip, 318
 spine, 305
 Pudendal hernia, 199
 Pulmonary abscess, 173
 apoplexy, 173
 ligament, 169, 173
 valve, 164
 vessels, 173
 Pulp of fingers, 426
 Pulse, double, 421
 radial, 414
 Punctum lachrymale, 59
 Pupil, 65, 72
 Argyll-Robertson, 72
 causes of contraction and dilatation of, 72
 mechanism of, 72
 nerve-supply of, 72
 Pyelitis, 245
 Pylorectomy, 209
 Pyloric antrum, 205
 canal, 205
 sphincter, 208
 tumours, 208
 valve, 205, 208
 vestibule, 205
 Pyloroplasty, 209
 Pylorus, 205
 altered position of, in disease, 207
 congenital tumour of, 208
 dilatation of, 209

- Pylorus, function of, 208
 resection of, 209
 stricture of, 208
 Pyonephrosis, 245
 Pyosalpinx, 281
 Pyramid, 32, 47
 Pyramidal lobe of thyroid, 130
 tracts, 32
 Pyriform fossa of pharynx, 110
 of larynx, 124

 Quadrilateral space of axilla,
 391

 Radical cure of hernia, 198, 199
 Radio-carpal joint, 432
 Radio-ulnar joint, inferior, 418
 superior, 410
 Radius, 416
 Colles's fracture of, 420
 dislocation of, 413
 epiphysis of, 421
 fractures of, 419
 head of, 409, 412
 nutrient vessel of, 416
 sarcoma of, 420
 styloid process of, 421
 Ranula, 102
 Receptaculum chyli, 217
 Recess, internal branchial, 137
 lateral, 124
 parotid, 89
 pubic, 289
 Rectal ampulla, 290
 cystocele, 261
 epithelioma, 296
 examination, 291
 excision, 296
 fistula, 297
 prolapse, 295
 sinuses, 293
 triangle, 289
 valves, 290
 Rectocele, 279, 289
 Recto-genital pouch, 275
 Recto-vaginal fistula, 279
 septum, 279
 Recto-vesical fascia, 251
 pouch, 257, 291
 Rectum, 290
 absent, 296
 absorptive power of, 298
 attachments of, 290
 bands of, 290
 carcinoma, 296
 curves of, 290
 deformities of, 296
 development of, 295

 Rectum, effects of distension of, 290
 excision of, 296
 fissure of, 297
 fistula of, 297
 introduction of hand into, 293
 of child, 295
 Kraske's sacral resection of,
 296
 ligaments of, 292
 lymphatics of, 294
 methods of examination of,
 290, 291, 292
 nerves of, 294
 peritoneum of, 291
 polypus, 292
 pouch of, 291
 prolapse, 295
 stricture of, 293, 296
 tumours of, 292
 valves of, 293
 vessels of, 293
 Referred pain, 155, 184, 206, 221,
 224, 233, 235, 245, 260, 268,
 273, 288, 295, 302, 316, 320,
 345, 357
 Reil, island of, 22
 Renal abscess, 245
 calculus, 245
 colic, 245
 hæmorrhage, 245
 Respiration in fractured spine,
 148
 Restiform body, 32
 Retained testicle, 273
 Retention of menses, 284
 of urine, 295
 Retina, 68
 detachment of, 69
 fovea centralis of, 69
 glioma of, 69
 inflammation of, 69
 optic disc of, 68
 ora serrata of, 68
 pars ciliaris of, 68
 iridica of, 68
 structure of, 68
 Retinitis, 69
 Retroflexion of uterus, 275
 Retroperitoneal abscess, 241
 hernia, 213
 Retropharyngeal abscess, 111
 Retropubic fat, 259
 Retroversion of uterus, 275
 Rhinitis, atrophic, 76
 hypertrophic, 76
 Rhinoliths of nose, 80
 Rhinoplasty, 74
 Rhinoscopy, 80

- Ribs, 152
 accessory, 152
 cervical, 152
 enumeration of, 152
 fractures of, 152
 insane, 153
 resection of, 154
 rickets of, 153
 tubercle of, 153
- Richter's hernia, 198
- Rickets of femur, 326
 of pelvis, 250
 of ribs, 153
 of skull, 9
 of tibia, 351
- Rider's bone, 311
 sprain, 310, 311
- Riedel's lobe, 228
- Rima glottidis, 125
- Ring, abdominal, 191, 189
 crural, 193, 309
- Risus sardonicus, 93
- Rivini, duct of, 102
- Rodent ulcer, 55, 85
- Rolandic area, 20
- Rolando, fissure of, 4
 tubercle of, 32
- Root of lung, 173
 of penis, 265
- Rosenmüller, fossa of, 110
 organ of, 282
- Rose's operation, 99
- Rouge's operation, 80
- Round ligament of liver, 230, 186
 of uterus, 283
 shortening of, 283
- Rupture of biceps, 396
 of urethra, 264, 287
- Sac, lachrymal, 59
- Sacral dermoids, 250
 nerves, 371
 tumour, 250
- Sacro-coccygeal joint, 251
 dislocation of, 251
 region, 250
 tumours of, 251
- Sacro-genital fold, 253, 257
- Sacro-iliac joint, 250
 disease of, 250
- Sacro-sciatic foramina, 304
 ligaments, 304
- Sacro-vertebral angle, 140
- Sacrum, section of, Bardenheuer, 297
 Kraske, 296
- Sagittal fontanelle, 4
 section, 2
- Sagittal suture, 2
- Salivary cyst, 92
 fistula, 92
- Salmon patch, 65
- Salpingitis, 281
- Salpingo-pharyngeal folds, 109
- Santorini, duct of, 236
 fissures of, 43
- Saphenous opening, 193, 306, 308
- Scalene tubercle, 136
- Scalp, 5
 abscess of, 8
 avulsion of, 6
 cephalhæmatoma, 8
 cirroid aneurism of, 7
 dangerous area of, 8
 effusions in, 8
 hæmorrhage from, 7
 hæmatoma of, 8
 lymphatics of, 7
 mobility of, 5
 nerves of, 7
 neuralgia of, 7
 sebaceous cysts of, 5
 temporal region of, 9
 vessels of, 6, 7
 wounds of, 7, 8
- Scaphoid bone, dislocation of, 367
- Scapula, acromion process of, 381
 excision of, 382
 fracture of, 381
 luxation of, 381
 surgical neck of, 382
 fracture of, 382
 tumours of, 382
- Scapular region, 381, 377
 spine, 377
- Scarpa's fascia, 285
 triangle, 305
 fascia of, 306
 glands of, 306
 superficial anatomy of, 305
 surgical affections of, 305, 306
 vessels of, 306
- Schlemm, canal of, 64
- Schneiderian membrane, 76
- Sciatic dislocation, 318
 hernia, 304
- Sciatica, 302
- Scirrhus mammæ, 159
- Sclerotic, 64
- Scoliosis, 140, 151
- Scrotum, 274
 development of, 274
 elephantiasis of, 274

- Scrotum, integuments of, 274
 lymphatics of, 274
 nerves of, 274
 œdema of, 274
 septum of, 274
 vessels of, 274
- Seat of election, amputation at, 353
- Sebaceous cyst, 5
- Semilunar cartilage of knee, 339
 dislocation of, 339
 fold of Douglas, 180
- Semicircular canals, 54, 48
- Seminal vesicles, 269
- Sensory tract in cord, 33
- Sentinel pile, 298
- Septum crurale, 193
 lingual, 105
 of nose, 75
 orbital, 57
 pectiniforme of penis, 265
- Sesamoid bones, 437
- Sheath, carotid, 132
 femoral, 309, 191
 of rectus abdominis, 179
- Shingles, 155
- Shoulder, 375
 clavi-pectoral region of, 377
 deltoid region of, 376
 dislocation of, 385
 tests for, 385
 fractures about, 381, 400
 girdle, 377
 joint, 383
 amputation at, 388
 disease of, 387
 excision of, 387
 luxation of, 385
 surface anatomy of, 375
- Shrapnell's membrane, 45
- Sigaultean operation, 250
- Sigmoid cavity of ulna, 409
 flexure, 224
 sinus, 27
 thrombosis, 51
- Sinus, accessory, of nose, 80
 cavernous, 27
 thrombosis of, 61
 circular, 27
 frontal, 82, 10
 great transverse, 163
 inferior petrosal, 27
 lateral, 27, 4
 longitudinal, tears of, 12
 petrosal, 14
 pleural, 168
 pocularis, 263
 pyriform, of larynx, 124
- Sinus, pyriform, of pharynx, 110
 sigmoid, 27
 aspiration, prevention of, 28
 thrombosis of, 28
 sphenoidal, 81
 straight, 28
 superior longitudinal, 26
 nævi connected with, 27
 thrombosis of, 27
 transverse, of pericardium, 163
- Skey's amputation, 370
- Skin, bronzing, 247
- Skull, abnormalities of, 1
 base of, 12
 brachycephalic, 1
 craniotabes of, 9
 development of, 9, 12
 diploic tissue of, 10
 dolichocephalic, 1
 emissary veins of, 10
 fractures of, 10, 11, 14
 gunshot wounds of, 9
 necrosis of, 9
 of infant, 11
 rickets of, 1
 soft parts covering, 5
 sutures of, 11
 syphilis of, 1
 tables of, 9
 thickness of, 10
 vault of, 9
 vessels of, 10, 16
- Small intestine, 214
 trochanter, 314
- Smith's amputation, 344
- Snuffles, 75
- Socia parotidis, 90
- Soft palate, 106
- Solar plexus, 247, 248
- Sole of foot, 354
- Spasmodic stricture of œsophagus, 175
 torticollis, 119, 41
- Spermatic cord, 271
- Spermatocele, 271
- Spermatorrhœa, 292
- Spheno-maxillary fissure, 97
 fossa, 99
- Spheno-palatine foramen, 97
- Sphenoidal fissure, 97
 sinus, 81
 ostium of, 81
- Spigelian lobe of liver, 228
- Spina bifida, 145
 occulta, 145

- Spinal cord, 143
 length of, 143
 relations of, 143
 concussion, 145
 crush, 146
 injuries, 145, 146
 lesions, localization of, 146
 meninges, 144
 meningitis, 144
 nerves, 146
 points of emergence of, 147
 operations, 149
 vessels, 143, 145
 wounds, 146
- Spine, caries of, 141
 curves of, 140
 fracture dislocations of, 142
 nasal, 106
 of Henle, 52
 of pubis, 305
 scoliosis of, 140
 sprains of, 141
- Spinous processes, fracture of, 143
- Spleen, 237
 abscess of, 238
 accessory, 237
 ague cake, 238
 capsule of, 237
 dislocation of, 238
 enlarged, 238
 extirpation of, 238
 hilum of, 237
 injuries to, 238
 in leucocythæmia, 238
 lymphatics of, 238
 nerves of, 238
 notches of, 237, 238
 position of, 238
 relations of, 237
 rupture of, 238
 supporting mechanism of, 237
 vessels of, 237
 wandering, 238
- Splenectomy, 239
 Splenic flexure, 223
 Splenopexy, 239
 Spondylolisthesis, 140
 Spongy urethra, 263
 Sprains of spine, 141
 of ankle, 358, 362
- Staphylorrhaphy, 108
 Stenotic gastroectasis, 206
 Stenson's duct, 91, 100
 cyst of, 92
 fistula of, 92
- Stercoral ulcer, 218
 Sternal angle, 151
 notch, 150
- Sterno-clavicular joint, 378
 disease of, 379
 dislocations of, 378
 movements of, 378
- Sterno-mastoid region, 113
 muscle, tenotomy of, 119
 tumour, 119
- Sternum, 151
 apertures in, 152
 depressions in, 152
 fractures of, 151
 injuries of, 152
 separation of segments of, 151
 trephining, 152
- Stilling, hyaloid canal of, 71
- Stomach, 203
 body of, 205
 cardia of, 203
 contraction of, 206
 cough, 41
 curvatures of, 203
 dilatation of, 206
 displacement of, 207
 foreign bodies in, 208
 fundus of, 204
 hour-glass contraction of, 207
 level of, 204
 lymphatics of, 206
 nerves of, 206
 notch of, 204
 operations on, 207
 perforation of, 207
 pylorus of, 205, 208
 ptosis of, 207
 relations of, 205
 space in abdomen containing,
 205
 tumours of, 207
 ulceration of, 207
 wounds of, 208
 vessels of, 205
- Stone in bladder, 261
 in kidney, 245
- Strabismus, 60
- Strangulation in femoral hernia,
 198
 in inguinal hernia, 198
 in obturator hernia, 195
 internal, 203
- Striæ acousticae, 31
 Stratum vasculosum, 67
 Stricture of œsophagus, 175
 of urethra, 264
- Student's elbow, 408
 Stump neuroma, 328
- Styte, 55
- Styloid processes of radius and
 ulna, 421, 422

- Stylo-mastoid foramen, 38
 Subacromial bursa, 383
 dislocation of humerus, 387
 Subarachnoid space, 18, 144
 Subastragaloid dislocation, 367
 Subclavian artery, ligature of, 136,
 138
 triangle of neck, 135
 Subclavicular dislocation of shoulder, 386
 fossa, 375
 Subcoracoid dislocation of shoulder, 386
 Subconjunctival hæmorrhage, 57
 Subdeltoid bursa, 383
 Subdural hæmorrhage, 18
 space, 17, 144
 Subglenoid dislocation of shoulder, 386
 Sublingual gland, 102
 Submaxillary abscess, 122
 capsule, 116
 glands, 122
 region, 121
 salivary glands, 105
 Submental triangle, 121
 Submesocolic compartment of abdomen, 202, 212
 Subperitoneal tissue, 182
 Subphrenic abscess, 207
 Subspinous dislocation of shoulder, 387
 Sucking-pad, 85
 Sulci of brain, relations of, 20
 Superficial cardiac area, 163
 cervical glands, 122, 132
 palmar arch, 430
 Superior longitudinal sinus, 26
 maxilla, 88
 excision of, 89
 fractures of, 88
 tumour of, 89
 vena cava, 165, 160
 Supernumerary mamma, 160, 306
 Supination, movement of, 419
 Supraclavicular fossa, 114
 region, 135
 Supracondyloid lymphatic gland, 395
 process, 398
 Suprameatal triangle, 52
 Supramesocolic compartment of abdomen, 205
 Supra-orbital foramen, 54
 notch, 4
 Suprapubic cystotomy, 262
 Suprenals, 246
 Suprasternal notch, 150
 Supratonsillar fossa, 108
 Surgical affections of long bones,
 341, 402
 kidney, 245
 neck of humerus, 399
 of scapula, 382
 Suture of skull, 11
 closure of, 11
 coronal, 2
 fœtal, 3
 lambdoidal, 2
 masto-squamosal, 53
 occipital, 3
 petro-squamosal, 46
 relations of, to surface, 2
 sagittal, 2
 separation of, 11
 Sylvius, aqueduct of, 24
 fissure of, 4, 19
 Symblepharon, 57
 Syme's amputation, 370
 Sympathetic ophthalmia, 67
 Symphysis pubis, 250
 Synechia, anterior, 65
 posterior, 67
 Synostosis of skull, 11
 Synovial sheaths of foot, 358
 of hand, 428
 Syphilis of bone, 1, 351, 402
 of testicle, 273
 of tongue, 105
 Syringomyelocoele, 145
 Tabatière anatomique, 422
 Tabes mesenterica, 217
 Tagliacozzi's operation, 395, 74
 Talipes, 367
 calcaneus, 368
 cavus, 357, 368
 equino-varus, 367
 equinus, 368
 valgus, 368
 varus, 368
 Tapping bladder, 258
 lateral ventricles, 25
 pericardium, 163
 pleura, 153
 Tarsal bones, 366
 fractures and dislocations of, 366
 cartilages, 54
 cysts, 55
 joints, 364
 ligaments, 56
 Tarsectomy, 369
 Tarso-metatarsus, 365
 Tarsus, 364
 Taxis, 194

- Tealc's amputation, 353
- Teeth, 94
 development of, 95
 extraction of, 95
 roots of, 95
 syphilis of, 95
 supernumerary incisor, 107
 time of eruption of, 94
 tumours of, 95
- Tegmen antri, 48
 tympani, 46
- Tegmentum, 30
- Temporal abscess, 9
 bone, 44
 fascia, 9
 lobes of brain, 21
 muscle, 9
 region, 9
- Temporo-maxillary articulation, 92
 ankylosis of, 93
 capsule of, 93
 disease of, 93
 dislocation of, 93
 excision of, 93
- Temporo-sphenoidal lobe, 21
 abscess of, 21
- Tendo Achillis, 349
 tenotomy of, 355
 oculi, 57
- Tendon, conjoined, 180
- Tendons of ankle, 358
 of wrist, 431
- Tenon's capsule, 62
- Tenotomy of biceps femoris, 334
 of hamstrings, 334
 of sterno-mastoid, 119
 of tendo Achillis, 355
 of tibialis anticus, 358
 of tibialis posticus, 358
- Tentorium, 14, 17
- Testicle, 272, 195
 descent of, 195
 injury to, 273
 inversion of, 274
 lymphatics of, 273
 mediastinum of, 272
 nerves of, 273
 pathological conditions affecting, 273
 retained or undescended, 273
 tunics of, 272
 vessels of, 273
- Thalami, optic, 23
- Thecal abscess, 428
- Thenar eminence, 426
- Thigh, 322
 amputation of, 327
 fasciæ of, 323
 septa from, 323
 fractures of, 325
 integuments of, 323
 muscles of, 323
 surface anatomy of, 322
- Third ventricle, 24
- Thomas's incision for removal of breast tumours, 160
- Thoracic aneurism, 167
 aorta, 166
 cavity, 160
 duct, 249
- Thoracoplasty, 172
- Thoracotomy, 153
- Thorax, 150
 deformities of, 150
 nerves of, 155
 paracentesis of, 153
 skin of, 150
 surface anatomy of, 150
 tumours of, 157, 167, 174
 vessels of, 164, 150
 viscera of, 164
 walls of, 152
 wounds of, 165
- Thrombosis, infective, 26
 marasmic, 27
- Thumb, 436
 amputation of, 437
 Hey's dislocation of, 437
- Thymus gland, 130, 161
- Thyro-glossal duct, 102, 103
- Thyro-hyoid bursa, 123
 membrane, 123
- Thyroid cartilage, 126
 cysts, 131
 dislocation of hip, 318
 gland, 128
 accessory, 131
 development of, 131
 excision of, 130
 in tracheotomy, 128
 isthmus of, 130
 lobes of, 128
 lymphatics of, 130
 nerves of, 130
 relations of, 129
 vessels of, 129, 130
- Thyroidectomy, 130
- Thyrotomy, 126
- Tibia, cuneiform osteotomy of, 352
 fractures of, 351
 head of, 341
 injuries to, 352
 nutrient foramen of, 351
 osteomyelitis of, 351
 rickets of, 351


- Tibia, sarcoma of, 341
 syphilitic disease of, 351
 tubercle of, 341
 vessels of, 351
- Tic-douloureux, 37, 87
- Toes, 369
- Tongue, 102
 dermoid of, 103
 epithelioma of, 105
 excision of, 105
 fissures of, 103
 foramen cæcum of, 103
 functions of, 102
 furrowed, 103
 lymphatics of, 104
 muscles of, 104
 nerve-supply of, 104
 paralysis of, 105
 septum, 105
 strawberry, 103
 tie, 103
 tumours of, 103
 ulcers of, 105
 vessels of, 103
- Tonsil, 108
 abscess of, 109
 bleeding from, 108
 calculi in, 109
 hypertrophy and deafness, 109
 lingual, 103
 Luschka's, 110
 lymphatics of, 108
 pharyngeal, 110
 tumours of, 109
 vessels of, 108
- Tonsillitis, 109
- Tonsillotomy, 108
- Torcular Herophilii, 26
- Torticollis, 118, 41
- Torus uterinus, 283
- Trachea, 127
 foreign bodies in, 168
 relations of, 127
 thoracic, 168
- Tracheal tugging, 167
- Tracheotomy, 128
- Trachoma, 58
- Tracts of cord, 32
- Transversalis fascia, 182, 189, 191
- Transverse colon, 223
 humeral ligament, 385
 sinus, 163
- Trapezium, 433
- Treitz, ligament of, 211
- Trendelenburg's operation, 250
- Trephining for middle meningeal artery, 26
 for intracranial lesions, 34
- Triangle, Bryant's, 300
 carotid, 112
 digastric, 121
 infrahyoid, 112, 123
 lingual, 122
 of Petit, 180, 241
 of Scarpa, 305
 occipital, 136
 rectal, 285
 subclavian, 135
 submaxillary, 112
 submental, 121
 suprameatal, 52
 urogenital, 285
- Triangles of neck, 112, 120
- Triangular fascia of Colles, 285,
 178, 265
 fibro-cartilage of wrist, 418
 ligament of urethra, 286
- Trichiasis, 55
- Tricuspid valve, 165
- Trigones of bladder, 259
- Trigonum femorale, 255
- Trismus, 93
- Trochanters, 314
 bursa of, 301
 fossa of, 300
 fracture of, 313
- Trochlea, 409
- Tropical abscess of liver, 233
- Tubal pregnancy, 281
- Tube, Eustachian, 47, 109
 Fallopian, 280
- Tuber ischii, 300
- Tubercle adductor, 329
 deltoid, 375, 399
 of Chassaignac, 133
 of Darwin, 42
 of Lisfranc, 136
 of Rolando, 32
 of tibia, 341
 scalene, 136
- Tumour, Pott's puffy, 17
- Tunica albuginea, 265, 272
 vaginalis, 197, 272
- Turbinal bones, 77
- Tympanic antrum, 45
 attic, 45
 membrane, 44
 incision of, 45
 rupture of, 45
 ossicles, 45
 promontory, 46
- Tympanum, 45
 attic of, 45
 boundaries of, 45
 infection of and spread from,
 48, 50

- Tympanum, mucous membrane
 of, 45
 museles of, 47
 nerves of, 47
 pyramid of, 47
 relation of faecal nerve to, 46
 roof of, 46
 vessels of, 47
- Uleer, duodenal, 211
 of stomach, 207
 stercoral, 218
- Ulna, 416
 dislocation of, 413
 fracture of, 419
 nutrient vessel of, 416
 ridge of, 414
 styloid process of, 421, 422
 upper extremity of, 409
- Umbilical canal, 187
 cord, 185
 fistula, 186
 hernia, aquired, 187
 congenital, 186, 187
 infantile, 187
 loop, 186
 notch of liver, 229
 region, 177
 ring, 185
 vesicle, 186
- Umbilicus, 185, 178
 fibrous ring of, 186
 fistulæ at, 186, 187
 vessels of, 186
- Umbo of membrana tympani, 44
- Uneinate process of ethmoid, 78
 of pancreas, 235
- Undescended testicle, 273
- Upper extremity, 375
 jaw, 88
 excision of, 89
 fracture of, 88
 tumours of, 89
- Uraehus, 186
- Uranoplasty, 108
- Ureter, abdominal, 247
 distension of, 247
 implantation of, 248
 pelvic, male, 253
 female, 284
 pelvis of, 245
 relations of, 247
 rupture of, 248
 vaginal palpation of, 284
 wounds of, 247
- Urethra, curves of, 262
 false passages in, 264
 female, 262
- Urethra, fossa navicularis of, 263
 male, 262
 membranous, 263
 narrowest parts of, 264
 nerve-supply, 265
 prostatic, 263
 rupture of, 264, 287
 spongy portion of, 263
 stricture of, 263
 gonorrhœal, 264
 syphilitic, 264
 traumatic, 264
- Urethral earuncle, 262
- Urinary fistula, 187
- Urine, extravasation of, 264, 287
 incontinence of, 297
- Urogenital sinus, 266
 space, 285
- Utero-sacral folds, 253
- Uterus, 275
 arbor vitæ of, 276
 bicornis, 279
 body of, 275
 broad ligaments of, 279
 carcinoma of, 276
 cavity of, 276
 cervix of, 275
 development of, 279
 external os of, 275
 flexion of, 275
 fundus of, 275
 inflammation of, 276
 interior of, 276
 internal os, 275
 lymphatics of, 277
 nerves of, 277
 operations on, 276
 peritoneum of, 275
 prolapse of, 275
 relations of, 276
 retroversion of, 275
 surgical affections of, 276
 vessels of, 276
- Uveal tract, 65
- Uvula vesicæ, 260
- Vagina, 277
 dilatability, 279
 fornices of, 278
 lymphatics of, 279
 nerves of, 279
 relations of, 279
 rugæ of, 277
 sphincter of, 279
 vessels of, 279
 walls of, 279
- Vaginal cystocele, 261, 279
 cystotomy, 262

- Vaginal enterocele, 279
 fistulæ, 261
 fornices, 278
 hernia, 279
 process, 196
- Vaginismus, 279
- Valsalva, sinus of, 166
- Valsalva's method of inflating the middle ear, 48
- Valve, ileo-cæcal, 221
 function of, 222
- Valves, anal, 293
 of heart, 164
 rectal, of Houston, 290
- Valvulæ conniventes, 215
- Varicocele, 272
- Varicose veins, 346
 cause of pain in, 345
- Vasa efferentia, 271
- Vas aberrans of arm, 398
 deferens, 270
 ampulla of, 270
 artery of, 271
 palpation of, 271
- Vater, ampulla of, 235
- Vault of skull, fracture of, 11
- Veins. See Various regions
 angular, 86
 axillary, 392
 azygos, 161
 basilic, 397, 405
 brachial, 397
 cava inferior, 248
 superior, 165
 cephalic, 377, 405
 of thumb, 422
 coronary, 206
 diploic, 10
 dorsal, of penis, 266
 emissary, of skull, 10
 epigastric, 179
 facial, 86
 femoral, 311
 hæmorrhoidal, 293
 hepatic, 232
 iliac, 256
 innominate, 377
 intercostal, 154
 internal saphenous, 194
 jugular, anterior, 113
 external, 113
 internal, 135
 long saphenous, 306, 311, 323
 thoracic, 391
 mastoid, 10, 28
 median, 405
 basilic, 397, 407
 cephalic, 405
- Veins, mesenteric, 216, 226
 nasal, 77
 of foramen cæcum, 10
 of Galen, 28
 ophthalmic, 72
 orbital, 10
 pampiniform plexus, 272
 para-umbilical, 179
 parietal, 10
 popliteal, 333
 portal, 231
 prostatic plexus, 267
 pterygoid plexus, 98
 radial, 414
 ranine, 103, 122
 renal, 244
 Salvatella, 425
 short saphenous, 331
 spermatic, 272
 splenic, 238
 subclavian, 378
 thoraco-epigastric, 179
 thyroid, 130
 uterine, 276
 utero-vaginal plexus, 277
 ulnar, 414
 umbilical, 179
 vertebral, 143
 vorticosæ, 72
- Veins, air in, 135, 391, 392
 canalized, 391
 circulation in, 346
 emissary, of skull, 10
 of neck, wound of, 135
- Velum interpositum, 18
- Venesection, 407
- Venous plexus, pampiniform,
 272
 prostatic, 267
 pterygoid, 98
 utero-vaginal, 277
- Ventral hernia, 178, 221
- Ventricles of brain, 24, 31
 of larynx, 125
- Vermiform appendix, 218
 abscess of, 221
 coproliths of, 220
 foreign bodies in, 220
 function of, 220
 gangrene of, 220
 inflammation of, 220
 lymphatics of, 220
 mesentery of, 219
 nerves of, 220
 operations on, 220
 pathological changes in,
 220
 structure of, 219

- Vermiform appendix, valve of, 219
 function of, 220
 variations in position of, 219
 vessels of, 219
- Vermis of cerebellum, 30
- Vertebra, aneurismal erosion of, 141
 caries of, 141
 prominens, 112
- Vertebral aponeurosis, 239
 column, 139
 fracture dislocation of, 142
 sprains of, 141
 bodies, 141
 curves, 140
 discs, 141
- Vertex of skull, 3
- Verumontanum, 260, 263
- Vesicocele, 279
- Vesicle, umbilical, 186
- Vesico-vaginal fistula, 261
- Vesiculi seminales, 269
 inflammation of, 270
- Vestibule of larynx, 125
 of mouth, 100
 of nose, 76
- Visceroptosis. See Various organs
- Vitello-intestinal duct, 186
- Vitreous humour, 70
 affections of, 71
 fossa patellaris of, 69, 70
 hyaloid, canal of, 71
 membrane of, 70
- Vocal cords, 125
- Volvulus, 225
- Vulva, 284
- Wardrop's operation, 133
- Water-bed of brain, 18
- Weaver's bottom, 302
 eye, 72
- Wen, 5
- Wharton's duct, 102
 jelly, 187
- White line at anus, 293
 of pelvic fascia, 251
- Whitlow, 426
- Wilde's incision, 53
- Willis, circle of, 28
- Winslow, foramen of, 201
 ligament of, 338
- Wirsung, duct of, 236
- Wolffian ducts, 266
- Word-hearing centre, 21
- Word-seeing centre, 21
- Wormian bones, 11, 2
- Wrist, 421
 drop, 439
 joint, 432
 amputation at, 435
 dislocation of, 434
 excision of, 434
 ligaments of, 431
 movements at, 434
 synovial cavities of, 433
 surface anatomy of, 421
 tendons of, 431
- Wry-neck, 118
- Y-shaped ligament of femur, 315
 cartilage of acetabulum, 312
- Yolk-sac, 186
- Zona ophthalmica, 65
 orbicularis of eyeball, 66
 of hip, 314
- Zonule of Zinn, 70
- Zygoma, fracture of, 98
- Zygomatic abscess, 97
 fossa, 96

THE END



An Abridged List of Works

PUBLISHED BY

BAILLIÈRE, TINDALL & COX.

AXENFELD'S Bacteriology of the Eye.

Translated by ANGUS MACNAB, F.R.C.S.

Royal 8vo. Pp. xv+410, with 105 Illustrations, mostly coloured.
Price 21s. net.

BALL'S Diseases of the Nose and Pharynx.

Fifth Edition. Demy 8vo. Pp. viii+392, with 78 Illustrations. Price
7s. 6d. net.

BIANCHI'S Text-book of Psychiatry.

Royal 8vo. Pp. xvi+904, with 106 Illustrations. Price 21s. net.

BROADBENT'S Heart Disease.

Fourth Edition. Demy 8vo. Pp. xvi+480, with Coloured Plate and
39 Illustrations. Price 12s. 6d. net.

BROWN'S Physiological Principles in Treatment.

Demy 8vo. Pp. viii+344. Price 5s. net.

BUCHANAN'S Manual of Anatomy, Systematic and Practical, including Embryology.

In 2 volumes. Price 12s. 6d. each net. Or complete in 1 volume. Price
21s. net. Demy 8vo. Pp. 1572, with 631 Illustrations, mostly original,
and in several colours. (*University Series of Manuals.*)

CHILDE'S Operative Nursing and Technique. A Hand- book for House-Surgeons, Dressers, and Nurses.

Demy 8vo. Pp. xii+224, with 8 Plates and 91 Illustrations. Price
3s. 6d. net.

CLAYTON'S Compendium of Food Microscopy. With Sections on Drugs, Water, and Tobacco.

Compiled, with Additions and Revisions, from the Works of the late Dr.
A. H. HASSALL.

Demy 8vo. Pp. xl+432, with 89 Plates and 282 Illustrations. Price
10s. 6d. net.

CROOK'S High-Frequency Currents.

Second Edition. Demy 8vo. Pp. x+206 with 44 Illustrations. Price
7s. 6d. net.

FRENCH'S Medical Laboratory Methods and Tests.

Second Edition. Pp. viii+168, with 2 Coloured Plates and 88 original Illustrations. Leather, gilt tops. Price 5s. net.

FREYER'S Clinical Lectures on Surgical Diseases of the Urinary Organs.

Demy 8vo. Pp. viii+425, with 141 Illustrations, mostly original. Price 12s. 6d. net.

GARDNER'S Surgical Anæsthesia.

[*In the Press.*]

Price 5s. net.

GILES' Gynæcological Diagnosis.

Demy 8vo. Pp. x+212, with 39 original Figures. Price 7s. 6d. net.

Handbook for Attendants on the Insane.

Published by the Authority of the Medico-Psychological Association. Fifth Edition, much enlarged. Thirty-third Thousand. Pp. xvi+390, with 20 Illustrations. Price 2s. 6d. net.

HEINE'S Operations on the Ear: The Operations for Suppurative Otitis Media and its Intracranial Complications.

Translated from the Second German Edition by W. LOMBARD MURPHY, F.R.C.S. Demy 8vo. Pp. xiv.+204, with 56 Illustrations. Price 8s. 6d. net.

JELLETT'S Manual of Midwifery.

Pp. xxiv+1176, with 9 Plates and 467 Illustrations, plain and coloured. Price 21s. net.

KELYNACK'S Tuberculosis in Infancy and Childhood.

Royal 8vo. Pp. xiv+376, with 28 Illustrations. Price 12s. 6d. net.

KERR'S Operative Midwifery.

Royal 8vo. Pp. xii+705, with 294 Illustrations, mostly original. Price 21s. net.

KITT'S Textbook of Comparative General Pathology.

Royal 8vo., with 4 Coloured Plates and 131 Illustrations. Price 25s. net.

KNOCKER'S Accidents in their Medico-Legal Aspect.

A Practical Guide for the Expert Witness, Solicitor, and Barrister, by leading Medical Authorities. Price 21s. net. [*In the Press.*]

LAMB'S Practical Guide to the Diseases of the Throat, Nose, and Ear.

Crown 8vo. Pp. xvi+322, with 55 Illustrations. Price 7s. 6d. net.

LATHAM'S Pulmonary Tuberculosis.

Third Edition. Demy 8vo. Pp. viii+260. Price 5s. net.

LAVERAN & MESNIL'S Trypanosomes and the Trypanosomiases.

Translated and Edited by DAVID NABARRO, M.D.
Royal 8vo. Pp. 538, with Coloured Plate and 81 Illustrations. Price 21s. net

LEEDHAM-GREEN'S Gonorrhœa in the Male.

Second Edition. Demy 8vo. Pp. xii+160, with 47 Illustrations. Price 5s. net.

LINDSAY'S Diseases of the Lungs.

Second Edition. Demy 8vo. Pp. x+510. Price 10s. 6d. net.

McKAY'S Operations upon the Uterus, Perineum, and Round Ligaments.

Demy 4to., Pp. xvi+454, with 148 original Plates. Price 21s. net.

McKISACK'S Dictionary of Medical Diagnosis.

Demy 8vo. Pp. xii+584, with 77 Illustrations. Price 10s. 6d. net.

MARSHALL'S Syphilology and Venereal Disease.

Demy 8vo. Pp. x+509, with 17 Illustrations. Price 10s. 6d. net.

MAY & WORTH'S Diseases of the Eye.

Second Edition. Demy 8vo. Pp. viii+400, with 336 Illustrations, including 22 Coloured Plates. Price 10s. 6d. net.

MINETT'S Differential Diagnosis of Bacteriology.

Crown 8vo. Pp. viii+72. Price 2s. 6d. net.

MONRO'S Manual of Medicine.

Second Edition. Demy 8vo. Pp. xxii+1022, with 42 Illustrations, plain and coloured. Price 15s. net. (*University Series of Manuals.*)

MOOR & HEWLETT'S Applied Bacteriology.

Third Edition. Pp. xii+480, with 81 Coloured and 29 plain Illustrations. Price 12s. 6d. net. (*University Series of Manuals.*)

MUMMERY'S After-Treatment of Operations.

Third Edition. Crown 8vo. With about 40 Illustrations. Price 5s. net.

OSTERTAG'S Handbook of Meat Inspection.

Third Edition. Royal 8vo. Pp. xxxvi+886, with Coloured Plate and 260 Illustrations. Price 31s. 6d. net.

PALMER'S Lessons on Massage.

Third Edition. Demy 8vo. Pp. xvi+272, with 118 original Illustrations, plain and coloured. Price 7s. 6d. net.

POLITZER'S Text-book of Diseases of the Ear.

Fifth Edition, entirely rewritten. Translated by M. J. BALLIN, M.D., and P. H. HELLER, M.D.
Royal 8vo. Pp. xiv + 892, with 337 original Illustrations. Price 25s. net.

RAMSAY'S Diathesis and Ocular Diseases.

Crown 8vo. Pp. viii + 184, with 17 Plates. Price 3s. 6d. net.

ROBERTSON'S Meat and Food Inspection.

Demy 8vo. Pp. x + 372, with 40 Illustrations. Price 10s. 6d. net.

ROSE & CARLESS' Manual of Surgery.

Seventh Edition. Demy 8vo. With many new and original Illustrations. Price 21s. net.

SAWYER'S (J. E. H.) Physical Signs.

Crown 8vo. Pp. xii + 188, with 23 Illustrations. Price 5s. net.

STARR'S Organic and Functional Nervous Diseases.

Second Edition. Royal 8vo. Pp. 816, with 26 Plates, plain and coloured, and 282 Figures in the text. Price 25s. net.

STEWART'S Manual of Physiology.

Fifth Edition. Pp. xviii + 912, with 2 Coloured Plates and 395 Illustrations. Price 15s. net. (*University Series of Manuals.*)

SUTHERLAND'S Blood-Stains.

Demy 8vo. Pp. xiv + 167, with 10 Coloured and 8 plain Illustrations. Price 10s. 6d. net.

TREGOLD'S Mental Deficiency.

Demy 8vo. Pp. xviii + 391, with 67 Illustrations and 9 Charts. Price 10s. 6d. net.

TUCKEY'S Treatment by Hypnotism and Suggestion.

Fifth Edition. Demy 8vo. Pp. xviii + 418. Price 10s. 6d. net.

WALSH'S The Röntgen Rays in Medical Work.

Fourth Edition. Demy 8vo. Pp. xviii + 434, with 172 Plate and other Illustrations. Price 15s. net.

WHEELER'S Operative Surgery.


Crown 8vo. Pp. xii + 300, with 134 Illustrations. Price 5s. net.

WILLIAMS' Minor Maladies and their Treatment.

Second Edition. Crown 8vo. Pp. xii + 404. Price 5s. net.

LONDON :

BAILLIÈRE, TINDALL & COX, 8, HENRIETTA ST., COVENT GARDEN.



L/12

21.7.

11

72

GLASGOW
UNIVERSITY
LIBRARY:

