





*The glands of the ciliary body in the human eye.*

By E. TREACHER COLLINS.

(With Plates II and III.)

MANY ingenious experiments have during the last few years been performed for the purpose of determining the source of the aqueous humour, and of the nutrient fluids of the lens and vitreous. That the aqueous was secreted by some part of the walls of the posterior chamber seemed likely by its accumulation behind the iris when the pupil became closed, either by total posterior or total anterior synechiæ. It seemed improbable that it came from the iris, for in cases of aniridia, either congenital or traumatic, no alteration in its constituents or in its amount was noticed.

Deutschmann\* excised the iris and ciliary body from the eye of a rabbit, and found that secretion of the aqueous was arrested, and that the vitreous shrank.

Schœler and Uhthoff,† adopting a method of subcutaneous injection of a solution of fluoresceine originally suggested by Ehrlich, found that from four to ten minutes after such injection the colouration could be detected coming through the pupil into the anterior chamber. On dissection of eyes excised at various periods after subcutaneous injection, they found that simultaneously with or immediately after the colouration of the pupil, some of the

\* 'Archiv für Ophth.,' xxvi, iii, p. 117.

† 'Jahresbericht über die Wirksamkeit der Augenklinik,' von Prof. Schœler, 1882, p. 52.

furrows between the ciliary processes were tinged with green. These green lines grew narrower in the direction of the equator of the eye, and ended at the posterior limit of the processes. There was also a gradual colouration of the vitreous body proceeding from the ciliary processes and passing backwards. In an eye in which the ciliary processes had become atrophied or destroyed in consequence of previous cyclitis no colour entered the anterior chamber through the pupil, and on section the atrophied processes were almost entirely destitute of colouration. These experiments seem to prove that the aqueous and the nutrient fluid of the vitreous are secreted in the ciliary region. They are confirmed by those of Leplat,\* who injected iodide of potassium subcutaneously, and after enucleation cut up the frozen eyeballs into zones, testing each zone quantitatively for iodine with starch. At the present time there are appearing in the 'Archives d'Ophtalmologie' † a series of articles by M. Nicati, in which he claims to have established, on histological, physiological, and pathological grounds, the existence of a glandular apparatus for the elaboration of the aqueous humour. His histological researches refer to rabbits' eyes, and he speaks of the pars ciliaris retinæ as the gland of the aqueous humour.

In order to study accurately the arrangement of the pigmented portions of the human eyeball, I have tried several different methods for bleaching sections of it. The one which up to the present time I have found answer best is briefly as follows:—I place the sections from an eye which has been previously embedded in celloidin, into some water which has been thoroughly mixed with chloride of lime and then filtered. After they have remained in this for about three minutes I transfer them to water acidulated with hydrochloric acid (m℥ to ʒj). The sections must be passed backwards and forwards from these two solutions until the pigment quite disappears. I then

\* 'Annales d'oculistique,' vol. xxviii, p. 89.

† Vols. x and xi,

transfer them to water mixed with liq. ammoniæ (mj to ʒiv) to get rid of the chlorine, when after thoroughly washing in three changes of distilled water they can be stained with logwood. The manipulation of the sections requires considerable care, as after exposure for some time to the chlorine they have a great tendency to come to pieces—the substance of the cornea peeling off Descemet's membrane, the choroid separating from the uveal pigment layer of the retina, and so forth, in spite of the embedding celloidin. In fact, it is not easy to get a perfect section first bleached and then stained. Bleached sections of an eyeball show quite distinctly that the uveal pigment on the posterior surface of the iris is composed of two layers. I have given a description of the arrangement of the cells in these layers in the current number of the 'Ophthalmic Hospital Reports.'\*

At the root of the iris the inner of these two layers loses its pigment, and the part which extends from this point to the ora serrata is spoken of as the pars ciliaris retinae. The outer of the two layers continues pigmented, and it is of it which I am going to speak especially tonight. From my bleached sections I find that this layer from the root of the iris to the ora serrata consists of a single row of somewhat flattened cells, projecting from the outer surface of which are numerous little processes, each composed of a group of cells. These processes vary in size and number in different parts. Thus in the anterior portion of the plicated part they are small, few, and far apart, confined to the depressions between the ciliary processes, none being situated at their apices. In the posterior portion of the plicated part, and at its junction with the non-plicated part, they are largest and most numerous. They present here a very striking appearance, being pear-shaped, connected by their stalks with the surface, and having their rounded ends projecting towards the ciliary muscle. Some of them can be made out to be composed of two parallel rows of cells (Plate II, figs. 1

\* Vol. xiii, pt. i, p. 63.

and 2). In the non-plicated part of the ciliary body they lose their pyriform outline, are smaller and more widely separated. They give rise to the elevations and depressions in the lamina vitrea which have been described by several observers, forming what Müller termed the reticulum of the ciliary body. Immediately in front of the ora serrata the projecting processes of cells from this layer again alter in character. They are here broader than elsewhere, very definitely composed of two rows of cells, and having a direction somewhat outwards and backwards. From the ora serrata to the optic nerve the uveal pigment consists of but a single layer of cells, without any outgrowths projecting from it.

By the examination and comparison of a large number of bleached and unbleached sections of the ciliary region cut on the flat, I have been able to make out that the cells of these projecting processes are arranged in rings with a central lumen. Their tubular character is, however, much better shown when they have become enlarged in pathological conditions.

The above description is based upon the examination of a large number of eyes of various ages.

There are, then, situated in that portion of the eye which experimental evidence points to as the part from which the aqueous humour and nutrient fluid of the vitreous are secreted, numerous little tubular downgrowths of cells opening towards the interior of the eye, and separated only from the close vascular plexus of the ciliary region by a basement membrane. Their number in any one section it is impossible to count. The number in the whole circumference of the globe must be something enormous.

I have sought widely, but have been unable to find any description of these tubular processes; the reason being, I think, that they have remained hidden in their own pigment. The inference that they are glands concerned in the elaboration of the aqueous humour and nutrient fluid of the vitreous seems to me irresistible. If this is so, we



should expect to find them subject to the same diseases as secreting tubular glands in other parts of the body.

The disease which was originally described by Wardrop in 1808 as *aquo-capsulitis*, and which is now generally spoken of as *serous iritis*, is, I believe, primarily a catarrhal inflammation of these glands. The whole course of the disease points, I think, in this direction. I would interpret its symptoms as follows:—It commences with congestion of the blood-vessels around the glands, which manifests itself as circumcorneal injection. This is not associated with pain and photophobia, as usually occurs in iritis. The secretion from the glands becomes augmented, causing increase in the aqueous humour and deepening of the anterior chamber. It also becomes altered in character, more albuminous than usual, and containing a few leucocytes, some pigmented epithelial cells which have desquamated from the surface of the glands, and some shreds of fibrin. These formed elements tend to gravitate to the lower part of the anterior chamber, and to be deposited on the posterior surface of the cornea, forming the spots of "*keratitis punctata*," some of which are often pigmented, the pigments being derived from the desquamated cells above mentioned. Some of the leucocytes also collect in the meshes of the *ligamentum pectinatum*, thus tending somewhat to obstruct the exit of fluids from the eye.

This obstruction, combined with the excess of secretion, readily leads to increased tension, which is only temporarily relieved by iridectomy or paracentesis.

As the result of these changes in the composition of the aqueous it becomes slightly turbid, which turbidity produces an alteration in the colour of the iris. This latter is not at first affected, and there is no tendency to the formation of *synechiæ* until in the later stages, when it has become secondarily involved. The vitreous is early noticed to contain flocculi. The course of the disease, as in all catarrhs, is very variable, and there is great tendency to relapses.

Severe cases end in disorganisation of the structures which receive their nutrient fluids from these glands. Thus the vitreous shrinks, the lens becomes cataractous, and a condition of *phthisis bulbi* results. Besides being a primary disease, catarrh of these glands frequently follows on or accompanies inflammation in surrounding structures.

The histological appearances of sections from eyes affected with so-called serous iritis are quite in keeping with the theory I have given of its pathology. There is some increase in the size of the glands, some irregularity and proliferation of their epithelium, enlargement of the blood-vessels in their vicinity, and a variable amount of round-cell infiltration about them.

When inflammation in the ciliary region has been of a more plastic character the pigmented epithelium often shows more marked structural changes. There is considerable overgrowth of it, this overgrowth presenting a characteristic arrangement of its cells in the form of cylindrical tubes. I cannot do better than quote a description of this condition which has been given by Alt,\* and with which my own observations quite coincide. Speaking of plastic cyclitis and cyclitic membranes, he says, "Meanwhile the cells of the uveal layer have also undergone proliferation. The whole layer appears very much thickened, and grows into the cyclitic membrane in an irregular way. We also observe, however, frequently a more typical kind of proliferation of the cells of the uveal layer in the shape of cylindrical tubes (Plate III, fig. 1), which grow into the cyclitic membrane and give off branches. In longitudinal and transverse sections these tubes appear like the glandulæ tubulosæ, or the epithelial cylinders of an epithelioma.

"The cells of these tubes are either free of pigment or pigmented. Their shape and arrangement with their branches have given some authors (Schliess-Gemusens) the idea that they were blood-vessels whose walls were filled with pigment. Specimens in which the blood-vessels

\* 'Lectures on the Human Eye,' p. 106.



have been injected with a coloured fluid, however, plainly show that they are widely different from blood-vessels. They appear, as stated, just like glands or epithelioma cylinders."

"Not all the cells originating by proliferation from the uveal layer are pigmented, and I am even convinced that the young cells of this layer are at first always unpigmented, and form their pigment only later on. For this reason we find in cyclitic membranes also the same tubular formations without any pigment at all, which can nearly always be traced backwards to a pigmented cell-tube or the uveal layer itself." He gives woodcuts showing these cylindrical tubes. He also mentions and pictures what he calls "a tumour-like new formation of pigmented and unpigmented cell-cylinders, starting from the uveal layer of the ciliary body and neighbouring choroid."\* This tumour-like new formation growing in the region where I find these tubular glands situated I regard as an adenoma.

I have examined several ciliary-body tumours preserved in the Moorfields Hospital laboratory, and have found two, the cells of which are of an epithelial type.

One from a girl of nineteen, described as a melanotic sarcoma, was very densely pigmented. So little of it that I could bleach was preserved, that beyond determining its cells to be of an epithelial character I could make little out as to its nature. The other was from a woman aged sixty-three, who twenty-five years previously had had a severe blow on the eye from a fist, and two years subsequently had found that it was blind. It gave her no trouble until nine weeks previous to enucleation, when pain and inflammation set in. The growth, which was partially pigmented, sprang from the ciliary processes, and invaded the ciliary muscle and root of the iris. It was originally described as a sarcoma which had undergone mucoid degeneration. It was subsequently re-examined and shown by Mr. Solly at a meeting of the Pathological

\* *Ibid.*, p. 123.

Society on April 15th of last year, as "a melanotic growth from the eye which appeared to be epithelial." I have cut some more sections of this tumour and bleached them, and there can be no doubt of the epithelial character of its cells. In some parts of the tumour they have undergone colloid degeneration, while in others, especially towards its base, which is the most pigmented part, they are grouped in parallel columns cut in various directions (Plate III, fig. 2). The patient was seen twenty-three months after enucleation; there had been no return of the growth, and she was quite well. This growth I regard as a melanotic glandular carcinoma, and I think it highly probable that some other melanotic tumours growing in this region which have been described as sarcomata may have been of a similar nature.

To conclude, then, I claim that there are situated in the region which experimental evidence has proved to be the part from which the aqueous humour and nutrient fluid of the vitreous are secreted, numerous little tubular processes of epithelial cells, which can be nothing else than glands concerned in their elaboration; that the nature of these processes has been hidden by their pigment, and is only rendered evident in bleached sections. That these glands are, like secreting glands elsewhere, subject to attacks of catarrhal inflammation, which gives rise to the group of symptoms generally included under the term serous iritis. That as the result of chronic inflammation there may be considerable overgrowth of their tissue, which overgrowth preserves a glandular type; and that they may be the seat of tumours, either adenoma or glandular carcinoma.

(*March 12th, 1891.*)



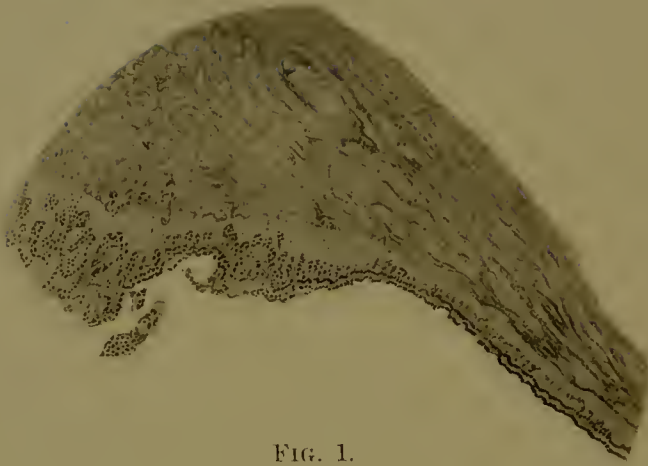

FIG. 1.

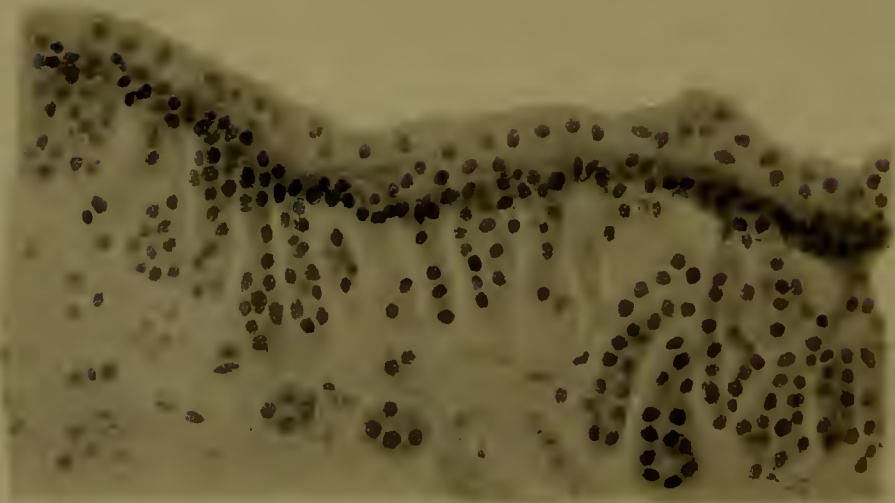


FIG. 2.

## DESCRIPTION OF PLATE II.

Illustrating Mr. Treacher Collins's paper on the Glands of the Ciliary Body in the Human Eye.

FIG. 1.—Bleached section of a normal eye showing the glands of the ciliary body.  $\times 120$ .

FIG. 2.—Glands of ciliary body; bleached section.  $\times 300$ .



### DESCRIPTION OF PLATE III.

Illustrating Mr. Treacher Collins's paper on the Glands of the Ciliary Body in the Human Eye.

FIG. 1.—Overgrowth of the glands of the ciliary body in a cyclitic membrane. × 300.

FIG. 2.—Melanotic new growth originating in the glands of the ciliary body; bleached section. × 300.

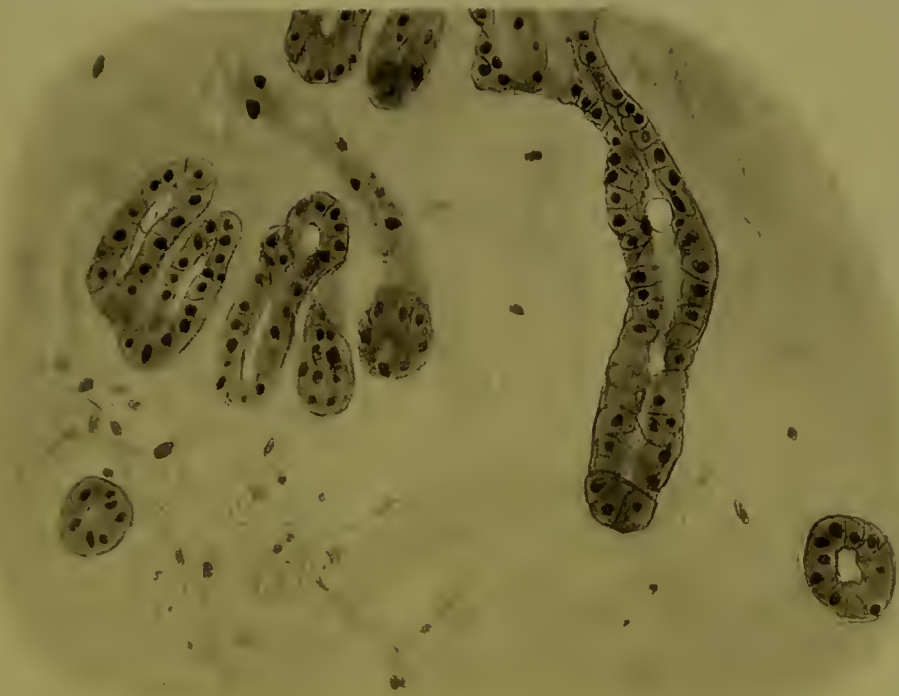


FIG. 1.

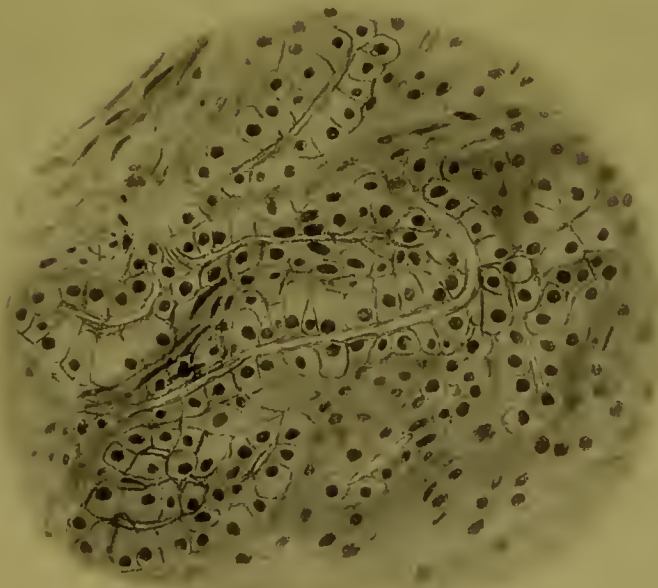


FIG. 2.





