

LIGAMENTS AND MUSCLES
OF
THE HORSE



S. SISSON, V. S.

ns



JOHN A. SEAVERNS



3 9090 013 413 154

Webster Family Library of Veterinary Medicine
Cummings School of Veterinary Medicine at
Tufts University
200 Westboro Road
North Grafton, MA 01536

LIGAMENTS AND MUSCLES

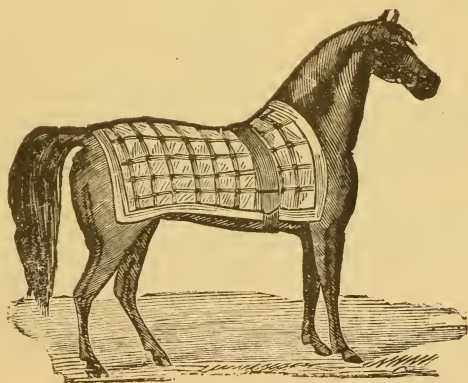
-- OF --

THE HORSE.

BY

S. SISSON, V.S.,

Demonstrator of Anatomy, Ontario Veterinary College, Toronto, Canada.



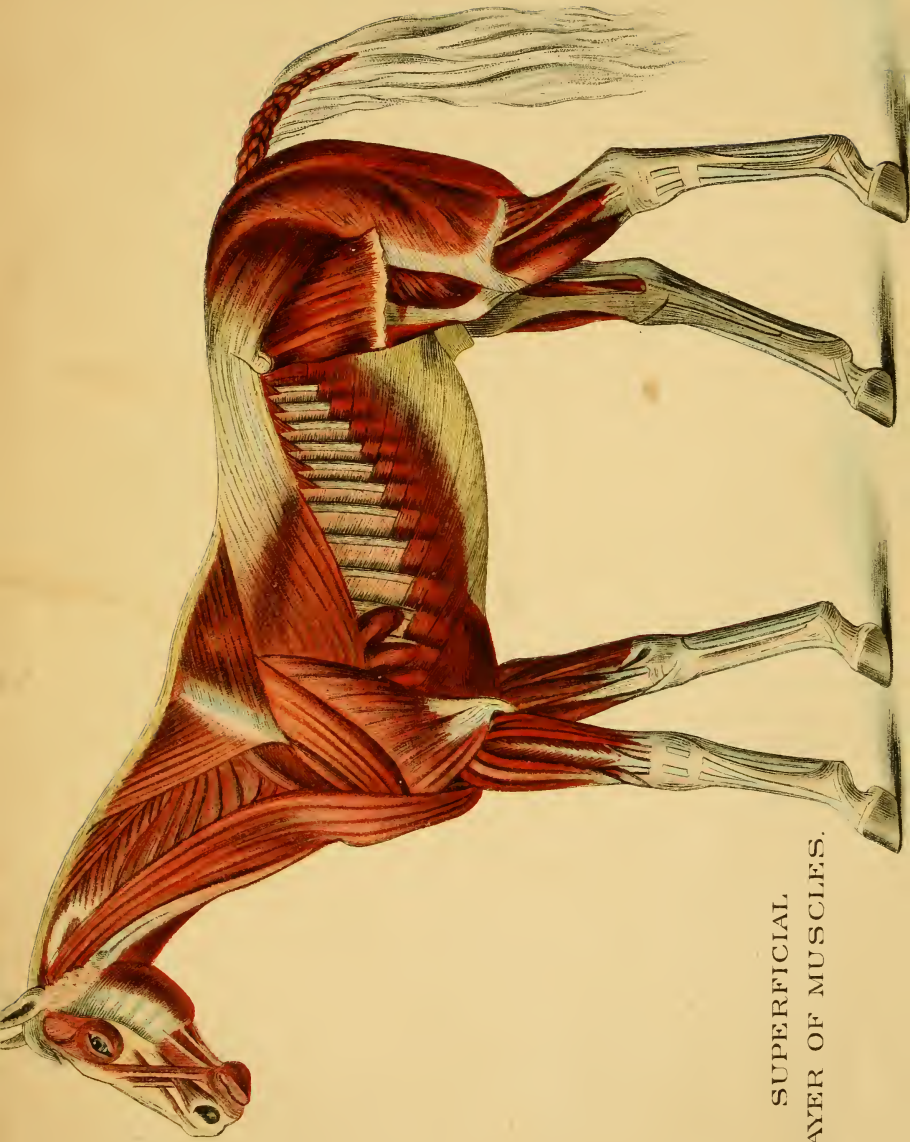
Toronto:

J. A. CARVETH & CO.

1895.

5
57
95

Entered according to Act of Parliament of Canada, in the year one thousand eight hundred and ninety-four, by J. A. CARVETH, at the Department of Agriculture, Ottawa.



SUPERFICIAL
LAYER OF MUSCLES.

PREFACE.



In the following pages an attempt is made to give the principal ligaments and skeletal muscles of the horse in a condensed and simplified form. Consequently, the smaller ligaments of the complex joints have been entirely omitted. The muscles of the eye, ear, larynx, etc., have also been omitted, as belonging more properly to the description of the special organs with which they are connected.

INDEX.

LIGAMENTS :	PAGE
Anterior common of knee.....	15
" of elbow.....	14
" of fetlock.....	16
" of hock.....	22
Antero-lateral of coffin-joint.....	18
Arciform.....	15
Astragalo-metatarsal.....	23
Atlo-axoid.....	11
Calcaneo-cuboid.....	23
Capsular, chondro-sternal.....	13
" hip.....	20
" femoro-patellar.....	21
" inter-transverse lumbar.....	10
" intervertebral.....	9
" shoulder.....	14
" sacro-iliac.....	19
" temporo-maxillary.....	12
Chondro-xiphoid.....	13
Costo-transverse.....	12, 13
Costo-vertebral.....	12
Cotyloid.....	20
Crucial.....	21
Inferior common.....	9
" sacro-iliac.....	19
" sesamoidean.....	17
Interarticular.....	12
Interosseus, of coffin-joint.....	18
" radio-ulnar.....	14
" tibio-fibular.....	22
Intersesamoidean.....	17
Interspinous.....	10
Intertransverse.....	9
Intervertebral substance.....	9
Lateral of elbow.....	14
" femoro-patellar.....	21
" femoro-tibial.....	20
" of fetlock.....	16
" of knee.....	15
" of pastern.....	17
" sesamoidean.....	17
" of hock.....	22
Ligamentum nuchae.....	10
" teres.....	20
Occipito-atloid.....	11
Patellar.....	21
Posterior, femoro-tibial.....	21
" of hock.....	22
" of knee.....	15
" temporo-maxillary.....	12
Postero-lateral of coffin-joint.....	18
Pubio-femoral.....	20

LIGAMENTS— <i>Continued.</i>	PAGE
Round.....	20
Sacro-Sciatic.....	19
Stellate.....	12
Straight, patellar.....	21
Styloid.....	11
Subcarpal, (or check).....	15
Subflava.....	10
Subtarsal, (or check).....	23
Superior, common.....	9
" Sacro-iliac.....	19
" Sesamoidean.....	16, 17
Supraspinous.....	10
Suspensory.....	16, 17.
Tarso-metatarsal.....	23
Transverse, (of hip).....	20
MUSCLES :	
Adductor brevis.....	52
" longus.....	52
" magnus.....	51
Anconeus.....	44
Antea spinatus.....	42
Anterior deep pectoral.....	37
" superficial pectoral.....	37
Biceps rotator tibialis.....	51
Buccinator.....	33
Caput magnum.....	44
" medium.....	44
" parvum.....	44
Complexus.....	27
Compressor coccygis.....	32
Coraco-humeralis.....	43
Coraco-radialis.....	43
Curvator coccygis.....	32
Deltoid.....	42
Depressor labii inferioris.....	33
" labii superioris.....	34
" coccygis.....	32
Diaphragm.....	31
Digastricus.....	35
Dilatator naris inferior.....	34
" naris lateralis.....	34
" naris superior.....	34
" naris transversalis.....	34
Erector coccygis.....	32
Extensor metacarpi magnus.....	45
" " obliquus.....	45
" " pedis (fore-limb).....	45
" " " (hind-limb).....	53
" " " brevis.....	56
" " suffraginis.....	46

MUSCLES— <i>Continued.</i>	PAGE
External intercostal.....	38
“ pterygoid.....	35
Flexor metacarpi externus.....	46
“ “ internus.....	46
“ “ medius.....	46
“ metatarsi.....	54
“ pedis accessorius.....	56
“ pedis perforans, (fore-limb).....	47
“ “ “ (hind-limb).....	55
“ “ perforatus, (fore-limb).....	47
“ “ “ (hind-limb).....	55
Gastrocnemius.....	55
Gemellus.....	53
Genio-hyoideus.....	36
Glutei.....	49
Gracilis.....	52
Humeralis obliquus.....	43
Hyoideus parvus.....	36
Hyoideus transversus.....	37
Iliacus.....	30
Internal intercostal.....	38
“ pterygoid.....	35
Interossei.....	48
Intertransversales colli.....	26
“ lumborum.....	30
Ischio-femoralis.....	52
Lateralis sterni.....	39
Latissimus dorsi.....	28
Levatores costarum.....	39
Levator humeri.....	24
“ labii superioris alaeque nasi.....	33
“ “ “ proprius.....	33
“ menti.....	33
Longissimus dorsi.....	29
Longus colli.....	26
Lumbrici.....	48
Masseter.....	34
Mylo-hyoideus.....	36
Obliquus abdominis externus.....	40
“ “ internus.....	40
“ capitis anticus.....	27
“ “ posticus.....	28
Obturator externus.....	52
“ internus.....	53
Occipito-styloideus.....	36
Orbicularis oris.....	32
Panniculus.....	24
Pectineus.....	52
Peroneus.....	54
Popliteus.....	55

MUSCLES—*Continued.*

PAGE

Postea-spinatus.....	42
Posterior, deep pectoral.....	38
“ superficial pectoral.....	37
Psoas magnus.....	30
“ parvus.....	30
Pyiformis.....	53
Quadratus lumborum.....	30
Rectus abdominis.....	40
“ capitis anticus major.....	25
“ “ “ minor.....	25
“ “ “ lateralis.....	25
“ “ posticus major.....	28
“ “ “ minor.....	28
“ femoris.....	50
“ parvus.....	50
Retractor costæ.....	41
Rhomboides.....	26
Sartorius.....	51
Scalenus.....	25
Scapulo-humeralis posticus.....	43
Scapulo-ulnaris.....	44
Semmembranosus.....	51
Semitendinosus.....	51
Serratus anticus.....	29
“ magnus.....	38
“ posticus.....	29
Soleus.....	55
Spinalis colli.....	27
Splenius.....	27
Sterno-maxillaris.....	25
Sterno-thyro-hyoideus.....	25
Stylo-hyoideus.....	36
Stylo-maxillaris.....	35
Subscapularis.....	43
Subscapulo-hyoideus.....	25
Superficialis costarum.....	29
Temporalis.....	35
Tensor fascia latae.....	49
Teres major.....	43
“ minor.....	42
Trachelo-mastoideus.....	27
Transversalis abdominis.....	41
“ costarum.....	29
Trapezius cervicalis.....	26
“ dorsalis.....	28
Triangularis sterni.....	39
Triceps abductor femoris.....	51
“ cruralis.....	50
“ extensor brachii.....	44
Vastus externus.....	50
“ internus.....	50
Zygomatius.....	33

LIGAMENTS AND MUSCLES

OF

THE HORSE.

PART I.

LIGAMENTS.

VERTEBRAL LIGAMENTS.

A. LIGAMENTS OF THE BODIES.

1. *Superior Common*.—This ligament is riband-like, and is attached to the superior surface of the bodies of the vertebræ from the axis to the sacrum. It is widened where it passes over the intervertebral discs, to which it is attached, and narrowest over the middle of the vertebral bodies.
2. *Inferior Common*.—Is attached to the under surface of the bodies of the vertebræ, from the 6th dorsal to the sacrum. At first cord like, it gradually expands and becomes continuous with the pelvic ligaments.
3. *Intervertebral Discs*.—These are placed between the extremities of the bodies of adjacent vertebræ, and are composed of fibrous tissue and fibro-cartilage. They are thinnest in the dorsal region, and that between the last lumbar and the sacrum is the thickest.

B. LIGAMENTS OF THE OBLIQUE PROCESSES.

Capsular.—These are attached round the diarthrodial facets of adjacent processes, and are yellow-elastic in the cervical region, white-fibrous in the dorsal and lumbar regions.

C. LIGAMENTS OF THE TRANSVERSE PROCESSES.

1. *Inter-Transverse*.—Extend between the borders of the transverse processes of adjacent vertebræ.
2. *Capsular*.—These surround the joints formed by the facets on the transverse processes of the 4th and 5th, and 5th and 6th lumbar, and between the last and the base of the sacrum.

D. LIGAMENTS OF THE SPINOUS PROCESSES.

1. *Supraspinous*.—Composed of two portions :—

(a) *Ligamentum nuchæ* (yellow elastic).

Cordiform portion, attached to the first three dorsal spines and to the occipital tuberosity.

Lamellar portion, its fibres are attached above to the first three dorsal spines and to the cordiform portion, below to the spinous processes of the last six cervical vertebræ.

(b) *Dorso Lumbar*.—(White fibrous).— Extends along vertebral spines from 4th dorsal to sacrum.

2. *Interspinous*.—Extend between the borders of the spinous processes of adjacent vertebræ. (Yellow elastic in the cervical region.)

E. LIGAMENTS OF THE ARCHES.

Ligamenta subflava.—Extend between the arches of adjacent vertebræ. (Yellow elastic in the cervical region.)

SACRO-COCYGEAL AND INTER-COCYGEAL.—These are connected by

1. *Intervertebral Discs*.—Small and biconcave.
2. *Fibrous Sheaths*.—Which may be considered to represent the superior and inferior common ligaments of the back and loins.

SYNOVIAL MEMBRANES.

These are found lining the capsular ligaments of the joints formed by the oblique processes; also surrounding the joints formed by the transverse processes of the 4th and

5th, and 5th and 6th, lumbar vertebræ; and between the last and the sacrum.

In old subjects, however, these latter joints have frequently become ankylosed.

MOVEMENTS.

These are flexion, extension, lateral inclination and rotation.

They are best seen in the cervical region. Rotation is absent in the lumbar region, and very slight in the dorsal region.

OCCIPITO-ATLOID.

1. *Capsular*.—Attached around the condyles of the occiput and the anterior border of the atlas.
2. *Cruciform*.—Formed by the superior fibres of the capsular which intercross.
3. *Styloid*.—Lateral thickenings of the capsular, attached to the styloid processes of the occipital.

SYNOVIAL MEMBRANES.

There are two of these, each belonging to an occipital condyle and its corresponding cavity, on the anterior part of the atlas. Each is related on its inner side to the dura mater and odontoid ligament, and on its outer side to the capsular ligament.

MOVEMENTS.

These are flexion and extension (nodding of the head).

ATLO-AXOID.

1. *Capsular* —A membranous ligament connecting the articular surfaces, having superior, inferior, and lateral thickenings.
2. *Odontoid*.—Flat and triangular in shape, is attached behind to the depression on the upper surface of the odontoid process, in front to the floor of the atlas, and to the lateral edges of the foramen magnum.

SYNOVIAL MEMBRANE.

There is a single synovial sac for this joint.

MOVEMENTS.

Rotation, in which the axis remains fixed, and the atlas rotates around the odontoid process, carrying the head with it.

TEMPORO-MAXILLARY ARTICULATION.

LIGAMENTS.

Capsular.—This is membranous, and is attached above, around the articular surface of the temporal bone; below, around the condyle of the inferior maxilla.

Thickenings of the capsular are sometimes designated posterior and external ligaments.

Inter-articular fibro-cartilage.—A disc of fibro-cartilage interposed between the joint surfaces.

SYNOVIAL MEMBRANES.

Two in number, one above, the other below the cartilage.

MOVEMENTS.

Depression, elevation, protraction, retraction and lateral movement of the inferior maxilla.

LIGAMENTS OF THE RIBS.

A. COSTO-VERTEBRAL.

(a) COSTO-CENTRAL.

1. *Interarticular*.—Attached in the groove on the head of each rib, and to the upper border of the intervertebral disc, meeting the ligament of the opposite side at the median line.
2. *Stellate*.—Attached to the rib just below the head, to the bodies of the vertebræ in front and behind, and to the intermediate disc.

(b) COSTO-TRANSVERSE.

Anterior.

Posterior.—Bands stretching across the joint before and behind, being attached to the neck of the rib and the transverse process.

B. CHONDRO-COSTAL.—Continuity of the periosteum and perichondrium.

C. CHONDRO-STERNAL.

Capsular.

Superior and Inferior.—Merely thickenings of the capsular above and below.

Cartilage of the 9th rib.—Attached to the preceding cartilage by fibrous bands, also to the ensiform cartilage of the sternum, by the chondro-xiphoid ligament. The succeeding cartilages are attached each to the posterior edge of the cartilage in front by fibro-elastic bands.

SYNOVIAL MEMBRANES.

In the costo-central joint there are two sacs, separated by the interarticular ligament, except in the first, which has a single sac.

In the costo-transverse joint there is a single sac. But in the last two or three there is no separate sac, as the two joint cavities are continuous.

In the 8 chondro-costal joints there are synovial sacs, the first pair having a common sac.

MOVEMENT.

Rotation. In inspiration, the rib moves forwards and outwards, in expiration, it returns to its former position.

Note.—There are no movable joints in the sternum of the horse, the segments being united by persisting cartilage. There are, however, two fibrous cords (suprasternal ligaments) on the lateral borders of its upper surface.

ANTERIOR LIMB.

SHOULDER JOINT. (Scapulo-humeral.)

LIGAMENT.

Capsular.—This is the only ligament of this joint. It is attached around the glenoid cavity of the scapula above, and the head of the humerus below. It is a loose sac and comparatively thin, except in front, where it is reinforced by fibres passing from the coracoid process to the inner and outer lips of the bicipital groove.

SYNOVIAL MEMBRANE.

This is single, and lines the capsular ligament.

MOVEMENTS.

Extension, flexion, adduction, abduction, circumduction, and rotation.

Note.—The absence of binding ligaments is fully compensated for by the numerous tendons and muscles surrounding the joint. These are the antea-spinatus, postea-spinatus, flexor brachii, teres minor, caput magnum, and the subscapularis. Atmospheric pressure is of undoubted assistance also.

ELBOW JOINT.

A. HUMERO-RADIAL.

1. *Anterior.*—Membranous, being attached above to the humerus, below, to the radius.
2. *Internal lateral.*—Attached above to a small eminence on the inner side of the distal extremity of the humerus, below, to the radius just below the bicipital tuberosity.
3. *External lateral.*—Fixed above to a depression on the outer side of the lower extremity of the humerus, below, to the external tuberosity of the radius.

B. RADIO-ULNAR.

1. *Interosseus.*—Those below the radio-ulnar arch being ossified in the adult.

2. *Arciform*.—These pass from the lateral surfaces of the ulna to blend with the lateral ligaments.

SYNOVIAL MEMBRANE.

There is a single synovial membrane. It is supported in front by the anterior ligament, and laterally by the lateral ligaments, but posteriorly it is in relation to the anconeus muscle. It sends a process upwards into the olecranon fossa, and two downwards to lubricate the small facets between the radius and ulna.

MOVEMENTS.

Flexion and extension.

(Movement between the radius and ulna is inappreciable.) In flexion, the forearm deviates a little outwards. Extension is limited by the beak of the olecranon and by the tension of the lateral ligaments.

KNEE JOINT.

1. *Anterior Common*.—Membranous.—Attached above to the radius, below, to the metacarpal, blending laterally with the lateral ligaments.
 2. *Posterior Common*.—Much thicker than preceding. Attached in a similar way, its anterior surface being intimately united to the carpal bones.
 3. *Internal Lateral*.—Attached above to the internal eminence of the radius, below, to the large and small metacarpals, giving slips to the bones over which it passes
 4. *External Lateral*.—Attached above to the external eminence of the radius, below, to the external small metacarpal, giving slips to the cuneiform and unciiform.
- (*Check Ligament*.—This is a strong fibrous band, and is a continuation of the posterior common ligament of the carpus. It joins the tendon of the flexor pedis perforans near the middle of the metacarpus.)

SYNOVIAL MEMBRANES.

These are three in number :—

- (a) *Radio-carpal*.—Which lubricates the joint between the radius and the upper row of carpal bones, also descending between the latter.
- (b.) *Inter-carpal*.—Which lubricates the joint between the two rows, and has prolongations upwards and downwards between the bones. It communicates with the
- (c.) *Carpo-metacarpal*.—Which lubricates the joint between the lower row and the heads of the metacarpals, sending pouches down for the facets on the large and small metacarpals.

MOVEMENTS.

Flexion and extension. When the limb is flexed, also abduction and adduction. The movement is principally at the radio-carpal joint, least at the carpo-metacarpal.

FETLOCK JOINT.

(Metacarpophalangeal.)

A. PROPER.

1. *Anterior*—(*Membranous*.) attached above to the large metacarpal, below, to the os suffraginis, blending laterally with the lateral ligaments.
2. *External Lateral*.
3. *Internal Lateral*.—Each attached above to a depression on the large metacarpal, below, to the upper extremity of the os suffraginis and to the sesamoid.

B. ACCESSORY. (Sesamoidean ligaments.)

1. *Superior or Suspensary*.—This important ligament originates behind the carpus, from the lower row of carpal bones, and from the upper part of the large metacarpal; bifurcating above the sesamoids, each branch gives fibres to the sesamoid, and passes downwards and forwards to join the

extensor pedis tendon, forming with it the so-called broad ligament.

2. *Inferior*.—Consisting of three portions :—

- (a.) *Superficial or Y Shaped*—Attached above to the base of the sesamoids and inter-sesamoidean ligament, below, to the glenoidal fibro-cartilage behind the upper end of the os coronæ.
 - (b.) *Middle or V Shaped*.—Attached above to the base of the sesamoids, below, to ridges on the posterior surface of the os suffraginis.
 - (c.) *Deep or X Shaped*.—Fixed to the base of the sesamoids and the supero-posterior surface of the os suffraginis.
3. *Lateral* (2).—Each passes from the external surface of the sesamoid to the upper extremity of the os suffraginis.
4. *Intersesamoidean*.—A pad of fibro-cartilage which unites the sesamoids, and with them forms a pulley for the passage of the flexor tendon.

SYNOVIAL MEMBRANE.

This is supported in front by the anterior ligament, and laterally by the lateral ligaments. Posteriorly, it is supported in its lower part by the deep inferior sesamoidean ligament, but in its upper part it is unsupported, and consequently may bulge upwards between the branches of the suspensory ligament.

MOVEMENTS.

Flexion and extension are the only natural movements. But if the joint is flexed, slight lateral movement may be produced.

PASTERN JOINT.

(Proximal interphalangeal.)

1. *Lateral*.—Each of these stretches from the side of the distal extremity of the os suffraginis to the side of the proximal extremity of the os coronæ.

(Anteriorly the tendon of the extensor pedis acts as a ligament, and posteriorly the glenoidal fibro-cartilage is attached by three fibrous bands passing on each side to the os suffraginis.)

SYNOVIAL MEMBRANE.

This is supported in front by the extensor tendon, laterally by lateral ligaments, and posteriorly by the glenoid fibro-cartilage, above which it forms a pouch behind the lower end of the os suffraginis.

MOVEMENTS.

Similar to the fetlock.

COFFIN JOINT.

(distal interphalangeal.)

1. *Antero-lateral*.—These pass from the sides of the distal extremity of the os corona to depressions on each side of the pyramidal process of the os pedis.
2. *Postero-lateral*.—These are the downward continuation of the lateral ligaments of the pastern. Each is attached to the upper border of the navicular bone, and sends slips to the wing of the os pedis and the lateral cartilage.
3. *Interosseous*.—Composed of short fibres passing from the inferior border of the navicular bone to the tendinous surface of the os pedis behind the semilunar crest.

SYNOVIAL MEMBRANE.

Related in front to the extensor pedis tendon (broad ligament), and laterally to the lateral ligaments, between which it protrudes, reaching the inner surface of the lateral cartilage. Another pouch passes upwards between the navicular bone and the os coronæ.

MOVEMENTS.

Flexion and extension.

Note.—As described above, the postero-lateral includes the broad ligament and lateral navicular ligaments of Strange-

ways ; and the interosseous is the inferior navicular ligament of that anatomist.

POSTERIOR EXTREMITY.

SACRO-ILIAC ARTICULATION.

1. *Sacro-iliac (or Capsular.)*—Composed of strong fibres, passing between the sacrum and ilium, surrounding the joint.
2. *Superior Sacro-iliac.*—Is a band attached to the internal angle of the ilium and the summits of the sacral spines.
3. *Inferior Sacro-iliac.*—Is a triangular expansion, fixed anteriorly to the internal border of the ilium, inferiorly to the border of the sacrum, and posteriorly continuous with the coccygeal fascia.
4. *Sacro-sciatic.*—Quadrilateral in shape. Upper border attached to the border of the sacrum and 1st coccygeal bone ; lower border, to the superior ischiatic spine and tuberischii ; anterior border short, and helps to form the greater sacro-sciatic foramen ; posterior border is thin, and united to the adductor magnus muscle.

FORAMINA.

1. *Great Sacro-sciatic.*—Is formed by the internal border of the ilium and anterior border of the sacro-sciatic ligament. It transmits the great sciatic nerve, and gluteal vessels and nerves.
2. *Lesser Sacro-sciatic.*—Is formed by the lower border of the sacro-sciatic ligament, and the external border of the ischium ; transmits the common tendon of the obturator internus and piriformis muscles.

SYNOVIAL MEMBRANE.

This is rudimentary.

MOVEMENT.

Scarcely appreciable.

HIP-JOINT.

1. *Capsular*.—Attached above to the rim of the cotyloid cavity, and to the cotyloid ligament; below, around the head of the femur.
2. *Cotyloid*.—Consists of a ring of fibro-cartilage attached around the rim of the cotyloid cavity, which it deepens.
3. *Transverse*.—Is that part of the preceding which bridges over the cotyloid notch.
4. *Pubio-femoral*.—Attached in the sulcus on the head of the femur; it passes inwards in the sub-pubic groove, blending with the prepubic tendon and its fellow of the opposite side (the fibres intercrossing).
5. *Round (ligamentum teres)*.—Attached below to the sulcus on the head of the femur, above, to the rough depression of the cotyloid cavity (non-articular portion).

SYNOVIAL MEMBRANE.

This completely lines the capsular ligament, and is also reflected on the pubio-femoral and round ligaments.

MOVEMENTS.

This joint admits of more extensive movements than any other in the limbs. These are flexion, extension, abduction, adduction, circumduction, and rotation. Abduction is restricted by the pubio-femoral ligament, which is absent in the other domesticated animals.

STIFLE-JOINT.

A. FEMORO-TIBIAL LIGAMENTS.

1. *Lateral*.—

(a) *Internal*.—Attached above to a tubercle on the internal condyle of the femur, below, to the internal tuberosity of the tibia.

(b) *External*.—Attached above to a depression on the external condyle of the femur, below, to the head of the fibula.

2. *Posterior*.—Membranous. Attached above to the posterior surface of the femur above the condyles, below, to the tibia just below its articular surface, blending laterally with the lateral ligaments.
3. *Crucial*.—These are two fibrous cords crossing each other, named anterior and posterior. The anterior is attached above in the intercondyloid groove, below, to the tibial spine; the posterior, also attached above in the groove, passes downwards and backwards, to be inserted to a tubercle on the posterior border of the tibial articular surface.

(*Semilunar Cartilages*.—These are crescent-shaped, each having a flat, inferior surface, resting on the tibial facet, a concave upper surface, related to the condyle of the femur, a convex, thick, outer border, and a concave, thin, inner border, embracing the tibial spine. The inner one is held in position by two bands, the outer by three, constituting the so-called coronary ligaments.)

B. FEMORO-PATELLAR.

1. *Capsular*.—Attached around the articular surface of the patella and the trochlea of the femur.
2. *Lateral*.—Thickenings of the capsular ligament on each side.

C. PATELLAR.

1. *Internal Straight*.—Attached to the internal border of the patella and inner side of anterior tuberosity of the tibia. This ligament has a fibro-cartilaginous thickening which enlarges the articular surface of the patella.
2. *Middle Straight*.—Attached to apex of patella and a groove on the anterior tuberosity of the tibia.
3. *External Straight*.—Attached to external border of patella and outer side of anterior tuberosity of the tibia.

Note.—These may properly be considered continuations of the triceps cruralis.

TIBIO-FIBULAR JOINT.—United by

1. *Peripheral Fibres*.—Surrounding the joint.
2. *Interosseous Fibres*.—Extending across the tibio-fibular arch.

SYNOVIAL MEMBRANES.

These are three in number. The first lubricates the joint between the femoral trochlea and the patella. It lines the capsular ligament and protrudes upwards under the triceps. Below it touches and sometimes communicates with the synovial membranes of the femoro-tibial joint. The other two membranes lubricate the femoro-tibial joint. They are separated by the crucial ligament, and a quantity of fat separates them from the straight patellar ligaments. The external sac also pouches downwards, investing the tendon of origin of the popliteus, and the common tendon of the flexor metatarsi and extensor pedis muscles.

MOVEMENTS (of the joint as a whole.)

These are flexion and extension, with slight lateral movement and rotation when the joint is flexed

HOCK-JOINT.

1. *Anterior (membranous)*.—Attached above to the tibia, below, to the astragalus, cuneiform magnum and medium, and the astragalo-metatarsal ligament, blending laterally with the lateral ligaments.
2. *Posterior (membranous)*.—Attached above to the tibia, below, to the astragalus and os calcis, blending laterally with the lateral ligaments.
3. *Internal lateral*.—Attached above to the internal malleolus of the tibia, below, to the large and inner small metatarsals, and to the bones it passes over.
4. *External lateral*.—Attached above to the external malleolus of the tibia, below, to the large and outer small metatarsals, and the bones over which it passes.

4. *Astragalo-metatarsal*. - Attached above to a tubercle on the inner side of the astragalus, and, widening below, is attached to the cuneiform magnum and medium, and large metatarsal bones.
5. *Tarso-metatarsal*. - Is a thick mass of fibrous tissue covering the posterior surface of the hock, blending inwardly with the lateral ligament, outwardly with the calcaneo-cuboid ligament.
Below, it is continued to form the check-ligament.
6. *Calcaneo-cuboid (or Calcaneo-metatarsal)*.—Attached to the posterior border of the os calcis, the cuboid, and the outer small metatarsal.

Note. This ligament is affected in curb.

SYNOVIAL MEMBRANES.

These are three in number. The first (and most important) lubricates the joint between the tibia and astragalus. It is supported by the anterior, posterior, and lateral ligaments. When distended (as in bog-spavin), it causes the anterior ligament to bulge out at the antero-internal part of the joint.

The second lubricates the joint between the astragalus and os calcis above, and the cuneiform magnum and cuboid below. It has prolongations above, in front, and below.

The third supplies the joint formed between the cuboid, cuneiform medium and parvum above, and the three metatarsals below. It descends to supply the facets of the large and small metatarsals.

MOVEMENTS.

Flexion and extension.

Note.—For a detailed description of the synovial apparatus, the student is referred to Chauveau.

PART II.

MYOLOGY.

SUBCUTANEOUS REGION.

PANNICULUS CARNOSUS.

The facial portion consists of scattered bundles of fibres, best developed over the masseter muscles, being continued into the submaxillary space and over the parotid gland. Other fibres reach the angle of the mouth, which they retract.

The cervical portion is attached below, to the cariniform cartilage of the sternum. Here it is a thick band, but becomes thin anteriorly and superiorly.

The thoracic portion consists of fibres running in a vertical direction, covering the scapular region.

The abdominal portion reaches from the groin to the elbow muscles, where it sends a tendon to be attached to the inner tuberosity of the humerus.

The action of this muscle is to shake the skin, thus removing offending insects.

INFERIOR CERVICAL REGION.

- | | |
|---|---|
| 1. <i>Levator Humeri.</i> | 6. <i>Rectus capitis anticus minor.</i> |
| 2. <i>Sterno maxillaris.</i> | 7. <i>Rectus capitis lateralis.</i> |
| 3. <i>Sterno-thyro-hyoideus.</i> | 8. <i>Scalenus.</i> |
| 4. <i>Subscapulo hyoideus.</i> | 9. <i>Longus colli.</i> |
| 5. <i>Rectus capitis anticus major.</i> | 10. <i>Intertransversales colli.</i> |

1. LEVATOR HUMERI.

Origin.—From the mastoid process, occipital crest, wing of the atlas and transverse processes of 2nd, 3rd, and 4th cervical vertebræ.

Insertion.—To the deltoid ridge.

Action.—Extension and inward rotation of shoulder joint; if the limb is fixed, it bends the neck laterally.

2. STERNO-MAXILLARIS.

Origin.—From the cariniform cartilage of the sternum.

Insertion.—To the angle of inferior maxilla.

Action.—Together they depress the head, singly, flex it laterally.

3. STERNO-THYRO-HYOIDEUS.

Origin.—From the cariniform cartilage of sternum.

Insertion.—To the thyroid cartilage of the larynx, and the body of hyoid bone.

Action.—To depress the hyoid bone and larynx.

4. SUBSCAPULO-HYOIDEUS.

Origin.—From the fascia of the subscapularis muscle.

Insertion.—To the body of the hyoid bone.

Action.—To depress the hyoid bone.

5. RECTUS CAPITIS ANTICUS MAJOR.

Origin.—From the transverse processes of the 3rd, 4th and 5th cervical vertebræ.

Insertion.—To the tubercles at the junction of basilar process of occipital, and body of sphenoid.

Action.—Together they depress the head, singly, flex it laterally.

6. RECTUS CAPITIS ANTICUS MINOR.

Origin.—From the lower part of the anterior border of atlas.

Insertion.—with preceding muscle.

Action.—Same as preceding muscle.

7. RECTUS CAPITIS LATERALIS.

Origin.—From the atlas external to preceding.

Insertion.—To the styloid process of the occipital.

Action.—Same as preceding muscle.

8. SCALENUS.

Origin.—From the transverse processes of the last 4 cervical vertebræ.

Insertion.—To the external surface and anterior border of 1st rib, by two slips.

Action.—To draw forward or fix the first rib, thus aiding in inspiration; or, if the rib is fixed, to flex the neck or incline it to one side, according as the muscles act together or singly.

9. LONGUS COLLI

Origin.—From the bodies of the first 6 dorsal vertebræ, and from the bodies and transverse processes of the last 6 cervical vertebræ.

Insertion.—To the tubercle of the atlas.

Action.—To bend the neck downwards.

10. INTERTRANSVERSALES COLLI.

Consists of six bundles, each having

Origin.—From the oblique process of one vertebra.

Insertion.—To the transverse process of preceding vertebra.

Action.—Lateral bending of the neck.

SUPERIOR CERVICAL REGION.

- | | |
|---------------------------------|---|
| 1. <i>Trapezius cervicalis.</i> | 6. <i>Spinalis colli.</i> |
| 2. <i>Rhomboideus Longus.</i> | 7. <i>Obliquus capitis anticus.</i> |
| 3. <i>Splenius.</i> | 8. <i>Obliquus capitis posticus.</i> |
| 4. <i>Complexus (major).</i> | 9. <i>Rectus capitis posticus major.</i> |
| 5. <i>Trachelo-mastoideus.</i> | 10. <i>Rectus capitis posticus minor.</i> |

1. TRAPEZIUS CERVICALIS.

Origin.—From the funicular portion of the ligamentum nuchæ, as far forward as the 3rd cervical vertebra.

Insertion.—To the tubercle on the spine of the scapula.

Action.—It draws the scapula forwards and upwards.

2. RHOMBOIDEUS LONGUS.

Origin.—From the funicular portion of the ligamentum nuchæ, as far forward as the axis.

Insertion—To the antero-internal surface of the cartilage of prolongation.

Action.—Draws scapula upwards and forwards.

3. SPLENIUS.

Origin.—From the funicular portion of the ligamentum nuchae and from the 2nd, 3rd, and 4th dorsal spines.

Insertion.—To the mastoid crest, wing of the atlas and transverse processes of 2nd, 3rd, 4th and 5th cervical vertebrae.

Action.—Acting together they elevate head and neck, singly, they incline these to one side.

4. COMPLEXUS.

Origin.—From the spines of the 2nd, 3rd and 4th dorsal vertebrae, transverse processes of 1st six dorsal vertebrae, and oblique processes of last six cervical vertebrae.

Insertion.—To the occipital bone on each side of the tuberosity.

Action.—Together, they extend the head; singly, also turn it slightly to one side.

5. TRACHELO-MASTOIDEUS.

Origin.—From the transverse processes of the first two dorsal vertebrae, and oblique processes of last six cervical vertebrae.

Insertion.—To the mastoid crest and to the wing of the atlas.

Action.—Together, they extend the head; singly, bend the neck laterally.

6. SPINALIS COLLI.

Consists of five bundles.

Origin.—From the oblique processes of the last five cervical vertebrae.

Insertion.—To the spines of all the cervical except the first and last.

Action.—Together, they extend the neck; acting singly, they incline the neck to the opposite side.

7. OBLIQUUS CAPITIS ANTICUS.

Origin.—From the edge of the wing of the atlas.

Insertion.—To the mastoid crest, and styloid process of the occipital.

Action.—To extend the head on the atlas.

8. OBLIQUUS CAPITIS POSTICUS.

Origin.—From the side of the spine of the dentata.

Insertion.—To the superior surface of wing of atlas.

Action.—To rotate the head around the odontoid process.

9. RECTUS CAPITIS POSTICUS MAJOR.

Origin.—From the spine of the dentata.

Insertion.—To the occipital bone beneath the complexus.

Action.—To extend the head.

10. RECTUS CAPITIS POSTICUS MINOR.

Origin.—Upper surface of the ring of the atlas.

Insertion.—To the occipital bone beneath the preceding.

Action.—Same as the preceding muscle.

DORSO-LUMBAR REGION.

1. *Trapezius dorsalis.*

2. *Latissimus dorsi.*

3. *Serratus anticus.* } *Superficialis costarum.*

4. *Serratus posticus.* }

5. *Longissimus dorsi.*

6. *Transversalis costarum.*

1. TRAPEZIUS DORSALIS.

Origin.—From the summits of the 3rd to the 10th dorsal spines.

Insertion.—To the tubercle on the spine of the scapula.

Action.—It pulls the scapula upwards and backwards.

2. LATISSIMUS DORSI.

Origin.—From the supraspinous ligament, from the 4th dorsal to the last lumbar vertebra.

Insertion.—To the internal tubercle of the humerus.

Action.—Flexion and inward rotation of the shoulder joint.

3. SERRATUS ANTICUS.

Origin.—From the dorsal spines, 2nd to 13th inclusive.

Insertion.—To the anterior border and external surface of the nine ribs posterior to the 4th.

Action.—It assists in inspiration, by drawing the ribs forwards.

4. SERRATUS POSTICUS.

Origin.—From the last seven dorsal spines, and first two lumbar.

Insertion.—To the posterior border and external surface of last nine ribs.

Action.—It assists in expiration.

Note.—The two preceding muscles constitute the superficialis costarum of Strangeways.

5. LONGISSIMUS DORSI.

Origin.—From the inferior surface of the ilium anterior to the sacro-iliac articulation, first two bones of sacrum, dorsal and lumbar spines and supraspinous ligament.

Insertion.—To the transverse and oblique processes of the lumbar, transverse processes of the dorsal, transverse and spinous processes of last four cervical, and external surface of last sixteen ribs.

Action.—Acting together, they are the great extensors of the vertebral column; acting singly, it inclines the spine to the side of the acting muscle.

It may also assist in expiration.

6. TRANSVERSALIS COSTARUM.

Origin.—From the transverse processes of the first two lumbar vertebræ, and from the anterior border of the ribs, near their angles.

Insertion.—To the posterior border of the ribs, anterior to the 14th, and to the last cervical transverse process.

Action.—It draws the ribs backwards, thus assisting in expiration.

SUBLUMBAR REGION.

- | | |
|-------------------------|--|
| 1. <i>Psoas magnus.</i> | 4. <i>Quadratus lumborum.</i> |
| 2. <i>Psoas parvus.</i> | 5. <i>Intertransversales lumborum.</i> |
| 3. <i>Iliacus.</i> | |

1. PSOAS MAGNUS.

Origin.—From the inferior surface of the bodies of the last two dorsal vertebrae, last two ribs and transverse processes of lumbar, except the last.

Insertion.—To the internal trochanter of the femur.

Action.—Flexion, and outward rotation of hip joint. If hind limb is fixed, both muscles will arch the loins; or singly, incline the trunk to one side.

2. PSOAS PARVUS.

Origin.—From the bodies of last four dorsal and all the lumbar vertebrae.

Insertion.—To the ilio-pectineal line.

Action.—Both muscles flex the pelvis on the loins; singly, cause lateral motion.

3. ILIACUS.

Origin.—From the venter surface and external angle of the ilium and sacro-iliac ligament.

Insertion.—To the internal trochanter of femur.

Action.—Similar to Psoas Magnus.

4. QUADRATUS LUMBORUM.

Attachments.—To the tips of the transverse processes of the lumbar vertebrae, last three ribs, and sacro-iliac ligament.

Action.—Both muscles fix the last ribs and thus assist the diaphragm. Singly, lateral bending of the loins is produced.

5. INTERTRANSVERSALES LUMBORUM.

These connect adjacent transverse processes, and assist preceding muscle.

THE DIAPHRAGM

Consists of

- (a.) A tendinous centre.
- (b.) A fleshy rim.
- (c.) Two crura or pillars.

The rim is attached to the ensiform cartilage of the sternum, and the cartilages of the false ribs (anteriorly), or to the rib above the chondro costal joint (posteriorly).

The right crus (much the largest), is attached to the lumbar vertebræ, (blending with the inferior common ligament), and joins the tendinous centre.

The left crus is smaller, and is attached to the first two lumbar vertebræ in a similar manner.

The tendinous centre is composed of white glistening fibres which interlace.

FORAMINA OF DIAPHRAGM.

- (a.) *Hiatus Aorticus*.—A notch between the two pillars, giving passage to the posterior aorta, vena azygos, and thoracic duct.
- (b.) *Foramen Dextrum*.—Situatd slightly to the right of the median plane, about the middle of the tendinous centre. It gives passage to the posterior vena cava, which is adherent to its margin.

- (c.) *Foramen Sinistrum*.—This is a slit in the fibres of the right crus, a little to the left of the median plane. Through it pass the oesophagus, oesophageal branches of the pneumogastric nerve, and the pleural artery.

The sympathetic and splanchnic nerves pass to the abdomen above the crura, and underneath the psoas parvus muscles.

Action of Diaphragm.—It is the principal muscle of inspiration, increasing the antero-posterior diameter of the Thorax.

COCCYGEAL REGION.

- | | |
|--------------------------------|---------------------------------|
| 1. <i>Erector coccygis</i> . | 3. <i>Curvator coccygis</i> . |
| 2. <i>Depressor coccygis</i> . | 4. <i>Compressor coccygis</i> . |

1. ERECTOR COCCYGIS.

Origin.—From the sides and summits of the sacral spines.

Insertion.—To the upper surface of the coccygeal vertebræ.

Action.—Both elevate the tail; acting separately, incline it to one side, and also elevate it.

2. DEPRESSOR COCCYGIS.

Origin.—From the inferior surface of the sacrum as far forward as the 3rd foramen.

Insertion.—To the inferior surface of the coccygeal vertebræ.

Action.—Depression or lateral movement of tail.

3. CURVATOR COCCYGIS.

Origin.—From the last two lumbar spines and sacral spines.

Insertion.—To the sides of the coccygeal bones.

Action.—Lateral inclination of the tail.

4. COMPRESSOR COCCYGIS.

Origin.—From the sacro-sciatic ligament and ischiatic ridge.

Insertion.—To the last sacral and first two coccygeal bones.

Action.—It depresses the tail.

FACIAL REGION.

1. *Orbicularis oris.*7. *Levator labii superioris alaeque nasi.*2. *Zygomaticus.*3. *Levator labii superioris propius (nasalis longus.)*8. *Dilatator naris lateralis.*4. *Depressor labii inferioris.*9. " " *superior.*5. *Levator menti.*10. " " *transversalis.*6. *Buccinator.*11. " " *inferior.*12. *Depressor labii superioris.*

1. ORBICULARIS ORIS.

This muscle is arranged in the form of a sphincter; its fibres circumscribing the opening of the mouth in an elliptical manner.

Action—To close the lips.

2. ZYGOMATICUS.

Origin.—From the surface of the masseter muscle.

Insertion.—To the buccinator muscle just above the angle of the mouth.

Action.—To raise the angle of the mouth.

3. LEVATOR LABII SUPERIORIS PROPRIUS (nasalis longus.)

Origin.—From the malar and superior maxillary bones below the orbit.

Insertion.—To the upper lip.

Action.—Together, they elevate the lip ; separately, raise and draw it to the side of the muscle acting.

4. DEPRESSOR LABII INFERIORIS.

Origin.—From the edge of ramus of inferior maxilla behind last molar tooth.

Insertion.—To the lower lip.

Action.—To retract lower lip.

5. LEVATOR MENTI (Levator labii inferioris.)

Origin.—From the inferior maxilla below the intermediate and corner incisors, and as far back as the canine.

Insertion.—It mixes with orbicularis oris, and forms the prominence of the chin.

Action.—To raise the lower lip.

6. BUCCINATOR.

Attachments.—To the superior maxilla from the alveolus of the canine tooth, back to the alveolar tuberosity ; in a similar manner to the inferior maxilla ; anteriorly blending its fibres with those of the orbicularis oris.

Action.—Principally to press the food between the teeth : but it may also retract the angle of the mouth.

7. LEVATOR LABII SUPERIORIS ALEQUE NASI.

Origin.—From the frontal and nasal bones.

Insertion.—To the nostril and upper lip.

Action.—To dilate the nostril and raise the upper lip.

8. DILATATOR NARIS LATERALIS.

Origin.—From the superior maxilla.

Insertion.—To the nostril (broad part of alar cartilage)

Action.—To dilate the nostril.

9. DILATOR NARIS SUPERIOR.

This muscle is composed of a few fibres arising from the extremity of the septum nasi, and terminating on the wall of the false nostril, and on the extremity of the superior turbinated bone.

Action.—To dilate the false nostril.

10. DILATATOR NARIS TRANSVERSALIS.

Composed of fibres passing across transversely, to be attached on each side on the wide part of the alar cartilages. It dilates the nostrils.

11. DILATATOR NARIS INFERIOR.

Origin.—From the nasal process of premaxilla, and edge of superior maxilla adjacent.

Insertion.—To the wall of the false nostril and the cartilaginous prolongation of the inferior turbinated bone.

Action.—To dilate the false nostril.

12. DEPRESSOR LABII SUPERIORIS.

Origin.—From the premaxilla above the interdental space.

Insertion.—To the upper lip.

Action.—To depress the upper lip.

TEMPORO-MAXILLARY REGION.

1. *Masseter.*

4. *Pterygoidens externus.*

2. *Temporalis.*

5. *Digastricus.*

3. *Pterygoidens internus.*

6. *Stylo-maxillaris.*

1. MASSETER.

Origin.—From the zygomatic ridge of the superior maxilla and malar.

Insertion.—To the external surface of the ramus of the inferior maxilla.

Action.—To raise the lower jaw, thus bringing the teeth strongly together.

2. TEMPORALIS.

Origin.—From the temporal fossa.

Insertion.—To the coronoid process of the inferior maxilla.

Action.—Chiefly to elevate the lower jaw ; or to oppose protrusion action of the external pterygoid. Also to cause lateral motion.

3. PTERYGOIDEUS INTERNUS.

Origin.—From a rough crest formed by the palatine bone and the pterygoid process of the sphenoid.

Insertion.—To the excavated internal surface of the ramus of the inferior maxilla.

Action.—Together, they elevate the lower jaw ; singly, produce lateral movement.

4. PTERYGOIDEUS EXTERNUS.

Origin.—From the wing and pterygoid process of the sphenoid.

Insertion.—To the neck below the condyle of the inferior maxilla.

Action.—Acting together, they protrude the lower jaw ; acting singly, the lower jaw is carried to the side opposite to the muscle acting.

5. DIGASTRICUS.

Origin.—From the styloid process of the occipital, in common with the stylo-maxillaris.

Insertion.—To the ramus of the inferior maxilla, near the symphysis.

Action.—To depress the lower jaw, and open the mouth.

6. STYLO-MAXILLARIS.

Origin.—From the styloid process of the occipital bone.

Insertion.—To the angle of the inferior maxilla.

Action.—To depress the lower jaw and open the mouth.

HYOIDEAL REGION.

1. *Mylo-hyoideus*.
2. *Genio-hyoideus*.
3. *Stylo-hyoideus* (hyoideus magnus).
4. *Kerato-hyoideus* (hyoideus parvus).
5. *Occipito-styloideus* (stylo-hyoideus).
6. *Hyoideus transversus*.

1. MYLO-HYOIDEUS.

Origin.—From a line on the inner surface of the inferior maxilla near the alveoli.

Insertion.—To the body and spur process of the hyoid bone, and to a median fibrous raphe.

Action.—The two muscles form a sling for the tongue, which they raise in contracting.

2. GENIO-HYOIDEUS.

Origin.—From the inner surface of the inferior maxilla, near the symphysis.

Insertion.—To the spur process of the hyoid bone.

Action.—To draw the hyoid bone forward.

3. STYLO-HYOIDEUS.

Origin.—From the posterior part of the great cornu of the hyoid bone.

Insertion.—To the heel process of the hyoid bone.

Action.—To elevate the base of the tongue and the larynx.

4. KERATO-HYOIDEUS (or hyoideus parvus).

Origin.—From the posterior edge of the small cornu, and the adjacent part of the great cornu of the hyoid bone.

Insertion.—To the upper edge of the heel process.

Action.—To elevate the larynx.

5. OCCIPITO-STYLOIDEUS.

Origin.—From the styloid process of the occipital bone.

Insertion.—To the posterior extremity of the great cornu of hyoid bone.

Action.—To retract the hyoid bone and attached structures.

(*Note.*—This muscle covers the guttural pouch, and is performed in opening the pouch).

6. HYOIDEUS TRANSVERSUS.

An unpaired muscle stretching across the median line between the small cornua of the hyoid bone, to which it is attached.

Action.—To raise the root of the tongue.

PECTORAL REGION.

1. *Anterior superficial pectoral.* 3. *Anterior deep pectoral.*

2. *Posterior superficial pectoral.* 4. *Posterior deep pectoral.*

1. ANTERIOR SUPERFICIAL PECTORAL (pectoralis anticus).

Origin.—From the cariniform cartilage, and first two or three inches of inferior border of the sternum.

Insertion.—To the deltoid ridge of the humerus.

Action.—Adduction.

2. POSTERIOR SUPERFICIAL PECTORAL (pectoralis transversus).

Origin.—From the inferior border of the sternum, from within an inch of its anterior extremity back to the sixth costal cartilage.

Insertion.—(Principally) to the fascia on the inner surface of the fore-arm, and by a small band to the deltoid ridge of the humerus.

Action.—It adducts the fore-limb, and also tenses the fascia of the fore-arm.

3. ANTERIOR DEEP PECTORAL (pectoralis parvus).

Origin.—From the cartilages of the first four ribs, and the adjacent lateral surface of the sternum.

Insertion.—To the fascia of the antea-spinatus muscle.

Action.—To draw the scapula backwards and downwards.

4. POSTERIOR DEEP PECTORAL (pectoralis magnus).

Origin.—From the cartilages of 5th to 8th ribs (inclusive), and from the adjacent lateral surface of the sternum ; also from the abdominal tunic.

Insertion.—To the inner trochanter of the humerus.

Action.—To draw the shoulder joint and fore-limb backwards.

COSTAL REGION.

1. *Serratus Magnus.*4. *Levatores Costarum* (17).2. *External Intercostals* (17).5. *Triangularis Sterni.*3. *Internal Intercostals* (17).6. *Lateralis Sterni.*

1. SERRATUS MAGNUS.

Origin — From the outer surface of the eight true ribs, and from the transverse processes of the last five cervical vertebrae.

Insertion.—To two rough triangular surfaces on the upper part of the internal surface of the scapula.

Action.—The two muscles form a sling to support the trunk. In contracting, it draws the upper extremity of the scapula downwards and backwards ; or, if the limb is fixed, it may act as a muscle of inspiration.

2. EXTERNAL INTERCOSTALS.

Each of these occupies an intercostal space, the fibres arising from the anterior rib, and passing downwards and backwards to be attached to the posterior rib.

Action.—To draw the ribs forwards and upwards, assisting in inspiration.

3. INTERNAL INTERCOSTALS.

The fibres of these arise from the posterior rib, and pass downwards and forwards to be attached to the anterior rib.

Action.—Opposed to the preceding, and thus muscles of expiration.

Note.—The internal intercostal muscles differ from the external set in being continued down to occupy the spaces between the costal cartilages, while in the extreme upper part of the intercostal spaces, they are either absent or thin and aponeurotic. This inter-cartilaginous portion is inspiratory.

4. LEVATORES COSTARUM.

Origin.—From the transverse processes of the dorsal vertebrae.

Insertion.—To the outer surfaces of the ribs, posterior to origin.

Action.—To draw the ribs forward and assist in inspiration.

5. TRIANGULARIS STERNI.

Origin.—From the borders of the upper surface of the sternum, extending from opposite to the 2nd costal cartilage, to the ensiform cartilage.

Insertion.—To the costal cartilages, 2nd to 8th inclusive.

Action.—To assist in expiration.

6. LATERALIS STERNI.

Origin.—Outer surface of 1st rib above its cartilage.

Insertion.—To the side of the sternum, some of its fibres also sometimes to the 3rd and 4th costal cartilages.

Action.—It has a feeble inspiratory action, with the 1st rib as the fixed point.

ABDOMINAL REGION.

1. *External Oblique* (obliquus abdominis externus).

2. *Internal Oblique* (obliquus abdominis internus).

3. *Great Straight* (rectus abdominis).

4. *Transverse* (transversalis abdominis).

5. *Retractor Costae.*

ABDOMINAL TUNIC.

This is an expansion of yellow elastic tissue spread over the external oblique muscles of the abdomen.

It is thickest at the prepubian tendon and along the median line, and gradually thins out towards its circumference. Anteriorly it extends a little underneath the posterior deep pectoral muscle.

Posteriorly in the male, it furnishes the suspensory ligaments of the sheath, and in the female, analogous slips to the mammary gland.

It forms an elastic abdominal bandage, assisting the muscles, and adapting the abdominal wall to the volume of its contents.

LINEA ALBA.

This is a fibrous band extending from the ensiform cartilage to the pubes, and is formed by the union of the aponeuroses of the right and left muscles.

1. EXTERNAL OBLIQUE.

Origin.—Outer surface of last fourteen ribs.

Insertion.—To the linea alba, prepubian tendon, and the external angle of the ilium.

Action.—Together they arch the back. If the spine is fixed, they draw the ribs back and assist in expiration. If both spine and ribs are fixed, they assist in defaecation, urination, and parturition. Acting singly, the trunk is drawn to the side of the muscle acting.

2. INTERNAL OBLIQUE.

Origin.—From the external angle of the ilium, and from the adjacent part of Poupart's ligament.

Insertion.—To the linea alba, prepubian tendon, and the last four (or five) costal cartilages.

Action.—Similar to the external oblique.

3. RECTUS ABDOMINIS.

Origin.—From the lower surface of the sternum, and from the 5th to the 9th costal cartilages, inclusive.

Insertion.—To the prepubian tendon.

Action.—It compresses the abdominal viscera and flexes the spine. It also draws the pelvis forward as in copulation.

4. TRANSVERSALIS ABDOMINIS.

Origin.—From the lower extremities or cartilages of the last ten ribs, and from the lumbar transverse processes.

Insertion.—To the linea alba and ensiform cartilage of the sternum.

Action.—Similar to the oblique muscles.

5. RETRACTOR COSTAE.

Origin.—From the first two or three lumbar transverse processes.

Insertion.—To the posterior border of the last rib.

Action.—To assist in expiration.

Note.—This small muscle is usually described as a part of the internal oblique muscle.

POUPART'S LIGAMENT.

This is formed by the reflection of the aponeurosis of the external oblique.

It may be described as having two surfaces two borders, and two extremities.

The anterior surface is concave, forming inwardly the posterior boundary of the inguinal canal, and outwardly giving attachment to the internal oblique muscle.

The posterior surface is convex and covers the sartorius, iliacus, and psoas magnus muscles; also the femoral artery and crural nerve.

The lower border is the line of continuity with the external que.

The upper border is thin, and fuses with the sublumbar fascia.

The inner extremity is attached to the pubes, and the outer to the external angle of the ilium.

EXTERNAL SCAPULAR REGION.

- | | |
|----------------------------|---|
| 1. <i>Antea-spinatus.</i> | 3. <i>Deltoid.</i> |
| 2. <i>Postea-spinatus.</i> | 4. <i>Teres minor (or Postea-spinatus minor).</i> |

1. ANTEA SPINATUS.

Origin—From the antea-spinatus fossa and cartilage of prolongation.

Insertion—By two tendons, the outer one being attached to the anterior part (summit) of the external trochanter of the humerus, and the inner one to the corresponding part of the internal trochanter.

Action.—It extends the shoulder-joint.

2. POSTEA-SPINATUS.

Origin.—From the fossa of the same name, and from the cartilage of prolongation.

Insertion.—By two tendons, the deep (or short) one being attached just inside of the convexity of the external trochanter of the humerus, the long (or superficial) one passing over the convexity, to be inserted into a ridge just below.

Action.—It abducts the humerus and rotates it outwards.

3. DELTOID.

Origin.—From the tubercle on the spine of the scapula, and from the dorsal angle of the same.

Insertion.—To the deltoid ridge of the humerus.

Action.—To abduct the humerus and rotate it outwards. Acting with the teres internus, it also flexes the shoulder.

4. TERES MINOR.

Origin.—From the lower part of the posterior border of the scapula, from the rough lines at the lower part of the postea spinous fossa, and from a small tubercle on the outer edge of the glenoid cavity.

Insertion.—To the deltoid ridge.

Action.—Like the preceding muscle.

INTERNAL SCAPULAR REGION.

1. *Subscapularis*.

3. *Coraco-humeralis*.

2. *Teres internus (or major)*.

4. *Scapulo-humeralis posticus*.

1. SUBSCAPULARIS.

Origin.—From the fossa of the same name.

Insertion.—To the internal trochanter of the humerus.

Action.—To adduct the shoulder.

2. TERES INTERNUS.

Origin.—From the dorsal angle of the scapula.

Insertion.—To the internal tubercle of the humerus.

Action.—It flexes the shoulder and rotates it inwards.

3. CORACO-HUMERALIS.

Origin.—From a small tubercle on the inner side of the coracoid process of the scapula.

Insertion.—To the inner surface of the humerus above the internal tubercle, and to a line a little lower down and more anterior.

Action.—To adduct and flex the shoulder.

4. SCAPULO-HUMERALIS POSTICUS.

Origin.—Just above the rim of the glenoid cavity.

Insertion.—To the posterior surface of the humerus just below the head.

Action.—To tense the capsular ligament and prevent its injury during flexion of the joint.

ANTERIOR BRACHIAL REGION.

1. *Flexor brachii (or Coraco-radialis).*

2. *Humeralis obliquus (or externus).*

1. FLEXOR BRACHII.

Origin.—From the coracoid process of the scapula. It emerges between the two tendons of the antea-spinatus, and passes over the bicipital groove to its

Insertion.—To the bicipital tuberosity of the radius.

Action.—To flex the elbow and extend the shoulder.

2. HUMERALIS OBLIQUUS.

Origin.—From the posterior surface of the humerus just below the head.

Insertion.—The tendon passes underneath the internal lateral ligament of the elbow-joint, to be attached to the radius and ulna.

Action.—To flex the elbow-joint.

POSTERIOR BRACHIAL REGION.

- | | |
|----------------------------|------------------------------------|
| 1. <i>Caput magnum</i> | } <i>Triceps extensor brachii.</i> |
| 2. " <i>medium</i> | |
| 3. " <i>parvum</i> | |
| 4. <i>Scapulo-ulnaris.</i> | 5. <i>Anconeus.</i> |

1. CAPUT MAGNUM.

Origin.—From the dorsal angle and posterior border of the scapula.

Insertion.—To the summit of the olecranon.

Action.—To extend the elbow and flex the shoulder.

2. CAPUT MEDIUM.

Origin.—From a rough line extending up from the deltoid ridge of the humerus.

Insertion.—To the olecranon.

Action.—To extend the elbow-joint.

3. CAPUT PARVUM.

Origin.—From the humerus below and behind the internal tubercle.

Insertion.—To the olecranon.

Action.—Same as preceding.

4. SCAPULO-ULNARIS.

Origin.—From the posterior border of the scapula.

Insertion.—To the posterior border of the olecranon, and to the fascia of the fore-arm.

Action.—To extend the elbow-joint and tense the fascia of the fore-arm.

5. ANCONEUS.

Origin.—From the margin of the olecranon fossa

Insertion.—To the anterior and external part of the olecranon.
Action.—The principal use of this small muscle is to raise the synovial membrane, and prevent injury to it in extension of the joint.

ANTERIOR ANTIBRACHIAL REGION.

- | | |
|--------------------------------------|---------------------------|
| 1. <i>Extensor metacarpi magnus.</i> | 3. <i>Extensor pedis.</i> |
| 2. " " <i>obliquus.</i> | 4. " <i>suffraginis.</i> |

1. EXTENSOR METACARPI MAGNUS.

Origin.—From the external condyle of the humerus.

Insertion.—To an eminence on the upper end of the large metacarpal bone, towards its inner side.

Action.—To extend the metacarpus.

Note.—Where the tendon passes over the anterior ligament of the knee it is enclosed in a synovial sheath.

2. EXTENSOR METACARPI OBLIQUUS.

Origin.—From the lower part of the outer border of the radius.

Insertion.—To the head of the inner small metacarpal bone.

Action.—Like the preceding muscle.

Note.—Where the tendon plays through the oblique groove at the lower end of the radius, a small synovial bursa is interposed.

3. EXTENSOR PEDIS.

Origin.—By a tendon (common to it and the large extensor) from the external condyle of the humerus; also from the external tuberosity of the radius, and external lateral ligament.

Insertion.—To the pyramidal process of the os pedis.

Action.—To extend the foot (more exactly, it extends the coffin, pastern, fetlock, and knee joints in succession).

Note.—The fleshy part of the muscle consists of two unequal portions, and these are succeeded by two tendons, placed close together. The outer and smaller of these (muscle of Phillips) joins the tendon of the extensor suffraginis. At

the carpus, the tendons are bound down by the annular ligament, and invested with a synovial sheath. A synovial bursa is also found at the fetlock. At the middle of the first phalanx, the branches of the suspensory ligament join the tendon.

4. EXTENSOR SUFFRAGINIS.

Origin.—From the external tuberosity and outer border of the radius; also from the external lateral ligament and the ulna.

Insertion.—To the supero-anterior part of the os suffraginis.

Action.—It extends the digit.

Note.—Two slips reinforce the tendon, one from the extensor pedis, the other from the outer side of the carpus. Where the tendon plays over the fetlock, a small bursa is interposed.

POSTERIOR ANTIBRACHIAL REGION.

- | | |
|--------------------------------------|-----------------------------------|
| 1. <i>Flexor metacarpi externus.</i> | 5. <i>Flexor pedis perforans.</i> |
| 2. <i>Flexor metacarpi medius.</i> | 6. <i>Ulnaris accessorius.</i> |
| 3. <i>Flexor metacarpi internus.</i> | 7. <i>Radialis accessorius.</i> |
| 4. <i>Flexor pedis perforatus.</i> | |

1. FLEXOR METACARPI EXTERNUS.

Origin.—From the external condyle of the humerus.

Insertion.—By two tendons; one to the trapezium, the other to the head of the outer small metacarpal.

Action.—To flex the knee.

2. FLEXOR METACARPI MEDIUS.

Origin.—From the internal condyle of the humerus, and from the olecranon.

Insertion.—To the trapezium.

Action.—Same as preceding.

3. FLEXOR METACARPI INTERNUS.

Origin.—From the internal condyle of the humerus.

Insertion.—To the head of the inner small metacarpal.

Action.—Same as preceding.

4. FLEXOR PEDIS PERFORATUS.

Origin. From the internal condyle of the humerus.

Insertion. To the lateral sides of the os coronæ (in two divisions)

Action -- To flex the pastern, fetlock and knee successively.

Note.—At the lower part of the radius, the tendon is reinforced by a fibrous band from the back of the radius. It then passes through the carpal sheath, in company with the deep flexor. On arriving behind the fetlock, it forms a remarkable ring, through which the deep flexor tendon plays.

5. FLEXOR PEDIS PERFORANS.

Origin.—From the internal condyle of the humerus.

Insertion.—To the semilunar crest of the os pedis.

Action.—To flex the foot, pastern, fetlock, and knee-joints successively.

Note.—The tendon passes through the carpal sheath, close to and in front of that of the superficial flexor. Above the knee it is joined by the ulnaris and radialis accessorius (which are in reality only portions of the perforans); and below the knee it is reinforced by the check ligament. The tendon then passes over the sesamoid pulley (through the ring formed by the perforatus), over the glenoid cartilage and the navicular bone to its insertion, where it widens out to form the plantar aponeurosis.

6. ULNARIS ACCESSORIUS.

7. RADIALIS ACCESSORIUS.

These are really heads of the perforans, arising from the ulna, and back of the radius respectively.

CARPAL SHEATH.

This is formed behind the carpus, and forms a tubular passage for the flexors of the digit. It is bounded anteriorly by

the posterior common ligament of the knee, outwardly, by the trapezium, and posteriorly by a strong fibrous band, extending from the trapezium to the inner side of the carpus. This sheath is lined by a synovial membrane, which is reflected on the flexor tendons; it extends two or three inches above the knee, and downwards to the middle of the metacarpus.

SESAMOID SHEATH.

The synovial membrane of this extends two or three inches above the fetlock, and downwards till it meets the navicular sheath.

(When distended, it bulges upwards, forming the condition known as wind-gall.)

NAVICULAR SHEATH (or bursa).

This facilitates the play of the perforans tendon over the navicular bone. It extends above the navicular bone to meet the sesamoid sheath.

METACARPAL REGION.

- | | |
|--------------------------|-------------------------------|
| 1. <i>Interossei</i> (2) | } Very small and unimportant. |
| 2. <i>Lumbrici</i> (2) | |

1. INTEROSSEI.

Origin.—Near the head of the small metacarpal.

Insertion.—To the bifurcation of the suspensory ligament.

Action.—Inappreciable.

2. LUMBRICI.

Origin.—From the deep flexor tendon above the fetlock.

Insertion.—To the fibrous basis of the ergot.

Action.—Inappreciable.

GLUTEAL REGION.

1. *Gluteus externus* (superficial gluteus).
2. *Gluteus maximus* (middle gluteus).
3. *Gluteus internus* (deep gluteus).

1. GLUTEUS EXTERNUS.

Origin.—Anteriorly from the external angle of the ilium ; posteriorly from the gluteal fascia.

Insertion.—To the trochanter minor externus of the femur.

Action.—To abduct and flex the femur ; when the leg is fixed, it assists in rearing.

2. GLUTEUS MAXIMUS.

Origin.—From the aponeurosis of the longissimus dorsi, from the upper surface of the ilium, from the sacro-iliac and sacro-sciatic ligaments, and from the gluteal fascia.

Insertion.—By one tendon to the summit of the great trochanter, by another passing over the convexity to be attached to a ridge below it, and by a fleshy slip to the back of the trochanteric ridge.

Action.—To extend and abduct the femur ; when the limb is fixed, to assist in rearing.

Note.—A synovial bursa is interposed between the second tendon of insertion and the convexity.

3. GLUTEUS INTERNUS.

Origin.—From the superior ischiatic spine, and the adjacent upper surface of the ilium.

Insertion.—To the inner side of the convexity of the great trochanter.

Action.—It abducts the femur and rotates it inwards.

ANTERIOR FEMORAL REGION.

1. *Tensor fasciæ late.*

2. *Rectus femoris.*

3. *Vastus externus.*

4. *Vastus internus.*

5. *Rectus parvus*

} Triceps cruralis.

1. TENSOR FASCLE LATE.

Origin.—From the external angle of the ilium.

Insertion.—To the fascia lata.

Action.—To flex the femur and tense the fascia lata.

Note.—The fascia lata is a continuation downward of the gluteal fascia, forming a sheath for the muscles of the thigh. It divides into a superficial and a deep layer. The former becomes attached to the patella, the latter passes between the triceps abductor femoris and vastus externus, to be attached to the external border of the femur.

2. RECTUS FEMORIS.

Origin.—By two heads from two depressions in front of the acetabulum.

Insertion.—To the anterior surface of the patella.

Action.—To flex the hip joint and extend the stifle.

3. VASTUS EXTERNUS.

Origin.—From the external border and external half of the anterior surface of the femur.

Insertion.—To the patella.

Action.—To extend the stifle.

4. VASTUS INTERNUS.

Origin.—From the internal border and inner half of the anterior surface of the femur.

Insertion.—To the patella.

Action.—To extend the stifle.

5. RECTUS PARVUS.

Origin.—From the ilium, just external to the outer head of the rectus femoris.

Insertion.—To the femur just below the head, and to the capsular ligament.

Action.—To tense the capsular ligament during flexion of the femur.

Note.—No distinct crureus muscle is present in the horse.

POSTERIOR FEMORAL REGION.

1. *Triceps abductor femoris.*

2. *Biceps rotator tibialis (Semitendinosus).*

3. *Adductor magnus (Semimembranosus).*

1. TRICEPS ABDUCTOR FEMORIS.

Origin.—From the sacral spines, sacro-sciatic ligament, and tuberosity of the ischium.

Insertion.—To the back of the femur between the two trochanters, to the patella, to the tibial crest, and to the fascia of the thigh.

Action.—The anterior part of the muscle extends the stifle, and abducts the hip; the posterior part flexes the stifle and rotates it outwards. When the leg is fixed, it assists in rearing.

2. BICEPS ROTATOR TIBIALIS.

Origin.—Sacral spines, sacro-sciatic ligament, and tuberosity of the ischium.

Insertion.—To the tibial crest.

Action.—To flex the stifle and rotate the leg inwards. Or to aid in rearing.

3. ADDUCTOR MAGNUS.

Origin.—From the inferior surface and tuberosity of the ischium, and from the coccygeal fascia.

Insertion.—To the internal condyle of the femur.

Action.—To adduct and extend the hip; or to assist in rearing.

INTERNAL FEMORAL REGION.

1. *Sartorius.*6. *Ischio-femoralis.*2. *Gracilis.*7. *Obturator externus.*3. *Pectineus.*8. *Obturator internus*4. *Adductor brevis.*9. *Pyriformis.*5. *Adductor longus.*10. *Gemellus.*

1. SARTORIUS.

Origin.—From the iliac fascia, near the tendon of the psoas parvus.

Insertion.—To the internal straight ligament of the patella.

Action.—To adduct the leg, and flex the hip.

2. GRACILIS.

Origin.—From the ischio-pubic symphysis, being united to its fellow of the opposite side.

Insertion.—To the internal straight ligament of the patella, and to the supero-internal surface of the tibia.

Action.—To adduct the limb and rotate it inwards.

3. PECTINEUS.

Origin —From the brim and inferior surface of the pubis, on each side of the pubio-femoral ligament, from which some fibres arise.

Insertion.—To the internal border of the femur, near the nutrient foramen.

Action —To adduct the limb and flex the hip.

4. ADDUCTOR BREVIS

Origin —From the inferior surface of the pubis.

Insertion.—To the posterior surface of the femur, near its middle.

Action.—To adduct the femur and rotate it outwards.

5. ADDUCTOR LONGUS.

Origin.—From the inferior surface of the ischium.

Insertion.—To the back of the femur, with the brevis, and to the supracondyloid crest.

Action.—To adduct the femur and rotate it outwards.

6. ISCHIO-FEMORALIS.

Origin.—From the inferior surface of the ischium.

Insertion.—To an oblique line on the back of the femur, near the inner trochanter.

Action.—To extend and adduct the femur.

7. OBTURATOR EXTERNUS

Origin.—From the inferior surface of the ischium and pubis, around the obturator foramen.

Insertion.—In the trochanteric fossa.

Action.—To adduct, extend, and rotate the femur.

8. OBTURATOR INTERNUS.

Origin.—From the upper surface of the pubis and ischium, around the obturator foramen.

Insertion.—In the trochanteric fossa, by a tendon common to it and the pyriformis.

Action.—To rotate the thigh outward.

9. PYRIFORMIS.

Origin.—From the inferior surface of the ilium.

Insertion.—In the trochanteric fossa.

Action.—Same as preceding.

Note.—The two preceding muscles have a common tendon which emerges from the pelvic cavity by the lesser sacro sciatic foramen.

10. GEMELLUS.

Origin.—From the external border of the ischium.

Insertion.—In the trochanteric fossa.

Action.—Same as preceding.

Note.—The Gemellus is a single muscle in the horse, consisting of anterior and posterior rounded fasciculi, united by a thin median portion, concealed by the common tendon of the obturator internus and pyriformis.

ANTERIOR TIBIAL REGION.

1. *Extensor Pedis.*

3. *Flexor Metatarsi.*

2. *Peroneus.*

1. EXTENSOR PEDIS.

Origin.—From the pit between the external condyle and trochlea of the femur, in common with the tendinous portion of the flexor metatarsi.

Insertion.—To the pyramidal process of the os pedis.

Action.—To extend the foot, pastern, and the fetlock, and to flex the hock.

Note.—At the front of the hock, the tendon is bound down by three fibrous bands. About the middle of the metatarsus,

it is joined by the tendon of the peroneus, and by the extensor pedis brevis. A small synovial bursa is interposed between the tendon and the anterior ligament of the fetlock. About the middle of the os suffraginis, it is joined by the branches of the suspensory ligament.

2. PERONEUS.

Origin.—From the external lateral ligament of the stifle, and from the fibula.

Insertion.—It joins the tendon of the extensor pedis below the hock.

Action.—To assist the extensor pedis.

3. FLEXOR METATARSI.

Origin.—

(a) *Tendinous portion.*—From the pit between the external condyle and trochlea of the femur.

(b) *Fleshy portion.*—From the supero-external surface of the tibia.

Insertion.—

(a) To the upper extremity of the large metatarsal, and to the cuboid.

(b) To the upper extremity of the large metatarsal and to the cuneiform parvum.

Action.—To flex the hock. In this, the tendinous portion acts only mechanically, flexing the hock when the stifle is flexed.

Note.—At the front of the hock, the tendinous portion is perforated for the passage of the tendon of the muscular portion.

POSTERIOR TIBIAL REGION.

1. *Gastrocnemius* (externus).
2. *Flexor pedis perforatus* (gastrocnemius internus).
3. *Soleus* (Plantaris).
5. *Flexor pedis perforans*.
4. *Popliteus*.
6. *Flexor pedis accessorius*.

1. GASTROCNEMIUS.

Origin.—By two heads, one from each side of the supracondyloid fossa of the femur.

Insertion.—To the middle of the summit of the os calcis.

Action.—To extend the hock.

Note.—A small synovial bursa is interposed between the tendon and the forepart of the summit of the os calcis.

2. FLEXOR PEDIS PERFORATUS.

Origin.—From the supracondyloid fossa.

Insertion.—To the summit of the os calcis, and to the sides of the os coronae.

Action.—To flex the pastern and fetlock, and to extend the hock.

Note.—This muscle is almost entirely tendinous in character. Its tendon winds round the inner side of the gastrocnemius tendon to reach the back of it, and the summit of the os calcis. It plays over and forms a cap over the latter, to which some fibres are attached, a synovial bursa being interposed. An important action of this muscle is its mechanical one of assisting the animal to stand, while the hip and stifle joints are kept extended.

3. SOLEUS.

Origin.—From the head of the fibula.

Insertion.—It joins the tendon of the gastrocnemius

Action.—To assist (very slightly), the gastrocnemius.

4. POPLITEUS.

Origin.—From the lower depression on the external condyle of the femur.

Insertion.—To a triangular surface on the back of the tibia (above the oblique line)

Action.—To flex the stifle, and (slightly) to rotate it inwards.

5. FLEXOR PEDIS PERFORANS.

Origin.—From the posterior surface of the tibia below the oblique line, from the external tuberosity, and from the fibula.

Insertion.—To the semilunar crest of the os pedis.

Action.—To flex the coffin, pastern and fetlock joints, and to extend the hock in succession.

Note.—This muscle is indistinctly divided into outer and inner portions, with two tendons. These soon unite and pass through the tarsal sheath. The tendon below the hock is joined by the check ligament, which is not so strong as that of the fore limb. Below this the arrangement is identical with that of the fore limb.

6. FLEXOR PEDIS ACCESSORIUS.

Origin.—From the external tuberosity of the tibia.

Insertion.—It joins the perforans, after passing through a synovial theca at the inner side of the tarsus.

Action.—To assist the deep flexor.

TARSAL SHEATH.

This is a tubular passage at the back of the tarsus. It is bounded anteriorly by the posterior common and tarso-metatarsal ligaments, externally by the os calcis, and postero-internally by a fibrous band. It is lined by a synovial membrane, which is reflected on the flexor tendon, extending upwards two or three inches, and downwards below the middle of the metatarsus. (Distension of this sac is known as “thorough-pin”).

METATARSAL REGION (unimportant).

1. *Extensor pedis brevis.* 3. *Interossei* (2).

2. *Lumbrici* (2).

1. EXTENSOR PEDIS BREVIS.

Origin.—From the os calcis and astragalus.

Insertion.—It joins the tendons of the extensor pedis and peroneus at their angle of union, to which its

Action.—Is auxiliary.

The lumbrici and interossei are exactly similar to those of the fore limb.

Webster Family Library of Veterinary Medicine
Cummings School of Veterinary Medicine at
Tufts University
200 Westboro Road
North Grafton, MA 01536

